Received: 8 May 2019 | Accepted: 8 August 2019

DOI: 10.1002/cia2.12080

ORIGINAL ARTICLE

Journal of Cutaneous Immunology and Allergy

WILEY

Three cases of photoallergic contact dermatitis induced by the ultraviolet absorber benzophenone that occurred after dermatitis due to ketoprofen-Investigation of cosensitization with other ultraviolet absorbers and patient background

Tomoko Tanahashi[1] | Kazumi Sasaki[2] | Mitsuru Numata[2] | Kayoko Matsunaga[3,4]

[1]Wakatsu Clinic, Fukuoka, Japan

[2]Biological Resource Center, National Institute of Technology and Evaluation, Tokyo, Japan

[3]Department of Integrative Medical Science for Allergic Disease, Fujita Health University School of Medicine, Aichi, Japan

[4]SSCI-Net, Aichi, Japan

Correspondence
Tomoko Tanahashi, Wakatsu Clinic, 2585-6 Mukaijima Okawa-shi, Fukuoka 831-0005, Japan.
Email: tanahashi@ozuma-med.or.jp

Abstract

Objectives: Three teenage patients developed dermatitis at the site of contact of a free-pass wristband from an amusement park. Each had experienced dermatitis due to ketoprofen. A chemical analysis of the components of the wristband and patch testing determined that the cause of the dermatitis was benzophenone, and this reaction was considered to be due to the cross-reaction of ketoprofen and benzophenone. Because those who are photosensitized to ketoprofen are often known to coreact with several ultraviolet absorbers, we investigated the presence of cosensitization to various ultraviolet absorbers in the three patients. We also wanted to explore the background of how photosensitization to ketoprofen can occur in such young individuals.

Methods: The three patients underwent patch testing and photopatch testing with various ultraviolet absorbers. We also conducted a questionnaire survey of patients using ketoprofen-containing topical medications.

Results: Positive photoallergic reactions were observed only with benzophenone-3, benzophenone-4, and octocrylene. The frequency of positive reactions was higher than in previous studies of cases after ketoprofen sensitization. About half of patients using topical medications containing ketoprofen did not know that ketoprofen could cause photocontact dermatitis. Most patients did not know about the duration of avoidance of ultraviolet exposure.

Conclusions: It is possible that photocontact allergy to substituted benzophenones and octocrylene was strongly established by being sensitized twice to ketoprofen and benzophenone. Sensitization to ketoprofen sometimes occurs at a young age, probably because of insufficient communication of the risk of photosensitization.

KEYWORDS

benzophenone, coreact, ketoprofen, surveys and questionnaires, ultraviolet absorber

This is an open access article under the terms of the Creative Commons Attribution-NonCommercial License, which permits use, distribution and reproduction in any medium, provided the original work is properly cited and is not used for commercial purposes.
© 2019 The Authors. *Journal of Cutaneous Immunology and Allergy* published by John Wiley & Sons Australia, Ltd on behalf of The Japanese Society for Cutaneous Immunology and Allergy

1 | INTRODUCTION

Three patients who experienced photocontact dermatitis from using ketoprofen-containing tape between the ages of 9 and 15 years developed photocontact dermatitis induced by benzophenone contained in an amusement park wristband in their teens.[1] Because benzophenone is the main component of the chemical structure of ketoprofen, this dermatitis was thought to be due to cross-sensitization to ketoprofen. Benzophenone was included as an ultraviolet (UV) absorber in the wristband.

Ketoprofen is a well-known cause of photoallergic or photoexacerbated contact dermatitis. Ketoprofen is known to cross-react with benzophenone-type UV absorbers.[2–5] Furthermore, octocrylene, a UV absorber first used in the latter half of the 1990s, was also reported to cause photoallergic contact dermatitis[6–8] in the 2000s. Octocrylene itself has low structural similarity to ketoprofen, but it is reported that those sensitized to ketoprofen often react to octocrylene.[9,10] We examined the presence or absence of sensitization and photosensitization to various UV absorbers, including octocrylene or substituted benzophenones, in these three teenage patients.

After 2010, the European Medicines Agency reviewed and examined the balance of benefit and risk with the use of ketoprofen in Europe,[11] and ketoprofen was also reevaluated in Japan in 2010. Results indicated that the photosensitivity of ketoprofen was slightly higher than or equivalent to that of other analgesics and that there were few severe cases in Japan. In Europe[11] and in Japan,[12,13] decisions on countermeasures for the prevention of photosensitivity dermatitis were made. However, even now, dermatologists often encounter patients with dermatitis due to ketoprofen in routine practice. Because several teenagers experienced photoallergic contact dermatitis induced by benzophenone due to cross-sensitization to ketoprofen at a young age, a questionnaire survey was performed with patients using ketoprofen to investigate the potential reasons why photosensitization to ketoprofen occurs in young people.

2 | METHODS

2.1 | Patients and determination of the cause of dermatitis

As shown in Table 1, all three patients had been treated from 2013 to 2016, when they were less than 15 years old, for dermatitis caused by ketoprofen-containing tape (Mohrus®; Hisamitsu Pharmaceutical Co., Inc., Tosu, Japan) topically applied on the lower legs or dorsum of the foot. In August and September 2017, dermatitis developed on the right wrist of each of these patients after they wore an amusement park wristband (Case 3; Figure 1A).[1] All had dermatitis with relatively strong inflammation, and their treatment required systemic and topical corticosteroid administration. As a result of a patch test and a photopatch test with 2.5% ketoprofen, ketoprofen photoallergy was established (Case 1; Figure 1C). These cases were reported to SSCI-Net (Skin Safety Care Information Network), which was founded in April 2016 with the aim of early discovery and minimization of skin damage through cooperation with doctors (mainly dermatologists), enterprise, and administration. The SSCI-Net acquired the wristband (Figure 1B), and the chemical analysis of its components was carried out in cooperation with related organizations (Biological Resource Center, National Institute of Technology and Evaluation).

Gas chromatography revealed that benzophenone (Figure 2) was included as a UV absorber in the wristband in large amounts. We performed a patch test and a photopatch test with the detected substances in the wristband to identify the cause of dermatitis. Only the photopatch test of 1% benzophenone showed a positive reaction (Case 3; Figure 1D) in all three patients. Therefore, the dermatitis from the wristband was diagnosed as photoallergic contact dermatitis induced by benzophenone.

2.2 | Patch testing and photopatch testing of various UV absorbers

All three patients underwent patch testing and photopatch testing with various UV absorbers (Table 2). All UV absorbers were allergEAZE allergens (SmartPractice, Calgary, Canada). Among these allergens, benzophenone-3 and benzophenone-4 (Figure 2) are benzophenone-type UV absorbers. Octocrylene (Figure 2) is not a benzophenone-type absorber, but many reports indicate that octocrylene coreacts with ketoprofen.[9,10,14] The trade names of the UV absorbers and their UV absorption wavelengths, the number of domestic products using them, and other features are listed in Table 2.

The patch test was applied to each patient's back with Finn Chambers® on Scanpor® tape (SmartPractice, Yokohama, Japan) for 2 days. The reactions were assessed 20 minutes later, and an additional 1 or 2 days and 5 days after removal, according to ICDRG/ESCD recommendations.[15] On the side opposite the closed patch testing, test substances were closed patched symmetrically for 2 days and then irradiated with 5 J/cm^2 UVA (Terumo Clinical Supply Co., Ltd., Gifu, Japan). Readings were performed 1 or 2 days and 5 days after irradiation, based on ICDRG/ESCD recommendations.[15] All procedures used in this research were approved by the Ethics Committee of Fujita Health University School of Medicine (HM 17–258).

2.3 | Questionnaire survey of patients using ketoprofen

We conducted a questionnaire survey of patients who were prescribed ketoprofen-containing topical products at other medical institutions and who visited Fujita Health University Bantane Hospital or Wakatsu Clinic (Figure 3). This study was approved by the Ethical Committee of Fujita Health University School of Medicine (HM19-132).

TABLE 1 Patient characteristics

	Sex	Age of onset of dermatitis by ketoprofen tape	Site of application of ketoprofen tape	How ketoprofen tape was obtained	Age of onset of dermatitis induced by amusement park wristband	Results of patch and photopatch test of 1% benzophenone	
						UV+	UV−
Case 1	M	9	Lower leg	From his grandfather	10	+	−
Case 2	M	11	Dorsum of the foot	Prescribed	15	+ +	−
Case 3	F	15	Lower leg	From her father	18	+ +	−

Note: Tomoko et al.[1]
Abbreviations: F, female; M, male; UV, ultraviolet.

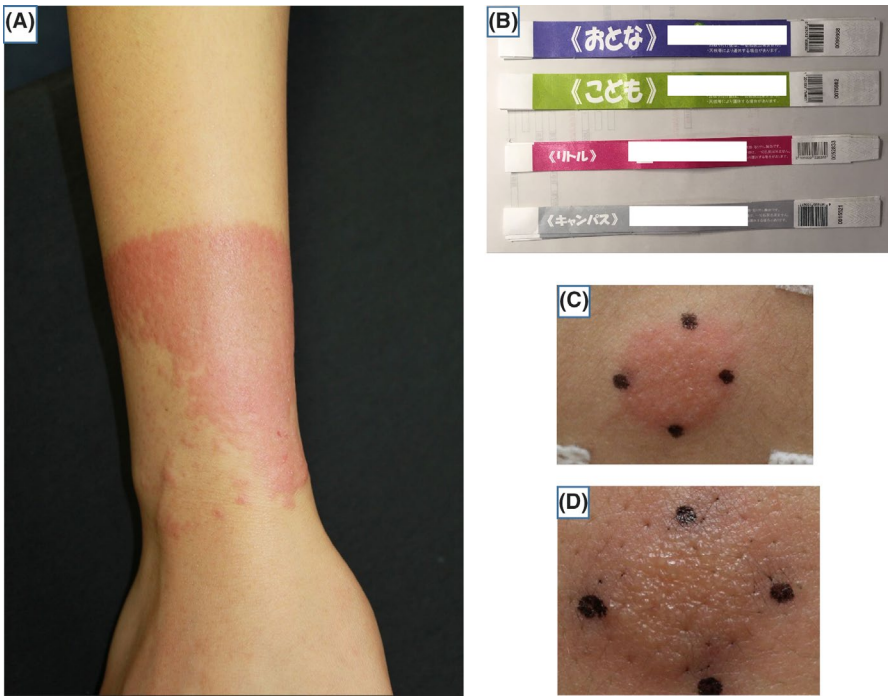

FIGURE 1 Three patients who had been treated for photocontact dermatitis caused by ketoprofen-containing tape and who had a positive photoallergic reaction to ketoprofen developed dermatitis after wearing an amusement park wristband (reproduced with permission from *Contact Dermatitis*). A, Case 3: An enlarged band-shaped erythema. Photograph was taken when the patient visited Wakatsu Clinic one week after she wore a wristband on her right wrist. B, Four different wristbands used as a free pass at an amusement park. C, Case 1: Photopatch test showing a strong positive reaction to 2.5% ketoprofen, 1 d after 5 J/cm^2 UVA irradiation. D, Case 3: Photopatch test showing a strong positive reaction to 1% benzophenone 1 d after 5 J/cm^2 UVA irradiation. (Ref. [1])

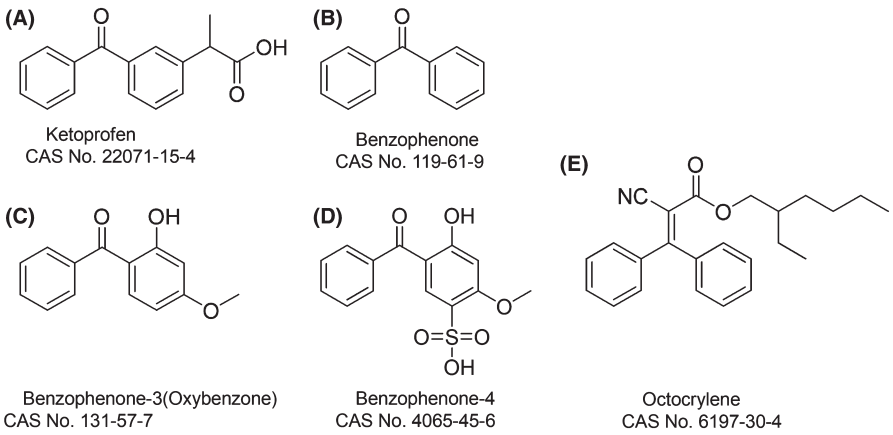

FIGURE 2 The chemical structures of ketoprofen, benzophenone, benzophenone-3, benzophenone-4, and octocrylene. Benzophenone is the main component of the ketoprofen chemical structure. Octocrylene has low structural similarity to ketoprofen

TABLE 2 UV absorbers patch-tested and photopatch-tested, and their features

Allergen	Test concentration and vehicle	Trade name	Absorbing ultraviolet wavelength	Number of products in Japan (at least)[a]	Other features
2-Ethylhexyl-*p*-methoxycinnamate	10% pet	Parsol MCX Eusolex 2292	UVB	7526	Effective UV absorber
4-*tert*-Butyl-4'-methoxydibenzoylmethane	10% pet	Parsol 1789 Eusolex 9020	UVA	1830	Effective UV absorber, poor solubility
Octocrylene	10% pet	Escalol 597 Eusolex OCR	Long UVB ~ short UVA	909	Not effective UV absorber, excellent photostability, water resistance
Benzophenone-3	10% pet	Uvinul M Eusolex 4360	UVB ~ UVA	750	Not effective UV absorber
Benzophenone-4	2% pet	Uvinul MS-40	UVB ~ UVA	315	Water-soluble, antifading
Methylene-bis-benzotriazolyl tetramethylbutylphenol	10% pet	Tinuvin 360 Tinosorb M	UVB ~ UVA	219	Micronization, excellent photostability
Phenylbenzimidazole sulfonic acid	10% pet	Eusolex 232	UVB	160	Water-soluble, combined with oil-soluble UV absorber
2-Ethylhexyl-4-dimethylaminobenzoate	10% pet	Escalol 507 Eusolex 6007	UVB	33	Effective UV absorber, high solubility
3-(4-Methylbenzylidene)camphor	10% pet	Eusolex 6300	UVB	2	Available in Europe (4% or less)
Isoamyl-4-methoxycinnamate	10% pet	Neo Heliopan E1000	UVB	6	Antifading
para-Aminobenzoic acid	5% pet	-	UVB	0	Currently not used, may provide a sunscreen effect after ingestion
Methyl anthranilate	5% pet	Meradimate	UVA	0	Sunscreen commercially available in the United States

Abbreviations: pet, petrolatum; UV, ultraviolet.
[a]https://www.cosmetic-info.jp (accessed August 1, 2019).

This questionnaire is intended for patients who have received this poultice/external preparation. Your cooperation is appreciated.

Ⅰ. Where on your body did a doctor tell you to apply this poultice/external preparation? (Please circle all that apply)
1. shoulder 2. lower back 3. knee 4. elbow 5. nape 6. wrist 7. back 8. ankle 9. other ( )

Ⅱ. Have you ever applied this poultice or external preparation outside of the area instructed by the doctor?

Ⅲ. Have you ever given this poultice or external preparation to others? (Please do not hesitate to answer, as this is just a questionnaire.)

Ⅳ. Did you know that this poultice/external preparation may cause a rash when it is exposed to UV light?

Ⅴ. To those who answered Yes in Ⅳ, Who provided the explanation? (Please circle all applicable items.)
1. prescribing doctor
2. pharmacist
3. prescribing doctor and pharmacist
4. other doctors / pharmacists
5. awareness by self (How did you notice it? _____)

Ⅵ. To those who answered Yes in Ⅳ, When do you need to be careful not to be exposed to UV rays?
Please choose from the following: 1 or 2, a., b., c., d.
1. only while putting on the poultice
2. after peeling off the poultice
a. 1 day b. 1 week c. one month d. one month or more

Ⅶ. To those who answered No in Ⅳ
1. I do not remember receiving an explanation.
2. I think that there was no explanation.

FIGURE 3 Questionnaire given to patients who were prescribed ketoprofen-containing external preparations at other hospitals

3 | RESULTS

3.1 | Results from patch tests and photopatch tests with UV absorbers

None of the three patients had a positive reaction to any of the UV absorbers other than benzophenone-3, benzophenone-4, and octocrylene (Table 3). In Case 1, contact sensitization was established with octocrylene. Because the patient was 10 years old, we stopped UVA irradiation on the site with octocrylene to avoid further sensitization.

Positive photoallergic reactions were observed in 3/3 tests with benzophenone-3, 2/2 tests with octocrylene, and 2/3 tests with benzophenone-4 (Table 3, Figure 4).

3.2 | Results from the questionnaire survey of patients using ketoprofen-containing external preparations

The questionnaire survey was given to 373 patients. Because there were several elderly individuals among the relevant patients, we targeted those whose cognitive function was clearly maintained. The results are shown in Figure 5. Most (86%) of the patients prescribed ketoprofen-containing external preparations at other medical institutions and who participated in the survey were over the age of 60; 4% were under the age of 19. The sites instructed for topical application included parts that could be exposed to UV light, such as the wrist, knee, ankle, and nape. More than 40% of those surveyed used the preparations outside of the site instructed for topical

TABLE 3 Results from patch tests and photopatch tests with benzophenone-3 and octocrylene and benzophenone-4

UV absorber		Benzophenone-3			Octocrylene			Benzophenone-4		
Reading time		2 D	3 D or 4 D	7 D	2 D	3 D or 4 D	7 D	2 D	3 D or 4 D	7 D
Case 1	UV +	–	–	+ +	NT	NT	NT	–	–	+
	UV –	–	–	–	+	+	+	–	–	–
Case 2	UV +	-	–	+	–	–	+	–	–	–
	UV –	–	–	–	–	–	–	–	–	–
Case 3	UV +	–	+	+ +	–	+	+ +	+ ?	–	+ +
	UV –	–	–	–	–	–	–	–	–	–

Note: In Case 1, contact sensitization was established with octocrylene. Because the patient was 10 years old, we stopped UVA irradiation on the site with octocrylene to avoid further sensitization.
Abbreviations: D, day; NT, not tested; UV, ultraviolet.

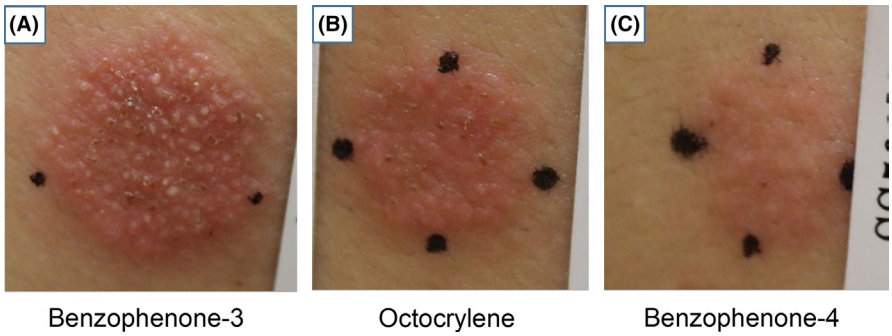

FIGURE 4 Strong positive photopatch test reactions were observed to A, benzophenone-3, B, octocrylene, and C, benzophenone-4 on day 7 in Case 3

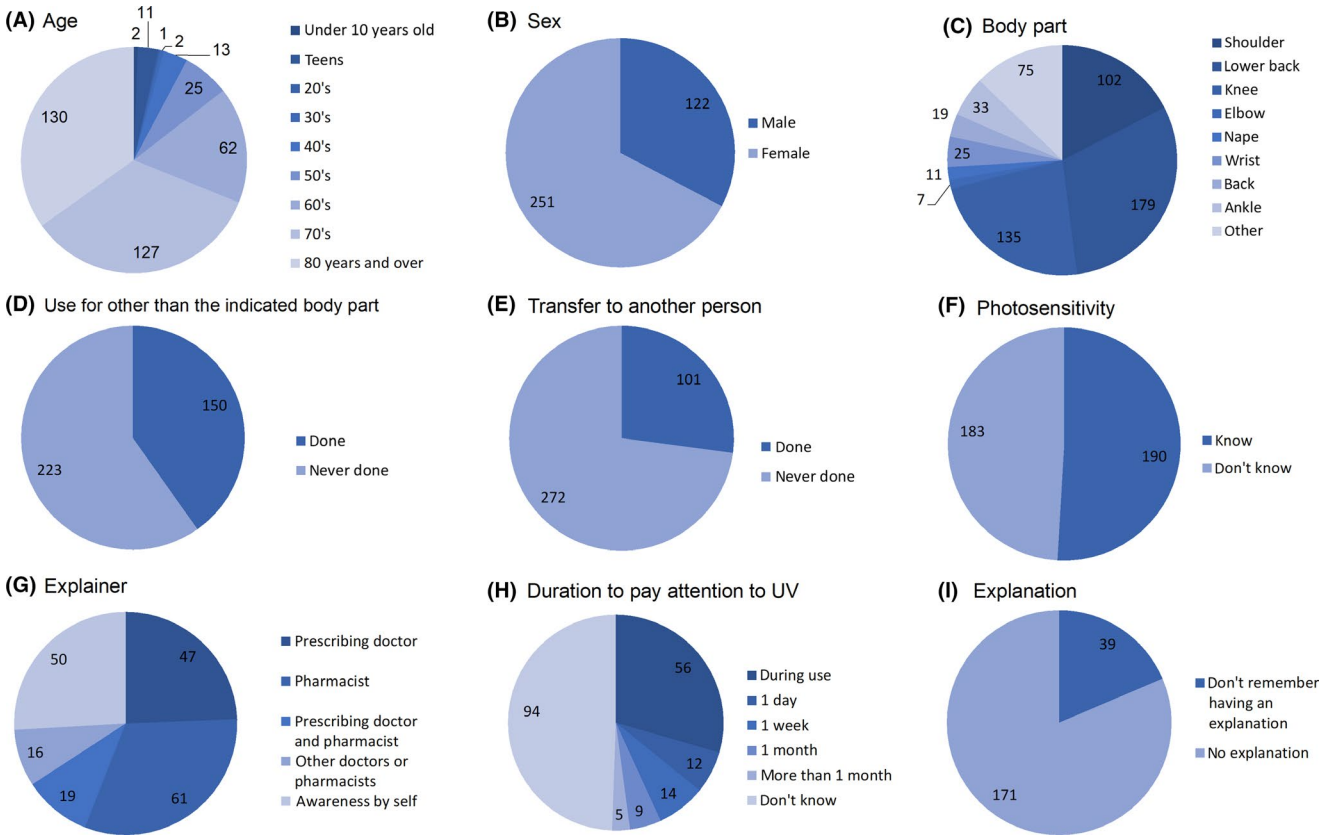

FIGURE 5 Results of questionnaires given to patients prescribed ketoprofen-containing external preparations. A, Age distribution. B, Sex distribution. C, Body part where the doctor told patients to apply the poultice/external preparation. D, Whether the patient applied the poultice or external preparation outside the area instructed by the doctor. E, Whether the patient had given the poultice or external preparation to others. F, Patient knowledge that the poultice/external preparation may cause a rash when exposed to UV light. G, Provider of knowledge of UV photosensitivity. H, Knowledge of period to avoid exposure to ultraviolet rays. I, No explanation of photosensitivity provided or recalled?

application. More than a quarter of those gave others the prescribed ketoprofen-containing products. About half did not know that ketoprofen could cause photocontact dermatitis. Among those who did know, about 66% learned about it from doctors and pharmacists at the time it was prescribed, and about 26% had noticed the warning, from the description on the product package, or learned about it from others or through the press. Most of the patients who knew that ketoprofen could cause photocontact dermatitis did not know about the duration of avoidance of UV exposure.

4 | DISCUSSION

Ketoprofen, which was synthesized in the late 1960s, has been used as a topical anti-inflammatory analgesic since the early 1970s in Europe and since the latter half of the 1980s in Japan. It is a nonsteroidal anti-inflammatory agent that is a derivative of benzophenone, and it is a well-known cause of photoallergic or photoexacerbated contact dermatitis.[2,16–20] Since the 1990s, it has been known that ketoprofen cross-reacts with

benzophenone-type UV absorbers.[2–5] Cross-reaction of the benzophenone-type UV absorbers benzophenone-3 and benzophenone-4 with ketoprofen was investigated. Benzophenone-3 cross-reacts with ketoprofen relatively frequently, and benzophenone-4 is less likely to cross-react[2,20–22] due to the substitution of the side chain.[21]

Since the 2000s, octocrylene was also reported to cause photoallergic contact dermatitis and often coreacts with ketoprofen.[9,10] As for octocrylene, since structural similarity with ketoprofen is low, the reason for photo-coreactivity is not well understood.[23]

Patch tests and photopatch tests of various kinds of UV absorbers were performed in these cases, and as a result, only octocrylene, benzophenone-3, and benzophenone-4 showed positive reactions.

When the results of the patch test and photopatch test of benzophenone-3 and benzophenone-4 were compared, it was found that in the case of benzophenone-3, positive photopatch test reactions occurred in all three patients, and that in the case of benzophenone-4, positive photopatch test reactions occurred in only 2 of the 3 patients. When positive photopatch test reactions were compared, the positive reaction to benzophenone-4 was somewhat weaker than that to benzophenone-3. In addition, contact allergy was not established with either benzophenone-3 or benzophenone-4. In past reports, among individuals who had an established photocontact allergy to ketoprofen, a photocontact allergy to benzophenone-3 was established in 17% to 88%[2,20–24] and to benzophenone-4 was established in 0%.[2,20–22] In these 3 cases, photocontact allergy was established more frequently than in past reports.

It was possible that photocontact allergy to benzophenone-type UV absorbers was strongly established by being sensitized twice to benzophenone-type antigens, ketoprofen and benzophenone.

On the other hand, photocontact allergy to octocrylene is seen mostly in adult patients based on previous photosensitization to ketoprofen, and contact allergy to octocrylene is considerably less frequent,[10,25] but it is mainly observed in children as a result of sensitization to octocrylene in sunscreen products.[10,25] In Case 1, contact sensitization was established to octocrylene. Because the patient was 10 years old, we stopped UVA irradiation on the site with octocrylene to avoid further sensitization. Therefore, it has not been confirmed whether photoexacerbation of contact allergy to octocrylene occurs in this patient. However, he did not have a history of sunscreen intolerance, and he has never experienced dermatitis in exposed areas other than dermatitis by ketoprofen. Photocontact allergy or photoexacerbation of contact allergy has been established for ketoprofen, benzophenone, benzophenone-3, and benzophenone-4 (Figure 1C, Table 1 and 3). Based on the above findings, we suggest that sensitization to octocrylene in Case 1 could have been established not from sensitization to octocrylene by sunscreen products, but from the previous sensitization to ketoprofen and benzophenone. In past reports, among individuals who had established photocontact allergy to ketoprofen, photocontact allergy to octocrylene was established in 13% to 80% [10,14,22,24]. Positive photopatch test reactions to octocrylene were observed in 2 of the two patients, because UV irradiation was not performed in Case 1.

It was possible that photocontact allergy to octocrylene was strongly established by being sensitized twice to ketoprofen and benzophenone.

Octocrylene itself is not an efficient UV absorber, but in combination with other UV absorbers, it enhances UV absorbing ability and improves water resistance and photostability. It prevents deterioration due to sun exposure of cosmetics containing other UV absorbers and sun exposure of the skin. The use of octocrylene in sunscreens and daily cosmetics has been rapidly increasing recently. Octocrylene was an ingredient in more than 80% of sunscreen products and in more than 20% of daily cosmetic products in Europe and the United States in 2014.[25] Also in Japan, the number of cosmetic products containing octocrylene has increased to at least 909 (Table 2) in 2019 and continues to increase.

Considering that much of the sensitization to benzophenone-type UV absorbers and to octocrylene occurs after photosensitization to ketoprofen, measures against ketoprofen misuse are important.[10,14] In Japan, measures for ketoprofen use were reconsidered in 2010.[12,13]

In the case of the commercial marketing of ketoprofen-containing external preparations, it was decided to display them within 7 m of facilities that can provide information, not to use them concomitantly with octocrylene-containing products, and to caution that it is necessary to avoid UV exposure for 4 weeks after use.

Regarding the prescription of ketoprofen-containing external preparations, it was decided to provide detailed information to medical staff and to improve the instructions for use on the product package.

In Europe, measures against ketoprofen misuse were considered prior to those in Japan. In Europe, unlike in Japan, ketoprofen is no longer on the market, and it is only used if prescribed by a doctor.[11]

Even after taking such countermeasures, clinicians often see patients with photocontact dermatitis induced by ketoprofen and sensitization to ketoprofen established at a young age, as in these cases. We assessed the actual conditions of use by conducting a questionnaire survey of patients who were actually prescribed ketoprofen-containing topical medicines.

The indication for prescription of ketoprofen is determined by disease; there are no constraints on the site of use. For that reason, at the time of prescription, some patients received instructions for external application to body parts that may be subjected to UV exposure.

Many patients handed these products over to others. Since the poultice itself is a single-purpose product, it seems that hurdles for transfer are lower than with typical external skin preparations. Indeed, two of our three patients actually developed dermatitis with ketoprofen-containing tape that they obtained from their families (Table 1).

Only 51% of the patients knew that ketoprofen could cause photosensitization. At the time of prescription, 51% × 66% = 34% (about

one-third) understood that ketoprofen could cause photosensitization based on the explanation of a doctor or pharmacist.

Most patients did not know the period during which they could develop photosensitivity or had the misunderstanding that the period was only during the time when drugs were applied. For that reason, some people thought that it would not be necessary to avoid UV exposure during the day, because they were putting on a poultice overnight. At the time of prescription, 51% × 3% = 1.5% (about 1/67th) understood that body parts where ketoprofen-containing external preparations were applied should not be exposed to UV radiation for more than 4 weeks.

With any medication, there is a dissociation between the explanation provided by a doctor or pharmacist on how to use it and the detail with which the patient remembers that explanation. As long as patients have difficulty remembering how they were told to use ketoprofen-containing external preparations, the risk of photosensitization will not decrease. It is necessary to improve the provision of information to the medical staff concerning photosensitization of ketoprofen and to improve explanations from the medical staff to the patient at the time of prescription.

A sufficient explanation at the time of prescription is required as a measure to prevent photosensitization to ketoprofen, but this is not fully communicated to patients. It is presumed that the fact that sensitization to ketoprofen is established at a young age is due to such circumstances, as we experienced with our cases.

ACKNOWLEDGEMENTS

We thank the staff of SSCI-Net for consistently engaging in communication with related organizations and the staff of the Department of Integrative Medical Science for Allergic Disease, Fujita Health University. We also thank the staff of Biological Resource Center, National Institute of Technology and Evaluation, for assisting with the chemical analysis. We are very grateful to the staff of Wakatsu Clinic for helping with the patch testing and photopatch testing and the questionnaire survey.

CONFLICTS OF INTEREST

Kayoko Matsunaga is the chair of the department donated by Hoyu Co., Ltd. The other authors declare no potential conflicts of interest.

ORCID

Tomoko Tanahashi https://orcid.org/0000-0002-0202-6138

REFERENCES

1. Tomoko T, Kazumi S, Mitsuru N, Kayoko M. Three cases of photoallergic contact dermatitis induced by benzophenone in amusement park wristbands. Contact Dermatitis. 2019;80(3):191–3.
2. Hindsén M, Zimerson E, Bruze M. Photoallergic contact dermatitis from ketoprofen in southern Sweden. Contact Dermatitis. 2006;54(3):150–7.
3. Horn HM, Humphreys F, Aldridge RD. Contact dermatitis and prolonged photosensitivity induced by ketoprofen and associated with sensitivity to benzophenone-3. Contact Dermatitis. 1998;38(6):353–4.
4. Kawada A, Aragane Y, Asai M, Tezuka T. Simultaneous photocontact sensitivity to ketoprofen and oxybenzone. Contact Dermatitis. 2001;44(6):370.
5. Veyrac G, Paulin M, Milpied B, Bourin M, Jolliet P. Results of a French nationwide survey of cutaneous side effects of ketoprofen gel reported between September 1996 and August 2000. Therapie. 2002;57(1):55–64.
6. Carrote-Lefebvre I, Bonnevalle A, Segard M, Delaporte E, Thomas P. Contact dermatitis to octocrylene. Contact Dermatitis. 2003;48(1):46–7.
7. Vigan M. REVIDAL-GERDA: organisation and collaboration with pharmacovigilance [in French]. Therapie. 2002; 57(3): 263–4.
8. Pigatto PD, Guzzi G, Schena D, Guarrera M, Foti C, Francalanci S, et al. Photopatch tests: an Italian multicentre study from 2004 to 2006. Contact Dermatitis. 2008;59(2):103–8.
9. Foti C, Bonamonte D, Conserva A, Stingeni L, Lisi P, Lionetti N, Rigano L, Angelini G. Allergic and photoallergic contact dermatitis from ketoprofen: evaluation of cross-reactivities by a combination of photopatch testing and computerized conformational analysis. Curr Pharma Des. 2008;14(27):2833–9.
10. Avenel-Audran M, Dutartre H, Goossens AN, Jeanmougin M, Comte C, Bernier C, et al. Octocrylene, an emerging photoallergen. Arch Dermatol. 2010;146(7):753–7.
11. Referral: Ketoprofen topical. [Internet]. London: European Medicines Agency, [updated October 2010; Cited 22 Jul 2010]. Available from: http://www.ema.europa.eu.
12. Sixth of 2011 Pharmaceutical affairs· Food Hygiene Council Drug Safety Measures Committee Safety measures investigation meeting Document 7 (Safety measures and risk classification of ketoprofen external preparation).
13. Medicine, Medical equipment etc. Safety information No. 276 (January 2011).
14. Romita P, Foti C, Hansel K, Stingeni L. Photo-contact allergy to octocrylene: a decreasing trend? Contact Dermatitis. 2018;78(3):224–5.
15. Johansen JD, Aalto-Korte K, Agner T, Andersen KE, Bircher A, Bruze M, et al. European Society of Contact Dermatitis guideline for diagnostic patch testing - recommendations on best practice. Contact Dermatitis. 2015;73(4):195–221.
16. Alomar A. Ketoprofen photodermatitis. Contact Dermatitis. 1985;12(2):112–3.
17. Cusano F, Rafenelli A, Bacchilega R, Errico G. Photo-contact dermatitis from ketoprofen. Contact Dermatitis. 1987;17(2):108–9.
18. Sugiura M, Hayakawa R, Kato Y, Sugiura K, Ueda H. 4 cases of photocontact dermatitis due to ketoprofen. Contact Dermatitis. 2000; 43(1): 16–9.
19. Sugiyama M, Nakada T, Hosaka H, Sueki H, Iijima M. Photocontact dermatitis to ketoprofen. Am J Contact Dermatitis. 2001; 12(3): 180–1.
20. Matthieu L, Meuleman L, Van Hecke E, Blondeel A, Dezfoulian B, Constandt L, et al. Contact and photocontact allergy to ketoprofen. The Belgian experience. Contact Dermatitis. 2004;50(4):238–41.
21. Coz CJ, Bottlaender A, Scrivener J-N, Santinelli F, Cribier BJ, Edouard EH, et al. Photocontact dermatitis from ketoprofen and tiaprofenic acid: cross-reactivity study in 12 consecutive patients. Contact Dermatitis. 1998;38(5):245–52.
22. Devleeschouwer V, Roelandts R, Garmyn M, Goossens A. Allergic and photoallergic contact dermatitis from ketoprofen: results

of (photo) patch testing and follow-up of 42 patients. Contact Dermatitis. 2008;58(3):159–66.
23. Karlson I, Vanden Broecke K, Martensson J, Goosens A, Börje A. Clinical and experimental studies of octocrylene's allergic potency. Contact Dermatitis. 2011;64(6):343–52.
24. The European Multicentre Photopatch Test Study (EMCPPTS) Taskforce. A European multicenter photopatch test study. Br. J. Dermatol. 2012; 166(5): 1002–9.
25. Groot AC, Robert DW. Contact and photocontact allergy to octocrylene: a review. Contact Dermatitis. 2014;70(4):193–204.

How to cite this article: Tanahashi T, Sasaki K, Numata M, Matsunaga K. Three cases of photoallergic contact dermatitis induced by the ultraviolet absorber benzophenone that occurred after dermatitis due to ketoprofen-Investigation of cosensitization with other ultraviolet absorbers and patient background. *J Cutan Immunol Allergy*. 2019;00:1–9.
https://doi.org/10.1002/cia2.12080