Annals of Medicine and Surgery 66 (2021) 102452

Contents lists available at ScienceDirect

Annals of Medicine and Surgery

journal homepage: www.elsevier.com/locate/amsu

Case Report

# Pediatric hyperimmunoglobulin E syndrome (Job's syndrome) with STAT3 mutation: A case report

Namita Bhutani [a,*], Urvashi Sharma [a], Ashok Kumar [a], Pradeep Kajal [b]

[a] Deptt. of Pathology, North DMC Medical College and Hindu Rao Hospital, New Delhi, India
[b] Deptt. of Pediatric Surgery, PGIMS Rohtak, Haryana, India

ARTICLE INFO

*Keywords:*
Buckley syndrome
Eosinophilia
Hyper-immunoglobulin E syndrome
Job syndrome
Primary immunodeficiency

ABSTRACT

*Introduction:* Job's syndrome or hyper-immunoglobulin E syndromes (HIES) is a rare, heterogeneous complex of primary immunodeficiency disorders. It is characterized by triad of extremely high serum immunoglobulin E (IgE) levels, recurrent cutaneous infections like chronic eczematous dermatitis, skin abscesses and recurrent sinopulmonary infections. These patients have characteristic facial appearance and many oral manifestations. Eosinophilia, retention of deciduous teeth and skeletal abnormalities are other important clinical features of this syndrome. Familial HIES is of two types depending on the type of gene involved; autosomal-dominant HIES (AD-HIES), which develops due to mutation in human signal transducer and activator of transcription 3 gene (STAT3) and autosomal recessive HIES caused by DOCK8 gene mutation, but most cases are sporadic.

*Case presentation:* Hereby, we present a case of 5 years old female child who presented to our hospital with extensive eczematous lesions over flexural aspect of arms and over the gluteal region extending to the lower limb. The complete clinical presentation and lab investigations have confirmed AD-HIES syndrome. A novel missense mutation in exon 17 (c.1593A > T, p.K531 N) was identified in the STAT3 gene.

*Discussion:* The therapeutic strategy is directed mainly toward the prevention and management of infections and symptoms. Children affected with HIES can develop life-threatening pulmonary infections. Pulmonary complications must be identified in the early stage of the disease to treat them effectively. Hence, early diagnosis and proper management are necessary.

*Conclusion:* To date, information about paediatric HIES is limited. This case presents the clinical features, investigational procedures and management strategy for that particular condition in paediatric population.

## 1. Introduction

Job's syndrome or hyper-immunoglobulin E syndrome (HIES) is a rare primary immunodeficiency disorder, occurring in one in one million individuals [1]. Both males and females have equal predisposition for the disease. It was first described by Davis, Schaller and Wedgwood in 1966 [2]. The nomenclature is derived from the similarity of the condition to the Biblical Prophet Job who was afflicted with sore boils from the sole of his feet up to his crown [2]. The first case from India was reported in 1994 by Pherwani et al. [3]. In 2001, Pherwani and Madnani reported six patients with prominent cutaneous and respiratory features, but only one had familial involvement [3]. In 1972, Buckley et al. found extremely high serum IgE levels in these patients. It is characterized by markedly elevated serum levels of immunoglobulin E syndrome (IgE), peripheral eosinophilia, recurrent fungal and/or bacterial infections of soft tissues, eczematous dermatitis, sino-pulmonary infections and the tendency for vascular abnormalities. In addition to these immunologic features, a characteristic facial appearance, scoliosis, retained primary teeth, joint hyperextensibility, bone fractures following minimal trauma, and craniosynostosis are the main non-immunologic manifestations [4].

There are two forms of HIES: autosomal dominant which develops due to mutations in signal transducer and activator of transcription 3 (STAT3) and a recessive (AR-HIES) form, which is caused by UU dedicator of cytokinesis (DOCK8) mutations and a tyrosine kinase 2 gene mutation, with DOCK8 being much more prevalent [5]. AR-HIES differs in regards to predilection towards cutaneous viral infections and severe atopic eczema. However, most cases of HIES are sporadic. These two

* Corresponding author.
*E-mail addresses:* namitabhutani89@gmail.com (N. Bhutani), urvsharma1@gmail.com (U. Sharma), ashokumar@gmail.com (A. Kumar), drpradeepkajal@gmail.com (P. Kajal).

https://doi.org/10.1016/j.amsu.2021.102452
Received 26 April 2021; Received in revised form 20 May 2021; Accepted 23 May 2021
Available online 1 June 2021
2049-0801/© 2021 The Author(s). Published by Elsevier Ltd on behalf of IJS Publishing Group Ltd. This is an open access article under the CC BY-NC-ND license (http://creativecommons.org/licenses/by-nc-nd/4.0/).

different syndromes have distinct presentations, courses, outcomes and share very little in terms of pathogenesis other than the IgE elevation. While the underlying cause of HIES remains unknown, the gene has been mapped to the proximal arm of chromosome 4q [5]. Patients have defective T-cell cytokine response resulting in excessive IgE synthesis. Although the National Institute of Health (NIH) developed a clinical HIES scoring system in 1999 [5], but making this diagnosis in young children can be challenging as symptoms accumulate over time along with confounding clinical signs. HIES occurs in individuals from diverse ethnic backgrounds and does not seem to be more common in specific populations [4]. Hereby we present a case of 5 years old female child who presented with classical symptoms of Job's syndrome. Then, we sequenced the STAT3 gene by complementary DNA (cDNA) and genomic DNA, and we found the mutation locus. Review of literature revealed that very few cases of Job's syndrome in paediatrics have been published till now. Diagnosis in young children can be challenging as symptoms accumulate over a period of time along with confounding clinical dilemmas. Due to its rarity, this case report shed light on clinical features, investigational procedures and management strategy opted in this particular case. The SCARE criteria were utilized for this case report [6]. The parents of the patient gave the consent for the study to be published.

## 2. Case report

A 5-years-old female child born out of non-consanguineous parentage and uneventful pregnancy was brought to paediatric outpatient department with eczematous lesions over flexural aspect of arms and lower limbs for 7 days. Physical examination revealed erythematous lesions over the flexure aspects of arms and gluteal region extending to the lower limbs (Fig. 1). There was no history of fever and cervical lymphadenopathy. She had similar such episodes in past for which she was hospitalised along with episodes of upper and lower respiratory tract infections. Her medical history was significant for eczema since newborn period and recurrent pustular and eczematoid rashes on the face and scalp in the childhood. Family history was not significantly related to condition. On physical examination, her vitals were normal. Systemic examinations were unremarkable. Her routine haematological investigations revealed a haemoglobin level of 12.2 g/dL with MCV of 78.2 fl, total leucocyte count of 58,000 cells/mm3 with eosinophila (80%) (Fig. 2), and Absolute eosinophil count (AEC) was 45,240 SI units. The ESR, reticulocyte count and LDH were within normal limits. Serum IgE was detected with rate nephelometry using an Immage 800 (Beckman Coulter, Inc., Brea, CA) and were markedly elevated (39000 IU/mL) (reference range, 0–100 IU/mL). Microcytic, hpypochromic erythrocytes were observed on Peripheral smear along with elliptocytes, spherocytes, and target cells. Bone marrow examination ruled out any leukaemia process instead revealed significantly increased mature eosinophils within the marrow.

Radiological workup showed few subcentral nodes in the mesenteric and cervical region. HRCT revealed fine parenchymal infiltrative lesions scattered in both lung fields. Clinical symptoms and the appearance of the lung on imaging studies were improved after antimicrobial and antifungal treatment. The rash had been treated with topical betamethasone dipropionate. Oral vitamin C 500 mg was started daily with reduced recurrence of infections but the eczema did not regress. Based on the above clinical features and supportive immunological findings, a diagnosis of Hyper-IgE syndrome (HIES) was made. Non immunological features of HIES, such as scoliosis, skeletal fractures, and vascular abnormalities were not identified. Mutational Analysis was done as per standard methods. The mRNA expression of STAT3 gene in the leucocyte from whole blood samples of the patient and his family control was examined by RT-PCR, using a pair of specific primers amplifying a 111-bp amplicon of this gene. The housekeeping gene β-actin was used as an internal control for normalization. Reduced level of expression of STAT3 gene was observed in the patient. The diagnosis of HIES was confirmed by genetic studies showing a STAT3 mutation. During the follow-up period, the patient developed a cervical lymphatic abscess followed by a liver abscess. Both were positive for *S. aureus* and required surgical intervention. Patient had HIES and a STAT3 defect with no family history of the disease, the parents of both patients were recruited for mutation analysis to evaluate the inheritance. Expectedly, the parents did

**Fig. 1.** Dermatological examination reveals extensive erythematous lesions over the groin extending over the lower limb.

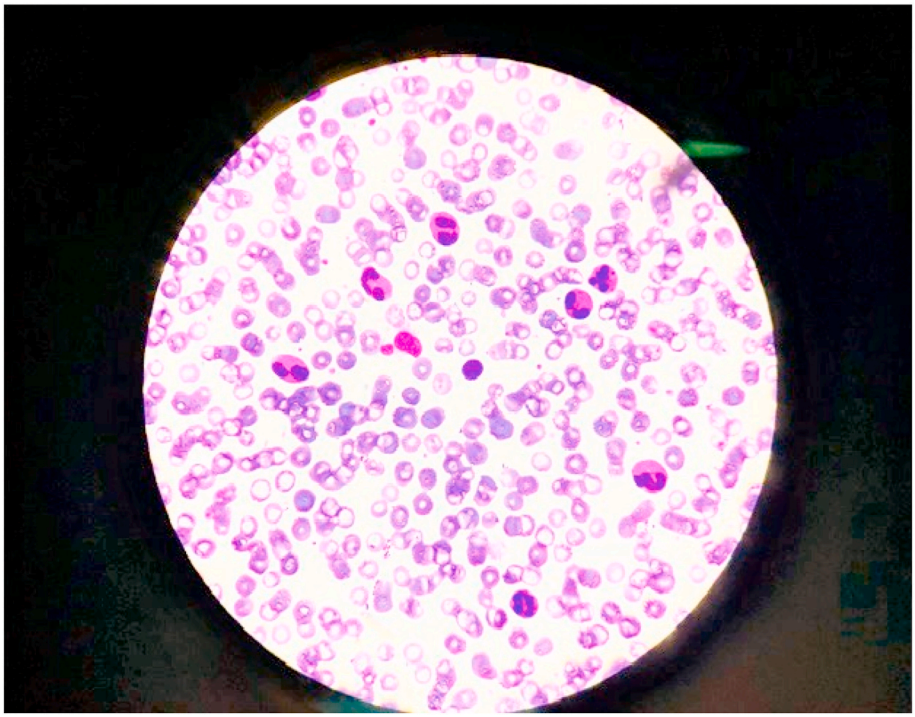

**Fig. 2.** Peripheral blood smear showing numerous multiple bilobed (spectacle shaped) eosinophils (H & E− 100X).

not carry the mutation found in the child. Parents of patients have given the permission for publication of this case report.

## 3. Discussion

HIES is a rare genetically mediated primary immunodeficiency disorder with multisystem involvement. It was first described in 1966 by Davis, Wedgwood, and Schaller and was given the name "Job's syndrome," attributing the clinical symptoms prophet job had suffered. In 1972, Buckley et al. elaborated the clinical description, and hence, it is also called "Buckley's syndrome" [8]. The exact pathogenesis is still unknown. Although most cases are sporadic, two distinct forms are being identified. Relatively common, autosomal dominant (AD-HIES) variety is caused by mutations in signal transducer and activator of transcription 3 (STAT 3) which is critical in the signaling pathways for interleukin (IL)-6 and IL-10 which mediate acute phase reactions and anti-inflammatory actions, respectively [5]. In the recessive form of HIES, homozygous mutations in DOCK8 gene were identified. In addition to these mutations, recently, homozygous mutations in phosphoglucomutase 3 (PGM3) have been described in some cases [8]. The c.1144C > T mutation in STAT3 is a known pathogenic mutation [5]. These two types have different pathogenesis and outcomes, and the only common ground is the IgE elevation, with values reaching >2000 IU (normal < 200 IU) [1].

This syndrome is characterized by both immunologic and non-immunologic manifestations. The most frequently found immunological abnormalities are eczematoid rashes, skin abscesses, recurrent respiratory infections, markedly elevated serum IgE, mucocutaneous candidiasis, and eosinophilia. The non-immunologic manifestations include craniofacial, musculoskeletal, dental, and vascular abnormalities. Facial asymmetry, prominent forehead, broad nose, deep eyes, rough facial skin, and retention of primary teeth are few of the developmental abnormalities observed in patients. There is no specific unique immunological or molecular marker of HIES. It is distinguished from many other primary immunodeficiencies by its many nonimmunologic features [4]. Thus, in pediatric HIES, nonimmunological manifestations, including craniofacial and vascular system abnormalities and malignant tumors, are rare and may appear gradually over time. Pulmonary fungal infections may be a significant cause of morbidity in paediatric patients with HIES [7]. Cutaneous manifestation could be an early diagnostic feature of HIES, especially in a patient with elevated serum IgE and recurrent respiratory infections. The HIES brings about an increased risk of severe recurrent respiratory infections, pneumonias and autoimmune diseases like systemic lupus erythemathosus dermatomyositis and membranoproliferative glomerulonephritis [4,5].

Serum IgE concentrations are extremely high in patients with HIES (>2000 IU/ml) and the molecular mechanism for this hyper-IgE is unclear. HIES patients have normal or decreased serum IgM, IgG and IgA levels. Eosinophilia is the other consistent laboratory finding. Total white blood cell counts are normal but they fail to elevate appropriately during acute infection. An impaired chemotaxis of neutrophils or monocytes has been described, a defect that explains the "cold abscesses" seen in these patients. There is no specific clinical and laboratory test for confirming. Several symptoms such as elevated IgE levels and eosinophilia might also be found in other immunodeficiency syndromes [2]. Therefore, one must synthetically analyze the medical history, appearance, skin characteristics, visceral abnormalities, and necessary laboratory study findings including cytokines and immunoglobulins levels. A scoring system, comprising of both clinical and laboratory diagnostic criteria has been proposed by Grimbacher and colleagues and accepted by the National Institute of Health (NIH). The assessment of the suspected patient according to this scoring system and the gaining ≥15 points makes the recognition of hyper-IgE phenotype highly probable [9].

There is no definite treatment for HIES. The therapeutic strategy is directed mainly toward the prevention and management of infections. Every episode of infection should be treated with full course of antibiotics such as penicillins and cephalosporin which should be modified according to culture and sensitivity report. Many advocate long-term prophylactic antibiotic therapy against *S. aureus*. Systemic antibiotics and antifungal drugs are of great importance, as they can prevent serious, overwhelming infections and prevent lung parenchymal damage; trimethoprim-sulfamethoxazole or amoxicillin-clavulinic acids are used frequently [4]. Other treatment options include intravenous

immunoglobulins, methotrexate, levamisole, cimetidine, ascorbic acid, and transfer factor [5]. Intravenous immunoglobulin may decrease the number of infections for some individuals and is the most frequent immunomodulator used. Ascorbic acid has been reported to improve the chemotactic responsiveness of neutrophils and helps in reducing the recurrences of infection [10]. Other options include IFN-gamma, which has inconsistent effects on IgE levels [11].

## 4. Conclusion

Although rare, primary immunodeficiency disorders like HIES usually present in early childhood. It is rather a complex group of disorders posing a diagnostic challenge. Dermatological manifestations may mimic atopic dermatitis and can be misleading. However, children with HIES are in danger as pulmonary infections can be fatal at any point of their life. Hence, early diagnosis and proper management are necessary. Thorough clinical as well as laboratory evaluation should be conducted in any child presenting with recurrent skin and lung infections. The new and evolving genetic and immunologic understandings probably eventually lead to more effective disease specific treatment for patients, including stem cell transplantations and gene-targeted therapies.

Provenance and peer review not commissioned, externally peer-reviewed

## Ethical approval

N/A.

## Source of funding

N/A.

## Authors contribution

1. Dr. Namita Bhutani: written the manuscript
2. Dr. Urvashi Sharma: data collection
3. Dr. Ashok Kumar: assisted in framing manuscript
4. Dr. Pradeep Kajal: assisted in framing manuscript

## Research Registration

N/A.

## Guarantor

Dr. Namita Bhutani.

## Patient consent statement

Parents of patient have given consent to publish the case report.

## Declaration of Competing interest

We don't have any conflict of interest.

## References

[1] J. Ghaffari, H. Ahanchian, F. Zandieh, Update on hyper IgE syndrome (HIES), J Pediatr Rev 2 (2014) 39–46.
[2] H. Donabedian, J.I. Gallin, The hyperimmunoglobulin E recurrent-infection (Job's) syndrome. A review of the NIH experience and the literature, Medicine (Baltim.) 62 (1983) 195–208.
[3] A.V. Pherwani, C. Rodrigues, A. Dasgupta, M. Bavadekar, N.D. Rao, Hyper immunoglobulin E syndrome, Indian Pediatr. 31 (1994) 328–330.
[4] A. Szczawinska-Poplonyk, Z. Kycler, B. Pietrucha, The hyperimmunoglobulin E syndrome: clinical manifestation diversity in primary immune deficiency, Orphanet J. Rare Dis. 6 (2011) 76.
[5] B. Grimbacher, S.M. Holland, J.M. Puck, Hyper-IgE syndromes, Immunol. Rev. 203 (2005) 244–250.
[6] R.A. Agha, T. Franchi, C. Sohrabi, G. Mathew, for the SCARE Group, The SCARE 2020 Guideline: Updating Consensus surgical CAse REport (SCARE) Guidelines, Int. J. Surg. 84 (2020) 226–230.
[7] R.H. Buckley, B.B. Wray, E.Z. Belmaker, Extreme hyperimmunoglobulinemia E and undue susceptibility to infection, Pediatrics 49 (1972) 59–70.
[8] L. Yang, M. Fliegauf, B. Grimbacher, Hyper-IgE syndromes: reviewing PGM3 deficiency, Curr. Opin. Pediatr. 26 (2014) 697–703.
[9] L.F. Schimke, J. Sawalle-Belohradsky, J. Roesler, A. Wollenberg, A. Rack, M. Borte, et al., Diagnostic approach to the hyper-IgE syndromes: immunologic and clinical key findings to differentiate hyper-IgE syndromes from atopic dermatitis, J. Allergy Clin. Immunol. 126 (2010) 611–617.
[10] A.F. Freeman, S.M. Holland, Clinical manifestations, etiology, and pathogenesis of the hyper-IgE syndromes, Pediatr. Res. 65 (5Pt 2) (2009), 32R-7R.
[11] F. Bilora, F. Petrobelli, V. Boccioletti, F. Pomerri, Moderate-dose intravenous immunoglobulin treatment of Job's syndrome: case report, Minerva Med. 91 (2000) 113–116.