G Chir Vol. 26 - n.11/12- pp. 425-429
Novembre-Dicembre 2005

Eosinophilic cystitis associated with urethral stricture disease from pelvic trauma. Case report and literature review

G. MARTINO, A. TORCASIO, C. IAVARONE, A. CARDARELLI, M. MONTI

SUMMARY: **Eosinophilic cystitis associated with urethral stricture disease from pelvic trauma. Case report and literature review.**

G. MARTINO, A. TORCASIO, C. IAVARONE, A. CARDARELLI, M. MONTI

We report a case of eosinophilic cystitis (EC) in a 65-year-old man with urethral stricture disease from blunt pelvic traumatic event. EC is a rare condition characterized by eosinophilic infiltration of the bladder wall, that usually presents with irritative voiding symptoms, suprapubic pain and hematuria. Etiology is still not clear although a review of the literature suggests that pathogenetic mechanisms probably engage an altered immune response in the bladder, with the inflammatory reaction caused by factors such as exogenous allergens and previous bladder injury or surgery to the bladder or the prostate. The diagnosis of EC has to be confirmed by biopsy, since in some cases it may manifest as other inflammatory and malignant bladder disorders.

A conservative medical management is indicated initially, since this disease may be self-limited, with a benign course especially in children and young patients. In adults EC is more often a chronic recurrent condition that requires close follow-up since it may lead to serious progressive bladder and/or upper urinary tract disease.

More invasive therapies (including transurethral resection, partial or total cystectomy) may also be required when conservative therapy fails.

RIASSUNTO: **La cistite eosinofila associata a stenosi dell'uretra da trauma pelvico. Osservazione personale e revisione della letteratura.**

G. MARTINO, A. TORCASIO, C. IAVARONE, A. CARDARELLI, M. MONTI

Sulla base dell'osservazione di un caso di cistite eosinofila (CE) in un uomo di 65 anni, portatore di stenosi dell'uretra posteriore da trauma da schiacciamento pelvico, vengono esaminati gli aspetti eziologici, istopatologici, clinico-diagnostici e terapeutici di questa rara affezione vescicale, imputabile verosimilmente ad una abnorme risposta del sistema immunitario a svariati stimoli antigenici locali e/o sistemici. I segni e i sintomi clinici della malattia sono del tutto aspecifici, così come i reperti desumibili dagli esami strumentali, in grado di simulare fra l'altro la presenza di una neoplasia. La diagnosi di certezza viene posta esclusivamente sulla base dell'esame istologico dopo biopsia per via cistoscopica, considerando patognomonica la presenza di un infiltrato polimorfocellulare ricco di eosinofili a carico di tutti gli strati della parete vescicale.

Il trattamento di scelta è inizialmente quello medico, dal momento che la CE, almeno nell'età pediatrica e negli individui giovani, mostra generalmente un decorso benigno con elevate percentuali di guarigione definitiva. Viceversa, nei pazienti adulti o anziani assume più spesso un andamento cronico, con periodi di remissione ed esacerbazione della sintomatologia e con complicazioni anche gravi sia vescicali che del tratto urinario superiore.

In tali evenienze, e nei soggetti che non rispondono in maniera adeguata alla terapia medica, non rimangono che opzioni terapeutiche invasive, che possano contemplare ampie resezioni vescicali per via endoscopica, cistectomia parziale o, finanche, cistectomia totale con derivazione urinaria o neovescica.

KEY WORDS: Eosinophilic cystitis - Male-urethral stricture.
Cistite eosinofila - Stenosi uretra maschile.

Introduction

Eosinophilic cystitis (EC), first described by Brown and Palubinskas in 1960 (7, 27) but identified since 1949 by Kindall and Nickels (21), is a rare and unusual form of bladder inflammation, characterized by the presence of eosinophilic leukocytes throughout all layers of the bladder as well as muscle necrosis.

Clinical presentation of this disease is non-specific, the most predominant symptoms usually being irritative voiding symptoms and hematuria. The ultrasound and cystoscopic findings often may be

University "La Sapienza" of Rome, Italy
Department of Surgical Sciences
Section of General and Reconstructive Surgery
(Chief: Prof. M.Monti)

© Copyright 2006, CIC Edizioni Internazionali, Roma

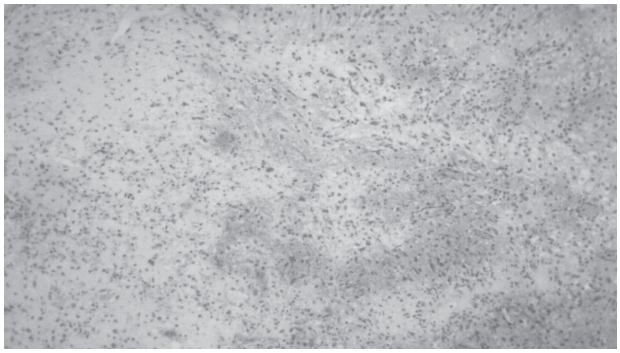

Fig. 1 - Bladder biopsy specimen showing mucosal oedema and focal acute necrosis of superficial muscularis associated with a prominent infiltration of eosinophils in lamina propria (H&E, x20).

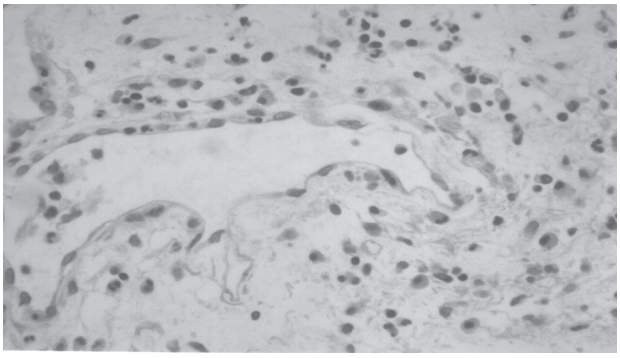

Fig. 2 - Bladder biopsy specimen showing pathognomonic eosinophilic infiltrate (H&E, x 40).

misdiagnosed for malignant bladder tumors or some other pseudoneoplastic conditions (7, 8, 15, 16, 19, 20, 22, 23, 33, 35, 39).

An abnormal immune response to some stimulus has been believed to be a significant factor in the genesis of EC, but several associations are known, including infection, parasitic infestations, previous bladder injury or surgery, bladder cancer (15, 29, 33, 38, 39, 41).

To date etiology remains unclear and therapeutic options are generally symptomatic and not standardized. We report on a case of EC in an older male patient with urethral stricture disease from blunt pelvic trauma. The aim of this study is to evaluate the main features of pathogenesis, diagnosis and management of this uncommon bladder disorder.

Case report

I.R., a 65-year-old white man, was admitted to our Department in January 2004 with urethral stricture disease from poorly managed pelvic blunt trauma by motor vehicle accident occurred 4 years before. Unrecognized urethral injury was located in the posterior tract of urethra and was not associated with pelvic fracture distraction defects.

The initial signs and symptoms were underestimated also by the patient and urethral trauma manifested 2 years later as a severe stricture. The patient was hospitalized at another institution and diagnosis of a narrowed short area (1 cm in length) in the membranous urethra was made by retrograde urethrography. Sequential urethral dilatations were preferred to more invasive surgical treatments, initially twice a week, then weekly for 4 weeks, twice monthly for 6 months and every month thereafter. More than once it was necessary a urethral catheter indwelling for five or seven days, to act as a splint to support the urethra after being dilated.

During this course the patient experienced a worsening of the symptoms, with recurrent episodes of urinary urgency, frequency, dysuria, enuresis, microhematuria and suprapubic pain. In addition he developed chronic cystitis refractory to the usual therapy and iatrogenic injury to the anterior urethra from traumatic catheter placement or dilation.

The patient was referred to us with a 3-day history of gross painless terminal hematuria, that was immediately treated with temporary bladder irrigation. His medical history was unremarkable. He had no known drug allergies and was taking no medications. At admission physical examination was normal except for some mild suprapubic tenderness. Urinalysis confirmed the hematuria with greater than 40 red and only 2 white blood cells per high power field. Urinary cultures yielded no growth and were negative for ova, cysts, trophozoites and parasites; urine cytology showed no atypia and no eosinophiluria. Stools showed no cysts or worm eggs. The eosinophils in the peripheral blood were not elevated; the other laboratory investigations were normal, except for an erythrocyte sedimentation ratio over 50 mm/h.

The patient underwent a renal and pelvic ultrasonographic examination which demonstrated no related upper tracts abnormality but a focal thickening of the right bladder wall, with reduction of bladder capacity. A mild restenosis of membranous urethra was confirmed by retrograde and anterograde urethrography.

An urethrotomy with the Sachse urethrotome and a transurethral cystoscopy were performed. Cistoscopic examination revealed edematous bladder mucosa, ulcers and several velvety erythematous plaques (diameter <1 cm), localized to the right bladder wall and extending towards bladder neck. Biopsy of those lesions showed severe chronic inflammation of the mucosa and superficial muscularis, with focal acute muscle necrosis (Fig. 1) and massive eosinophilic infiltration (Fig. 2). No evidence of malignancy could be observed. The histological findings led to the diagnosis of EC in the acute phase.

The patient was started on a high-dose steroid regimen (40 mg prednisone per day) with a reduction and tailing of the dose over 6 weeks. After 2 weeks the patient was totally symptom-free. A follow-up cystoscopy, 7 weeks after steroid was begun and 6 months later showed objective remission of bladder findings. He has remained well during the last 14 months.

Discussion and conclusion

The first reported case of EC in an adult patient was by Brown almost 45 years ago (7) and the first case of this disease observed in children was by Farber in 1963 (12). Since then, about 150 cases have been reviewed in the literature. This rare condition can be observed in any age group, without racial predilection, although it seems to be more common in adults (60-70%). In children, males are more frequently affected than females. In young and middle-aged patients, two thirds of the reported cases are women (2, 9, 10, 29).

The etiology of EC is yet poorly understood, although the allergy hypothesis, first reported by Goldstein in 1971 (14), has been supported by most authors. Patients with a history of allergies are at increased risk of developing this form of cystitis. Many agents and/or conditions have been claimed as possible allergens in the urinary tract, including different kinds of food (fruits, vegetables, spices, chocolate and coffee), inhalant allergens, contact allergens (condoms, vaginal tampons, spermatocidal jellies, glutaraldehyde solution), different medications (methicilline, N-3',4'-dimethoxycinnamoyl-anthranilic acid, warfarin, cyclophosfamide, penicillin), topical admistration of drugs (thiotepa, mytomycin C, dimethylsulfoxide), surgical sutures (chromic catgut) (1, 9, 10, 35, 36, 38, 39, 41). Additional risk factors have been reported: bacterial and viral infections, parasitic infestations (toxocariasis, schistosomiasis, sparganosis, hydatidosis), bronchial asthma and atopic diseases (18, 22, 29, 35, 40). Conditions that have been associated with EC include eosinophilic gastroenteritis (28), Glanzmann's thrombasthenia (6), X-linked chronic granulomatous disease (4, 31), glandularis and interstitial cystitis (3), renal transplantation and also pregnancy or delivery by caesarian section (9, 10 , 38).

Several studies reviewed in the literature have emphasized that two factors seem to favour the development of the disease: dysfunction of the immune system and associated bladder conditions. Therefore two etiological groups of affected patients can be distinguished. In the former (mainly women and children), allergies and eosinophilia of the peripheral blood may be observed; in the latter (mainly old man), allergic conditions were rare and peripheral eosinophils were in the normal range, but some kind of bladder injury had occurred (5, 17, 25, 29, 30, 32, 38). In these patients, with a more local form of disease, bladder outflow obstruction due to benign prostatic hypertrophy, bladder carcinoma or congenital anomalies have been reported. In several, symptoms followed trauma to the bladder or prostate, especially for the form of transurethral surgical procedures. This bladder-injury type of EC probably occurs more commonly than generally appreciated.

In our experience it would seem that chronic vesical irritation due to repeated urethral catheterisations, or bladder injury related with too much vigorous dilatations of posterior urethra, also can cause an eosinophilic response in the bladder wall. A local antigenic stimulus (bacteria? foreign protein?) is believed to cause an immunoglobulin E-mediated mast cells degranulation, release of eosinophil chemotactic factor and ultimately the release of damaging lysosomal enzymes capable of causing bladder tissue destruction and inflammation. Activated eosinophils synthesize interlukin-4 and -5, thus enhancing the activation of eosinophils and their cytotoxic potential (10, 11, 25, 37).

The two subtypes of EC are characterized by similar clinical features, cystoscopic findings and somewhat similar microscopic patterns. Common symptoms include dysuria (65%), urinary frequency and/or urgency (70%), suprapubic pain (50%) and, when lesions are located near the bladder neck, acute painful retention (10%) (9, 10, 37, 38). Physical examination is usually unremarkable but may reveal suprapubic or flank tenderness and rarely an anterior rectal mass (7% of the patients, mostly children) (5, 22, 35). Proteinuria and microscopic or gross hematuria are common, although it seems there are no pathognomonic laboratory findings. Eosinophiluria, which is present in 10-30% of all cases of urinary tract allergy, is rarely observed because eosinophils are rapidly degraded or there is little mucosal shedding. Blood eosinophilia may be as high as 50% but it has been noted in only 40% of the patients with EC and, although characteristic, it is not considered diagnostic (5, 18, 26, 29).

Imaging (ultrasonography, excretory urogram, voiding cystourethrography and CT scan) may reveal diffuse thickening of bladder wall, filling defects or a mass-like effect in the bladder, decreased capacity, unilateral or bilateral hydronephrosis (27%) if the ureterovesical junctions are involved (8, 10, 15, 18, 20, 29, 33, 34, 38). Reported cystoscopic findings range from focal or diffuse mucosal erythema with superficial ulcerations to raised mucosal lesions, variously described as edematous polyps, red velvety areas, nodular or plaque-like lesions and invasive-appearing masses (17, 18, 22, 35).

Bladder neoplasm, mainly rhabdomyosarcoma (expecially in children) or sarcoma botryoides, may be suspected on the basis of imaging and cystoscopic findings. In addition, although neoplastic transformation of EC has never been reported in the literature, tumor associated bladder tissue eosinophilia is known to occur in 2-3% of patients with superficial bladder transitional cell carcinoma (10, 13, 18, 20). Therefore the definitive diagnosis of EC is only made by multiple deep biopsy specimens obtained during the acute attack. Infiltration of the lamina propria and muscularis by the eosinophils is pathognomonic, but findings such as mucosal edema and hyperemia, mucosal polyps, muscle necrosis, chronic inflammation, and fibrosis of mucosa and muscularis have been emphasized in various combinations in all the cases previously reported in the literature (8, 9, 17, 18, 33, 38).

EC may be acute or chronic with periods of remission and exacerbation. Treatment is symptomatic after a allergic full evaluation and removal of potential allergens if identified. The current recommendation is conservative medical management with oral antihistamines, nonsteroidal anti-inflammatory drugs and oral steroids

singly or in some combination. Antibacterial agents should be employed in patients in whom concomitant urinary infection is demonstrated and in those with potential urinary tract obstruction. Other modalities of treatment (intravesical silver nitrate or dimethylsulphoxide irrigations, cytotoxic agents, azathioprine, radiation, cyclosporin A) have been mentioned just occasionally in the literature (29, 35, 38).

It is believed by some Authors that in most of the children EC is a short-lived and self-limited disease, which requires no specific therapy and resolve rapidly (2-12 weeks) and completely, although resolution of the symptoms appears to occur faster in those patients treated with medications as opposed to those who receive no treatment at all (5, 15, 22, 39). In middle aged and elderly patients this disease is more often a chronic condition that requires close long-term follow-up (mean length 12-19 months), since relapses and progression may occur even while treatment (15, 18, 22, 35). Complete bladder fibrosis with secondary involvement of the upper urinary tract, resulting in obstructive nephropathy with variable degrees of renal insufficiency, is a potential complication (29, 33, 41).

If EC presents an aggressive, unyielding tumefactive course and when patients fail to respond to the medical treatment, surgery could be required. Surgical procedures for EC include transurethral resection of the oedematous areas or papillary lesions and partial cystectomy, although total cystectomy with urinary diversion or neobladder has been also reported if the bladder capacity was severely reduced and for severe hematuria that could not be controlled by more conservative therapy (5, 8, 10, 15, 18, 24, 33, 38).

References

1. Abramow Y, Goldberg RP, Mcguire M, Golden B, Gandhi S, Sand P: Eosinophilic cystitis after bladder instillation with dimethyl sulfoxide. Urology 2004; 63, 1182.
2. Al-Omar O, Fisher MB, Sarle R, Mclorie GA. Eosinophilic cystitis in a neonate. J Urol 2004; 173, 576.
3. Baldi A, Di Marino MP, Persichetti P, Ferrara N, Baldi F. Cystitis glandularis complicating an eosinophilic cystitis: a case report. In Vivo 2003; 17: 651.
4. Barese CN, Podesta M, Litvak E, Villa M, Rivas EM. Recurrent eosinophilic cystitis in a child with chronic granulomatous disease. J Pediatr Hematol Oncol 2004; 26, 209.
5. Barry KA, Jafri SZ. Eosinophilic cystitis: CT findings. Abdom Imaging 1994; 19: 272
6. Botma JP, Burger EG, De Kock ML. Eosinophilic cystitis associated with Glanzmann's thrombasthenia. A case report. S Afr Med J 1987; 71: 533.
7. Brown EW. Eosinophilic granuloma of the bladder. J Urol 1960; 83: 665.
8. Cai B, Xie H, Xu MS, Geng HQ, Zhang ZD, Li ZC, Liu GH, Chen F. Eosinophilic cystitis in children: report of six cases and review of literature. Zhonghua Yi Xue Za Zhi 2003; 25: 83.
9. Choe JM, Kirkemo AK, Sirls LT. Intravesical Thiotepa-induced eosinophilic cystitis. Urology 1995; 46: 729.
10. Devasia A, Kekre NS, Date A, Pandey AP, Gopalakri Shnan G. Eosinophilic cystitis. Scand J Urol Nephrol 1999; 33: 396.
11. Dubuchquoi S, Jamin A, Desreumax P, Rigot JM, Copin MC, Francois M. Evidence of eosinophilic activation in eosinophilic cystitis. Eur Urol, 1994; 25: 254.
12. Farber S, Vawter GF. Clinical pathologic conference. J Pediatr, 1963; 62: 941.
13. Flamm J. Tumor-associated tissue inflammatory reaction and eosinophilia in primary superficial bladder cancer. Urology 1992; 40: 180.
14. Goldstein M. Eosinophilic cystitis. J Urol 1971; 106:854.
15. Grounlund A, Glenthoy A, Kvist E. Eosinophilic cystitis. Diagnosis and treatmnent in Denamark Scand J Urol Nephrol 1998; 33: 321.
16. Hansen MV, Kristensen PB. Eosinophilic cystitis simulating invasive bladder carcinoma. Scand J Urol Nephrol 1993; 27: 275.
17. Hellstrom HR, Davis BK, Shonnard JW. Eosinophilic cystitis: a study of 16 cases. Am J Clin Pathol 1979; 72:777.
18. Itano NMB, Malek RS. Eosinophilic cystitis in adults. J Urol 2001; 165: 805.
19. Joung RH. Pseudoneoplastic lesions of the urinary bladder. Pathol Ann, 1988; 1: 67.
20. Kilic S, Erguvan R, Ipek D, Gokce H, Aydin NE, Baydinc C. Eosinophilic cystitis: A rare inflammatory pathology mimicking bladder neoplasms. Urol Int 2003; 71: 285.
21. Kindall L, Nickels TT. Allergy of the pelvic urinary tract in the female: a preliminary report. J Urol 1949; 61: 222.
22. Ladocsi LT, Sullivan B, Hanna MK. Eosinophilic granulomatous cystitis in children. Urology 1995; 46: 732.
23. Leiobovitch I, Heyman Z, Chaim JB, Goldwasser B. Ultrasonographic detection and control of eosinophilic cystitis. Abdom Imaging 1994; 19: 270.
24. Lin HY, Chou YH, Wu WJ, Huang CH, Chai CY. Eosinophilic cystitis: eight cases report and literature review. Kaohsiung J Med Sci 2002; 18: 30.
25. Littleton RH, Farah RN, Cerny JC. Eosinophilic cystitis: an uncommon form of cystitis. J Urol 1982; 127: 132.
26. Matsuura H, Sakurai M, Arima K. Recurrent eosinophilic cystitis with peripheral eosinophilia and hyperimmunoglobulinemia. E Urol Int 2003; 70: 327.
27. Palubinskas AJ. Eosinophilic cystitis. Case report of eosinophilic infiltration of the urinary bladder. Radiology 1960; 75: 589.
28. Peterson NE, Silverman A, Campbell JB. Eosinophilic cystitis and coexistent eosinophilic gastroenteritis in an infant. Ped Rad 1989; 19: 484.

29. Pomeranz A, Eliakim A, Uziel Y, Gottesman G, Rathaus V, Zehavit T, Wolach B. Eosinophilic cystitis in a 4-year-old boy: successful long-term treatment with Cyclosporin A. Pediatrics, 2001; 108: 113.
30. Popert RJM, Ramsay JWA, Owen RA, Fisher C, Hendry WF. Eosinophilic cystitis mimicking invasive bladder tumour: discussion paper. J R Soc Med 1990; 83: 776.
31. Redman JF, Parham DM. Extensive inflammatory eosinophilic bladder tumors in child. Experience with three cases. South Med J 2002; 95: 1050.
32. Rubin L, Pincus MB. Eosinophilic cystitis: the relationship of allergy in the urinary tract to eosinophilic cystitis and the pathophysiology of eosinophilia. J Urol 1974; 112: 457.
33. Slama A, Khouni H, Sriha B, Brini K, Ben Sorba N, Taher Mosbah A. Bladder fibrosis due to eosinophilic cystitis. Ann Urol (Paris.), 2003; 37: 272.
34. Sujka SK, Fisher JE, Greenfield SP. Eosinophilic cystitis in children. Urology, 1992; 40: 262.
35. Thijssen A, Gerridzen RG. Eosinophilic cystitis presenting as invasive bladder cancer: comments on pathogenesis and management. J Urol 1990; 144: 977.
36. Tsakiri A, Balslev I, Klarskov P. Eosinophilic cystitis induced by penicillin. Int Urol Nephrol 2004; 36: 159.
37. Van Den Ouden D. Diagnosis and management of eosinophilic cystitis. A pooled analysis of 135 cases. Eur Urol 2000; 37: 386.
38. Van Den Ouden D, Van Kaam N, Eland D. Eosinophilic cystitis presenting as urinary retention. Urol Int 2001; 66: 22.
39. Verhagne PCMS, Nikkels PGJ, De Jong TPVM. Eosinophilic cystitis. Arch Dis Child 2001; 84:344.
40. Vetter V, Beck JD, Storr U, Bowing B, Rosch W. Case of the month. A 2-year-old girl with urinary stasis and a bladder mass. Eur J Pediatr 1995;154: 935.
41. Watson HS, Singh EO, Hermans MR, Coffield KS, Keegan GT. Recurrent eosinophilic cystitis: a case responsive to steroids. J Urol 1991; 147: 689.