Atopic dermatitis

Stephan Weidinger, Natalija Novak

Atopic dermatitis (also known as atopic eczema) is a chronic inflammatory skin disease that is characterised by intense itching and recurrent eczematous lesions. Although it most often starts in infancy and affects two of ten children, it is also highly prevalent in adults. It is the leading non-fatal health burden attributable to skin diseases, inflicts a substantial psychosocial burden on patients and their relatives, and increases the risk of food allergy, asthma, allergic rhinitis, other immune-mediated inflammatory diseases, and mental health disorders. Originally regarded as a childhood disorder mediated by an imbalance towards a T-helper-2 response and exaggerated IgE responses to allergens, it is now recognised as a lifelong disposition with variable clinical manifestations and expressivity, in which defects of the epidermal barrier are central. Present prevention and treatment focus on restoration of epidermal barrier function, which is best achieved through the use of emollients. Topical corticosteroids are still the first-line therapy for acute flares, but they are also used proactively along with topical calcineurin inhibitors to maintain remission. Non-specific immunosuppressive drugs are used in severe refractory cases, but targeted disease-modifying drugs are being developed. We need to improve understanding of the heterogeneity of the disease and its subtypes, the role of atopy and autoimmunity, the mechanisms behind disease-associated itch, and the comparative effectiveness and safety of therapies.

Published Online
September 14, 2015
http://dx.doi.org/10.1016/S0140-6736(15)00149-X

Department of Dermatology and Allergy, University Hospital Schleswig-Holstein, Campus Kiel, Kiel, Germany (Prof S Weidinger MD); **Department of Dermatology and Allergy, University Hospital Bonn, Bonn, Germany** (Prof N Novak MD)

Correspondence to: Prof Stephan Weidinger, Department of Dermatology and Allergy, University Hospital Schleswig-Holstein, Campus Kiel, 24105 Kiel, Germany **sweidinger@dermatology.uni-kiel.de**

Introduction

The description of atopic dermatitis (also known as atopic eczema) in ancient times already noted its clinical hallmarks—namely, intense itch and inflammatory eczematous lesions.[1] Nowadays, atopic dermatitis is one of the most common chronic diseases and affects up to a fifth of the population in developed countries. For many years, it was thought to be the first manifestation of atopy (the familial propensity to become IgE-sensitised to environmental allergens) and the initial step in the so-called atopic march that ultimately leads to asthma and allergic rhinitis. As such, research into pathogenesis, prevention, and treatment focused on systemic abnormalities of humoral and T-cell-mediated immune responses. However, findings from epidemiology and molecular research have questioned a primary role of allergic mechanisms and, although not detracting the importance of immune mechanisms, they have placed the epidermis and its barrier functions at the forefront of research and management efforts.[2,3]

Prevalence

Lifetime prevalence has shown a worldwide increase in the past 30 years. In developed countries, it seems to plateau now at 10–20%, whereas it is lower but continues to increase in many developing countries.[4,5] In roughly 60% of cases, the disease manifests during the first year of life (ie, early onset), but it can start at any age.[6,7] The earliest clinical signs are skin dryness and roughness, but eczematous lesions usually do not occur before the second month of life. The course can be continuous for long periods or of a relapsing–remitting nature with repeated flare-ups.[6,7] The disease is mild in about 80% of affected children.[8] Birth cohort studies[6,9] have suggested that, in up to 70% of cases, the disease greatly improves or resolves until late childhood and that early and severe onset, family history of atopic dermatitis, and early allergen sensitisations are risk factors for a long course. However, recent prevalence estimates in adults of around 10%[10] and findings from a paediatric registry[11] suggest that the prevalence of persistent or adult-onset disease is higher than previously assumed. Further, patients who have apparently outgrown the disease continue to have so-called sensitive hyper-reactive skin and might have recurrences after long symptom-free periods.[7]

Clinical features and diagnosis

No specific laboratory or histological findings have been reported, and thus the diagnosis relies exclusively on clinical features. Several sets of diagnostic criteria have been developed[12]—eg, the Hanifin and Rajka criteria, and an empirically derived, simplified version distinguishing essential, common, and associated features (appendix), which are useful in the clinical setting. Essential features are pruritus and eczematous lesions that can be acute, subacute, or chronic (figure 1). The lesions can affect any part of the body but typically show age-related morphology and distribution (figure 2); rarely, they can generalise to secondary erythroderma. Common features include generalised skin dryness

See Online for appendix

Search strategy and selection criteria

We searched MEDLINE and the Cochrane Library for reports in English from Jan 1, 2010, to March 31, 2015. We used the search terms "atopic dermatitis", "atopic eczema", "childhood eczema", "infantile eczema", and "endogenous eczema". Relevant articles were reviewed, and the most recent ones were preferably cited. Additional reports were identified from the reference lists of selected articles. In general, we gave priority to studies in man for basic scientific research, and to randomised placebo-controlled trials and meta-analyses for clinical research. Some highly regarded older publications were cited either directly or indirectly through review articles.

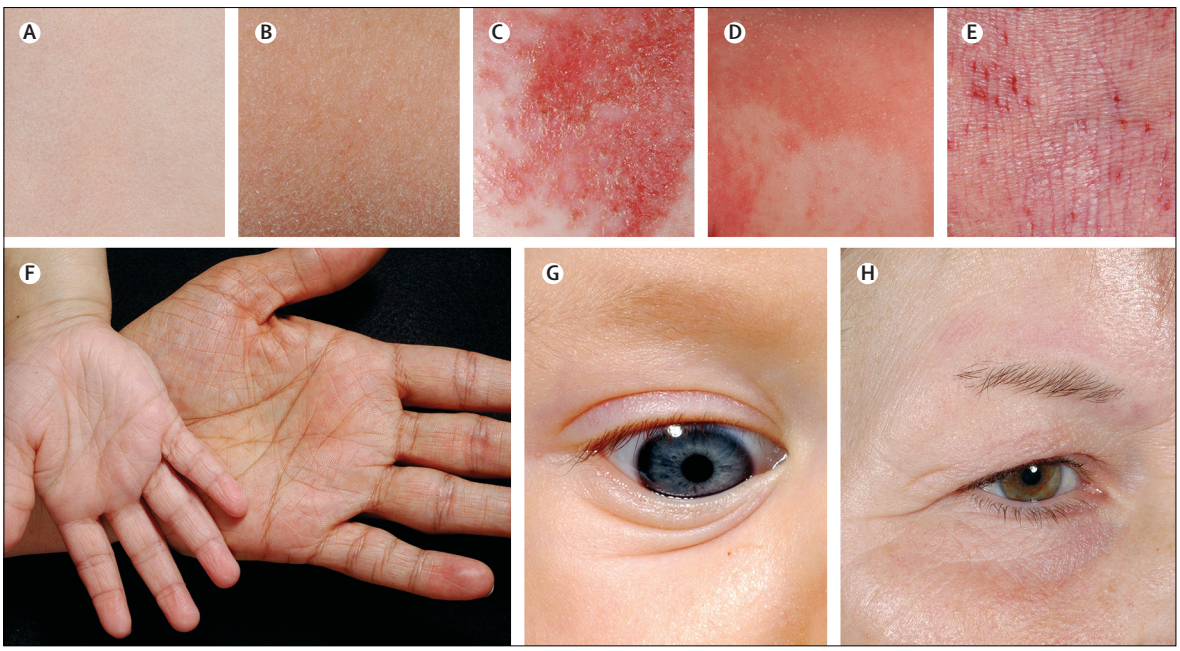

Figure 1: **Close-up view of (A) healthy skin, compared with (B) non-lesional, (C) acute, (D) subacute, and (E) chronic lesional skin in atopic dermatitis, and (F–H) associated atopic stigmata**

(B) Many patients with atopic dermatitis show generalised skin dryness (xerosis). (C) Acute lesions are characterised by diffuse erythematous patches and oozing papulovesicles. (D) Subacute lesions appear red, dry, and scaly. (E) Chronic lesions are poorly demarcated and have scaly patches and plaques with excoriation and lichenification. (F) Non-specific clinical features such as hyperlinear palms and soles are mostly seen in patients with filaggrin mutations or ichthyosis vulgaris. (G) Dennie–Morgan lines are single or double folds beneath the lower eyelids. (H) The Herthoge's sign refers to the thinning or absence of the lateral portion of the eyebrows.

(xerosis; figure 1B), early onset, and atopy. Associated features include so-called stigmata such as hyperlinearity of the palms and soles, Dennie–Morgan lines, and Herthoge's sign (figure 1F–H). Morphological variants include the follicular type characterised by densely aggregated follicular papules, which is frequently seen in dark-skinned and Japanese patients, and the prurigo type with erythematous, often excoriated papules and indurated nodules, which is sometimes seen in patients with longstanding disease. The UK working party criteria are a scientific refinement of the Hanifin and Rajka criteria of known validity and reliability, and are widely used for epidemiological and clinical studies of children.

Various methods have been established to measure disease severity. An international group working on a core outcome set for atopic dermatitis has recognised symptoms, objective signs, quality of life, and long-term control as core domains,[13] with the Eczema Area Severity Index and the Scoring of Atopic Dermatitis Index as preferred systems to measure signs.[14] High total or allergen-specific serum IgE concentrations are noted in many patients, although their absence does not exclude the diagnosis; the World Allergy Organization terminology uses the presence of specific IgE reactivity to distinguish atopic eczema from non-atopic eczema. In the first 2 years of life, up to two-thirds of infants with moderate to severe disease show sensitisation to food allergens,[15] whereas those with mild disease are less sensitised.[6] However, only a minor proportion of sensitised infants have IgE-mediated food allergy, which manifests as immediate-type non-eczematous skin reactions (eg, pruritus, flush, urticaria, and angio-edema) or gastrointestinal and respiratory symptoms, or both, but might be followed by eczema flares. Further, delayed reactions with gradual worsening of atopic dermatitis during 24–48 h after oral food challenge have been described.[16] Although insufficient data exist to accurately determine the prevalence of food allergy in individuals with atopic dermatitis, such allergy seems to affect around 30% of early and severe cases, is much lower in mildly affected and older children, and very rare in adults.[17–19] Whereas allergies to milk, egg, and wheat typically resolve during childhood, allergies to nuts and fish often persist.[16] As children grow older, the sensitisation pattern shifts towards inhalant allergens,[20] the exposure to which might also contribute to flares. A subgroup of patients show specific IgE reactivity against microbial antigens (such as yeast and *Staphylococcus aureus*).[21]

Other types of dermatitis sometimes resemble atopic dermatitis, and atopic dermatitis-like rashes might occur with rare primary immunodeficiency and keratinisation disorders, or as a result of nutritional deficiencies (table). In adults with erythrodermic or adult-onset dermatitis that is poorly responsive to topical treatment, skin biopsies should be done to rule out the possibility of cutaneous T-cell lymphoma.

Figure 2: **Typical clinical appearance and locations of atopic dermatitis at different ages**
(A) In infants, atopic dermatitis is generally acute, with lesions mainly on the face and the extensor surfaces of the limbs. The trunk might be affected, but the napkin area is typically spared. (B) From age 1–2 years onwards, polymorphous manifestations with different types of skin lesions are seen, particularly in flexural folds. (C) Adolescents and adults often present lichenified and excoriated plaques at flexures, wrists, ankles, and eyelids; in the head and neck type, the upper trunk, shoulders, and scalp are involved. Adults might have only chronic hand eczema or present with prurigo-like lesions.

Frequent complications

The skin of patients with atopic dermatitis is prone to secondary infections, which tend to generalise. *S aureus* is a leading cause of skin and soft-tissue infections. It is present transiently on healthy skin,[22] but permanently colonises patients' skin and frequently provokes an impetiginisation of lesions (figure 3A).[23] The progression to infection is often associated with a worsening of the disease. Eczema herpeticum (figure 3B) is a severe widespread skin infection with herpes simplex virus that occurs in up to 3% of patients, particularly in severely affected patients.[24] Children and adolescents with atopic dermatitis also have an increased susceptibility to molluscum contagiosum virus infection (figure 3C).[25] In patients with a so-called head and neck type of atopic dermatitis (figure 2), increased colonisation with and allergic sensitisation to the fungus *Malassezia sympodialis* are widely noted.[26] Although patients generally do not have an increased risk for contact sensitisations, they are more frequently sensitised against components of emollients such as preservatives, fragrances, emulsifiers, and antiseptics than are healthy individuals.[27]

	Main age group affected	Frequency*	Characteristics and clinical features
Other types of dermatitis			
Seborrhoeic dermatitis	Infants	Common	Salmon-red greasy scaly lesions, often on the scalp (cradle cap) and napkin area; generally presents in the first 6 weeks of life; typically clears within weeks
Seborrhoeic dermatitis	Adults	Common	Erythematous patches with yellow, white, or grayish scales in seborrhoeic areas, particularly the scalp, central face, and anterior chest
Nummular dermatitis	Children and adults	Common	Coin-shaped scaly patches, mostly on legs and buttocks; usually no itch
Irritant contact dermatitis	Children and adults	Common	Acute to chronic eczematous lesions, mostly confined to the site of exposure; history of locally applied irritants is a risk factor; might coexist with atopic dermatitis
Allergic contact dermatitis	Children and adults	Common	Eczematous rash with maximum expression at sites of direct exposure but might spread; history of locally applied irritants is a risk factor; might coexist with atopic dermatitis
Lichen simplex chronicus	Adults	Uncommon	One or more localised circumscribed lichenified plaques that result from repetitive scratching or rubbing because of intense itch
Asteatotic eczema	Adults	Common	Scaly, fissured patches of dermatitis overlying dry skin, most often on lower legs
Infectious skin diseases			
Dermatophyte infection	Children and adults	Common	One or more demarcated scaly plaques with central clearing and slightly raised reddened edge; variable itch
Impetigo	Children	Common	Demarcated erythematous patches with blisters or honey-yellow crusting
Scabies	Children	Common†	Itchy superficial burrows and pustules on palms and soles, between fingers, and on genitalia; might produce secondary eczematous changes
Congenital immunodeficiencies			
Hyper-IgE syndrome	Infants	Rare	Pustular and eczematous rashes within first weeks of life; staphylococcal infections of the skin, sinuses, and lungs; high serum IgE; eosinophilia
Wiskott-Aldrich syndrome	Infants	Very rare	Rash identical to that of atopic dermatitis, usually in first weeks of life in boys; microthrombocytopenia
Omenn syndrome	Infants	Very rare	Early-onset erythroderma, diffuse scaly rash, and chronic diarrhoea
Keratinisation disorders			
Ichthyosis vulgaris	Infants and adults	Uncommon	Dry skin with fine scaling, particularly on the lower abdomen and extensor areas; perifollicular skin roughening; palmar hyperlinearity; full form (ie, 2 *FLG* mutations) is uncommon; often coexists with atopic dermatitis
Netherton syndrome	Infants and adults	Very rare	Eczematous lesions spread over the skin in a serpiginous linear pattern with double-edged scales; hair shaft anomalies (bamboo hair); increased IgE; eosinophilia
Nutritional deficiency			
Zinc deficiency	Children	Uncommon	Erythematous scaly patches and plaques most often around the mouth and anus; rare congenital form accompanied by diarrhoea and alopecia
Neoplastic disease			
Cutaneous T-cell lymphoma	Adults	Uncommon	Erythematous pink-brown macules and plaques with a fine scale; poorly responsive to topical steroids; variable itch (in early stages)

FLG=filaggrin. *Common=roughly 1 in 10 to 1 in 100; uncommon=roughly 1 in 100 to 1 in 1000; rare=roughly 1 in 1000 to 1 in 10 000; very rare=less than 1 in 10 000. †Especially in developing countries.

Table: **Common differential diagnosis of atopic dermatitis**

Effects on patients

Itch, sleep deprivation, and social embarrassment due to visible lesions have substantial effects on the psychosocial wellbeing of patients and their relatives. In children, the effect of atopic dermatitis on health-related quality of life is similar to that of other major childhood disorders such as asthma and diabetes.[28] Children and adolescents with atopic dermatitis are also at a roughly 1·5-times increased risk for attention-deficit hyperactivity disorder, which might be driven by sleeping problems.[29] Further, the prevalence of depression, anxiety, conduct disorder, and autism is increased, particularly in severely affected children.[30] Adults with atopic dermatitis are more likely to have depression than are healthy individuals.[31]

Children with atopic dermatitis, particularly those with early sensitisation and severe disease, have an increased risk for asthma and allergic rhinitis.[6] However, a systematic review of 13 cohort studies[32] showed that only one in three infants with atopic dermatitis develops asthma; thus, the risk is lower than widely assumed. Further, in many cases, wheezing seems to coincide with or even precede development of skin symptoms, suggesting that it is a distinct subphenotype rather than a progressive so-called atopic march.[2,6] A latent class analysis in two large population-based cohorts[33] showed that only about 20% of children with atopic dermatitis followed disease trajectories that included the development of respiratory symptoms, and less than 7% showed development that resembled an atopic march. A cross-sectional analysis in 12 European

Figure 3: **Bacterial and viral complications**
The skin of patients with atopic dermatitis shows a less diverse microbiome, with a relative abundance of *Staphylococcus aureus*, than healthy individuals and an increased susceptibility to microbial superinfection. (A) Infantile atopic dermatitis with clinical signs of staphylococcal infection: affected areas typically present with increased erythema, oozing, and honey-coloured crusts. (B) Eczema herpeticum: monomorphic eruption of umbilicated and eroded punch-out vesicles predominantly occurs in eczematous areas. (C) Molluscum contagiosum infection: several flesh-coloured hemispheric and slightly umbilicated papules of 2–3 mm are shown in the flexural area of a patient with atopic dermatitis. Lesions also occur on non-inflamed skin and could spread by autoinoculation.

birth cohorts[34] showed that IgE-mediated sensitisation is not the major shared mechanism driving the excess comorbidity of asthma and allergic rhinitis.

Fewer high-quality data for comorbidities other than atopic and mental health disorders have been obtained. Preliminary evidence suggests that patients with atopic dermatitis are also at increased risk for alopecia areata, vitiligo, rheumatoid arthritis, and inflammatory bowel disease,[35,36] whereas the risk for type 1 diabetes and cancers such as glioma, meningioma, and acute lymphoblastic leukaemia is decreased.[35,37]

Effects on society

In the WHO 2010 Global Burden of Disease survey, atopic dermatitis ranked first among common skin diseases with respect to disability-adjusted life-years[38] and years lived with a disease.[39] These findings show that the disease has an important health effect at a population level, albeit the true burden was probably underestimated because psychosocial effects and comorbidities were not considered. The economic effects have been investigated only in a few studies, which are not readily comparable because of differences in patient settings and cost-accounting methods, but the overall medical costs seem to be high and broadly similar to those of diseases such as asthma. A review of four studies[40] estimated that the average direct annual costs could be close to US$5 billion (inflated to 2014 dollars) in the USA. Out-of-pocket expenses, such as for non-prescription expenditures, could constitute up to 10% of the household annual income.[41] Comorbidities add further to the costs, as shown in a case-control cohort study of more than 3 million people that showed an increase of 1·5 times in costs through comorbid atopic diseases.[42]

Causes and risk factors

The strongest risk factor is a positive family history for atopic diseases, particularly for atopic dermatitis.[43] Twin studies suggested a heritability of more than 80%,[44] although this percentage might be an overestimation, since gene–gene interaction effects were not considered. Until now, 32 susceptibility loci have been identified through gene-mapping studies, but they explain less than 20% of the estimated heritability.[45–50] The strongest known genetic risk factor is null mutations in filaggrin (*FLG*), which encodes a key epidermal structural protein.[51] *FLG* mutations cause the semidominant skin-scaling disorder ichthyosis vulgaris, which is characterised by abnormal skin dryness and palmar hyperlinearity—features often seen in patients with atopic dermatitis (table). Roughly 10% of individuals of European ancestry carry a single null mutation in *FLG* and have mild ichthyosis vulgaris, and their risk for atopic dermatitis is increased by three times.[51] Of note, most patients with atopic dermatitis do not have any *FLG* mutation, and up to 60% of carriers will not develop atopic disease[51]—ie, *FLG* mutations are neither necessary nor sufficient to cause atopic dermatitis.

Most of the other known risk genes contribute to immune mechanisms, particularly to innate immune signalling, T-cell activation, and T-cell specification (figure 4). Only few of these genes have been implicated in other atopic traits, but many of them have been linked to other inflammatory diseases, suggesting that non-atopy-related molecular processes are operational.[45] The inherited susceptibility is triggered into disease manifestation by environmental and lifestyle factors. Well established environmental risk factors are a so-called western diet with high amounts of sugar and poly-unsaturated fatty acids, small family size, high education

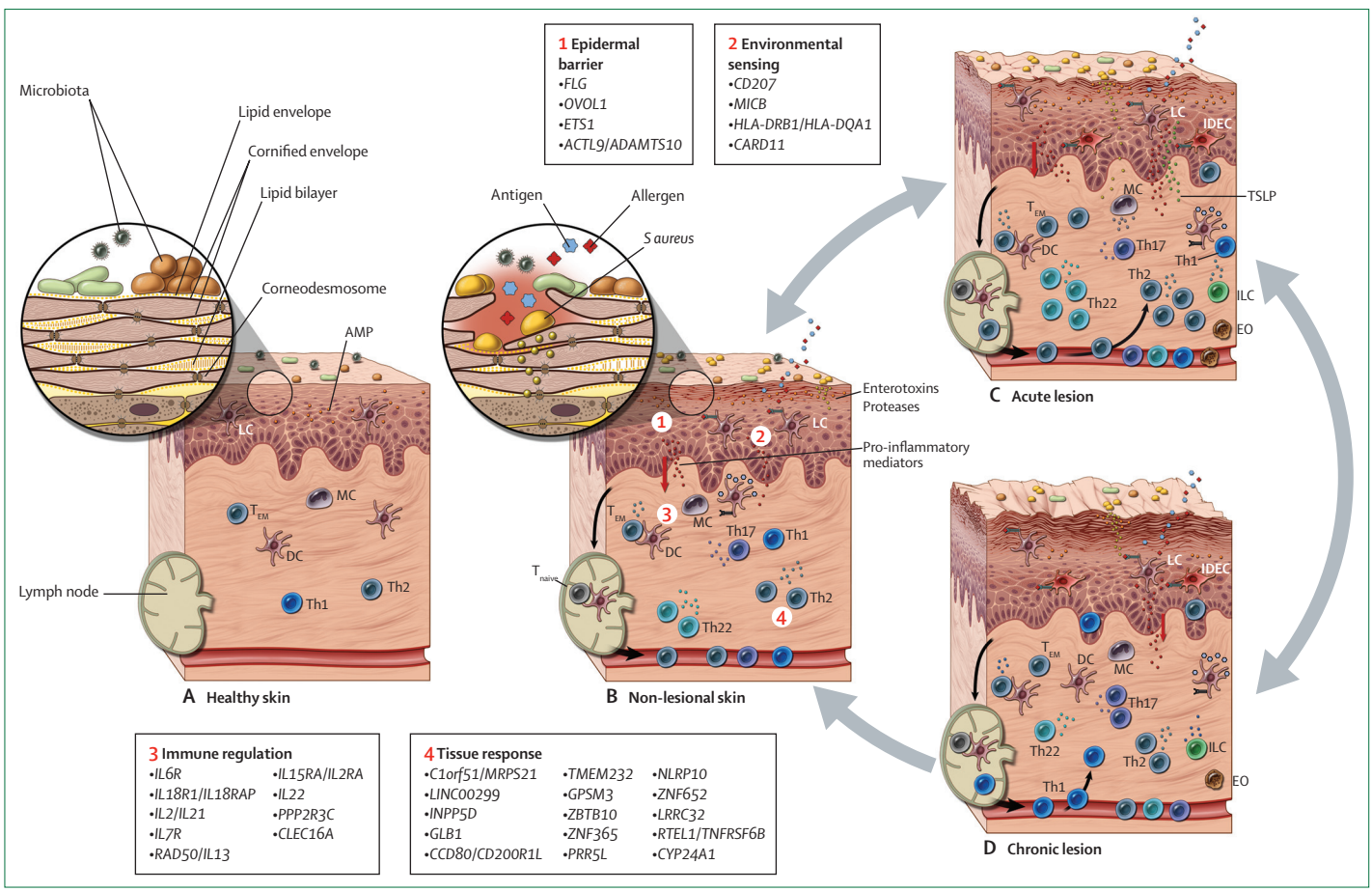

Figure 4: **Key pathophysiological changes in atopic dermatitis**

(A) The protective functions of the skin are mainly mediated by the stratum corneum, which consists of corneocytes filled with keratin fibrils and surrounded by a cornified cell envelope of a densely cross-linked layer of proteins. A monolayer of non-polar lipids is esterified to the cornified envelope and forms the matrix for the intercellular lipid bilayers. Corneodesmosomes form bridges between corneocytes and must be degraded for desquamation. (B) Clinically unaffected skin of patients with atopic dermatitis shows epidermal barrier dysfunction with reduced expression of several epidermal differentiation gene products such as filaggrin, altered lipid composition and organisation, release of innate immune cytokines from keratinocytes, and increased exposure to and uptake of antigens with subsequent B-cell and T-cell priming in the lymph nodes. Further, there are signs of low-level inflammation with some infiltration by Th2 and Th22 cells, and increased expression of Th2-promoting cytokines and chemokines. The microbial diversity is reduced in favour of *S aureus*. Text boxes show the most plausible candidate genes in susceptibility loci identified through genome-wide association studies. (C) The transition from non-lesional to acute lesional skin is associated with upregulation of a subset of terminal differentiation genes, in particular *S100A7*, *S100A8*, and *S100A9*, whereas the expression of other epidermal differentiation genes such as filaggrin remains low. Despite induction of AMPs, the abundance of *S aureus* further increases; *S aureus*-derived proteases and enterotoxins contribute to barrier disruption and inflammation. LCs and IDECs bearing specific IgE bound to the high-affinity receptor for IgE (FcεRI) and dermal DCs take up allergens and antigens encountered in the deficient epidermis. T_{EM} cells are activated from local skin pools and in regional lymph nodes. Th2 and Th22 responses are amplified, and initial Th1 and Th17 responses are induced. Their pro-inflammatory mediators further impair epidermal differentiation and integrity, and activate keratinocytes to release pro-inflammatory and pruritogenic mediators. (D) Chronic lesions are characterised by further progression of epidermal hyperplasia, altered corneocyte composition and adhesion, and reduced amounts of intercellular lipids. Continued activation of Th2 and Th22 subsets and activation of Th1 and Th17 pathways further impair epidermal barrier function, accelerate local inflammation, and promote cutaneous remodelling and neuroinflammation. AMP=antimicrobial peptides. DC=dendritic cell. EO=eosinophil. IDEC=inflammatory dendritic epidermal cell. ILC=innate lymphoid cell. LC=Langerhans cell. MC=mast cell. *S aureus*=*Staphylococcus aureus*. T_{EM}=effector memory T cell. Th=T-helper. TSLP=thymic stromal lymphopoietin.

level in the household, and living in urban settings and regions with low exposure to ultraviolet radiation and low humidity.[52] A systematic review of 113 population-based studies[53] identified no clear evidence for a role of specific infections or vaccinations, but that atopic dermatitis has a significant positive association with exposure to broad-spectrum antibiotics during pregnancy and infancy, particularly frequent courses; some less consistent evidence was reported for protective effects of early day care, endotoxin exposure, consumption of unpasteurised farm milk, and exposure to dogs—ie, increased exposures to non-pathogenic microorganisms.

Main mechanisms of disease

The two major and converging pathophysiological peculiarities are abnormalities of epidermal structure and function, and cutaneous inflammation due to inappropriate immune responses to antigens encountered in the skin. The primary events and key drivers of the disease are topics of continuing debate;[3] however, clearly, skin barrier biology and immune mechanisms closely interact.

The skin is an efficient physicochemical, microbial, and immunological barrier that exerts several protective functions, many of which are in the epidermis.

The two major epidermal barrier structures are the stratum corneum and its main structural components (figure 4), and tight-junction proteins, which mediate keratinocyte adhesion in the stratum granulosum and are thought to contribute to the paracellular diffusion barrier.[54] Stratum corneum function crucially depends on proper differentiation of keratinocytes, coordinated activity of acid, lipid, and enzyme constituents, and balanced desquamation of corneocytes. Several stratum corneum abnormalities are well established features associated with atopic dermatitis,[54] such as decreased hydration and increased water loss,[55,56] altered lipid composition with reduced ceramide content and chain length, decrease of some ceramide classes, aberrant lamellar organisation,[56–58] raised skin pH,[56] aberrant activity of serine proteases,[59] and reduced skin microbiome diversity with an increased abundance of *S aureus*.[23]

For a long time, these features were regarded as secondary effects of immunological mechanisms.[3] However, insights into genetically determined epidermal defects that confer susceptibility to atopic dermatitis have shifted the focus to impairments of epidermal function.[60] Apart from inherited *FLG* null mutations, several factors such as *FLG* copy number variants, mechanical damage, low humidity, and the cutaneous cytokine dysbalance in atopic dermatitis cause a reduction in filaggrin expression.[61] Filaggrin deficiency affects several pathways that are relevant for epidermal barrier dysfunction, including disturbed keratinocyte differentiation,[62] impaired corneocyte integrity and cohesion,[63] impaired tight-junction formation,[63] decreased water retention,[55,56] stratum corneum acidification,[64] altered lipid formation,[56,63,64] and enhanced cutaneous infectivity.[65,66] Further, filaggrin deficiency is associated with subclinical inflammation,[67–69] increased permeability to low-molecular-weight, water-soluble tracers,[63,67,70] reduced inflammatory thresholds to irritants and haptens,[67,68] and enhanced percutaneous allergen priming.[68,71] However, poor epidermal barrier function is not confined to defects of structural proteins and not exclusive to *FLG* mutation carriers. Other inherited factors and environmental exposures such as soaps, detergents, exogenous proteases (eg, from mite allergens), and repetitive scratching might impair various aspects of barrier function.[54] Supposedly, different combinations and accumulations of inherited and exogenous factors can initiate a breakdown of epidermal function.

Cutaneous inflammation is the second hallmark and is characterised by sequential and progressive patterns of inflammatory cell infiltration, particularly by $CD4^+$ cells (figure 4). Non-lesional skin already shows signs of a subclinical inflammation with increased numbers of T-helper-2 (Th2) cells, Th22 cells, and, to a lesser degree, Th17 cells, and a pro-inflammatory cytokine milieu.[72] Infiltrating T cells express various skin-homing adhesion molecules, such as cutaneous lymphocyte antigen, chemokines, and lipid chemoattractant receptors, which enable their recruitment into cutaneous sites.[73] Besides constant recirculation through the skin, antigen-primed T cells persist as resident effector memory cells in local skin pools and exert rapid recall responses.[73] Further, increased numbers of Th2-cytokine-producing type 2 innate lymphoid cells are found in atopic dermatitis lesions and contribute to local inflammation.[74,75]

The progression to flares is characterised by increased epidermal thickness with sprouting of nerve fibres,[76] enhanced expression of immunostimulatory chemokines,[77] and noticeable infiltration, particularly by Th2 cells and epidermal dendritic cells.[77–79] In chronic lesions, the cellular infiltrate is further expanded but contains both Th2 and Th1 cells, and it has fewer Th22 and Th17 cells than acute lesions.[78] Th17 and Th22 cells, together with chemokines and cytokines derived from fibroblasts and keratinocytes, such as thymic stromal lymphopoietin,[80] drive tissue remodelling and fibrosis.[81,82] Thymic stromal lymphopoietin also enhances maturation and proliferation of dendritic cells, promotes Th2-cell polarisation, and induces B-cell proliferation and differentiation.[83] Treated and resolved areas continue to show immunological and structural abnormalities that might contribute to the reoccurrence of inflammation at the same sites.[84]

In atopic dermatitis, apart from dermal dendritic cells, antigen presentation occurs through epidermal Langerhans cells and inflammatory dendritic epidermal cells, which bear a trimeric high-affinity receptor for IgE.[85] Through IgE bound to this receptor, these cells can take up allergens that classically cause immediate-type allergic reactions and induce T-cell-mediated reactions of the delayed type.[85] T-cell responses might also be directed towards self-antigens, at least in subgroups of patients. Several keratinocyte-derived antigens that bind to IgE have been described, many of which show homology with environmental allergens.[86] A systematic review[87] provided evidence for IgE autoreactivity in up to a third of patients. Preliminary evidence has also been reported for the presence of autoreactive T-cell clones in the skin and blood of patients.[88,89] However, their frequency, specificities, and temporal importance remain to be determined.

Epidermal barrier disruptions and skin inflammation are mutually reinforcing processes (appendix). Perturbations of the epidermal barrier intrinsically stimulate inflammation by activation of keratinocytes to release chemokines that attract T cells,[90] cytokines mediating innate immune responses (such as members of the interleukin [IL]-1 family),[69] and cytokines driving Th2-cell polarisation and Langerhans-cell activation (such as IL-25,[91] IL-33,[92] and thymic stromal lymphopoietin).[93] Accumulating evidence shows that interaction of the compromised barrier with this immune environment also promotes percutaneous allergic sensitisation.[71,94,95]

For more on the **Global Resource for Eczema Trials** see www.greatdatabase.org.uk

The deficient epidermal barrier, together with an insufficient upregulation of specific antimicrobial peptides, further enhances colonisation with *S aureus*.[96,97] *S aureus* contributes to exacerbations and chronification through production of proteases,[98] stimulation of innate signalling pathways,[99] and release of enterotoxins that act as T-cell-activating superantigens;[100] it can also cause IgE-mediated sensitisation[21] and directly induce degranulation of mast cells.[101] The susceptibility to herpes simplex virus infection seems to result from a combination of epidermal deficiency[65] and aberrant innate[102] and adaptive[24,103] immune responses.

In turn, cutaneous inflammation and immune dysregulation affect epidermal structure and function. In particular, the expression of differentiation-associated proteins and tight-junction proteins is decreased,[104–107] protease activities are upregulated,[108] and lipid synthesis and processing are impaired.[109] The crosstalk between keratinocytes and immune cells is also crucial in the regulation of itch.[110] On activation, these types of cells both generate high concentrations of mediators that contribute to sprouting of nerve fibres and directly or indirectly stimulate sensory nerve endings.[110] Thymic stromal lymphopoietin derived from keratinocytes seems to have a dual role in that it directly communicates with somatosensory nerves[110] and elaborates Th2 cytokines such as IL-13 and IL-31, which stimulate nerve fibres directly and via upregulation of the release of cellular pruritogens.[111,112] The resulting neurogenic inflammation completes the vicious circle by promotion of Th2 responses, keratinocyte proliferation, and epidermal thickening.[113]

Management

Atopic dermatitis cannot be cured at present; thus, the aim of management is to improve symptoms and achieve long-term disease control with a multistep approach, as outlined in national and international guidelines (appendix). The main principles are continuous epidermal barrier repair with emollients, avoidance of individual trigger factors, and anti-inflammatory therapy with topical corticosteroids or calcineurin inhibitors. In severely affected cases, phototherapy or systemic immunosuppressants are indicated (appendix).

Treatment failure due to poor adherence, in particular to topical therapy, is common and is related to irrational fears around potential adverse effects of corticosteroids, insufficient information, and inconvenience of regimens.[114] Therefore, doctors should spend sufficient time to explain the disease and its treatment, and to keep the regimen straightforward and tailored to the individual patient. Written action plans might be helpful. More comprehensive and structured education and training programmes, such as multidisciplinary training schools and nurse-led clinics, reduce disease severity and improve quality of life.[115] A wide range of other educational, psychological, and behavioural interventions with different service delivery models is available, but trial data to assess their effectiveness are insufficient at present.[115] Randomised controlled trials and systematic reviews of atopic dermatitis treatments are deposited in the Global Resource for Eczema Trials database.

The generalised skin dryness and research evidence for a major pathogenic role of epidermal dysfunction underscore the importance of continuous restoration and maintenance of epidermal barrier homoeostasis. Although supported by few trial data, the frequent and generous use of emollients is of key importance in this respect.[116] Emollients soften the skin through supply of exogenous lipids and reduce water loss by formation of an occlusive layer. Added humectants such as urea (not to be used in infants), glycerine, and lactic acid can further increase water binding in the stratum corneum. Some new products contain other adjuvant ingredients such as ceramides and essential fatty acids, but no evidence exists for their superiority over traditional emollients. Likewise, no evidence has been reported to support the benefit of preparations containing antiseptics and antimicrobials. To avoid irritant and allergic reactions, emollients with few ingredients and without fragrances and perfumes should be used. Further, the choice of emollients should meet the individual patient's needs—ie, age, body area, acuteness, climate, and individual preferences. Creams with intermediate lipid content are best applied on large and subacute areas. Ointments are richer in lipids, provide more lubrication and occlusion, and are useful for treatment of dry and lichenified areas. Lotions have a high water content and can be used to cool or dry strongly inflamed and oozing lesions. Emollients should be used at least twice per day all over the body, including after bathing; soaps, bubble baths, and shower gels should be replaced by non-soap fragrance-free cleaners with a neutral to low pH.[116] The true added value of bath additives is unclear.

Factors widely assumed to provoke flares or cause worsening of the disease include specific factors such as food, inhalant, or contact allergens, and unspecific factors such as detergents, wool fabrics, extremes of temperature and humidity, infections, cutaneous microbial colonisation, and psychological stress.[117,118] In general, these factors have not been well studied for their role in flares, and most recommendations are based on clinical experience and theoretical considerations rather than scientific evidence. Therefore, environmental avoidance measures should be individualised and based on a definite history of worsening after exposure, along with allergy testing when necessary.[119–121]

Topical corticosteroids are the first-line anti-inflammatory treatment to control acute exacerbations. Their efficacy has been measured in several randomised controlled trials.[122] A systematic review[123] showed that their appropriate intermittent use bears little risk. Available products differ in terms of type, potency, concentration of

the active molecule, and the formulation. Although most countries recognise four classes of strength, from mild (class I) to very potent (class IV), the US classification, which considers both drug concentration and formulation, ranges from ultra-high potency (group I) to low potency (group VII). As a general rule, on the face, on areas with thinner skin, and in children, low-potency corticosteroids are preferred, except for short-term treatment of severe flares. Traditionally, a twice-daily application on affected areas is recommended, but a systematic review of ten randomised controlled trials[124] showed that, for more potent and newer preparations, a once daily application is equally effective. As an acute intervention, (diluted) corticosteroids can also be applied under wet wrap dressings to enhance penetration and skin hydration.[125] No evidence exists to support a benefit from combinations of topical corticosteroids and antiseptics over topical corticosteroids alone.

Topical calcineurin inhibitors are non-steroidal anti-inflammatory agents that are available as ointments (tacrolimus 0·03% and 0·1% for adults, 0·03% for children aged ≥2 years) and creams (pimecrolimus 1% for patients aged ≥2 years). They are regarded as a second-line option for short-term and intermittent treatment. Systematic reviews of randomised controlled trials[126,127] showed that they are safe and effective, and that the potency of tacrolimus 0·1% is roughly equivalent to that of moderately potent topical corticosteroids, and the potency of pimecrolimus cream is roughly similar to that of mildly potent topical corticosteroids. The main rationale for topical calcineurin inhibitors is that they do not cause skin atrophy and are therefore of particular value in delicate skin areas such as the face and the groins.[128,129] However, a multicentre, open-label, randomised, parallel-group phase 4 trial[130] did not report any evidence of clinically significant skin thinning when mild to moderate topical corticosteroids were used in infants aged 3–12 months for a period of 5 years. Topical pimecrolimus treatment needed considerable so-called rescue treatment from topical corticosteoids, but not vice versa. In the absence of safety data for the long-term continuous use of topical calcineurin inhibitors, the US Food and Drug Administration issued a black box warning regarding a theoretically increased risk for lymphoma and non-melanoma skin cancer (induced by ultraviolet radiation), but no scientific evidence of such an increased risk has been reported.

The absence of controlled studies investigating the best order of and interval between topical applications is an important issue for clinical practice. At present, the general recommendation is to apply emollients first and leave at least an hour until corticosteroids or calcineurin inhibitors are applied, or to apply them at different times of the day, to avoid their dilution and diversion.

After stabilisation of an acute flare, remission maintenance should be attempted through continued emollient treatment. Additionally, application of topical corticosteroids or topical calcineurin inhibitors to previously active sites for two consecutive days per week can further reduce flares, as shown in a systematic review of eight vehicle-controlled trials.[131] This so-called proactive secondary prevention approach is especially useful in patients with frequent outbreaks on the same body sites and can be scheduled, for example, as a so-called pulsed weekend therapy.

If the disorder cannot be controlled with topical measures, short-term phototherapy (usually 4–8 weeks) should be considered. A systematic review of 19 randomised controlled trials[132] showed that narrow-band ultraviolet B radiation and medium-dose ultraviolet A1 radiation are more effective than other phototherapy regimens. Because of a potentially increased cumulative risk of skin cancer, phototherapy should not be combined with topical calcineurin inhibitors and systemic ciclosporin treatment, and should be used with caution in children.

When topical treatment and phototherapy fail, systemic immunosuppressive therapies are required. The most widely used agents are ciclosporin, azathioprine, methotrexate, and mycophenolate mofetil. With the exception of ciclosporin, which is licensed for short-term treatment of severe refractory atopic dermatitis in many European countries, these agents are used off-label. In a systematic review summarising findings from 34 randomised controlled trials on systemic therapies,[133] the strongest evidence was reported for the effectiveness of ciclosporin in both adults and children. A meta-analysis of 18 controlled and uncontrolled trials[134] showed a roughly 50% improvement in mean disease severity after 6–8 weeks of treatment. Ciclosporin has a rapid onset of action and can be used for a short course or several courses of 12 weeks with intermission periods, or continuously for up to 1–2 years.[134] Unfortunately, its discontinuation is often followed by disease relapses. Mycophenolate mofetil has a favourable side-effect profile but is regarded only as a third-line option because of insufficient effectiveness data. A randomised controlled trial[135] showed that it might be a valuable option for long-term maintenance after induction therapy with ciclosporin. The efficacy of azathioprine in short-term (up to 24 weeks) treatment is well established, whereas fewer conclusive data are available on methotrexate. In a randomised comparison trial,[136] both azathioprine and methotrexate led to a reduction of clinical scores by roughly 40–50%, but their relative efficacy could not be estimated reliably. On the basis of indirect comparisons, both drugs seem to be less efficient than ciclosporin, but are also safe and well tolerated in children.[137,138] Systemic corticosteroids have an unfavourable risk–benefit profile, and insufficient trial evidence has been reported for their use in atopic dermatitis; therefore, they should be restricted to exceptional cases and short-term treatments.

A systematic review of 26 studies of 1229 participants[139] showed no clear evidence for a clinical benefit of

anti-staphylococcal interventions such as antiseptic bath additives or soaps, or the addition of antimicrobial agents to topical therapies in non-infected atopic dermatitis, although such agents might be helpful for individual patients with frequent superinfections. Although no clear evidence supports the role of topical antiseptics in clinically infected atopic dermatitis, such antiseptics might be sufficient to treat small areas and are preferable over topical antibiotics with regard to the development of bacterial resistance. More extensive forms of superinfection need treatment with short courses of systemic antibiotics. In any case, topical therapy with emollients and corticosteroids should be continued.[140] If eczema herpeticum is suspected, treatment with systemic aciclovir should be started immediately. Molluscum contagiosum is usually self-limited, but lesions often resolve slowly and tend to spread in patients with atopic dermatitis. For very large, widespread, or persistent molluscum contagiosum infection, several treatment options exist, but none is universally effective.[25] Patients with the head, neck, and shoulder type of atopic dermatitis and those sensitised to *Malassezia* spp might benefit from a course of oral azole antifungals for 1–2 months.[21,141] The effectiveness of topical antifungals has not been well studied.

Oral H1-antihistamines are frequently used in atopic dermatitis, but little evidence exists that they are effective for atopic dermatitis signs and symptoms, including itch.[142] No evidence has been reported in favour of probiotics,[143] dietary supplements,[144] botanical extracts,[145] and homoeopathy.[146] Similarly, no evidence-based recommendation for the routine use of specialised clothing fabrics can be made, but, in individual cases, silk garments or clothing impregnated with silver might be beneficial.[147] The value of specific immunotherapy for atopic dermatitis is still unclear.[148]

Driven by new research findings and advances in biotechnology, several therapies that act on specific molecular targets are emerging. Although the development of these approaches (eg, to restore filaggrin deficiency[149,150]) is still in early stages, drugs modifying immune pathways involved in atopic dermatitis are already in advanced stages of development (appendix). An analysis of pooled randomised controlled phase 1b studies on dupilumab,[151] a monoclonal anti-IL-4Rα antibody, showed large improvements in clinical scores and pruritus.

Panel: Important developments in understanding and management of atopic dermatitis

- Atopic dermatitis starts most frequently in infancy but is outgrown less often than widely assumed; in most patients, it causes life-long skin problems
- The associations of atopic dermatitis with asthma and allergic rhinitis are weaker than previously assumed
- Atopic dermatitis causes substantial psychological morbidity
- Apart from T-helper-2 (Th2) cells, other T-cell subsets such as Th1, Th17, and Th22 cells contribute to skin inflammation
- A large fraction of effector T cells are recruited from skin-resident pools of memory cells
- Autoimmune mechanisms might contribute to the chronicity of the disease
- Inherited and acquired factors lead to abnormal epidermal structure and function
- Thymic stromal lymphopoetin derived from keratinocytes drives allergic responses, skin remodelling, and itch
- The continuous use of emollients is important in established disease, and their early use from birth might have preventive effects
- A proactive application of topical corticosteroids and calcineurin inhibitors for two consecutive days per week can help to reduce disease flares
- Data for long-term safety and comparative effectiveness of systemic immunosuppressive therapies are insufficient

Prevention

No primary prevention strategy has been established at present. Most interventions tested so far focused on allergen avoidance or immunomodulation,[152] but an overview of systematic reviews[153] did not report clear evidence for effectiveness of measures such as maternal dietary antigen avoidance during pregnancy and breastfeeding, long-term breastfeeding, hydrolysed protein formulas, soy formulas, omega-3 or omega-6 fatty acid supplementation, and interventions with prebiotics or probiotics. Similarly, results from a German birth cohort study[154] showed no evidence in support of a delayed introduction of solid foods. Prevention approaches aiming to enhance skin barrier function have been developed. One pilot study[155] and two randomised controlled trials[156,157] reported that a daily full-body emollient therapy from birth reduced the cumulative incidence of atopic dermatitis in high-risk infants by 30–50%.

Unresolved questions

Despite much progress (panel), a synthesis of research findings for atopic dermatitis has proved difficult. Our understanding of the natural history of childhood disease and the factors determining its remission and persistence is incomplete, as is the knowledge on epidemiology and clinical features in adults. Ironically, pathophysiological investigations were mostly done in tissue from (few) adult patients, and the generalisability of these results is unclear. Epidermal dysfunction is undoubtedly a major pathogenic mechanism, but is it the primary driver and equally important in all patients, and how exactly does it affect the permeability for exogenous substances? Autoimmune mechanisms might be of particular relevance for chronification and persistence, but their exact role has yet to be defined. The precise mechanisms through which emollients exert their beneficial effects are insufficiently understood, and few evidence-based data exist to guide the selection of specific preparations. Knowledge of the relative importance of the different barrier components and their relation with immune regulation needs to be deepened to optimise barrier enhancement approaches. Likewise, more research addressing the comparative effectiveness of available

topical and systemic anti-inflammatory therapies is needed. Finally, although itch is a major symptom, knowledge on its precise mechanisms is incomplete.

Many of the uncertainties are related to the striking heterogeneity of the disease, which is exemplified by variations in clinical features, course, and individual risk factors, and shown by the absence of reliable biomarkers, diagnostic tests, or specific treatments that would apply to all patients. The broad and inclusive notion of atopic dermatitis probably encompasses distinct subtypes with varying importance of different and interacting pathomechanisms that affect the homoeostasis of epidermal barrier function and immune response (appendix). To divide the disease into meaningful subtypes, long-term longitudinal studies with improved phenotyping and integration of clinical and molecular data will be instrumental.

Contributors

Both authors contributed equally to the literature search, writing and editing of the manuscript, and the generation of figures and table.

Declaration of interests

We declare no competing interests.

Acknowledgments

We thank Thomas Schwarz for review of the manuscript and helpful discussion, and Lennart Lenk, Thomas Heller, Arne Voss, Dagmar Blankenburg, Heidi Pönicke, and Hansjörg Schütze for help with the clinical pictures and illustrations. We acknowledge researchers whose work we could not cite because of space limitations. SW's research group received support from the German National Research Council (DFG) through individual grants and the Cluster of Excellence "Inflammation at Interfaces" (grant EXC306/2), and the German Federal Ministry of Education and Research (BMBF) within the framework of the e:Med research and funding concept (sysINFLAME, grant 01ZX1306A). NN's research group received support from the DFG through grant SFB704, the Cluster of Excellence "ImmunoSensation", and the Christine Kühne Stiftung Center for Allergy Research and Education (CK-CARE).

References

1 Wallach D, Taïeb A. Atopic dermatitis/atopic eczema. *Chem Immunol Allergy* 2014; **100:** 81–96.

2 Williams H, Flohr C. How epidemiology has challenged 3 prevailing concepts about atopic dermatitis. *J Allergy Clin Immunol* 2006; **118:** 209–13.

3 Elias PM, Steinhoff M. "Outside-to-inside" (and now back to "outside") pathogenic mechanisms in atopic dermatitis. *J Invest Dermatol* 2008; **128:** 1067–70.

4 Deckers IA, McLean S, Linssen S, Mommers M, van Schayck CP, Sheikh A. Investigating international time trends in the incidence and prevalence of atopic eczema 1990–2010: a systematic review of epidemiological studies. *PLoS One* 2012; **7:** e39803.

5 Williams H, Stewart A, von Mutius E, Cookson W, Anderson HR, and the International Study of Asthma and Allergies in Childhood (ISAAC) Phase One and Three Study Groups. Is eczema really on the increase worldwide? *J Allergy Clin Immunol* 2008; **121:** 947–54, e15.

6 Illi S, von Mutius E, Lau S, et al, and the Multicenter Allergy Study Group. The natural course of atopic dermatitis from birth to age 7 years and the association with asthma. *J Allergy Clin Immunol* 2004; **113:** 925–31.

7 Garmhausen D, Hagemann T, Bieber T, et al. Characterization of different courses of atopic dermatitis in adolescent and adult patients. *Allergy* 2013; **68:** 498–506.

8 Ballardini N, Kull I, Söderhäll C, Lilja G, Wickman M, Wahlgren CF. Eczema severity in preadolescent children and its relation to sex, filaggrin mutations, asthma, rhinitis, aggravating factors and topical treatment: a report from the BAMSE birth cohort. *Br J Dermatol* 2013; **168:** 588–94.

9 Peters AS, Kellberger J, Vogelberg C, et al. Prediction of the incidence, recurrence, and persistence of atopic dermatitis in adolescence: a prospective cohort study. *J Allergy Clin Immunol* 2010; **126:** 590–95, e1–3.

10 Silverberg JI, Hanifin JM. Adult eczema prevalence and associations with asthma and other health and demographic factors: a US population-based study. *J Allergy Clin Immunol* 2013; **132:** 1132–38.

11 Margolis JS, Abuabara K, Bilker W, Hoffstad O, Margolis DJ. Persistence of mild to moderate atopic dermatitis. *JAMA Dermatol* 2014; **150:** 593–600.

12 Brenninkmeijer EE, Schram ME, Leeflang MM, Bos JD, Spuls PI. Diagnostic criteria for atopic dermatitis: a systematic review. *Br J Dermatol* 2008; **158:** 754–65.

13 Schmitt J, Apfelbacher C, Spuls PI, et al. The Harmonizing Outcome Measures for Eczema (HOME) roadmap: a methodological framework to develop core sets of outcome measurements in dermatology. *J Invest Dermatol* 2015; **135:** 24–30.

14 Schmitt J, Langan S, Williams HC, and the European Dermato-Epidemiology Network. What are the best outcome measurements for atopic eczema? A systematic review. *J Allergy Clin Immunol* 2007; **120:** 1389–98.

15 de Benedictis FM, Franceschini F, Hill D, et al, and the EPAAC Study Group. The allergic sensitization in infants with atopic eczema from different countries. *Allergy* 2009; **64:** 295–303.

16 Longo G, Berti I, Burks AW, Krauss B, Barbi E. IgE-mediated food allergy in children. *Lancet* 2013; **382:** 1656–64.

17 Eller E, Kjaer HF, Høst A, Andersen KE, Bindslev-Jensen C. Food allergy and food sensitization in early childhood: results from the DARC cohort. *Allergy* 2009; **64:** 1023–29.

18 Worm M, Forschner K, Lee HH, et al. Frequency of atopic dermatitis and relevance of food allergy in adults in Germany. *Acta Derm Venereol* 2006; **86:** 119–22.

19 Martin PE, Eckert JK, Koplin JJ, et al, and the HealthNuts Study Investigators. Which infants with eczema are at risk of food allergy? Results from a population-based cohort. *Clin Exp Allergy* 2015; **45:** 255–64.

20 Wisniewski JA, Agrawal R, Minnicozzi S, et al. Sensitization to food and inhalant allergens in relation to age and wheeze among children with atopic dermatitis. *Clin Exp Allergy* 2013; **43:** 1160–70.

21 Sonesson A, Bartosik J, Christiansen J, et al. Sensitization to skin-associated microorganisms in adult patients with atopic dermatitis is of importance for disease severity. *Acta Derm Venereol* 2013; **93:** 340–45.

22 Oh J, Conlan S, Polley EC, Segre JA, Kong HH. Shifts in human skin and nares microbiota of healthy children and adults. *Genome Med* 2012; **4:** 77.

23 Kong HH, Oh J, Deming C, et al, and the NISC Comparative Sequence Program. Temporal shifts in the skin microbiome associated with disease flares and treatment in children with atopic dermatitis. *Genome Res* 2012; **22:** 850–59.

24 Beck LA, Boguniewicz M, Hata T, et al. Phenotype of atopic dermatitis subjects with a history of eczema herpeticum. *J Allergy Clin Immunol* 2009; **124:** 260–69, e7.

25 Chen X, Anstey AV, Bugert JJ. Molluscum contagiosum virus infection. *Lancet Infect Dis* 2013; **13:** 877–88.

26 Darabi K, Hostetler SG, Bechtel MA, Zirwas M. The role of Malassezia in atopic dermatitis affecting the head and neck of adults. *J Am Acad Dermatol* 2009; **60:** 125–36.

27 Heine G, Schnuch A, Uter W, Worm M, and the Information Network of Departments of Dermatology (IVDK), the German Contact Dermatitis Research Group (DKG). Type-IV sensitization profile of individuals with atopic eczema: results from the Information Network of Departments of Dermatology (IVDK) and the German Contact Dermatitis Research Group (DKG). *Allergy* 2006; **61:** 611–16.

28 Beattie PE, Lewis-Jones MS. A comparative study of impairment of quality of life in children with skin disease and children with other chronic childhood diseases. *Br J Dermatol* 2006; **155:** 145–51.

29 Schmitt J, Buske-Kirschbaum A, Roessner V. Is atopic disease a risk factor for attention-deficit/hyperactivity disorder? A systematic review. *Allergy* 2010; **65:** 1506–24.

30 Yaghmaie P, Koudelka CW, Simpson EL. Mental health comorbidity in patients with atopic dermatitis. *J Allergy Clin Immunol* 2013; **131:** 428–33.

31 Dalgard FJ, Gieler U, Tomas-Aragones L, et al. The psychological burden of skin diseases: a cross-sectional multicenter study among dermatological out-patients in 13 European countries. *J Invest Dermatol* 2015; **135:** 984–91.

32 van der Hulst AE, Klip H, Brand PL. Risk of developing asthma in young children with atopic eczema: a systematic review. *J Allergy Clin Immunol* 2007; **120:** 565–69.

33 Belgrave DC, Granell R, Simpson A, et al. Developmental profiles of eczema, wheeze, and rhinitis: two population-based birth cohort studies. *PLoS Med* 2014; **11:** e1001748.

34 Pinart M, Benet M, Annesi-Maesano I, et al. Comorbidity of eczema, rhinitis, and asthma in IgE-sensitised and non-IgE-sensitised children in MeDALL: a population-based cohort study. *Lancet Respir Med* 2014; **2:** 131–40.

35 Schmitt J, Schwarz K, Baurecht H, et al. Atopic dermatitis is associated with an increased risk for rheumatoid arthritis and inflammatory bowel disease, and a decreased risk for type-1 diabetes. *J Allergy Clin Immunol* 2015; published online Aug 4. DOI:10.1016/j.jaci.2015.06.029.

36 Mohan GC, Silverberg JI. Association of vitiligo and alopecia areata with atopic dermatitis: a systematic review and meta-analysis. *JAMA Dermatol* 2015; **151:** 522–28.

37 Deckert S, Kopkow C, Schmitt J. Nonallergic comorbidities of atopic eczema: an overview of systematic reviews. *Allergy* 2014; **69:** 37–45.

38 Murray CJ, Vos T, Lozano R, et al. Disability-adjusted life years (DALYs) for 291 diseases and injuries in 21 regions, 1990–2010: a systematic analysis for the Global Burden of Disease Study 2010. *Lancet* 2012; **380:** 2197–223.

39 Vos T, Flaxman AD, Naghavi M, et al. years lived with disability (YLDs) for 1160 sequelae of 289 diseases and injuries 1990–2010: a systematic analysis for the Global Burden of Disease Study 2010. *Lancet* 2012; **380:** 2163–96.

40 Mancini AJ, Kaulback K, Chamlin SL. The socioeconomic impact of atopic dermatitis in the United States: a systematic review. *Pediatr Dermatol* 2008; **25:** 1–6.

41 Ricci G, Bendandi B, Pagliara L, Patrizi A, Masi M. Atopic dermatitis in Italian children: evaluation of its economic impact. *J Pediatr Health Care* 2006; **20:** 311–15.

42 Suh DC, Sung J, Gause D, Raut M, Huang J, Choi IS. Economic burden of atopic manifestations in patients with atopic dermatitis—analysis of administrative claims. *J Manag Care Pharm* 2007; **13:** 778–89.

43 Apfelbacher CJ, Diepgen TL, Schmitt J. Determinants of eczema: population-based cross-sectional study in Germany. *Allergy* 2011; **66:** 206–13.

44 Thomsen SF, Ulrik CS, Kyvik KO, et al. Importance of genetic factors in the etiology of atopic dermatitis: a twin study. *Allergy Asthma Proc* 2007; **28:** 535–39.

45 Ellinghaus D, Baurecht H, Esparza-Gordillo J, et al. High-density genotyping study identifies four new susceptibility loci for atopic dermatitis. *Nat Genet* 2013; **45:** 808–12.

46 Esparza-Gordillo J, Weidinger S, Fölster-Holst R, et al. A common variant on chromosome 11q13 is associated with atopic dermatitis. *Nat Genet* 2009; **41:** 596–601.

47 Paternoster L, Standl M, Chen CM, et al, and the Australian Asthma Genetics Consortium (AAGC), the Genetics of Overweight Young Adults (GOYA) Consortium, the EArly Genetics & Lifecourse Epidemiology (EAGLE) Consortium. Meta-analysis of genome-wide association studies identifies three new risk loci for atopic dermatitis. *Nat Genet* 2012; **44:** 187–92.

48 Sun LD, Xiao FL, Li Y, et al. Genome-wide association study identifies two new susceptibility loci for atopic dermatitis in the Chinese Han population. *Nat Genet* 2011; **43:** 690–94.

49 Hirota T, Takahashi A, Kubo M, et al. Genome-wide association study identifies eight new susceptibility loci for atopic dermatitis in the Japanese population. *Nat Genet* 2012; **44:** 1222–26.

50 Paternoster L, Standl M, Waage J, et al. Multi-ethnic genome-wide association study of 21,000 cases and 95,000 controls identifies new risk loci for atopic dermatitis. *Nat Genet* (in press).

51 Irvine AD, McLean WH, Leung DY. Filaggrin mutations associated with skin and allergic diseases. *N Engl J Med* 2011; **365:** 1315–27.

52 Flohr C, Mann J. New insights into the epidemiology of childhood atopic dermatitis. *Allergy* 2014; **69:** 3–16.

53 Flohr C, Yeo L. Atopic dermatitis and the hygiene hypothesis revisited. *Curr Probl Dermatol* 2011; **41:** 1–34.

54 Kezic S, Novak N, Jakasa I, et al. Skin barrier in atopic dermatitis. *Front Biosci* 2014; **19:** 542–56.

55 Flohr C, England K, Radulovic S, et al. Filaggrin loss-of-function mutations are associated with early-onset eczema, eczema severity and transepidermal water loss at 3 months of age. *Br J Dermatol* 2010; **163:** 1333–36.

56 Jungersted JM, Scheer H, Mempel M, et al. Stratum corneum lipids, skin barrier function and filaggrin mutations in patients with atopic eczema. *Allergy* 2010; **65:** 911–18.

57 Ishikawa J, Narita H, Kondo N, et al. Changes in the ceramide profile of atopic dermatitis patients. *J Invest Dermatol* 2010; **130:** 2511–14.

58 Janssens M, van Smeden J, Gooris GS, et al. Increase in short-chain ceramides correlates with an altered lipid organization and decreased barrier function in atopic eczema patients. *J Lipid Res* 2012; **53:** 2755–66.

59 Voegeli R, Rawlings AV, Breternitz M, Doppler S, Schreier T, Fluhr JW. Increased stratum corneum serine protease activity in acute eczematous atopic skin. *Br J Dermatol* 2009; **161:** 70–77.

60 Samuelov L, Sprecher E. Peeling off the genetics of atopic dermatitis-like congenital disorders. *J Allergy Clin Immunol* 2014; **134:** 808–15.

61 Thyssen JP, Kezic S. Causes of epidermal filaggrin reduction and their role in the pathogenesis of atopic dermatitis. *J Allergy Clin Immunol* 2014; **134:** 792–99.

62 Pendaries V, Malaisse J, Pellerin L, et al. Knockdown of filaggrin in a three-dimensional reconstructed human epidermis impairs keratinocyte differentiation. *J Invest Dermatol* 2014; **134:** 2938–46.

63 Gruber R, Elias PM, Crumrine D, et al. Filaggrin genotype in ichthyosis vulgaris predicts abnormalities in epidermal structure and function. *Am J Pathol* 2011; **178:** 2252–63.

64 Vávrová K, Henkes D, Strüver K, et al. Filaggrin deficiency leads to impaired lipid profile and altered acidification pathways in a 3D skin construct. *J Invest Dermatol* 2014; **134:** 746–53.

65 Gao PS, Rafaels NM, Hand T, et al. Filaggrin mutations that confer risk of atopic dermatitis confer greater risk for eczema herpeticum. *J Allergy Clin Immunol* 2009; **124:** 507–13, e7.

66 Miajlovic H, Fallon PG, Irvine AD, Foster TJ. Effect of filaggrin breakdown products on growth of and protein expression by *Staphylococcus aureus*. *J Allergy Clin Immunol* 2010; **126:** 1184–90, e3.

67 Scharschmidt TC, Man MQ, Hatano Y, et al. Filaggrin deficiency confers a paracellular barrier abnormality that reduces inflammatory thresholds to irritants and haptens. *J Allergy Clin Immunol* 2009; **124:** 496–506, e6.

68 Kawasaki H, Nagao K, Kubo A, et al. Altered stratum corneum barrier and enhanced percutaneous immune responses in filaggrin-null mice. *J Allergy Clin Immunol* 2012; **129:** 1538–46, e6.

69 Kezic S, O'Regan GM, Lutter R, et al. Filaggrin loss-of-function mutations are associated with enhanced expression of IL-1 cytokines in the stratum corneum of patients with atopic dermatitis and in a murine model of filaggrin deficiency. *J Allergy Clin Immunol* 2012; **129:** 1031–39, e1.

70 Mildner M, Jin J, Eckhart L, et al. Knockdown of filaggrin impairs diffusion barrier function and increases UV sensitivity in a human skin model. *J Invest Dermatol* 2010; **130:** 2286–94.

71 Fallon PG, Sasaki T, Sandilands A, et al. A homozygous frameshift mutation in the mouse *Flg* gene facilitates enhanced percutaneous allergen priming. *Nat Genet* 2009; **41:** 602–08.

72 Suarez-Farinas M, Tintle SJ, Shemer A, et al. Nonlesional atopic dermatitis skin is characterized by broad terminal differentiation defects and variable immune abnormalities. *J Allergy Clin Immunol* 2011; **127:** 954–64, e4.

73 Islam SA, Luster AD. T cell homing to epithelial barriers in allergic disease. *Nat Med* 2012; **18:** 705–15.

74 Imai Y, Yasuda K, Sakaguchi Y, et al. Skin-specific expression of IL-33 activates group 2 innate lymphoid cells and elicits atopic dermatitis-like inflammation in mice. *Proc Natl Acad Sci USA* 2013; **110:** 13921–26.

75 Salimi M, Barlow JL, Saunders SP, et al. A role for IL-25 and IL-33-driven type-2 innate lymphoid cells in atopic dermatitis. *J Exp Med* 2013; **210:** 2939–50.

76 Tominaga M, Takamori K. Itch and nerve fibers with special reference to atopic dermatitis: therapeutic implications. *J Dermatol* 2014; **41:** 205–12.

77 Stutte S, Quast T, Gerbitzki N, et al. Requirement of CCL17 for CCR7- and CXCR4-dependent migration of cutaneous dendritic cells. *Proc Natl Acad Sci USA* 2010; **107:** 8736–41.

78 Gittler JK, Shemer A, Suárez-Fariñas M, et al. Progressive activation of T_H2/T_H22 cytokines and selective epidermal proteins characterizes acute and chronic atopic dermatitis. *J Allergy Clin Immunol* 2012; **130:** 1344–54.

79 Nograles KE, Zaba LC, Shemer A, et al. IL-22-producing "T22" T cells account for upregulated IL-22 in atopic dermatitis despite reduced IL-17-producing TH17 T cells. *J Allergy Clin Immunol* 2009; **123:** 1244–52, e2.

80 Ziegler SF. Thymic stromal lymphopoietin and allergic disease. *J Allergy Clin Immunol* 2012; **130:** 845–52.

81 Eyerich S, Eyerich K, Pennino D, et al. Th22 cells represent a distinct human T cell subset involved in epidermal immunity and remodeling. *J Clin Invest* 2009; **119:** 3573–85.

82 Simon D, Aeberhard C, Erdemoglu Y, Simon HU. Th17 cells and tissue remodeling in atopic and contact dermatitis. *Allergy* 2014; **69:** 125–31.

83 Leyva-Castillo JM, Hener P, Michea P, et al. Skin thymic stromal lymphopoietin initiates Th2 responses through an orchestrated immune cascade. *Nat Commun* 2013; **4:** 2847.

84 Khattri S, Shemer A, Rozenblit M, et al. Cyclosporine in patients with atopic dermatitis modulates activated inflammatory pathways and reverses epidermal pathology. *J Allergy Clin Immunol* 2014; **133:** 1626–34.

85 Novak N. An update on the role of human dendritic cells in patients with atopic dermatitis. *J Allergy Clin Immunol* 2012; **129:** 879–86.

86 Zeller S, Rhyner C, Meyer N, Schmid-Grendelmeier P, Akdis CA, Crameri R. Exploring the repertoire of IgE-binding self-antigens associated with atopic eczema. *J Allergy Clin Immunol* 2009; **124:** 278–85, e7.

87 Tang TS, Bieber T, Williams HC. Does "autoreactivity" play a role in atopic dermatitis? *J Allergy Clin Immunol* 2012; **129:** 1209–15, e2.

88 Heratizadeh A, Mittermann I, Balaji H, et al. The role of T-cell reactivity towards the autoantigen α-NAC in atopic dermatitis. *Br J Dermatol* 2011; **164:** 316–24.

89 Balaji H, Heratizadeh A, Wichmann K, et al. Malassezia sympodialis thioredoxin-specific T cells are highly cross-reactive to human thioredoxin in atopic dermatitis. *J Allergy Clin Immunol* 2011; **128:** 92–99, e4.

90 Homey B, Steinhoff M, Ruzicka T, Leung DY. Cytokines and chemokines orchestrate atopic skin inflammation. *J Allergy Clin Immunol* 2006; **118:** 178–89.

91 Hvid M, Vestergaard C, Kemp K, Christensen GB, Deleuran B, Deleuran M. IL-25 in atopic dermatitis: a possible link between inflammation and skin barrier dysfunction? *J Invest Dermatol* 2011; **131:** 150–57.

92 Savinko T, Matikainen S, Saarialho-Kere U, et al. IL-33 and ST2 in atopic dermatitis: expression profiles and modulation by triggering factors. *J Invest Dermatol* 2012; **132:** 1392–400.

93 Oyoshi MK, Larson RP, Ziegler SF, Geha RS. Mechanical injury polarizes skin dendritic cells to elicit a T_H2 response by inducing cutaneous thymic stromal lymphopoietin expression. *J Allergy Clin Immunol* 2010; **126:** 976–84, e5.

94 Brough HA, Liu AH, Sicherer S, et al. Atopic dermatitis increases the effect of exposure to peanut antigen in dust on peanut sensitization and likely peanut allergy. *J Allergy Clin Immunol* 2015; **135:** 164–70.

95 Bartnikas LM, Gurish MF, Burton OT, et al. Epicutaneous sensitization results in IgE-dependent intestinal mast cell expansion and food-induced anaphylaxis. *J Allergy Clin Immunol* 2013; **131:** 451–60, e6.

96 Kopfnagel V, Harder J, Werfel T. Expression of antimicrobial peptides in atopic dermatitis and possible immunoregulatory functions. *Curr Opin Allergy Clin Immunol* 2013; **13:** 531–36.

97 van Drongelen V, Haisma EM, Out-Luiting JJ, Nibbering PH, El Ghalbzouri A. Reduced filaggrin expression is accompanied by increased *Staphylococcus aureus* colonization of epidermal skin models. *Clin Exp Allergy* 2014; **44:** 1515–24.

98 Hirasawa Y, Takai T, Nakamura T, et al. *Staphylococcus aureus* extracellular protease causes epidermal barrier dysfunction. *J Invest Dermatol* 2010; **130:** 614–17.

99 Takeuchi O, Akira S. Pattern recognition receptors and inflammation. *Cell* 2010; **140:** 805–20.

100 Ganem MB, De Marzi MC, Fernández-Lynch MJ, et al. Uptake and intracellular trafficking of superantigens in dendritic cells. *PLoS One* 2013; **8:** e66244.

101 Nakamura Y, Oscherwitz J, Cease KB, et al. *Staphylococcus* δ-toxin induces allergic skin disease by activating mast cells. *Nature* 2013; **503:** 397–401.

102 Bin L, Edwards MG, Heiser R, et al. Identification of novel gene signatures in patients with atopic dermatitis complicated by eczema herpeticum. *J Allergy Clin Immunol* 2014; **134:** 848–55.

103 Leung DY, Gao PS, Grigoryev DN, et al. Human atopic dermatitis complicated by eczema herpeticum is associated with abnormalities in IFN-γ response. *J Allergy Clin Immunol* 2011; **127:** 965–73, e5.

104 Cornelissen C, Marquardt Y, Czaja K, et al. IL-31 regulates differentiation and filaggrin expression in human organotypic skin models. *J Allergy Clin Immunol* 2012; **129:** 426–33, e8.

105 Batista DI, Perez L, Orfali RL, et al. Profile of skin barrier proteins (filaggrin, claudins 1 and 4) and Th1/Th2/Th17 cytokines in adults with atopic dermatitis. *J Eur Acad Dermatol Venereol* 2015; **29:** 1091–95.

106 Omori-Miyake M, Yamashita M, Tsunemi Y, Kawashima M, Yagi J. In vitro assessment of IL-4- or IL-13-mediated changes in the structural components of keratinocytes in mice and humans. *J Invest Dermatol* 2014; **134:** 1342–50.

107 De Benedetto A, Rafaels NM, McGirt LY, et al. Tight junction defects in patients with atopic dermatitis. *J Allergy Clin Immunol* 2011; **127:** 773–86, e7.

108 Morizane S, Yamasaki K, Kajita A, et al. TH2 cytokines increase kallikrein 7 expression and function in patients with atopic dermatitis. *J Allergy Clin Immunol* 2012; **130:** 259–61, e1.

109 Danso MO, van Drongelen V, Mulder A, et al. TNF-α and Th2 cytokines induce atopic dermatitis-like features on epidermal differentiation proteins and stratum corneum lipids in human skin equivalents. *J Invest Dermatol* 2014; **134:** 1941–50.

110 Buddenkotte J, Steinhoff M. Pathophysiology and therapy of pruritus in allergic and atopic diseases. *Allergy* 2010; **65:** 805–21.

111 Oh MH, Oh SY, Lu J, et al. TRPA1-dependent pruritus in IL-13-induced chronic atopic dermatitis. *J Immunol* 2013; **191:** 5371–82.

112 Cevikbas F, Wang X, Akiyama T, et al. A sensory neuron-expressed IL-31 receptor mediates T helper cell-dependent itch: involvement of TRPV1 and TRPA1. *J Allergy Clin Immunol* 2014; **133:** 448–60.

113 Roggenkamp D, Köpnick S, Stäb F, Wenck H, Schmelz M, Neufang G. Epidermal nerve fibers modulate keratinocyte growth via neuropeptide signaling in an innervated skin model. *J Invest Dermatol* 2013; **133:** 1620–28.

114 Aubert-Wastiaux H, Moret L, Le Rhun A, et al. Topical corticosteroid phobia in atopic dermatitis: a study of its nature, origins and frequency. *Br J Dermatol* 2011; **165:** 808–14.

115 Ersser SJ, Cowdell F, Latter S, et al. Psychological and educational interventions for atopic eczema in children. *Cochrane Database Syst Rev* 2014; **1:** CD004054.

116 Ng JP, Liew HM, Ang SB. Use of emollients in atopic dermatitis. *J Eur Acad Dermatol Venereol* 2015; **29:** 854–57.

117 Langan SM, Silcocks P, Williams HC. What causes flares of eczema in children? *Br J Dermatol* 2009; **161:** 640–46.

118 Langan SM, Williams HC. What causes worsening of eczema? A systematic review. *Br J Dermatol* 2006; **155:** 504–14.

119 Langan SM, Flohr C, Williams HC. The role of furry pets in eczema: a systematic review. *Arch Dermatol* 2007; **143:** 1570–77.

120 Nankervis H, Pynn EV, Boyle RJ, et al. House dust mite reduction and avoidance measures for treating eczema. *Cochrane Database Syst Rev* 2015; **1:** CD008426.

121 Bath-Hextall F, Delamere FM, Williams HC. Dietary exclusions for improving established atopic eczema in adults and children: systematic review. *Allergy* 2009; **64:** 258–64.

122 Hoare C, Li Wan Po A, Williams H. Systematic review of treatments for atopic eczema. *Health Technol Assess* 2000; **4:** 1–191.

123 Castela E, Archier E, Devaux S, et al. Topical corticosteroids in plaque psoriasis: a systematic review of risk of adrenal axis suppression and skin atrophy. *J Eur Acad Dermatol Venereol* 2012; **26** (suppl 3): 47–51.

124 Green C, Colquitt JL, Kirby J, Davidson P, Payne E. Clinical and cost-effectiveness of once-daily versus more frequent use of same potency topical corticosteroids for atopic eczema: a systematic review and economic evaluation. *Health Technol Assess* 2004; **8:** iii,iv, 1–120.

125 Janmohamed SR, Oranje AP, Devillers AC, et al. The proactive wet-wrap method with diluted corticosteroids versus emollients in children with atopic dermatitis: a prospective, randomized, double-blind, placebo-controlled trial. *J Am Acad Dermatol* 2014; **70:** 1076–82.

126 Ashcroft DM, Dimmock P, Garside R, Stein K, Williams HC. Efficacy and tolerability of topical pimecrolimus and tacrolimus in the treatment of atopic dermatitis: meta-analysis of randomised controlled trials. *BMJ* 2005; **330:** 516.

127 Chen SL, Yan J, Wang FS. Two topical calcineurin inhibitors for the treatment of atopic dermatitis in pediatric patients: a meta-analysis of randomized clinical trials. *J Dermatolog Treat* 2010; **21:** 144–56.

128 Aschoff R, Schmitt J, Knuschke P, Koch E, Bräutigam M, Meurer M. Evaluation of the atrophogenic potential of hydrocortisone 1% cream and pimecrolimus 1% cream in uninvolved forehead skin of patients with atopic dermatitis using optical coherence tomography. *Exp Dermatol* 2011; **20:** 832–36.

129 Shlivko IL, Kamensky VA, Donchenko EV, Agrba P. Morphological changes in skin of different phototypes under the action of topical corticosteroid therapy and tacrolimus. *Skin Res Technol* 2014; **20:** 136–40.

130 Sigurgeirsson B, Boznanski A, Todd G, et al. Safety and efficacy of pimecrolimus in atopic dermatitis: a 5-year randomized trial. *Pediatrics* 2015; **135:** 597–606.

131 Schmitt J, von Kobyletzki L, Svensson A, Apfelbacher C. Efficacy and tolerability of proactive treatment with topical corticosteroids and calcineurin inhibitors for atopic eczema: systematic review and meta-analysis of randomized controlled trials. *Br J Dermatol* 2011; **164:** 415–28.

132 Garritsen FM, Brouwer MW, Limpens J, Spuls PI. Photo(chemo) therapy in the management of atopic dermatitis: an updated systematic review with implications for practice and research. *Br J Dermatol* 2014; **170:** 501–13.

133 Roekevisch E, Spuls PI, Kuester D, Limpens J, Schmitt J. Efficacy and safety of systemic treatments for moderate-to-severe atopic dermatitis: a systematic review. *J Allergy Clin Immunol* 2014; **133:** 429–38.

134 Schmitt J, Schmitt N, Meurer M. Cyclosporin in the treatment of patients with atopic eczema—a systematic review and meta-analysis. *J Eur Acad Dermatol Venereol* 2007; **21:** 606–19.

135 Haeck IM, Knol MJ, Ten Berge O, van Velsen SG, de Bruin-Weller MS, Bruijnzeel-Koomen CA. Enteric-coated mycophenolate sodium versus cyclosporin A as long-term treatment in adult patients with severe atopic dermatitis: a randomized controlled trial. *J Am Acad Dermatol* 2011; **64:** 1074–84.

136 Schram ME, Roekevisch E, Leeflang MM, Bos JD, Schmitt J, Spuls PI. A randomized trial of methotrexate versus azathioprine for severe atopic eczema. *J Allergy Clin Immunol* 2011; **128:** 353–59.

137 Fuggle NR, Bragoli W, Mahto A, Glover M, Martinez AE, Kinsler VA. The adverse effect profile of oral azathioprine in pediatric atopic dermatitis, and recommendations for monitoring. *J Am Acad Dermatol* 2015; **72:** 108–14.

138 El-Khalawany MA, Hassan H, Shaaban D, Ghonaim N, Eassa B. Methotrexate versus cyclosporine in the treatment of severe atopic dermatitis in children: a multicenter experience from Egypt. *Eur J Pediatr* 2013; **172:** 351–56.

139 Bath-Hextall FJ, Birnie AJ, Ravenscroft JC, Williams HC. Interventions to reduce *Staphylococcus aureus* in the management of atopic eczema: an updated Cochrane review. *Br J Dermatol* 2010; **163:** 12–26.

140 Travers JB, Kozman A, Yao Y, et al. Treatment outcomes of secondarily impetiginized pediatric atopic dermatitis lesions and the role of oral antibiotics. *Pediatr Dermatol* 2012; **29:** 289–96.

141 Kaffenberger BH, Mathis J, Zirwas MJ. A retrospective descriptive study of oral azole antifungal agents in patients with patch test-negative head and neck predominant atopic dermatitis. *J Am Acad Dermatol* 2014; **71:** 480–83.

142 van Zuuren EJ, Apfelbacher CJ, Fedorowicz Z, Jupiter A, Matterne U, Weisshaar E. No high level evidence to support the use of oral H1 antihistamines as monotherapy for eczema: a summary of a Cochrane systematic review. *Syst Rev* 2014; **3:** 25.

143 Boyle RJ, Bath-Hextall FJ, Leonardi-Bee J, Murrell DF, Tang ML. Probiotics for treating eczema. *Cochrane Database Syst Rev* 2008; **4:** CD006135.

144 Bath-Hextall FJ, Jenkinson C, Humphreys R, Williams Hywel C. Dietary supplements for established atopic eczema. *Cochrane Database Syst Rev* 2012; **2:** CD005205.

145 Reuter J, Merfort I, Schempp CM. Botanicals in dermatology: an evidence-based review. *Am J Clin Dermatol* 2010; **11:** 247–67.

146 Simonart T, Kabagabo C, De Maertelaer V. Homoeopathic remedies in dermatology: a systematic review of controlled clinical trials. *Br J Dermatol* 2011; **165:** 897–905.

147 Lopes C, Silva D, Delgado L, Correia O, Moreira A. Functional textiles for atopic dermatitis: a systematic review and meta-analysis. *Pediatr Allergy Immunol* 2013; **24:** 603–13.

148 Bae JM, Choi YY, Park CO, Chung KY, Lee KH. Efficacy of allergen-specific immunotherapy for atopic dermatitis: a systematic review and meta-analysis of randomized controlled trials. *J Allergy Clin Immunol* 2013; **132:** 110–17.

149 Otsuka A, Doi H, Egawa G, et al. Possible new therapeutic strategy to regulate atopic dermatitis through upregulating filaggrin expression. *J Allergy Clin Immunol* 2014; **133:** 139–46, e10.

150 Stout TE, McFarland T, Mitchell JC, Appukuttan B, Stout JT. Recombinant filaggrin is internalized and processed to correct filaggrin deficiency. *J Invest Dermatol* 2014; **134:** 423–29.

151 Beck LA, Thaçi D, Hamilton JD, et al. Dupilumab treatment in adults with moderate-to-severe atopic dermatitis. *N Engl J Med* 2014; **371:** 130–39.

152 Simpson EL, Keck LE, Chalmers JR, Williams HC. How should an incident case of atopic dermatitis be defined? A systematic review of primary prevention studies. *J Allergy Clin Immunol* 2012; **130:** 137–44.

153 Foisy M, Boyle RJ, Chalmers JR, Simpson EL, Williams HC. The prevention of eczema in infants and children: an overview of Cochrane and non-Cochrane reviews. *Evid Based Child Health* 2011; **6:** 1322–39.

154 Zutavern A, Brockow I, Schaaf B, et al, and the LISA Study Group. Timing of solid food introduction in relation to eczema, asthma, allergic rhinitis, and food and inhalant sensitization at the age of 6 years: results from the prospective birth cohort study LISA. *Pediatrics* 2008; **121:** e44–52.

155 Simpson EL, Berry TM, Brown PA, Hanifin JM. A pilot study of emollient therapy for the primary prevention of atopic dermatitis. *J Am Acad Dermatol* 2010; **63:** 587–93.

156 Horimukai K, Morita K, Narita M, et al. Application of moisturizer to neonates prevents development of atopic dermatitis. *J Allergy Clin Immunol* 2014; **134:** 824–30, e6.

157 Simpson EL, Chalmers JR, Hanifin JM, et al. Emollient enhancement of the skin barrier from birth offers effective atopic dermatitis prevention. *J Allergy Clin Immunol* 2014; **134:** 818–23.

THE LANCET

Supplementary appendix

This appendix formed part of the original submission and has been peer reviewed. We post it as supplied by the authors.

Supplement to: Weidinger S, Novak N. Atopic dermatitis. *Lancet* 2015; published online Sept 14. http://dx.doi.org/10.1016/S0140-6736(15)00149-X.

Recent atopic dermatitis guidelines

Recent atopic dermatitis guidelines include those from the European Academy of Dermatology and Venereology,[1, 2] the American Academy of Dermatology,[3-5] the Japanese Society of Allergology,[6] the Latin American Society of Allergy, Asthma and Immunology,[7] and the Asia-Pacific Consensus Group for Atopic Dermatitis.[8]

Webfigure 1: Most plausible candidate genes in susceptibility loci identified through genome-wide association studies.

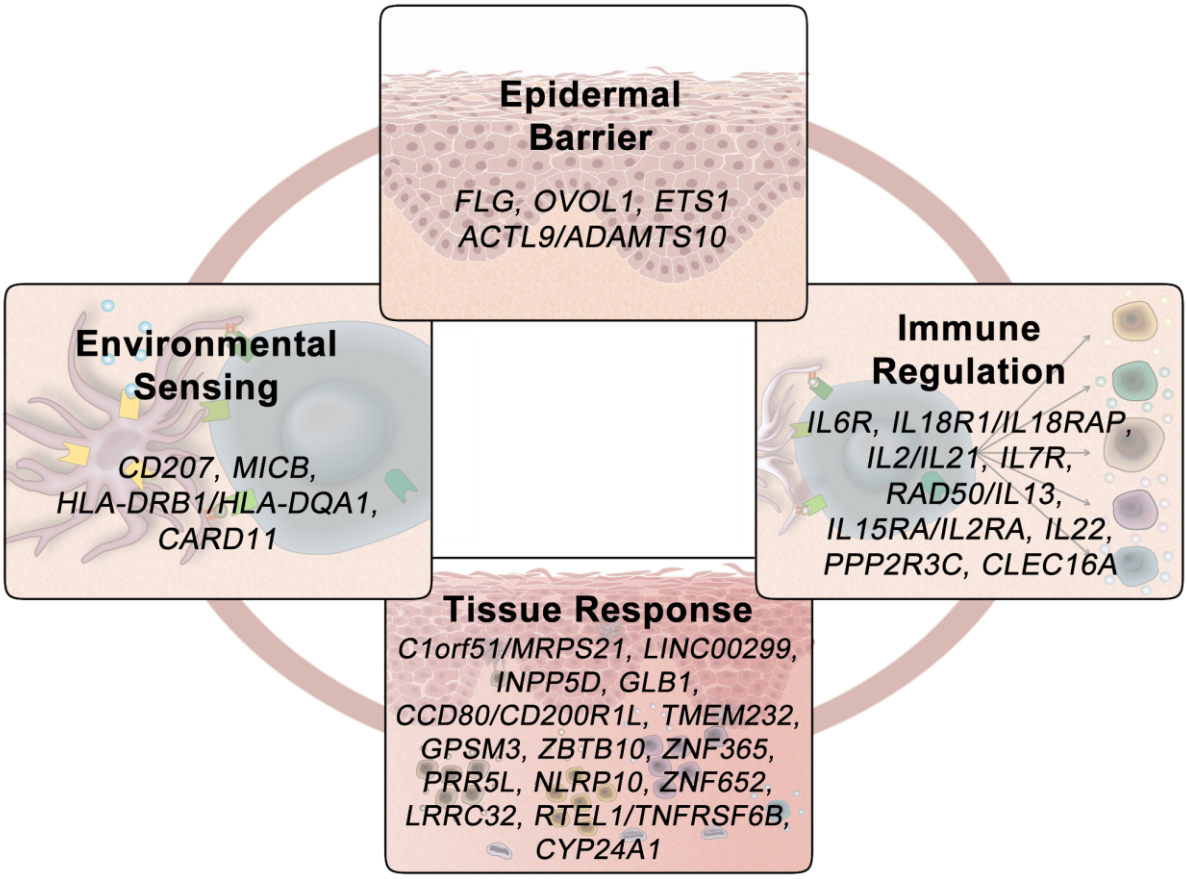

Webfigure 2: Conceptual diagram of the two major mechanisms of atopic dermatitis

Epidermal barrier impairment and chronic inflammation are based on an inherited susceptibility, triggered by environmental factors, and driven by cascades of pathophysiologic events; the intensity and relative importance may differ between patients and over time.

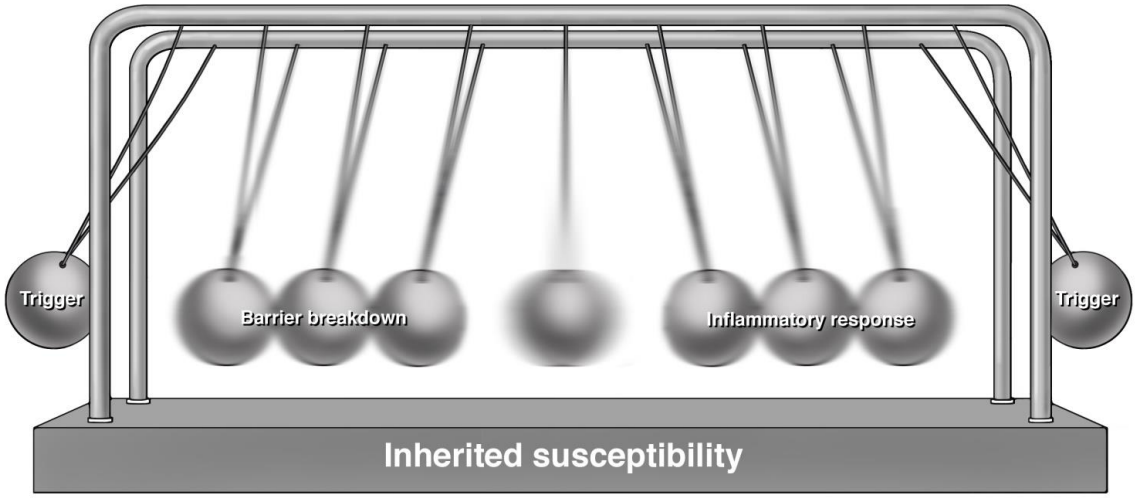

Webfigure 3: Key steps of atopic dermatitis management

The stepwise approach (step up/step down according to severity) is meant to assist, not to replace the clinical decision made to meet individual patient needs.

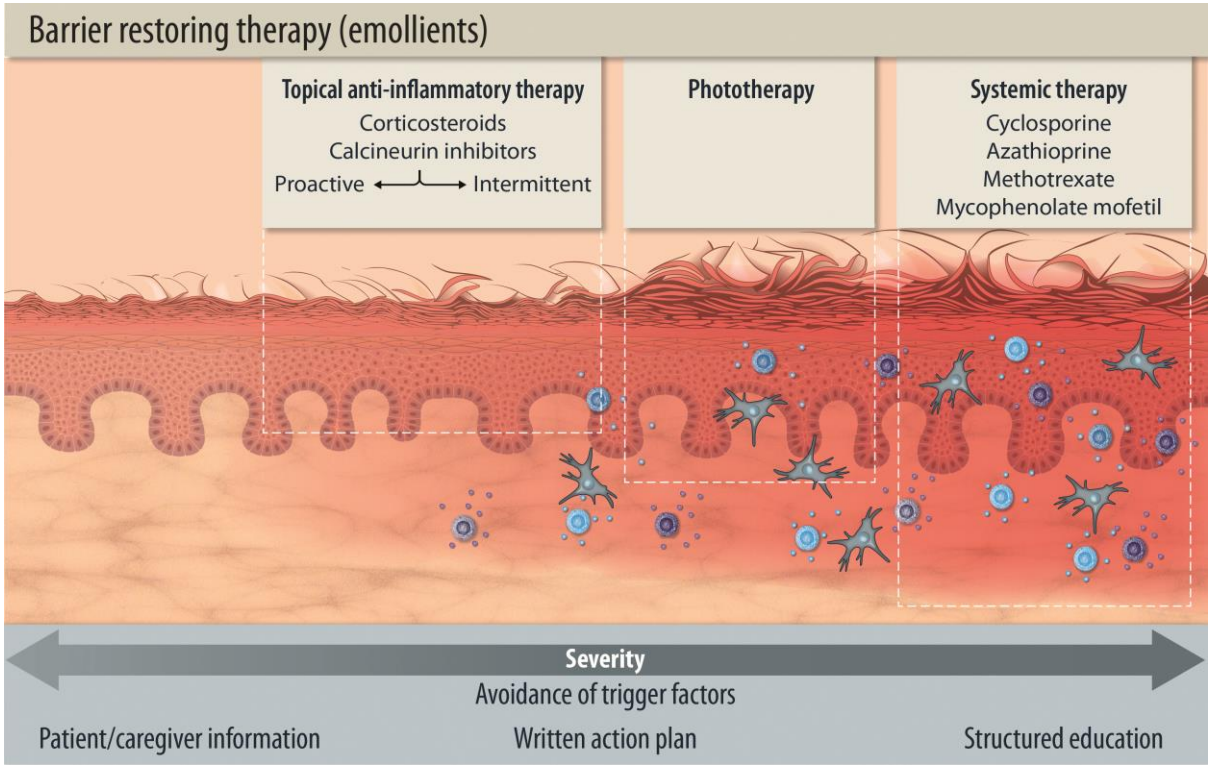

Webpanel 1: Simplified diagnostic criteria for atopic dermatitis in the clinical setting.[10]

Essential features (must be present)
Pruritus
Eczema (acute, subacute, chronic)
Typical morphology and age specific patterns*
Chronic or relapsing history
*1. Facial, neck and extensor involvement in infants or children
*2. Current or previous flexural lesions in any age-group
*3. Sparing of the groin and axillary regions
Important features (in most cases present, support diagnosis)
Early age of onset
Atopy
- personal and/or family history
- Immunglobulin E hyperreactivity
Xerosis
Associated features (help to detect the diagnosis but too nonspecific to defining it)
Atypical vascular response (i.e. facial pallor, white dermographism, delayed blanch response)
Keratosis pilaris, pityriasis alba, hyperlinear palms, ichthyosis
Ocular/periorbital changes
Other regional changes (perioral changes, periauricular lesions)
Perifollicular accentuation, lichenification, prurigo lesions

Webtable 1: Novel systemic therapeutics currently investigated in clinical studies (source: ClinicalTrials.gov website of the U.S. National Institute of Health, accessed 03/01/2015).

Substance	Phase	Mechanism
Th2 pathway/IgE		
REGN668 (Dupilumab)	III / NCT01949311	binds to the common alpha-chain of the IL-4/13 receptor, antagonizes IL-4 and IL-13
Aeroderm/Pitrakinra	II / NCT00676884	binds to the common alpha-chain of the IL-4/13 receptor, antagonizes IL-4 and IL-13
Tralokinumab	II / NCT02347176	antibody which targets IL-13
Lebrikizumab	II / NCT02340234	antibody which blocks IL-13
QAW039	II / NCT01785602	antagonist of CRTH2 (DP2), a chemokine receptor expressed by Th2 cells
OC000459	II / NCT02002208	antagonist of CRTH2 (DP2), a chemokine receptor expressed by Th2 cells
QGE031 (Ligelizumab)	II / NCT01552629	antibody to IgE, binds IgE, blocks IgE binding to high affinity receptor for IgE
IGEIAAD	II / NCT02365246	IgE-specific immunoadsorption
MEDI-4212	I / NCT01544348	antibody to IgE, blocks IgE binding to high and low affinity receptor for IgE
AMG157	I / NCT00757042	binds to the TSLP-receptor, activation promotes Th2 cell responses
Pruritus/mast cells/nervous system		
ASB17061	II / NCT01756898	mast cell chymase inhibitor
BMS-981164	I / NCT01614756	anti-IL-31 antibody, neutralizes IL-31
CIM331	II / NCT01986933	anti-IL-31 receptor antibody, inhibits IL-31 receptor binding
DNK333	II / NCT01033097	neurokinin (NK) 1/2 receptor antagonist
VLY-686	II / NCT02004041	neurokinin (NK) 1 receptor antagonist
S-777469	II / NCT00703573	agonist to the CB2 cannabinoid receptor
Th22/Th17 pathway		
ILV-094 (Fezakinumab)	II / NCT01941537	anti-IL-22 antibody, neutralizes IL-22
Ustekinumab	II/NCT01806662	Anti-IL23 antibody, neutralizes IL-23
Others		
Apremilast	II / NCT02087943	PDE4 inhibitor, inhibits phosphodiesterase 4
AQX-1123	II / NCT02324972	targets the Ship1 pathway
Furestem-AD	I/II / NCT01927705	mesenchymal stem cells

Appendix references

1. Ring J, Alomar A, Bieber T, Deleuran M, Fink-Wagner A, Gelmetti C, et al. Guidelines for treatment of atopic eczema (atopic dermatitis) Part II. J Eur Acad Dermatol Venereol. 2012; **26**(9): 1176-93.
2. Ring J, Alomar A, Bieber T, Deleuran M, Fink-Wagner A, Gelmetti C, et al. Guidelines for treatment of atopic eczema (atopic dermatitis) part I. J Eur Acad Dermatol Venereol. 2012; **26**(8): 1045-60.
3. Eichenfield LF, Tom WL, Berger TG, Krol A, Paller AS, Schwarzenberger K, et al. Guidelines of care for the management of atopic dermatitis: section 2. Management and treatment of atopic dermatitis with topical therapies. J Am Acad Dermatol. 2014; **71**(1): 116-32.
4. Sidbury R, Davis DM, Cohen DE, Cordoro KM, Berger TG, Bergman JN, et al. Guidelines of care for the management of atopic dermatitis: section 3. Management and treatment with phototherapy and systemic agents. J Am Acad Dermatol. 2014; **71**(2): 327-49.
5. Sidbury R, Tom WL, Bergman JN, Cooper KD, Silverman RA, Berger TG, et al. Guidelines of care for the management of atopic dermatitis: Section 4. Prevention of disease flares and use of adjunctive therapies and approaches. J Am Acad Dermatol. 2014.
6. Katayama I, Kohno Y, Akiyama K, Aihara M, Kondo N, Saeki H, et al. Japanese Guideline for Atopic Dermatitis 2014. Allergol Int. 2014; **63**(3): 377-98.
7. Sanchez J, Paez B, Macias A, Olmos C, de Falco A. Atopic dermatitis guideline. Position paper from the Latin American Society of Allergy, Asthma and Immunology. Rev Alerg Mex. 2014; **61**(3): 178-211.
8. Rubel D, Thirumoorthy T, Soebaryo RW, Weng SC, Gabriel TM, Villafuerte LL, et al. Consensus guidelines for the management of atopic dermatitis: an Asia-Pacific perspective. J Dermatol. 2013; **40**(3): 160-71.
9. Mohan GC, Lio PA. Comparison of Dermatology and Allergy Guidelines for Atopic Dermatitis Management. JAMA Dermatol. 2015.
10. Eichenfield LF, Hanifin JM, Luger TA, Stevens SR, Pride HB. Consensus conference on pediatric atopic dermatitis. J Am Acad Dermatol. 2003; **49**(6): 1088-95.