International Immunopharmacology 71 (2019) 43–51

Contents lists available at ScienceDirect

International Immunopharmacology

journal homepage: www.elsevier.com/locate/intimp

Comparison of anti-atopic dermatitis activities between DHMEQ and tacrolimus ointments in mouse model without stratum corneum

Huan He[a], Xiaoxiao Gao[a], Xiaomin Wang[a], Xin Li[a], Xiaoxue Jiang[a], Zhehui Xie[a], Ke Ma[a], Jun Ma[b], Kazuo Umezawa[c], Yuyang Zhang[a,*]

[a] School of Life Science and Biopharmaceutics, Shenyang Pharmaceutical University, Shenyang 110016, China
[b] Department of Research and Development, Shenzhen Wanhe Pharmaceutical Co., Ltd., Shenzhen 518057, China
[c] Department of Molecular Target Medicine, Aichi Medical University School of Medicine, Nagakute 480-1195, Japan

ARTICLE INFO

Keywords:
Atopic dermatitis
Tape-stripping
DHMEQ ointment
Tacrolimus ointment
BABL/C mice

ABSTRACT

This study is aimed to further investigate the anti-atopic dermatitis (AD) activities of dehydroxymethylepoxyquinomicin (DHMEQ) ointment and compare its effect with that of tacrolimus ointment based on the previous study that DHMEQ improves AD-like lesions. AD were induced by 2,4-dinitroclilorobenzene/oxazolone (DNCB/OX) repeatedly on the ears of BABL/C mice while medical tape was additionally used to disrupt stratum corneum in order to exacerbate the lesions. The mice were randomly divided into groups, which are normal, vehicle, DHMEQ (0.1%) and tacrolimus (0.1%). Those in the last two groups were externally applied with DHMEQ ointment and tacrolimus ointment, respectively. The results showed that both of them significantly improved dermatitis symptoms of DNCB/OX-induced AD-like lesions, such as redness, itching, weeping, scaling and thickening of the skin, while reducing epidermis thickness, dermis thickness and the number of mast cells as well, which were examined histopathologically. In contrast with DHMEQ, tacrolimus led to a significant decrease in body weight after long-term application. Both DHMEQ and tacrolimus suppress DNCB-induced increase of serum total IgE and attenuate expression of inflammatory factors IL-4, IL-6, IL-13, IL-1β and interferon (IFN)-γ in the disrupted ear tissues. On the other hand, the mice applied with tacrolimus became obviously irritable, jumping up and down, and inflammatory exudation on the lesioned-skin surface of the mice was remarkably observed. Contrary to the side effects made by tacrolimus, DHMEQ didn't cause any adverse stimulus response. As a conclusion, DHMEQ is safer, milder and more suitable for long-term use than tacrolimus for the treatment of AD-like lesions.

1. Introduction

AD is a chronic, allergic and inflammatory skin disease, the main symptoms of which are characterized by itching, dryness, redness, scaling and peeling of the skin [1,2]. It is currently accepted that the development of AD-like lesions is associated with skin barrier dysfunction and a skewed balance of T-helper (Th) cells in immunological system [3]. Th cell dysfunction and IgE production are considered to probably play key roles in the pathogenesis. The main changes in patients with AD may include elevated IgE level in serum, markedly increased number of inflammatory cells such as eosinophils, mast cells and lymphocytes, which are mediated by Th1 and Th2 immune responses [4]. Besides, Th2 differentiation of naïve CD4 + cell is very important in the allergic state of AD, which increases the production of inflammatory mediators, primarily IL-4, IL-5, IL-13 and the level of IgE as well [5]. IL-6 is also regarded as a proinflammatory cytokine associated with skin healing and inflammation [6] that its regulation on the inflammatory cell transmission of genes may profoundly affect the pathology of dermatitis.

Nowadays, drugs used for the therapy of AD in clinic are still scarce, yet tacrolimus, one of calcineurin inhibitors (CNIs), exhibits satisfactorily therapeutic effect on AD to some extent [7]. Mechanisms of its action are involved in decreasing expression of inflammatory cytokines by inhibiting the activation of T cells [8]. Compared with corticosteroids, the drug is a newly developed external ointment but it has a few of problems, especially those concerning safety [9]. Several studies ascribed the poor efficacy of tacrolimus for topical treatment to its high hydrophobicity and high molecular weight [10]. Hanifin et al.

* Corresponding author at: Department of Pharmacology, School of Life Science and Biopharmaceutics, Shenyang Pharmaceutical University, Shenyang 110016, China.
E-mail address: 13614053862@163.com (Y. Zhang).

https://doi.org/10.1016/j.intimp.2019.03.015
Received 15 September 2018; Received in revised form 2 March 2019; Accepted 6 March 2019
1567-5769/ © 2019 Elsevier B.V. All rights reserved.

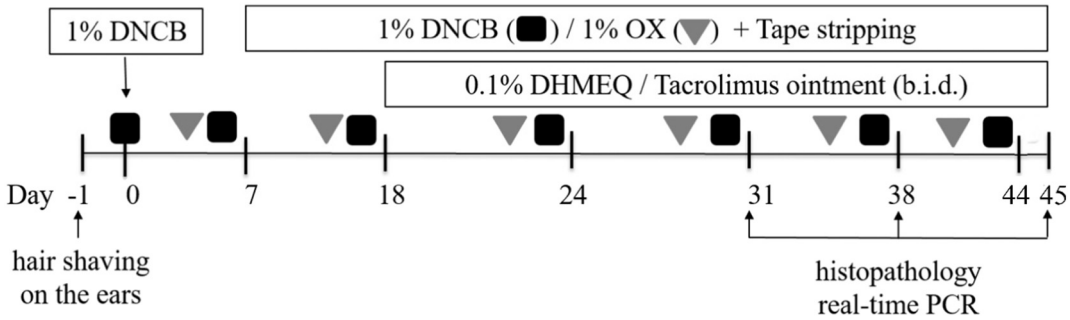

Fig. 1. Induction of stratum corneum-removed AD on mouse ears and drug treatment.

demonstrated that the most common adverse effects in the administration site are itches, skin burns and skin infections [11].

Dehydroxymethoxyquinolone (DHMEQ), firstly devised by Umezawa et al. [12], was found to have anti-cancer and anti-inflammation function in vitro and in vivo without apparent adverse effects. Stratum corneum is a major physiological barrier to transdermal drug delivery systems, so it is a big challenge to overcome the effect of stratum corneum barrier with enough active drug concentration to reach the dermis. Molecular properties of drugs are crucial for transdermal potential in transdermal drug delivery systems. It is believed that a drug cannot penetrate skin when molecular weight is > 500 Da [13]. It happens that DHMEQ is a nuclear factor-κB (NF-κB) inhibitor with low molecular weight and hopefully penetrate skin. NF-κB signaling pathway is a major regulatory system for cell proliferation, differentiation, immune response and inflammation [14]. The pathway in tissues is often activated in autoimmune diseases like AD [15]. NF-κB is the transcription factor, promoting transcription of immunoglobulin cytokines such as IL-1, IL-6 and TNF-α [16]. DHMEQ inhibited the TNF-α-induced nuclear accumulation of p65, one of the NF-κB family proteins, and showed anti-inflammation properties [17,18]. It has been also reported that DHMEQ does not merely inhibit the expression of various immune cytokines such as IL-4, IL-6, IL-13, but also reduce inflammation and the proliferation of breast, prostate, epithelial ovarian cancer thyroid and hepatocellular carcinoma cells [19–21]. Therefore, DHMEQ is promised to be an alternative and a new type of drug for the treatment of AD.

In the present study, the effects of DHMEQ and tacrolimus against AD were compared, and their inhibition of inflammatory mediators was investigated as well. Observation was focused on their side effects during the evaluation of the therapeutic outcomes of the AD-like lesions.

2. Materials and methods

2.1. Drugs and chemicals

Vehicle ointment (plastibase), containing 950 mg liquid paraffin and 50 mg polyethylene each gram, was supplied by Taisho Pharmaceutical Co., Ltd. (Tokyo, Japan). 0.1% DHMEQ ointment (micronized DHMEQ were evenly mixed into the plastibase) was provided by Shenzhen Wanhe Pharmaceutical Co., Ltd. (Guangdong, China). 0.1% Tacrolimus ointment, purchased from local pharmacy, was the product of Anstai Pharmaceutical Co., Ltd. (China). DNCB was bought from Xiya reagent Inc. (Chengdu, China) and OX from Sigma (St. Louis, MO, USA). RayBio® Mouse IgE ELISA Kit was made by RayBiotech, Inc. (Atlanta, GA, USA). Trizol® reagent came from Ambion Inc. (Carlsbad, CA, USA). PrimeScript™ reagent Kit with gDNA Eraser (Perfect Real Time) and SYBR® Premix Ex Taq™ II (Tli RNaseH Plus) were offered by Takara BIO, Inc. (Dalian, China). Other reagents available in this study were of analytical grade or higher grade without further purification.

2.2. Animals

Six-week-old female BABL/c mice, weighting 18-22 g, were provided by the Experimental Animal Center of Shenyang Pharmaceutical University. They were housed (15 mice per group) in standard environmental conditions (22 ± 1 °C, humidity 60 ± 5%, 12 h light: 12 h dark cycle) with free access to standard commercial diet and water ad libitum. After a 7-day adaptation period, all experiments were performed during the light phase. The animal experiments were conducted according to the rules of animal experimentation and the guide for the Care and Use of Laboratory Animals of Shenyang Pharmaceutical University. The protocol also followed the rules of the local Animal Ethics Committee (SYPU-IACUC-S20170405-107).

2.3. Methods

2.3.1. Induction of stratum corneum-removed AD and drug treatment

AD-like lesions without stratum corneum were induced according to the literatures [22,23], with slight modification. The mice were randomly allocated into four groups (n = 15 in each group), i.e. Normal group (without AD), Vehicle group, DHMEQ group and Tacrolimus group. Hair on the surfaces of both ear lobes was sheared with medical scissors ahead of time. Twenty microliters of 1% DNCB were painted on each ear and paw respectively for sensitization on Day 0 and twenty microliters of 1% DNCB or 1% OX was daily rubbed on each ear for challenge from Day 7 on. Both the agents were alternatively applied to the ears twice a week throughout 44 days. In addition, the stratum corneum layer of the ear skin was stripped off by adhesive tape before each challenge. 0.1% DHMEQ ointment and 0.1% tacrolimus ointment were respectively used on the skin-injured ears of the mice in Group DHMEQ and tacrolimus twice a day (b.i.d.) from Day 18 till Day 44. Twenty mice, i.e. five taken in each group, were examined on Days 31, 38 and 45, respectively. The protocol was shown in Fig. 1.

Hair on the surface of both ear lobes was sheared with medical scissors in advance. Twenty microliters of 1% DNCB were applied on each ear and paw respectively for sensitization on Day 0 and twenty microliters of 1% DNCB or 1% OX was daily painted on each ear for challenge from Day 7 on. The two agents were alternatively applied to the ears twice a week throughout 44 days. In addition, the stratum corneum layer of the ear skin was stripped off by adhesive tape before each challenge. 0.1% DHMEQ and 0.1% tacrolimus were respectively applied on the skin-injured ears of the mice in Group DHMEQ and tacrolimus twice a day (b.i.d.) from Day 18 to Day 44. The body weight of the mice was daily measured. They were sacrificed on Days 31, 38 and 45 and their blood and ear tissue samples were collected for the determination of the indices.

2.3.2. Microscopical measurement of ear thickness and evaluation of dermatitis

Thickness of mouse ear was measured with a dial thickness gauge (Shanghai, China) at 24 h after each challenge. Skin inflammation was

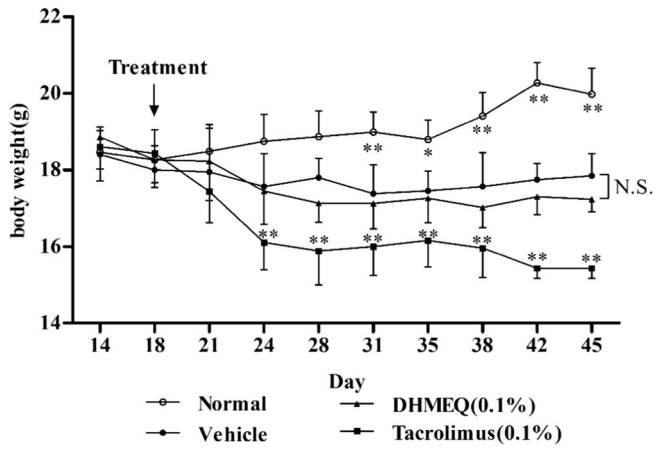

Fig. 2. Body weight of the mice daily measured during the experiment
Data are expressed as mean ± SD of five mice. $*p < 0.05$ and $**p < 0.01$, compared with the vehicle group. Normal = without AD, N.S. = no significance.

macroscopically graded from none (score, 0), red or mild (score, 1), scales or moderate (score, 2) to peeling or severe (score, 3). Moreover, the behavior of the mice was carefully observed after each drugs' treatment.

2.3.3. Histopathological examination of mouse ear tissues

Histopathological examination of inflammatory status or mast cell infiltration was performed according to the description in the previous study [22]. Briefly, the tissues were fixed with 10% formaldehyde and embedded in paraffin. 5 μm sections were prepared and stained with hematoxylin and eosin. The thickness of epidermis and dermis was respectively determined under a light microscope (40×, IX71, Olympus, Japan), based on three randomly selected fields from each slice. Mast cells were measured after sections were prepared and stained with toluidine blue. The number of mast cells in each group was calculated from mean value of five mice, and five areas from each slice were randomly chosen.

2.3.4. Determination of total serum IgE by ELISA

According to the method described above [22], the total serum IgE was examined. Blood samples were respectively collected on Days 31, 38 and 45 and the serum was separated by centrifugation (Legend Micro 21R Centrifuge, Thermo Scientific) at 1000*g* for 10 min at 4 °C. The level of IgE in the serum was determined in the light of instructions from manufacturer of the ELISA kit. The assay was performed on a 96-well plate which was coated with mouse IgE-specific antibody. Absorbance was measured at 450 nm with a microplate reader (Thermo Scientific, Rockford, IL, USA). IgE level was indicated by optical density (O.D.) value.

2.3.5. Determination of cytokines in ear tissues by real time PCR

Real time PCR was conducted by semi-quantifying mRNA expression of target genes in the ear tissues, according to the previous description [22]. Total RNA was extracted from the tissues with TRIzol® reagent in accordance with the manufacturer's protocol and reverse transcription reaction was performed by using PrimeScript™ RT reagent Kit for cDNA synthesis. Thereafter, target genes of the cytokines were checked by PCR performed on Agilent Technologies Stratagene M × 3000 P (Agilent Technologies Inc., Waldbronn, Germany), with SYBR® premix Ex Taq™. PCR protocol is consisted of 30 s at 95 °C followed by 40 cycles of 5 s at 95 °C, 31 s at 60 °C, 15 s at 95 °C, 1 min at 60 °C and 15 s at 95 °C. Specific primers used for quantification were mouse IL-4/IL-13/IFN-γ/β-actin, their forward and reverse primers were similar to those described in the previous study [22]. Mouse IL-6: forward 5′-CCA TCC AGT TGC CTT CTT G and reverse 5′-CTC ATT TCC ACG ATT TCC C; mouse IL-1β: forward 5'-CTT CAG GCA GGC AGT ATC AC and reverse 5′-TCA CAC ACC AGC AGG TTA TC. All the data were normalized to the expression level of β-actin gene.

2.3.6. Statistical analysis

Data are expressed as mean ± SD. The statistics were dealt with Version 5 of GraphPad Prism (GraphPad, Software, USA). Therapeutic effects of the tested drug were analyzed with one way ANOVA followed by Dunnett's test of mean values. Value of $p < 0.05$ above was used to express statistically significant difference.

3. Results

3.1. Comparison between the two drugs influencing the mouse weight after chronic application

To compare whether the two drugs had adverse influence on mice when applied for a long time, mouse body weight was daily determined at 24 h after each challenge throughout the experimental duration. Results showed that the body weight of the mice treated with 0.1% DHMEQ ointment maintained a steady trend similar to that of the vehicle group, while that of those rubbed with 0.1% tacrolimus ointment dropped rapidly (Fig. 2).

3.2. Comparable effectiveness between the two drugs in improving AD symptoms and few side effects of DHMEQ

The induction of AD-like lesions with DNCB and OX on the ears led to clinical manifestations such as redness, dryness, scales and peeling. Medical tape, used before each challenge to strip off the outer skin of the ears, accelerated the formation of the dermatitis. Either DHMEQ ointment or tacrolimus ointment improved the manifestations (Fig. 3) and dermatitis scores in the two groups significantly decreased (Fig. 3C). However, lots of exudate on skin surface of the ears painted with tacrolimus ointment was significantly observed. Mice treated with tacrolimus ointment became restless evidently due to skin irritation from the drug's application. In contrast, any uncomfortable reaction was not seen in the mice treated with DHMEQ ointment. Dermatitis score in mice treated with DHMEQ ointment decreased day after day and the efficacy was more stable than that of tacrolimus ointment (Fig. 3C).

3.3. Histopathological examination

3.3.1. Comparable effects between the two drugs on suppressing epidermal and dermal thickness

Histopathological analysis of the ear tissues of the mice in Vehicle group (Model group) showed that both epidermis and dermis became thick after chronic inflammatory stimulation with DNCB/OX plus tape (Fig. 4). Either DHMEQ or tacrolimus treatment improved significantly the histopathological changes (Fig. 4), suppressed considerably the tape-DNCB/OX-induced epidermis (Fig. 4A, B) and dermis (Fig. 4A, C) thickening, and reduced infiltration of inflammatory cells in the tissues Fig. 4A) on Days 31, 38 and 45, respectively. Interestingly, it is found that the efficacy of tacrolimus is slightly better than that of DHMEQ on Day 31, while vice versa on Days 38 and 45, the later period of the experiment, although significant difference of the therapy between the two drugs was not found throughout 45 days (Fig. 4A, B, C).

3.3.2. Comparable effect between the two drugs on suppressing infiltration of mast cells

AD is resulted from disorders in immune system, being associated with infiltration of inflammatory cells including mast cells. Therefore, the number of mast cells in all the groups was counted as an important index in this study. Histopathological slices were observed under

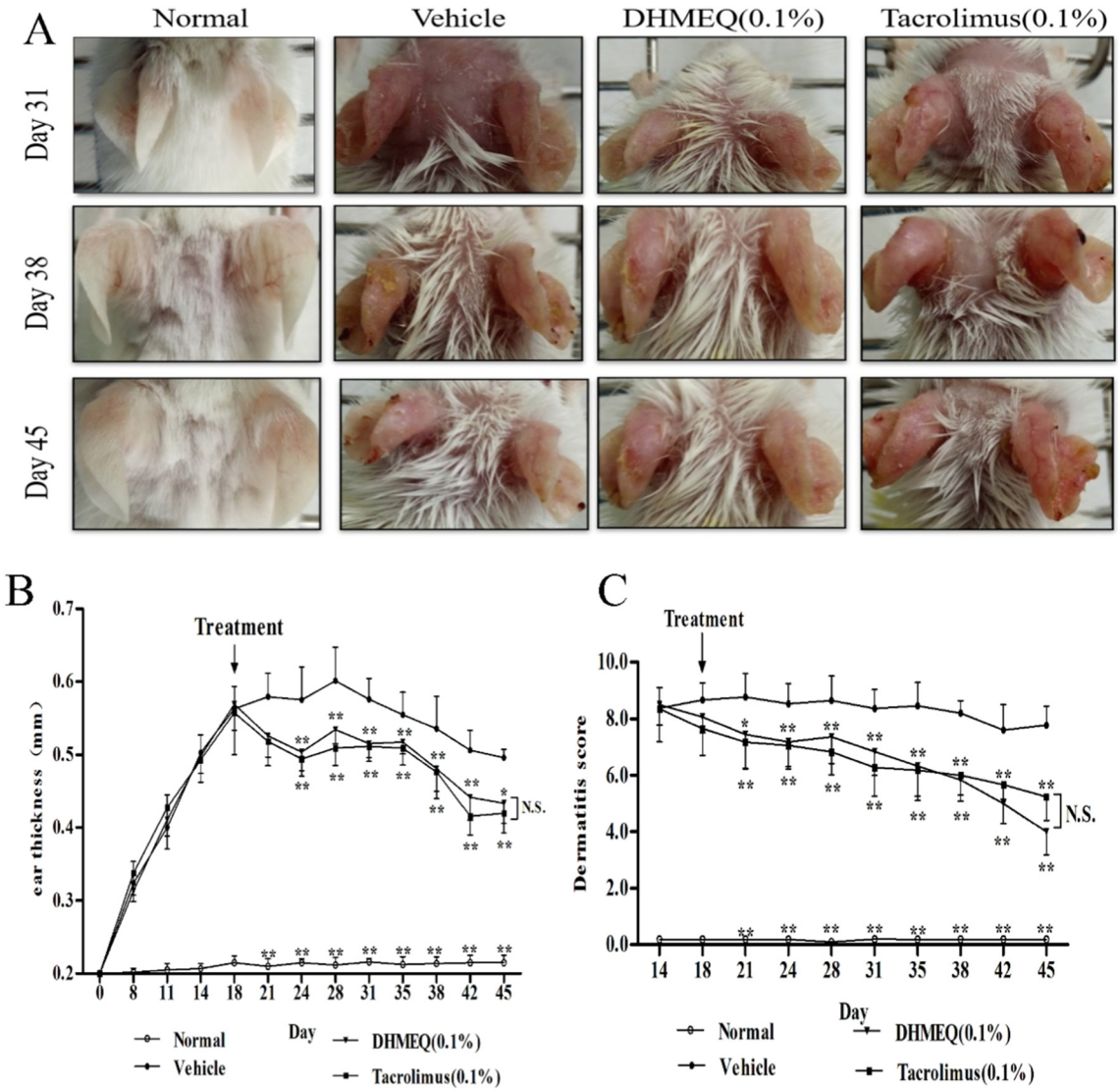

Fig. 3. Improvement in AD symptoms with DHMEQ and tacrolimus
The Photos of the ears were taken on Days 31, 38 and 45 in panel A. A stable dermatitis model was induced successively and alternatively by DNCB/OX plus tape. Ear thickness of the mice in all groups was measured at 24 h after each challenge in panel B. Both DHMEQ and tacrolimus significantly suppressed the abnormal ear thickness, whereas mucus secretion around ear skin treated with tacrolimus was seen, the occurrence of which was not in DHMEQ group. Inflammation score was macroscopically graded at 24 h after each challenge in panel C. Skin inflammation was macroscopically rated as described above. The dermatitis score of the vehicle group was obviously higher than that of the normal group. The two drugs significantly decreased the dermatitis score. There was no significantly different effect between them. Data are expressed as mean ± SD of five mice. $*p < 0.05$ and $**p < 0.01$, compared with Vehicle group. N.S. = no significance.

microscope after they were stained with toluidine blue. As a consequence, the number of mast cells in Vehicle group (Model group) was much more than that in Normal group (Fig. 5A, B) on Days 31, 38 and 45. DHMEQ and tacrolimus inhibited comparably the increase in the cells (Fig. 5A, B), but the former acts more effectively in trend than the latter although significant difference was not found between them.

3.4. Comparison of the suppressive effects between the two drugs on the induced high level of total serum IgE

IgE is an important pathogenic factor from the onset of AD and in the course of AD. Serum IgE level is obviously elevated under the induction with DNCB/OX [24]. As the results, the total serum IgE level of the mice in Vehicle group on Days 31, 38 and 45 was significantly increased by repeated challenges with DNCB/OX (Fig. 6). Either DHMEQ or tacrolimus significantly suppressed the increased IgE level (Fig. 6). There is a comparable efficacy between them as for the suppression on the increased IgE level (Fig. 6).

3.5. Comparison of the suppressive effects between the two drugs on the induced high level of inflammatory factors in the ear tissues

Th2 lymphocytes that produce IL-4 and IL-13 play major roles in the early stage of AD pathogenesis, while Th1 which mainly generate tumor necrosis factor alpha (TNF-α) and IFN-γ contributes to pathogenesis of chronic progression. Relative expression of IL-4 (Fig. 7A), IL-6 (Fig. 7B), IL-13 (Fig. 7C), IL-1β (Fig. 7D) and IFN-γ (Fig. 7E) at mRNA level was respectively determined in this study by real time PCR. Both DHMEQ ointment and tacrolimus ointment showed significantly suppressive effect on the factor expression. It was observed that suppressive effect of DHMEQ on IL-4 was stronger than that of tacrolimus on Day 31 ($p < 0.01$), while the situation on Day 38 just the opposite, i.e. tacrolimus became more effective than that of DHMEQ ($p < 0.01$). As for the effect on IL-6, tacrolimus was stronger than DHMEQ on Day 31 ($p < 0.01$), and on IL-1β, DHMEQ was better than tacrolimus on Day 31 ($p < 0.01$).

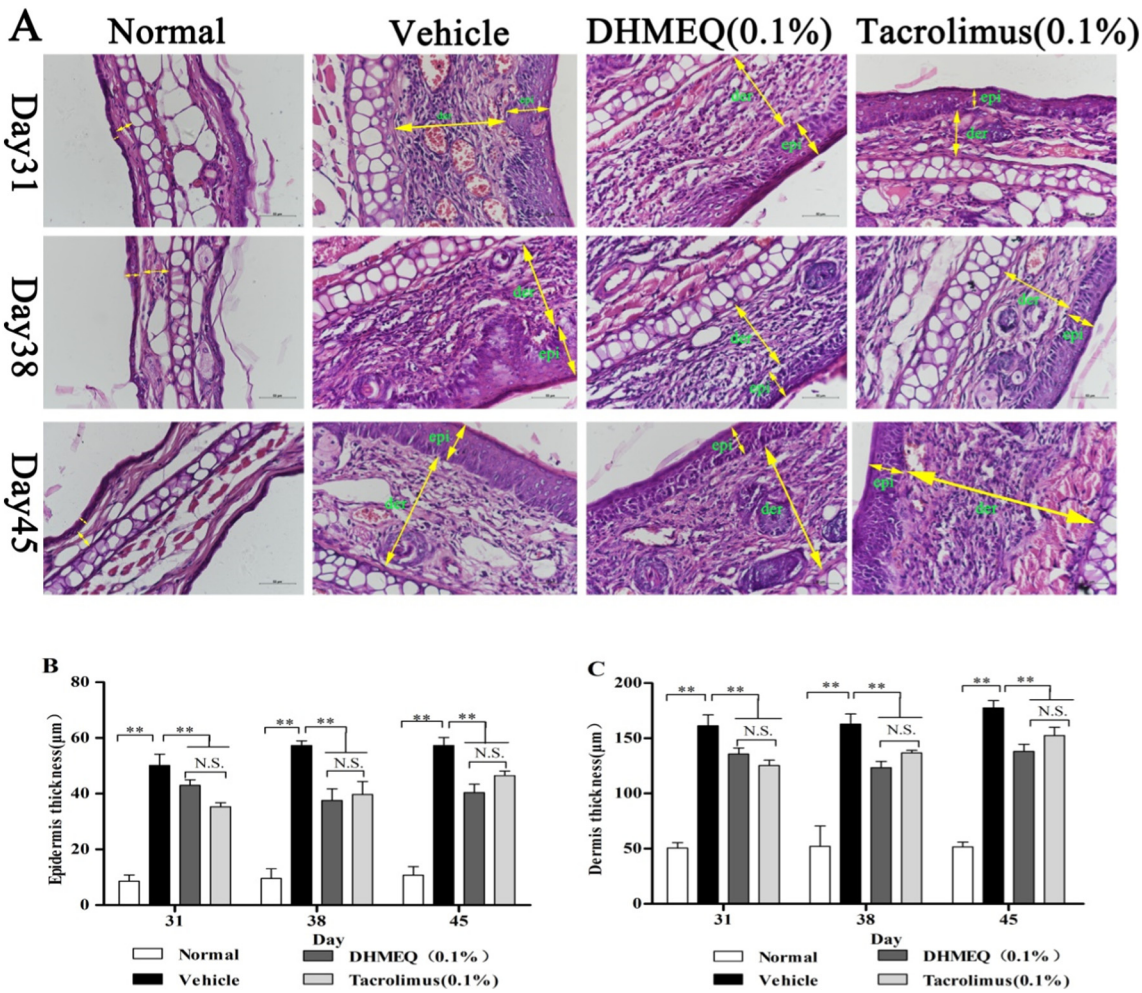

Fig. 4. Histopathological analysis of inflammation and *epi*dermis and dermis thickness in the ear tissues stained with hematoxylin and eosin
The photos of the mouse ear were taken under microscope (bar = 50 μm, 400×) in Subfigure A. Infiltration of inflammatory cells as well as epidermis and dermis thickness was shown (epi = epidermis, der = dermis). The yellow arrows indicate epidermis and dermis thickness, respectively. The data in Subfigure B and C, standing for epidermis thickness and dermis thickness, were derived from Subfigure A. They are calculated from the average of three slices in each mouse and two regions in each slice were randomly chosen to measure the epidermis and dermis thickness. Data are expressed as mean ± SD of five mice. $^{**}p < 0.01$, compared with Vehicle group. N.S. = no significance. (For interpretation of the references to colour in this figure legend, the reader is referred to the web version of this article.)

4. Discussion

It is well known that pathogenesis of AD closely relates to the dysregulation of T cell function and the production of IgE [25]. Tacrolimus, regarded as one of CNIs, is widely used as a topical agent to treat AD. CNIs inhibit proliferation of T cells and production and secretion of inflammatory cytokines because they may bind to key signaling proteins involved in the activation of T cells [26]. However, the risk of topical CNIs versus its benefit remains unclear. Recent literatures posed safety problems when topical CNIs are being used in the treatment for dermatitis. Long-term safety of the drugs has been under investigation [27,28]. It is reported that long-term use of tacrolimus causes lots of stimulated side effects such as skin burning, itching and skin erythema in clinic [11,27]. The current data demonstrated that 0.1% tacrolimus ointment significantly decreased body weight of the mice after being chronically applied, and exudate on the skin surface of the ears applied with tacrolimus ointment was observed. Mice treated with tacrolimus ointment became restless due to skin irritation from the drug's application. 0.1% DHMEQ ointment did not have any adverse influences on the whole status of the mice. The results indicate that the DHMEQ ointment is much safer than tacrolimus when topically used to treat chronic dermatitis for a long time.

It is considered that molecular weight and lipophilicity of a drug are important features that determine penetration and absorption of topical formulations. Drugs with < 500 g/mol molecular weight are generally believed to penetrate skin barrier easily [29]. Molecular weight of tacrolimus ($C_{44}H_{69}NO_{12}$) is over 800 g/mol, while that of DHMEQ ($C_{13}H_{11}NO_3$) is 261 g/mol. Therefore, it is theoretically difficult for tacrolimus to overcome skin barrier and penetrate into deep skin although it has relatively good lipophilicity [30]. However, skin barrier damaged upon the status of AD allows drug molecules > 800 g/mol to penetrate [31]. It leads to the fact that the therapeutic properties of both DHMEQ ointment and tacrolimus ointment can be remarkably observed in the initial period of the treatment, for they can easily penetrate skin. There is also a finding that the efficacy of tacrolimus was slightly worse than that of DHMEQ on Days 38 and 45, the reason of which might be that skin forms a barrier in the late period of the experiment and penetration of tacrolimus was limited with skin lesions being healed [32]. The efficacy of DHMEQ is better than that of tacrolimus in the late period although there was no significant effect between them.

It has been reported that balance between Th1 and Th2 responses is crucial for optimal immune function. The destruction of the balance causes a variety of immune-related diseases including AD [33]. In

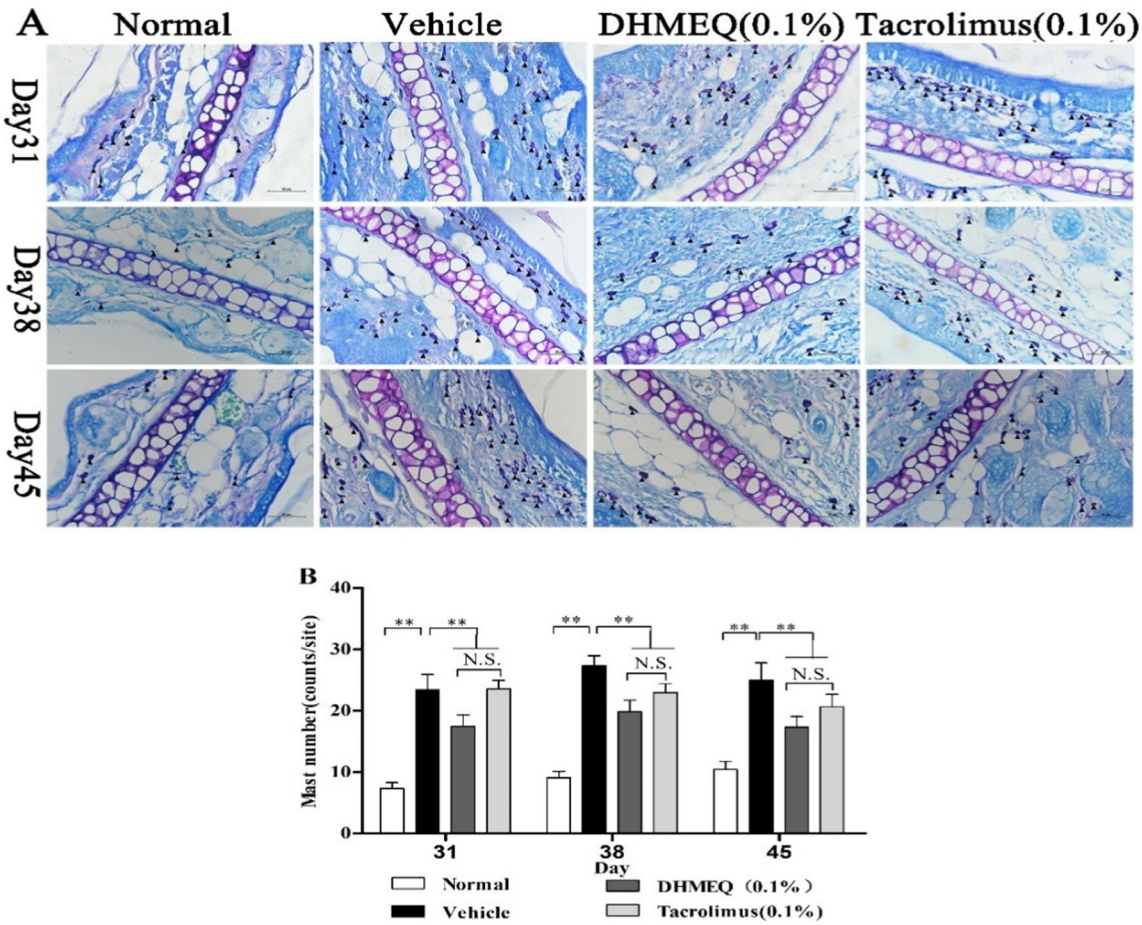

Fig. 5. Histopathological examination of the mast cells in the ear skin stained with toluidine blue.
The photos of the mouse ear skin were taken under microscope (bar = 50 μm, 400×) in Subfigure A. Black arrows denote mast cells. The data in Subfigure B were derived from Subfigure A. They are calculated from the average of three slices in each mouse and five regions in each slice were randomly chosen to count mast cells. Data are expressed as mean ± SD of five mice. $^{**}p < 0.01$, compared with Vehicle group. N.S. = no significance. (For interpretation of the references to colour in this figure legend, the reader is referred to the web version of this article.)

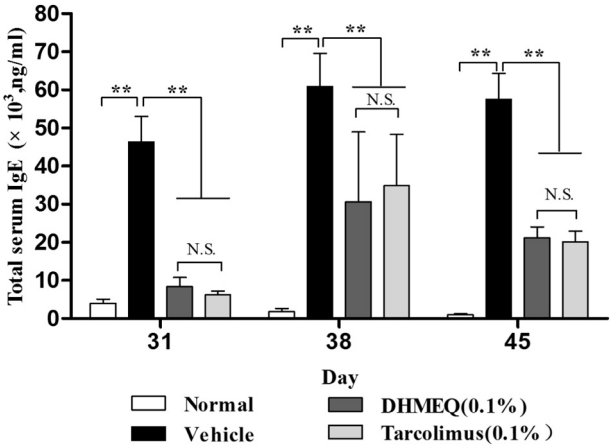

Fig. 6. Level of the total IgE in the serum of the mice in all the groups
The total IgE level in the serum was checked on Days 31, 38, and 45, respectively, with commercial ELISA kit according to its instruction. Both DHMEQ and tacrolimus significantly suppressed the increased IgE level. There was no significantly different effect between them. Data are expressed as mean ± SD of five mice. $^{**}p < 0.01$, compared with vehicle group. N.S. = no significance.

general, AD patients show a Th2 phenotypic enhancement, exhibiting increased expression of Th2 cytokines such as IL-4 and IL-13. IL-4 stimulates IgE production in B cells, which binds to mast cells and encourages the cells to release various biological mediators, and in return key effector cells and allergen-sensitized and IgE-activated mast cells lead to Th2 cell development and secretion of cytokines, inducing development of AD skin lesions [34]. Moreover, it is clear that IL-6, a rapid and transient production of infections and tissue damage, contributes to host defense by stimulating acute phase and immune responses [35]. In the present study, DHMEQ ointment and tacrolimus ointment inhibited the mRNA expression of inflammatory cytokines IL-4, IL-6, IL-13, IL-1β and TNF-γ, and the decreased trend of the cytokines was consistent with that of IgE. Tacrolimus notably inhibited IL-6 and IL-13 (Fig. 7B, C), which are inflammatory factors produced by Th2 cells in early stage of AD. Compared with tacrolimus, DHMEQ significantly inhibited IL-1β and IFN-γ (Fig. 7D, E), which are inflammatory factors produced by Th1 type cells in the late stage of AD. Consequently, there is a consistency with the speculations concerning the drugs' pharmaceutical properties mentioned above. In addition, Sampaio et al. confirmed that IL-4 and IL-6 are responsible for activation of inflammatory cascade [36]. The cytokines at systemic level are very important for regulating secretion of epithelial cells and other cytokines such as IL-13 and IL-1, etc. This study found that both DHMEQ ointment and tacrolimus ointment inhibited IL-4 and IL-6 mRNA expression and IL-4 was an order of magnitude greater than IL-6 on Day 38 (Fig. 7A, B) so that feedback regulation between IL-4 and IL-6 did not probably result in any change in IL-6 levels from Day 31 till Day 38, which needs to be confirmed in further study.

It has been reported that DHMEQ can be used via various routes,

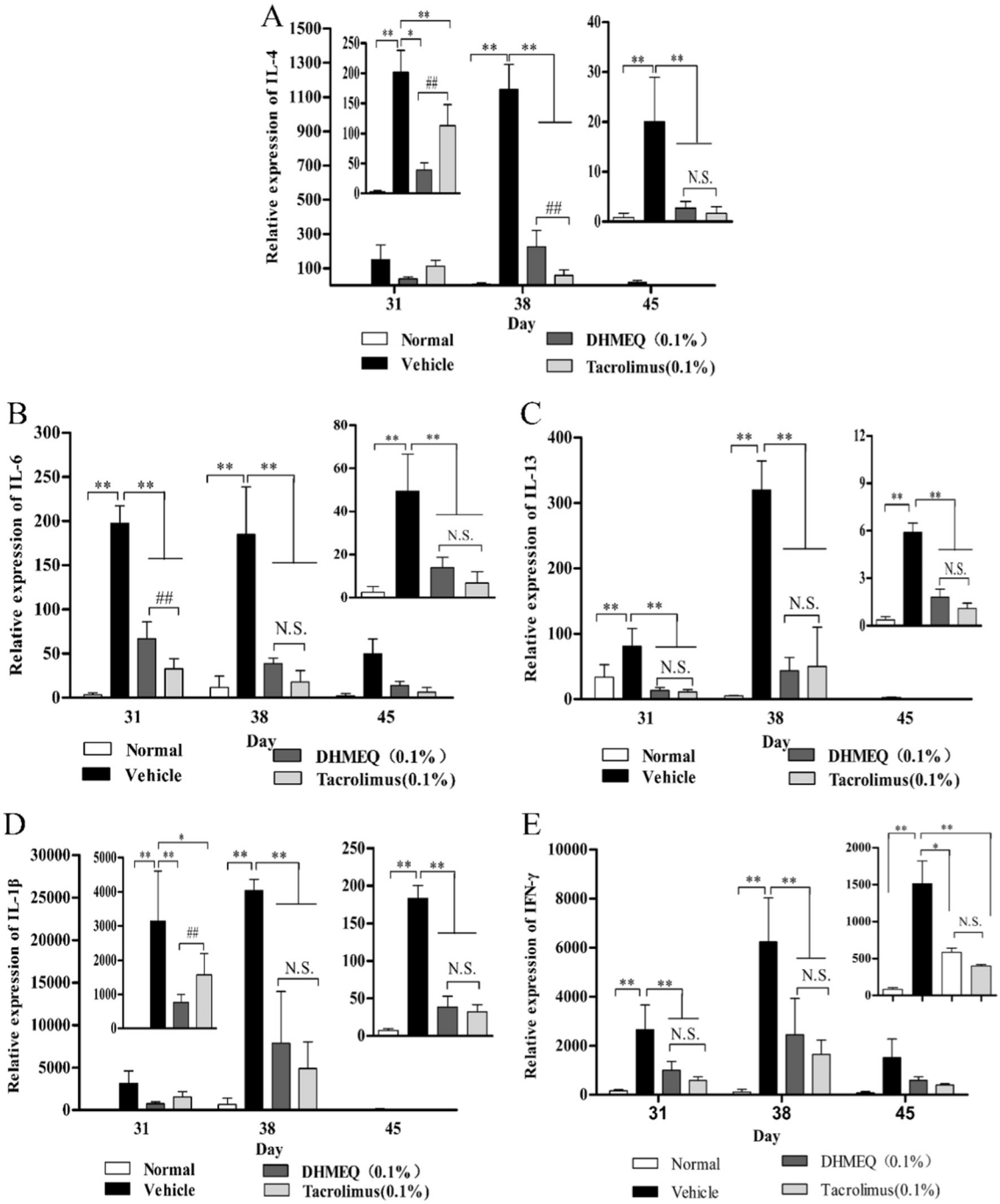

Fig. 7. Suppressive effects of the drugs on the increased cytokines in lesioned skin tissues induced by tape-DNCB/OX
Relative expression of IL-4 (Fig. 7A), IL-6 (Fig. 7B), IL-13 (Fig. 7C), IL-1β (Fig. 7D) and IFN-γ (Fig. 7E) at mRNA level was observed by real time PCR. DHMEQ or tacrolimus showed significantly suppressive effect on the factors. Data are expressed as mean ± SD of five mice. *$p < 0.05$ and **$p < 0.01$, compared with Vehicle group. ##$p < 0.01$, compared with Tacrolimus group. N.S. = no significance.

like systemically subcutaneous or intraperitoneal administration and topical application with ointment, as a cure for animal diseases [22,37,38]. Umezawa found that DHMEQ might rapidly be absorbed directly by peritoneal immune cells after intraperitoneal delivery [39], suggesting that the cells are firstly chosen as target cells of DHMEQ. After entering the cells, DHMEQ exerts its inhibition on molecular pathways relevant to inflammatory responses. What's more, it depresses LPS-induced secretions of various inflammatory cytokines in macrophage-like cells [40] and blocks the release of inflammatory cytokines IL-1β, IL-2, IL-6, IL-8 and TNF-α [39]. The suppression of inflammatory cytokines was proved in our previous studies [22,41] and the present study (Fig. 7). More observations are that the drug inhibits antigen and IgE-induced invasion in mouse mast cells [42], and suppresses the antigen-specific T-cell proliferation as well as the production of Thyl-type cytokines in cultured T-cells [43]. DHMEQ, after entering its target cells, directly binds to the Rel-family proteins to inhibit their DNA-binding activity [44]. Rel family proteins are the constituents of NF-κB molecules containing p65, Rel B, c-Rel, p50, and p52. DHMEQ combines with p65 covalently with a 1:1 stoichiometry [39]. Therefore, the inhibitory effect of DHMEQ on the cysteine residues in the NF-κB molecule is irreversible [45]. In contrast, tacrolimus achieves immunosuppression mainly by suppressing IL-2 transcription and

reducing responses of T lymphocytes to foreign antigens. It controls transcription of genes that code for several inflammatory mediators such as IL-2, granulocyte-macrophage colony-stimulating factor, TNF-α, IFN-γ and other interleukins which are requisite for development of immune responses. Tacrolimus also inhibits release of histamine from mast cells [46]. The most common adverse events regarding tacrolimus are also reported, including low and variable bioavailability, burning sensation and pruritus at the site of application and the potential to increase the risk of cutaneous infections, which is mostly due to its altering local cutaneous immune responses [47]. It is evident that the mechanisms of the anti-inflammation and immunosuppression between the two drugs are different from each other, leading to their individual pharmacological activities and whether side effects occur or not.

5. Conclusion

DHMEQ and tacrolimus ointment significantly improved dermatitis symptoms, like ear swelling, erythema hemorrhage, edema and scales, in the AD model induced by DNCB/OX plus tape. Long-term application with tacrolimus resulted in body weight loss significantly and mice treated with the drug became obviously irritable, jumping up and down, while DHMEQ didn't cause any adverse response due to its non-stimulus. Both of them showed good activity against AD, significantly reducing not only epidermal and dermal thickness but also the number of mast cells. They inhibited production of total IgE in the serum of the mice with AD and the expression of inflammatory factors IL-4, IL-6, IL-13, IL-1β and IFN-γ in ear tissues. It is concluded that DHMEQ which seems a potential drug of curing AD is softer and safer in long-term application than tacrolimus.

Acknowledgements

This study was supported in part by National Key Programs in Science and Technology-Discovery and Development of New Drugs with High Clinical Impact (No. 2012ZX09103101-004), Guangdong Provincial Programs for Achieving Core Technological Breakthroughs in Strategic Emerging Industries (No. 2012A080800010), and Shenzhen Municipal Programs for the Research and Development of Technologies (Three Key Industries) (No. JSA201105090126A).

Conflicts of interest

None to be declared.

References

[1] De Vuyst E, Salmon M, Evrard C, et al. Atopic dermatitis studies through in vitro models. Front. Med. 2017; 4: 119.
[2] E.L. Simpson, Atopic dermatitis: a review of topical treatment options, Curr. Med. Res. Opin. 26 (3) (2010) 633–640.
[3] B.K. Park, Y.C. Park, I.C. Jung, et al., Gamisasangja-tang suppresses pruritus and atopic skin inflammation in the NC/Nga murine model of atopic dermatitis, J. Ethnopharmacol. 165 (2015) 54–60.
[4] D.W. Choi, D.A. Kwon, S.K. Jung, et al., Silkworm dropping extract ameliorate trimellitic anhydride-induced allergic contact dermatitis by regulating Th1/Th2 immune response, Biosci. Biotechnol. Biochem. 26 (2018) 1–8.
[5] J.M. Ku, S.H. Hong, H.I. Kim, et al., Effects of Angelicae dahuricae Radix on 2, 4-dinitrochlorobenzene-induced atopic dermatitis-like skin lesions in mice model, BMC Complement. Altern. Med. 17 (2017) 98.
[6] E.G. Lee, B.M. Mickle-Kawar, R.M. Gallucci, et al., IL-6 deficiency exacerbates skin inflammation in a murine model of irritant dermatitis, J. Immunotoxicol. 10 (2013) 192–200.
[7] P. Nghiem, G. Pearson, R.G. Langley, Tacrolimus and pimecrolimus: from clever prokaryotes to inhibiting calcineurin and treating atopic dermatitis, J. Am. Acad. Dermatol. 46 (2002) 228–241.
[8] J. Cury Martins, C. Martins, V. Aoki, et al., Topical tacrolimus for atopic dermatitis, Cochrane Database Syst. Rev. 1 (2015) CD009864.
[9] K.T. Chang, H.Y. Lin, C.H. Kuo, et al., Tacrolimus suppresses atopic dermatitis-associated cytokines and chemokines in monocytes, J. Microbiol. Immunol. Infect. 49 (2016) 409–416.
[10] T. Wan, W. Pan, Y. Long, et al., Effects of nanoparticles with hydrotropic nicotinamide on tacrolimus: permeability through psoriatic skin and antipsoriatic and antiproliferative activities, Int. J. Nanomedicine 12 (2017) 1485–1497.
[11] J.M. Hanifin, et al., Efficacy and safety of tacrolimus ointment treatment for up to 4 years in patients with atopic dermatitis, J. Am. Acad. Dermatol. 53 (2005) S186–S194.
[12] K. Umezawa, A. Ariga, N. Matsumoto, Naturally occurring and synthetic inhibitors of NF-kappaB functions, Anticancer Drug Des. 15 (2000) 239–244.
[13] Xin Kong, Yuan Zhao, Peng Quan, et al., Development of a topical ointment of betamethasone dipropionate loaded nanostructured lipid carrier, Asian J. Pharm. Sci. 11 (2016) 248–254.
[14] S. Inokawa, T. Watanabe, H. Keino, et al., Dehydroxymethylepoxyquinomicin, a novel nuclear factor-kappaB inhibitor, reduces chemokines and adhesion molecule expression induced by IL-1beta in human corneal fibroblasts, Graefes Arch. Clin. Exp. Ophthalmol. 253 (2015) 557–563.
[15] V. Karuppagounder, S. Arumugam, R.A. Thandavarayan, et al., Modulation of HMGB1 translocation and RAGE/NFkappaB cascade by quercetin treatment mitigates atopic dermatitis in NC/Nga transgenic mice, Exp. Dermatol. 24 (2015) 418–423.
[16] G. Yang, I. Ham, H.Y. Choi, Anti-inflammatory effect of prunetin via the suppression of NF-kappaB pathway, Food Chem. Toxicol. 58 (2013) 124–132.
[17] E. Suzuki, Y. Ninomiya, K. Umezawa, Induction of histidine decarboxylase in macrophages inhibited by the novel NF-kappaB inhibitor (−)-DHMEQ, Biochem. Biophys. Res. Commun. 379 (2009) 379–383.
[18] K. Umezawa, C. Chaicharoenpong, Molecular design and biological activities of NF-kappaB inhibitors, Mol. Cell 14 (2002) 163–167.
[19] D. Nishimura, H. Ishikawa, K. Matsumoto, et al., DHMEQ, a novel NF-kappaB inhibitor, induces apoptosis and cell-cycle arrest in human hepatoma cells, Int. J. Oncol. 29 (2006) 713–719.
[20] C. Nishioka, T. Ikezoe, Y. Jing, et al., DHMEQ, a novel nuclear factor-kappaB inhibitor, induces selective depletion of alloreactive or phytohaemagglutinin-stimulated peripheral blood mononuclear cells, decreases production of T helper type 1 cytokines, and blocks maturation of dendritic cells, Immunology 124 (2008) 198–205.
[21] Nishio H, Yaguchi T, Sugiyama J, et al. Immunosuppression through constitutively activated NF-kappaB signalling in human ovarian cancer and its reversal by an NF-kappaB inhibitor. Br. J. Cancer 2014; 110:2965–2974.
[22] X. Jiang, Y. Lan, B. Wei, et al., External application of NF-kappaB inhibitor DHMEQ suppresses development of atopic dermatitis-like lesions induced with DNCB/OX in BALB/c mice, Immunopharmacol. Immunotoxicol. 39 (2017) 157–164.
[23] S.W. Hong, M.R. Kim, E.Y. Lee, et al., Extracellular vesicles derived from Staphylococcus aureus induce atopic dermatitis-like skin inflammation, Allergy 66 (2011) 351–359.
[24] J.S. Hwang, J.E. Kim, H.T. Kim, et al., Topical application of Taglisodog-eum inhibits the development of experimental atopic dermatitis, J. Ethnopharmacol. 145 (2013) 536–546.
[25] Y.Z. Li, X.Y. Lu, W. Jiang, et al., Anti-inflammatory effect of qingpeng ointment in atopic dermatitis-like murine model, Evid. Based Complement. Alternat. Med. 2013 (2013) 907016.
[26] B.K. Chia, H.L. Tey, Systematic review on the efficacy, safety, and cost-effectiveness of topical calcineurin inhibitors in atopic dermatitis, Dermatitis 26 (2015) 122–132.
[27] P.J. Munzenberger, J.M. Montejo, Safety of topical calcineurin inhibitors for the treatment of atopic dermatitis, Pharmacotherapy 27 (2007) 1020–1028.
[28] H.C. Frankel, A.A. Qureshi, Comparative effectiveness of topical calcineurin inhibitors in adult patients with atopic dermatitis, Am. J. Clin. Dermatol. 13 (2012) 113–123.
[29] J.D. Bos, M.M. Meinardi, The 500 Dalton rule for the skin penetration of chemical compounds and drugs, Exp. Dermatol. 9 (2000) 165–169.
[30] L.A. Beck, The efficacy and safety of tacrolimus ointment: a clinical review, J. Am. Acad. Dermatol. 53 (2005) S165–S170.
[31] A. Alomar, J. Berth-Jones, J.D. Bos, et al., The role of topical calcineurin inhibitors in atopic dermatitis, Br. J. Dermatol. 151 (2004) 3–27.
[32] A. Rubins, R. Gutmane, N. Valdmane, et al., Pharmacokinetics of 0.1% tacrolimus ointment after first and repeated application to adults with moderate to severe atopic dermatitis, J. Invest. Dermatol. 125 (2005) 68–71.
[33] J.H. Lee, Y.S. Lee, E.J. Lee, et al., Capsiate inhibits DNFB-induced atopic dermatitis in NC/Nga mice through mast cell and CD4+ T-cell inactivation, J. Invest. Dermatol. 135 (2015) 1977–1985.
[34] J. Punnonen, H. Yssel, J.E. de Vries, The relative contribution of IL-4 and IL-13 to human IgE synthesis induced by activated CD4+ or CD8+ T cells, T J Allergy Clin Immunol 100 (1997) 792–801.
[35] T. Tanaka, M. Narazaki, T. Kishimoto, IL-6 in inflammation, immunity, and disease, Cold Spring Harb. Perspect. Biol. 6 (2014) a016295.
[36] A.M. Sampaio, Silva M.R. Balseiro, et al., Association between IL-4 and IL-6 expression variants and gastric cancer among Portuguese population, GE Port. J. Gastroenterol. 22 (2015) 143–152.
[37] T. Shimo, Y. Adachi, K. Umezawa, et al., Dehydroxymethylepoxyquinomicin (DHMEQ) can suppress tumour necrosis factor-α production in lipopolysaccharide-injected mice, resulting in rescuing mice from death in vivo, Clin. Exp. Immunol. 11 (2011) 299–306.
[38] N. Nagai, Umezawa K. Izumi-Nagai, et al., Suppression of diabetes-induced retinal inflammation by blocking the angiotensin II type 1 receptor or its downstream nuclear factor-kappa B pathway, Invest. Ophthalmol. Vis. Sci. 48 (9) (2007) 4342–4350.
[39] K. Umezawa, Peritoneal NF-κB as a possible molecular target for suppression of various cancers and inflammation, Forum Immunopathol. Dis. Ther. 4 (2013) 63–77.

[40] E. Suzuki, C. Sugiyama, K. Umezawa, Inhibition of inflammatory mediator secretion by (−)-DHMEQ in mouse bone marrow-derived macrophages, Biomed. Pharmacother. 63 (2009) 351–358.
[41] X. Jiang, H. He, Z. Xie, et al., Dehydroxymethylepoxyquinomicin suppresses atopic dermatitis-like lesions in a stratum corneum-removed murine model through NF-κB inhibition, Immunopharmacol. Immunotoxicol. 6 (2019) 1–8.
[42] N. Noma, M. Asagiri, M. Takeiri, et al., Inhibition of MMP-2-mediated mast cell invasion by NF-κB inhibitor DHMEQ in mast cells, Int. Arch. Allergy Immunol. 166 (2015) 84–90.
[43] D. Iwata, N. Kitaichi, A. Miyazaki, et al., Amelioration of experimental autoimmune uveoretinitis with nuclear factor-κB inhibitor dehydroxy methyl epoxyquinomicin in mice, Invest. Ophthalmol. Vis. Sci. 4 (2010) 2077–2084.
[44] M. Yamamoto, R. Horie, K. Umezawa, Inactivation of nuclear factor kappa B components by covalent binding of (−)-dehydroxymethylepoxyquinomicin to specific cysteine residues, J. Med. Chem. 51 (2008) 5780–5788.
[45] C. Shimada, Y. Ninomiya, K. Umezawa, Efficient cellular uptake of the novel NF-κB inhibitor (−)-DHMEQ and irreversible inhibition of NF-κB in neoplastic cells, Oncol. Res. 18 (2010) 529–535.
[46] V.N. Sehgal, G. Srivastava, S. Dogra, Tacrolimus in dermatology-pharmacokinetics, mechanism of action, drug interactions, dosages, and side effects: part I, Skin Med. 7 (2008) 27–30.
[47] P.V. Pople, K.K. Singh, Targeting tacrolimus to deeper layers of skin with improved safety for treatment of atopic dermatitis, Int. J. Pharm. 398 (2010) 165–178.