Case Report

Unusual Presentation of Nickel Allergy Requiring Explantation of an Amplatzer Atrial Septal Occluder Device

Address for correspondence:
Andrew D. Michaels, MD, MAS
Division of Cardiology
University of Utah
30 North 1900 East, Room 4A100
Salt Lake City, UT 84132-2401 USA
andrew.michaels@hsc.utah.edu

David G. Rabkin, MD; Kevin J. Whitehead, MD; Andrew D. Michaels, MD, MAS; Douglas L. Powell, MD; S.V. Karwande, MD
Divisions of Cardiothoracic Surgery and Cardiology(Rabkin, Whitehead, Michaels, Karwande); Departments of Surgery, Medicine and Dermatology (Powell), University of Utah Medical Center, Salt Lake City, Utah

ABSTRACT

Systemic allergic reaction to a percutaneous patent foramen ovale (PFO) occlusion device is a rare event with only scattered reports in the literature. Serious allergic reactions to these devices have a poorly defined incidence, presentation, and natural history. We present a woman with a previously unknown nickel allergy who developed severe chest pain beginning the morning after percutaneous device closure of the PFO. Despite multiple visits to her cardiologists and primary care physicians, the cause of her chest pain remained unclear. After seeking a second opinion at our medical center, skin testing showed a severe reaction to nickel. These symptoms were refractory to treatment until device explantation 18 mo later. This case highlights the importance of recognizing nickel allergy as a cause of chest pain following implantation of certain types of devices used for closure of PFOs and other heart defects.

Introduction

Systemic allergic reaction to a percutaneous patent foramen ovale (PFO) occlusion device is a rare event with only scattered reports in the literature[1,2] and a poorly defined incidence, presentation, and natural history. We present a patient with a previously unknown nickel allergy who developed severe chest pain beginning the morning after percutaneous device closure of the PFO, which persisted until device explantation 18 mo later. The case is described and therapeutic implications discussed.

Clinical Summary

A 52-year-old woman underwent percutaneous PFO closure for recurrent transient ischemic attacks refractory to aspirin therapy using a 12 mm Amplatzer atrial septal occluder (AGA Medical Corporation, Plymouth, MN) at an outside cardiology private practice. Beginning the morning following implantation of the septal occluder device, the patient noted severe, burning left-sided chest pain near the anterior axillary line. She has had daily chest pain since then with occasional episodic palpitations. Her symptoms had provoked multiple prior evaluations, including 2 by the implanting physician and 5 by the outside general cardiology clinic. She had been treated with NSAIDs and beta-blockers with some symptomatic improvement; however, she continued to complain of residual, chronic dull pain.

Eighteen mo after PFO closure, the patient presented to our medical center seeking a second opinion for her continued chest pain syndrome. Her physical exam was unremarkable. She did not have a leukocytosis and her erythrocyte sedimentation rate and other biochemical indices were normal. A transesophageal echocardiogram revealed a small, hemodynamically insignificant pericardial fluid collection posterior to the left atrium in the transverse pericardial sinus. On further questioning, she reported a history of a reaction to inexpensive jewelry, raising the possibility of a previously unrecognized nickel allergy.

Skin patch testing revealed a prominent allergic contact dermatitis to nickel, which manifested as an unusual pustular reaction. Left and right heart catheterization demonstrated no evidence of constrictive physiology, normal coronary anatomy, and normal left ventricular function.

After a discussion of treatment options, the patient preferred surgical explantation over a trial of immunosuppressive therapy given the severe, chronic nature of her chest pain syndrome. She was referred to the cardiothoracic surgery service and underwent uneventful device removal and pericardial patch closure. Intraoperative findings were unremarkable (Figures 1 and 2). Because of concern for potential reaction to sternal wires as previously reported,[2] nonabsorbable sutures were used for sternal closure. Pathologic examination of the tissue adherent to the device showed fibrosis and chronic inflammatory changes without an eosinophilic infiltrate (Figure 3). Her postoperative course was unremarkable and she was discharged to her home on the third postoperative day. At follow-up 1 and 6 mo postoperatively, her symptoms had completely resolved.

Received: December 10, 2007
Accepted with revision: January 11, 2008

Published online in Wiley InterScience. (www.interscience.wiley.com)
DOI:10.1002/clc.20427 © 2009 Wiley Periodicals, Inc.

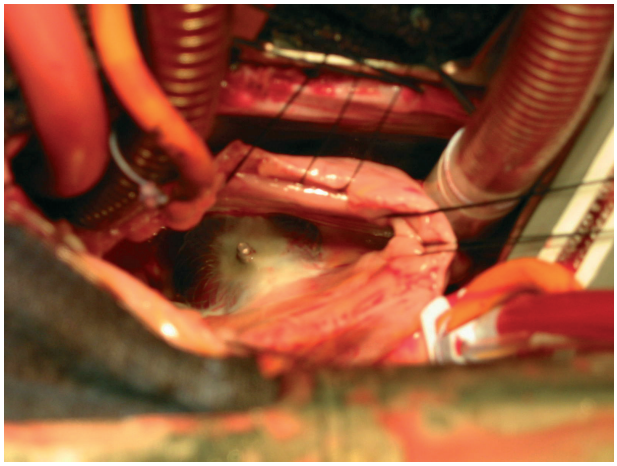

Figure 1. Intraoperative view of Amplatzer atrial septal occluder device. The device was well-seated. There was no evidence of pericarditis. A fibrotic reaction covering the device was evident.

Figure 2. Explanted device.

Discussion

Transcatheter closure of PFOs and atrial septal defects has evolved as the standard of care for amenable defects. Many of the currently available occlusion devices contain nitinol, an alloy developed in the 1960s by Buehler and Wang.[3] Nitinol is now widely used in medical products because of its superelasticity, radiopacity, thermal shape memory properties, and resistance to fatigue and corrosion; it is composed of 45% titanium and 55% nickel. Ries and colleagues demonstrated a systemic rise in serum levels of nickel after device implantation and cautioned that possible biologic side effects might have clinical relevance particularly in patients with nickel hypersensitivity.[4] The incidence of nickel contact allergies in the overall adult population is estimated at 10% with a higher prevalence in women than men.[5]

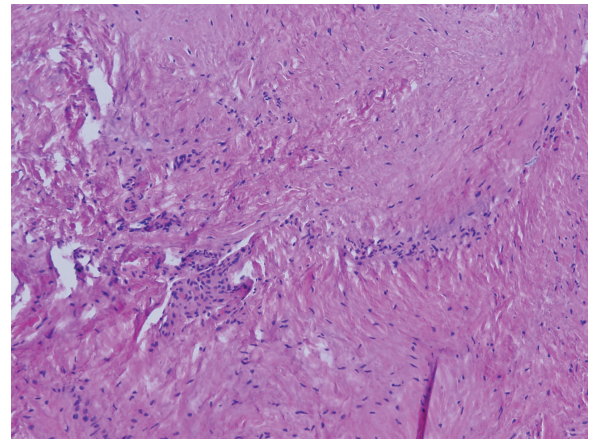

Figure 3. Histopathology of tissue adherent to explanted device. Hematoxylin and eosin stained, magnification x200. Note chronic inflammatory and fibrous changes and lack of eosinophilic infiltrate.

A higher incidence of coronary artery in-stent restenosis[6] and failure of nickel containing orthopedic[7] implants have been reported. To our knowledge this is only the third reference in the literature to a likely nickel allergy to an implanted transcutaneous PFO occlusion device requiring explantation.[1,2] Slavin and colleagues reported a significant *increase* in the incidence of migraine headaches and palpitations in patients undergoing Amplatzer device deployment and who were later found to have nickel allergies,[8] emphasizing the potential relevance even if the devices were not explanted. Lai and colleagues reported a case of likely nickel allergy to an Amplatzer device in which the patient complained of intermittent episodes of substernal chest pressure progressing to severe left scapular discomfort, which was successfully treated with steroids.[9] Also, it is likely that the true incidence of this phenomenon is underreported given its nonspecific and varied manifestations.

Previous reports of systemic allergic reaction to nitinol containing PFO occlusion devices described fever, dyspnea, and dependent edema, signs and symptoms that our patient denied. It is unusual for nickel allergy to present with the onset of chest pain shortly after PFO closure; more typically, the onset of symptoms occurs within the first several wks. As in the prior case report,[1] the histologic findings were not pathognomonic of an allergic reaction. However, given the temporal association of this patient's discomfort and the positive skin patch test a hypersensitivity reaction is the most likely explanation. Patients rarely volunteer metal reactions when asked about known allergies. There is a high prevalence of nickel hypersensitivity and accumulating evidence of adverse sequelae after device implantation in this population.

With ongoing large randomized clinical trials assessing PFO closure for patients with cryptogenic stroke (RESPECT

Published online in Wiley InterScience. (www.interscience.wiley.com)
DOI:10.1002/clc.20427 © 2009 Wiley Periodicals, Inc.

using Amplatzer PFO Occluder, AGA Medical, Plymouth, MN; CLOSURE-1 using StarFlex, NMT Medical, Boston, MA) or migraine headache (PREMIUM using Amplatzer PFO occluder, AGA Medical, Plymouth, MN; ESCAPE using Premere, St. Jude Medical, St. Paul, MN), PFO closure complications involving nickel allergy are expected to become a more prevalent problem. We recommend that metal allergies be specifically and routinely discussed prior to device implantation and that skin patch testing for metals be considered in select cases. Additionally, clinicians should have a low threshold for considering hypersensitivity reaction in patients with unusual postprocedure courses. Finally, in patients requiring device explantation due to nickel hypersensitivity, sternal wires should be avoided.

References

1. Fukahara K, Kazutomo M, Reiss N, Fassbender D, Koerfer R. Systemic allergic reaction to the percutaneous patent foramen ovale occluder. *J Thorac Cardiovasc Surg*. 2003;125:213–214.
2. Dasika UK, Kanter KR, Vincent R. Nickel allergy to the percutaneous patent foramen ovale occluder and subsequent systemic nickel allergy. *J Thorac Cardiovasc Surg*. 2003;126:2112 (letter to the editor).
3. Bueler WJ, Wang FE. A summary of recent research on the nitinol alloys and their application in ocean engineering. *Ocean Eng*. 1968; 1:105–120.
4. Ries MW, Kampmann C, Rupprecht H-J, et al. Nickel release after implantation of the Amplatzer occluder. *Am Hear J*. 2003;145: 737–741.
5. Schafer T, Bohler E, Ruhdorfer S, et al. Epidemiology of contact allergy in adults. *Allergy*. 2001;56:1192–1196.
6. Köster R, Vieluf D, Kiehn M, et al. Nickel and molybdenum contact allergies in patients with coronary in-stent restenosis. *Lancet*. 2000;356:1895–1897.
7. Gawkrodger DJ. Metal sensitivities and orthopedic implants revisited: The potential for metal allergy with the new metal-on-metal joint prostheses. *Br J Dermatol*. 2003;148:1089–1093.
8. Slavin L, Tobis JM, Rangarajan K, et al. Five-year experience with percutaneous closure of patent foramen ovale. *Am J Cardiol*. 2007;99: 1316–1320.
9. Lai DW, Saver JL, Araujo JA, Reidel M, Tobis J. Pericarditis associated with nickel hypersensitivity to the Amplatzer occluder device: a case report. *Cathet and Cardiovasc Intervent*. 2005;66:424–426.

Published online in Wiley InterScience. (www.interscience.wiley.com)
DOI:10.1002/clc.20427

© 2009 Wiley Periodicals, Inc.