PULMONARY ASPERGILLOSIS

With Report of a Case

By H. Scott Van Ordstrand, M.D.

Classification

Pneumomycoses are among the most interesting non-tuberculous chest diseases because of their relative rarity. Aspergillus lung infection is one of the more common forms of mycotic infestation of pulmonary tissue. Of the thirty-seven better-known strains of aspergillus, fumigatus and niger seem to be the only pathogens. Aspergillus fungi are classified as members of the filamentous group and are practically ubiquitous in nature.

Castellani[1] has classified fungi (which may produce lesions simulating pulmonary tuberculosis) as follows:

1. "Yeast-like" fungi	Blastomyces Cryptococcus (torula) Saccharomyces Monilia Endomyces
2. Filamentous fungi	
a. Slender type	Nocardia Anaeromyces Vibriothrix
b. Larger type	Oidium Hemispora
c. Types with characteristic conidial structures, fructifications, etc.	Aspergillus Penicillium Mucor Rhizomucor Acrimoniella Sporotrichum Acladium

History

Pneumomycosis was first described by Hughes Bennett in 1842. In 1853 Rayer and later Gairdner described cases of pulmonary tuberculosis in which the pleurae were invaded by a fungus. Virchow, in 1856, described several cases of aspergillary mycoses of the lungs and bronchi. Dieulafoy, Chautmesse, and Widal in 1890 described clinically several cases of pulmonary aspergillosis occurring in persons who were engaged in fattening pigeons for the Paris market, and they advanced the idea that the infection was a primary one.

In 1897 Renon brought forth a very complete monograph on the subject, experimental as well as clinical. He considered it to be a trade disease among those undertaking the artificial feeding of pigeons and those manipulating hair and hair products. He believed the disease to be rare outside of Paris. The infecting agent he elucidated as asper-

Downloaded from www.ccjm.org on June 6, 2013. For personal use only. All other uses require permission.

gillus fumigatus and rarely, aspergillus niger, spores of which may be mingled with grains, seeds or flour.

Mary Lapham[2] in 1926 reported ten cases of primary pulmonary aspergillosis from an obscure village in the Blue Ridge Mountains, and divided the cases into two groups: the wet or parenchymatous types, and the dry or interstitial types. She also called attention to a definite relation to asthmatic attacks in certain cases. Pinta in 1935 reported asymptomatic cases found in Oklahoma, during a routine chest examination of workers in iron mines. Wheaton's case, a child of thirty months, is the youngest recorded instance, and Virchow's patient, who was seventy-seven years of age, the oldest example.

The genus Aspergillus, first described in 1725 by Micheli, belongs to the family Aspergillaceae, order Aspergillales of class Ascomycetes. It is a regular inhabitant of the soil, at least in America, and is one of the most abundant molds encountered. It has been frequently isolated from cereal products, unmilled grain, hay and other stock feeds. As an agent of disease it selects for its victims chiefly certain species of birds, particularly the pigeon, but also canaries, penguins, ducks and chickens. Among mammals, dogs and cats are said to be insusceptible to its spores, but lesions have been produced experimentally, in rabbits, guinea pigs, monkeys and others.

The majority of writers supports the view that as far as man is concerned, healthy individuals are relatively immune to aspergillus[3]. It could hardly be otherwise if the race were to survive, in view of the boundless opportunity for contact with this organism in nature. Accordingly, because man is susceptible to the disease caused by this organism, one is led to recognize the possibility of particular predisposing conditions.

As mentioned before, the classic instances of pulmonary aspergillosis in man are found in certain occupations which involve prolonged and intimate contact with grains or with birds. Farmers, feed-mill workers and threshers are prone to this infection. The most frequently quoted example is that of the pigeon-stuffers of the suburbs of Paris who, with their own mouths, cram the beaks of the birds with a mixture of grains and water, many workers averaging from four to six thousand such gavages a day. Some of them develop a rather severe type of mycotic pseudo-tuberculosis with the double hazard of infection from the grain and from the infected birds.

Certain dusts are important sources of infection, such as that produced by sponge-cleaners who beat the dried sponges, and by the wigmakers of Paris who comb the hair with rye meal to remove the fat, the air in some of these establishments being practically unbreathable. In all of these instances it is probable that massive dosage, often repeated,

Downloaded from www.ccjm.org on June 6, 2013. For personal use only. All other uses require permission.

is the principal factor in the pathogenesis of the disease. Symptoms of infection in such cases may be long in making their appearance, and, even in cases severely afflicted, may disappear completely upon removal of the patient to another environment and occupation.

Under other circumstances, the factor of constitutional or of local predisposition is the determining one, and this has brought about the concept of "secondary aspergillosis." Uncontrolled diabetes has been cited as predisposing to pulmonary aspergillosis with massive necrosis of the lung. Fuerberinger has listed carcinoma, dysentery, enteritis, cirrhosis of the liver, and sepsis as additional predisposing factors. Grippe in a patient with latent pulmonary aspergillosis has been shown to excite a rapidly advancing necrotizing lesion. Many writers, particularly Wahl[4], have emphasized the frequency of this disease as a secondary invader in tuberculosis, and vice versa. Allergists are well aware of the frequency of aspergillus sensitivity in asthma and allergic rhinitis, with failure to cure often occurring if treatment does not include desensitization to these offenders.

Most pathologists describe the disease as roughly falling into two characteristic groups, a "superficial" and a "deep" form. In the former are included cases of bronchitis, catarrhal or asthmatoid, which run a fairly benign course. The "deep" or ulcerative type depends on the ability of the endotoxins of the mold to cause necrosis of lung tissue analogous to caseation as in tuberculosis. These distinctions between the two types are relative and vary also with the degree of the allergic component of the inflammatory response of the tissues or their disposition to undergo fibrosis. Experimentally, using rabbits, Henrici[5] has demonstrated well the lesions of the Aspergillus fumigatus and has shown that they have a high and constant virulence for laboratory animals. When spores from a young culture were inoculated intravenously, the type of disease produced varied with the dosage. With large doses, the animals died within a day or two, presenting only hemorrhages and necrosis about the germinating spores which had lodged in various tissues. With smaller doses, the animals survived two to seven days, with resulting miliary abscesses. With still smaller doses, the animals survived ten days or longer, the lesions developing into tubercles, resembling those produced by the tubercle bacillus.

Symptoms

The symptoms of pulmonary aspergillosis may be of acute or chronic nature. The acute form assumes clinically the picture of bronchitis or pneumonia. The bronchitic type has its onset in a manner not unlike the ordinary upper respiratory infections or common cold. The symptoms persist, however, with low grade fever and paroxysms of coughing productive of a minimal amount of tenacious mucoid sputum. The physical findings in this group are usually very meager, showing at most only a

Downloaded from www.ccjm.org on June 6, 2013. For personal use only. All other uses require permission.

few coarse hilar râles. The pneumonic form of acute onset simulates other pneumonias with the associated dyspnea, cyanosis and chills and moderate degrees of fever. The dyspnea may be most marked nocturnally, and occurs in paroxysms as does the cough. In acute cases, hemoptysis may be an early symptom, followed by fatigue, anorexia and loss of weight. Night sweats may be a very prominent symptom.

The course of chronic primary aspergillosis is similar to that of chronic pulmonary tuberculosis. There may be a history of recurrent attacks of pleurisy extending over a period of years. Symptoms of malaise, morning cough and undernutrition may have been present for a long duration of time. Cough with progressive dyspnea on exertion becomes more distressing as the disease progresses. The cough becomes more productive and the sputum more purulent as areas of parenchymal excavation occur.

Most authorities agree that the changes produced in the lungs by early aspergillosis, and for all pneumomycoses, cannot be differentiated roentgenographically from pulmonary tuberculosis. There may be no demonstrable lesion in early cases. When roentgen changes do occur, the infiltration is prone to be basal[6] in location, thus further confusing the roentgenologist. Many and varied roentgen appearances have been described. Probably the more nearly typical roentgen picture is the increase of hilar shadows with radiating spider-web appearance (as seen in figure 1 of the case report), which Sampson has appropriately called the "sun-burst" effect. Kindberg, Parat and Netter[7] have reported a case resembling a tumor which they have classified as primary pseudo-cancerous aspergillosis.

The possibility of pulmonary mycosis should be considered in everyone having pulmonary symptoms. The diagnosis of aspergillosis is made only after finding the fruiting spores in the sputum along with careful exclusion of all other possible etiologic factors. The fruiting heads of the fungus must be found on smear or hanging drop examination. Reproduction of the lesion with animal inoculation and with re-isolation of the fungus is of added support in establishing the diagnosis. A positive agglutination of the patient's serum on the suspected type of aspergillus, as well as a positive skin test with a stock extract or autogenous vaccine of the fungus will be added presumptive evidence. A positive culture alone is not considered sufficient evidence to warrant the diagnosis.

Various agents have been used in the treatment of pulmonary aspergillosis. Potassium iodide is time-honored as a remedy for this disease, as it is for many of the other mycoses. David Smith has emphasized desensitization to an extract of the fungus when marked skin sensitivity is found, prior to the use of iodides. Some men feel that inhalation of

Downloaded from www.ccjm.org on June 6, 2013. For personal use only. All other uses require permission.

ethyl-iodide is preferable to the oral use of iodides. Arsenicals, especially in the form of neoarsphenamine, intravenously, have proved to be very efficacious in some hands. Some also advocate the added use of intramuscular bismuth. Thymol is gaining wider use and may prove to be of considerable value. The multiple therapy employed in this disease emphasizes the lack of a "specific" drug.

Case Report

A thirty-six year old nurseryman came to the Clinic on October 26, 1939, with the complaint of a "chest cold which will not clear up." He described the onset three weeks previously as consisting of nasal obstruction with rhinitis and sore throat. Soon after the onset, he began to note daily fever and general malaise in the early evening, persisting through most of the night, and associated during the night hours with paroxysms of coughing and drenching sweats. The temperature would average 102° Fahrenheit at midnight. The coughing was productive of only a small amount of thick, tenacious, mucopurulent sputum. Anorexia was noted in the three days prior to entering the Clinic. There had been a six pound weight loss.

Nothing of significance was recorded in the past, personal and family history and the system review was non-contributory. The only significant finding on general physical examination was the presence of a few coarse crepitant râles near the hilar regions in both lung fields. The morning temperature was 98.6° Fahrenheit. Nose and throat examination with irrigations of the antra revealed no significant findings. Sinus roentgenograms revealed a small cyst in the left antrum. The remainder of the general physical examination revealed entirely normal findings.

Stereoroentgenograms of the chest (figure 1) revealed a proliferative infiltration of moderate degree extending out from each hilum into the middle and lower lung fields. This infiltration had much the appearance of spider-web or sun-burst pattern.

The intitial sputum specimen revealed numerous sprouting mycelial spore formations of aspergillus fumigatus on unstained wet coverslip preparation. These were better demonstrated in hanging drop after emulsification and digestion of equal parts of the sputum with equal parts of 4 per cent sodium hydroxide. Implantation of the sputum on Wort agar revealed growths of aspergillus fumigatus in all tubes, one tube containing a pure culture. Sputum examination was negative on smears and cultures for all other pathogenic organisms. Rabbits, inoculated intravenously with one cc. of sputum revealed multiple visceral mycotic nodules when autopsied in seventeen days. Unstained and stained smears, after crushing these nodules, revealed mycelial formations. Cultures of these mycotic abscesses produced a pure growth of the Aspergillus fumigatus.

Downloaded from www.ccjm.org on June 6, 2013. For personal use only. All other uses require permission.

Skin tests on the patient, using both a stock as well as autogenous extract of the Aspergillus fumigatus, were positive. The tuberculin test was negative. A sera-agglutination of the fumigatus spores was attempted with a questionable result, due to the tendency for the spores to clump together in any solution.

In the other laboratory studies, the blood sugar and blood counts were normal and the Wassermann and Kahn reactions of the blood were negative. Urine specimens revealed a one plus degree of albumin, but were

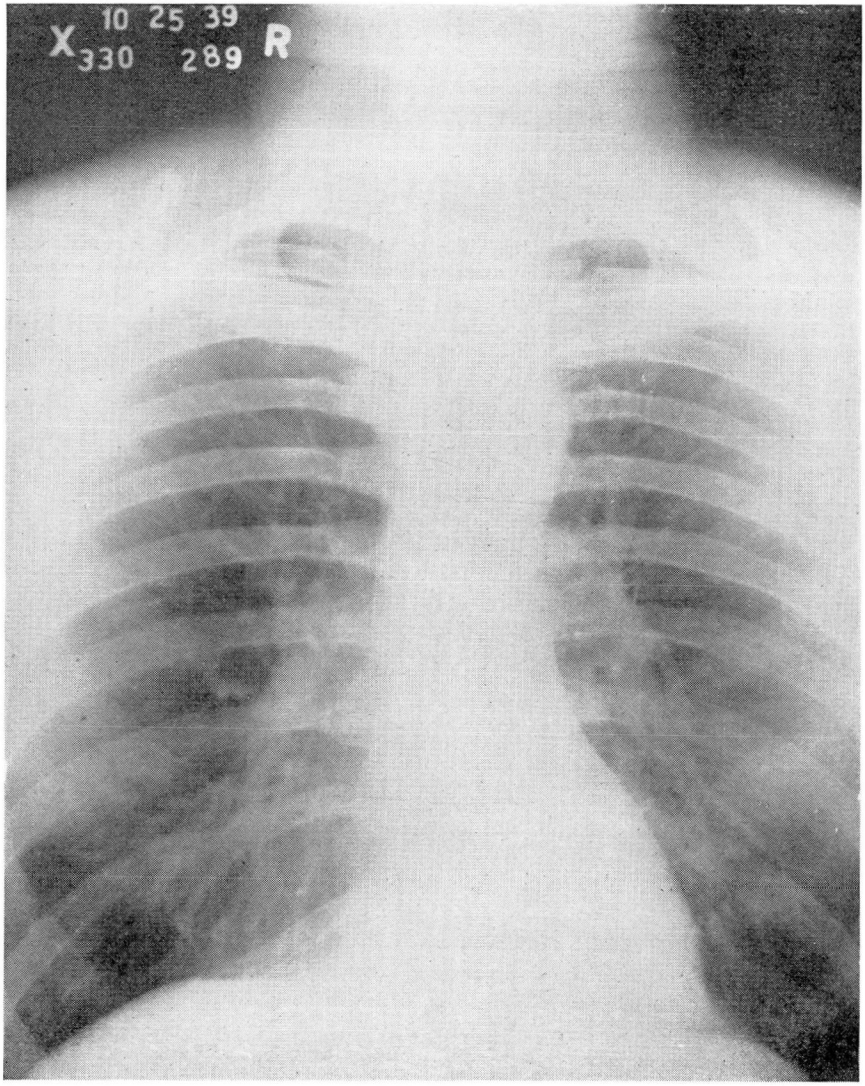

FIGURE 1: Roentgenogram taken at time of initial examination, showing the parenchymal infiltration extending from each hilum.

Downloaded from www.ccjm.org on June 6, 2013. For personal use only. All other uses require permission.

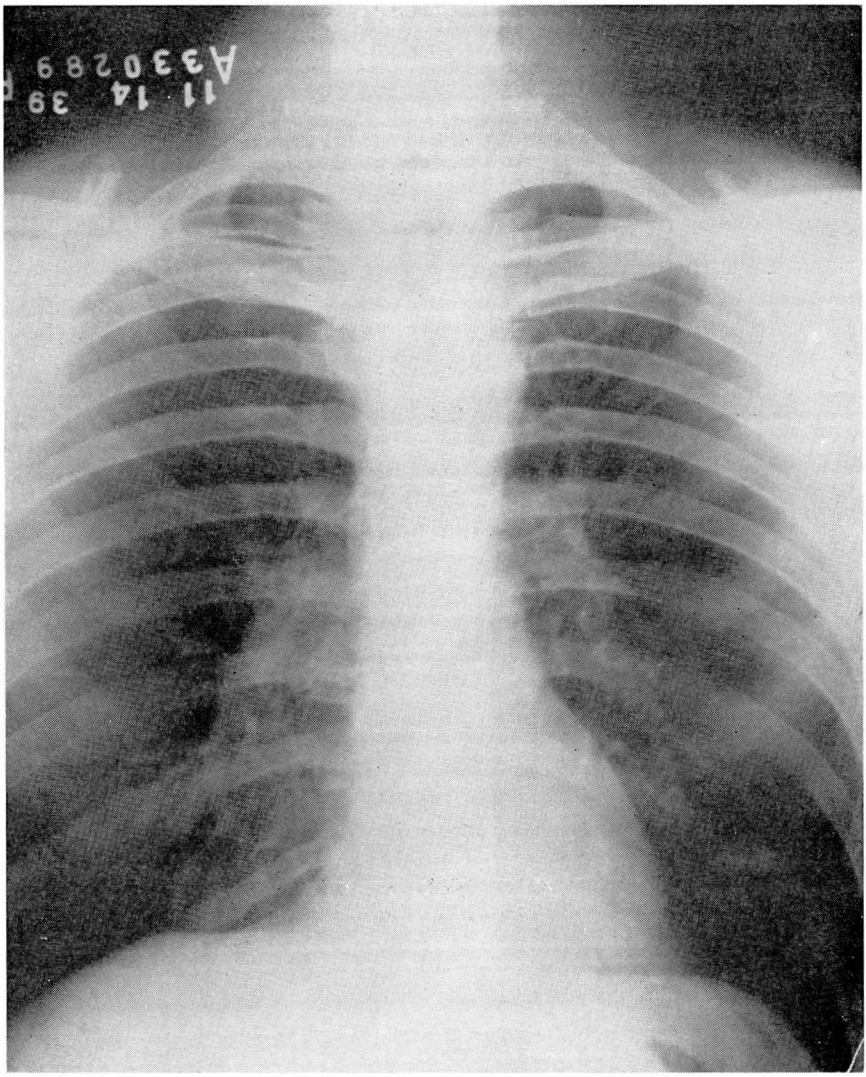

FIGURE 2: Roentgenogram taken twenty days after institution of treatment, showing a considerable clearing of the infiltration.

otherwise negative. The erythrocyte sedimentation rate was elevated to three times the normal. Undulant fever immunity was evidenced by a positive skin test to bacillus abortus, negative agglutination and the presence of 100 per cent phagocytosis in the opsonocytophagic index determination.

Treatment consisted of oral iodides and thymol. The patient became symptom-free within two weeks time and has remained so to date. A chest film (figure 2), taken nearly three weeks after treatment was instituted, revealed much clearing of the parenchymal process.

Downloaded from www.ccjm.org on June 6, 2013. For personal use only. All other uses require permission.

Summary

Pneumomycosis should be considered as a possibility in anyone having pulmonary symptoms. The history and development of our knowledge concerning aspergillosis is a fascinating subject.

The symptomatology, physical and roentgen findings are discussed. In diagnosis, the necessity of demonstrating the active fruiting heads of the fungus as well as the need of careful exclusion of other similar diseases, is stressed.

A case of Aspergillosis fumigatus of the acute "bronchitic" type is presented.

References

1. Castellani, A.: Certain bronchomycoses which may simulate pulmonary tuberculosis, J. Trop. Med., 32:1-17, 1929.
2. Lapham, M.: Aspergillosis of the lungs and its association with tuberculosis, J.A.M.A., 87: 1031-1033, (September 25) 1926.
3. Moolten, Sylvan E.: A case of primary broncho-pulmonary aspergillosis, J. Mt. Sinai Hosp., 5:29-35, (May-June) 1938.
4. Wahl, E. F.: Pulmonary aspergillosis, Tr. Am. Therap. Soc., 36:35-38, 1936.
5. Henrici, A. T.: Endotoxin from Aspergillus fumigatus, J. Immunol., 36:319-338, (April) 1939.
6. Van Ordstrand, H. S.: The diagnosis of basal tuberculosis, Med. Clin. of North America, (to be published March 1940).
7. Leon-Kindberg, M., Parat, H. and Netter, H.: A case of mycotic tumor due to primary pseudocancerous aspergillosis, Presse Med., 44:1834-1837, (November 14) 1936.

Downloaded from www.ccjm.org on June 6, 2013. For personal use only. All other uses require permission.