See related commentary on pg 1213

Deletion of the Major Bullous Pemphigoid Epitope Region of Collagen XVII Induces Blistering, Autoimmunization, and Itching in Mice

Tiina Hurskainen[1,2,8], Nina Kokkonen[1,2,8], Raija Sormunen[3,4], Joanna Jackow[5], Stefanie Löffek[6], Raija Soininen[3,7], Claus-Werner Franzke[6], Leena Bruckner-Tuderman[6] and Kaisa Tasanen[1,2]

Bullous pemphigoid (BP) is the most common autoimmune subepidermal blistering skin disease with a characteristic of pruritus and blistering. BP patients carry inflammation-triggering autoantibodies against the collagen XVII (ColXVII, also known as BP180) juxtamembraneous extracellular noncollagenous 16A (NC16A) domain involved in ectodomain shedding. Deletion of the corresponding NC14A region in a genetically modified mouse model (ΔNC14A) decreased the amount of ColXVII in skin, but it did not prevent ectodomain shedding. Newborn ΔNC14A mice had no macroscopic phenotypic changes. However, subepidermal microblisters, rudimentary hemidesmosomes, and loose basement membrane zone were observed by microscopy. ΔNC14A mice grow normally, but at around 3 months of age they start to scratch themselves and develop crusted erosions. Furthermore, perilesional eosinophilic infiltrations in the skin, eosinophilia, and elevated serum IgE levels are detected. Despite the removal of the major BP epitope region, ΔNC14A mice developed IgG and IgA autoantibodies with subepidermal reactivity, indicating autoimmunization against a dermo-epidermal junction component. Moreover, IgG autoantibodies recognized a 180-kDa keratinocyte protein, which was sensitive to collagenase digestion. We show here that ΔNC14A mice provide a highly reproducible BP-related mouse model with spontaneous breakage of self-tolerance and development of autoantibodies.

Journal of Investigative Dermatology (2015) **135,** 1303–1310; doi:10.1038/jid.2014.443; published online 6 November 2014

INTRODUCTION

Chronic pruritus is a major symptom in numerous dermatological diseases (Metz and Ständer, 2010; Garibyan *et al.*, 2013). In the most common autoimmune subepidermal blistering skin disease, bullous pemphigoid (BP), patients suffer from pruritus for weeks to months, sometimes even years, before development of other symptoms (Di Zenzo *et al.*, 2012; Schmidt and Zillikens, 2013; Nishie, 2014; Schmidt *et al.*, 2014). BP is characterized by the presence of autoantibodies against structural components of hemidesmosomes, with transmembrane collagen XVII (ColXVII, also known as BP180) being the main target. Nearly all BP patients have autoantibodies against the extracellular noncollagenous 16A (NC16A) domain of ColXVII (Giudice *et al.*, 1993; Schmidt and Zillikens, 2013; Nishie, 2014). In addition to harboring multiple epitopes to BP autoantibodies, the NC16A domain has a fundamental role in ColXVII trimerization (Franzke *et al.*, 2003; Van den Bergh and Giudice, 2003; Franzke *et al.*, 2005). The NC16A domain is also the main cleavage area for shedding proteases that constitutively release a soluble ectodomain of ColXVII from the cell surfaces (Franzke *et al.*, 2009; Nishie *et al.*, 2010).

In BP, autoantibodies trigger an inflammation process resulting in the destruction of hemidesmosomes and dermal–epidermal separation (Ujiie *et al.*, 2010b; Di Zenzo *et al.*, 2012). Clinically, BP presents typically with tense blisters and erythema, frequently in conjunction with urticarial plaques (Schmidt and Zillikens, 2013). The most important diagnostic method for BP is the direct immunofluorescence (IF) staining of perilesional skin biopsy showing subepidermal linear IgG and/or complement (C)3 staining at the dermo–epidermal junction (DEJ) (Di Zenzo *et al.*, 2012; Schmidt and Zillikens, 2013). In addition, IgE-class autoantibodies and elevated serum IgE levels are observed in a subgroup of BP patients

[1]*Department of Dermatology, University of Oulu, Oulu, Finland;* [2]*Medical Research Center Oulu (MRC Oulu), Oulu University Hospital, Oulu, Finland;* [3]*Biocenter Oulu, University of Oulu, Oulu, Finland;* [4]*Department of Pathology, University of Oulu, Finland and Oulu University Hospital, Oulu, Finland;* [5]*Laboratory of Genetic Skin Diseases, Inserm UMR1163 and Imagine Institute of Genetic Diseases, Paris, France;* [6]*Department of Dermatology, University Medical Center Freiburg and Freiburg Institute of Advanced Studies, University of Freiburg, Freiburg, Germany and* [7]*Biocenter Oulu, Faculty of Biochemistry and Molecular Medicine, University of Oulu, Oulu, Finland*

[8]*The first two authors contributed equally to this work.*

Correspondence: Kaisa Tasanen, Department of Dermatology, Medical Research Center Oulu, University of Oulu, Aapistie 5A, OULU FIN-90220, Finland. E-mail: kaisa.tasanen@oulu.fi

Abbreviations: BP, bullous pemphigoid; ColXVII, collagen XVII; DEJ, dermo–epidermal junction; IF, immunofluorescence; NC, noncollagenous; WT, wild type

Received 7 July 2014; revised 9 September 2014; accepted 24 September 2014; accepted article preview online 13 October 2014; published online 6 November 2014

© 2015 The Society for Investigative Dermatology

(Fania *et al.*, 2012). Histological examination of lesional skin reveals subepidermal blisters with inflammatory infiltration of eosinophils and lymphocytes in the upper dermis (Di Zenzo *et al.*, 2012; Schmidt and Zillikens, 2013; Nishie, 2014).

Previously developed animal models on BP rely on passive transfer of autoantibodies or recombinant peptides to neonatal (Liu *et al.*, 1993; Nishie *et al.*, 2007; Liu *et al.*, 2008) and adult mice (Hirose *et al.*, 2011; Oswald *et al.*, 2012). Injection of autoantibodies or repeated immunization induces skin blistering and deposition of IgG and C3 on the DEJ. In the active mouse model for BP, ColXVII humanized mice produce continuously anti-human ColXVII antibodies and develop blisters and erosions on their skin in addition to typical immunopathological features of BP (Ujiie *et al.*, 2010a). None of the previous mouse models are reported to have itching.

To better understand the multiple functions of the human NC16A domain of ColXVII, we have generated a genetically modified mouse line carrying a deletion in the corresponding NC14A region of murine ColXVII (ΔNC14A mice). Newborn and adult ΔNC14A mice have no obvious phenotypic changes distinct from the wild-type (WT) ones until the age of 2–3 months when they develop itch and begin to scratch. We show here that ΔNC14A mice have subepidermal microblisters and immunopathological findings similar to BP patient samples. Thus, the phenotype of ΔNC14A mice has features of both inherited (spontaneous blisters) and acquired (pruritus, blistering, and development of autoantibodies) bullous skin disease.

RESULTS

Generation of ΔNC14A mice

To generate the ΔNC14A mouse line with a deletion of exon 18, *Col17a1* knockout mice (Hurskainen *et al.*, 2012) were bred with a *Cre* recombinase–carrying mouse strain (Figure 1a). The deletion of exon 18 of *Col17a1* gene led to the depletion of 72 amino acids (aa) in the NC14A domain (aa 498–569 out of 498–573; Li *et al.*, 1993), which was detected in immunoblotting of the skin extracts as a decrease of about 10 kDa in molecular weight and loss of signal with the domain–specific antibody (Figure 1b). Interestingly, despite the deletion of the region containing physiological cleavage sites (aa 514–526 in human; Nishie *et al.*, 2010), shed ectodomain was detected in the skin extracts of ΔNC14A mice (EC-7 in Figure 1b).

ColXVII protein levels in skin extracts were quantified by immunoblotting and densitometric analysis. ΔNC14A mouse skin contains on average about half the amount of ColXVII found in WT mice, with large variation between individuals (Figure 1c). In quantitative real-time PCR analysis of ColXVII mRNA levels, no differences between ΔNC14A and WT mouse skin (mean 0.93-fold vs. 1.0) were observed, nor were any major differences detected in the expression levels of proteins that interact with ColXVII, e.g., integrin β4, laminin γ2, and keratins 5, 10, and 14 (data not shown).

ΔNC14A mice have subepidermal blisters and develop itching

Newborn ΔNC14A mice have no obvious phenotype distinct from WT. Male and female ΔNC14A pups are born in equal ratios. They grow normally but begin to scratch later (Figure 2a and b; Supplementary Movie S1 online), typically (43%) at the age of 10–16 weeks (Figure 2e). The scratching is very intense (Supplementary Movie S1 online). Among male mice, 31 (62%) out of 50 mice that were allowed to age up to 1 year began to scratch themselves, whereas 43 (83%) out of 52 female mice were scratching. Only 19% of ΔNC14A mice reached the age of 1 year without scratching. However, a few developed itching later. Simultaneously with scratching, ΔNC14A mice develop large erosions (Figure 2b–d) that are mostly covered by crusts on the nape of the neck, ears, snout, and tail. In some cases, erosions were also found on paws (Figure 2d). In addition, ΔNC14A mice appear to gray early, their fur is thinner than that of their WT littermates (Figure 2a–d), and some mice carry patchy fur or even total hair loss.

Histopathological analysis revealed subepidermal microblisters in the skin of newborn ΔNC14A mice (Figure 3b), whereas none were detected in newborn WT skin (Figure 3a). In the perilesional skin of scratching mice, vacuolization in the DEJ, hyperkeratosis, thickening of the epidermis, and hyperproliferation of fibroblasts were observed (Figure 3c and d).

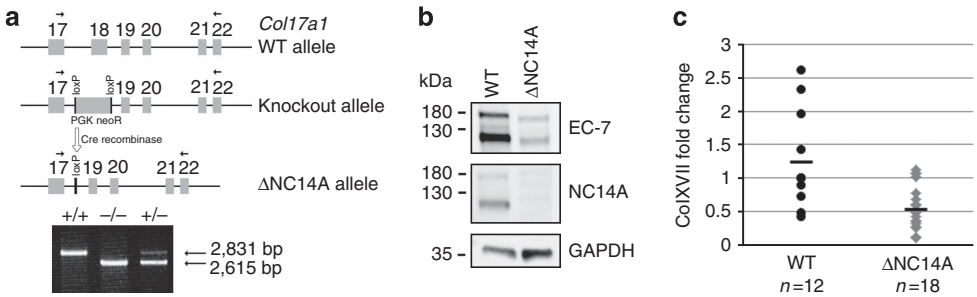

Figure 1. Generation and characterization of ΔNC14A mice. (**a**) *Cre* recombination removes the loxP-flanked *PGK-neoR* cassette, and the reading frame is restored in the targeted *Col17a1* locus lacking the 216-bp exon 18. Exons are marked as rectangles and primers with arrows. Bottom: genomic DNA PCR products. (**b**) Immunoblotting of skin extracts of adult mice. The domain–specific antibody NC14A revealed the absence of the NC14A domain. EC-7 binds to the extracellular domain and shows lower molecular weight of ColXVII in the ΔNC14A mouse sample. A shed ectodomain, approximately 110–120 kDa, was detected in both WT and ΔNC14A skin. GAPDH was used as a loading control. (**c**) Relative ColXVII protein levels quantified from immunoblots showed variation between individuals. Bars, mean values. ColXVII, collagen XVII; NC, noncollagenous; WT, wild type.

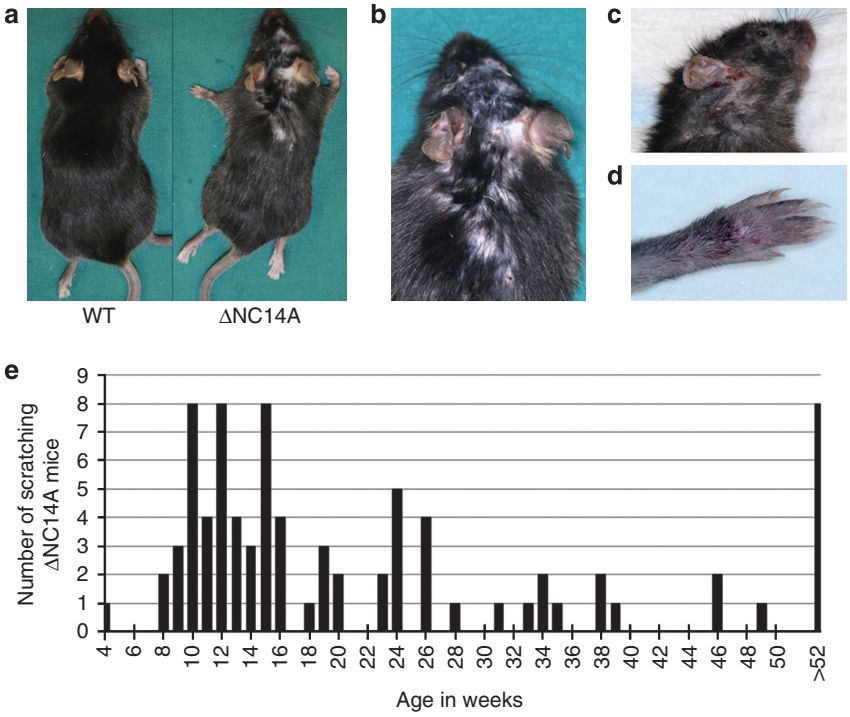

Figure 2. Appearance of the ΔNC14A mice. (**a**) The fur of ΔNC14A mice appears to turn gray, and it is thinner than the fur of the WT mice at the same age (13 weeks). (**b**–**d**) Because of scratching, ΔNC14A mice develop large erosions and crusts in their skin. Symptomatic skin is also seen on the ears (**c**) and paws (**d**) of ΔNC14A mice (**b** = 13, **c** = 20, **d** = 9 weeks). (**e**) The number of mice in time point (age in weeks) when scratching was initiated. The age when mice were observed to start scratching was typically 10–16 weeks ($n = 39$). In total, 82 ΔNC14A mice out of 102 were detected to scratch at varying age, a few ($n = 8$) not until >52 weeks old. NC, noncollagenous; WT, wild type.

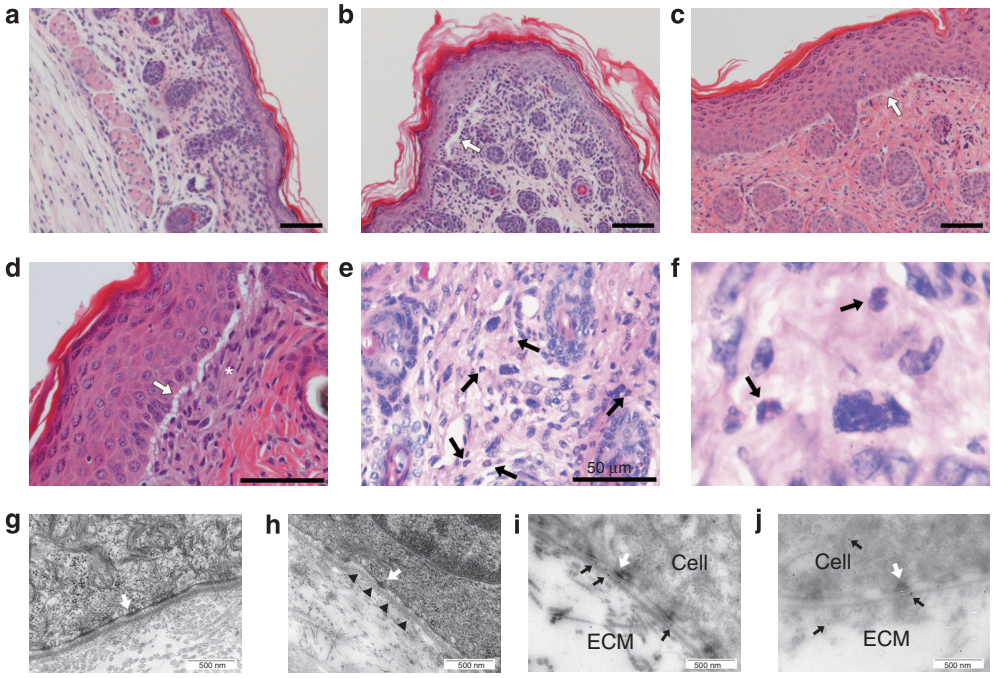

Figure 3. Histopathological and ultrastructural analysis of skin. (**a**–**f**) Hematoxylin–eosin-stained skin sections. (**a**) Newborn WT skin. (**b**) Subepidermal microblisters (white arrow) in the skin of the newborn ΔNC14A mouse. (**c**–**f**) Thickening of the epidermis, subepidermal blistering (white arrows), hyperkeratosis, and eosinophils (black arrows), as well as hyperproliferation of fibroblasts (asterisk), were detected in the perilesional skin of scratching ΔNC14A mice. Scale bars = 50 μm. (**g**, **h**) Transmission electron microscopy of adult WT (**g**) and ΔNC14A (**h**) mouse skin. (**h**) Malformed hemidesmosomes (white arrows) and basement membrane zone (arrowheads) in the skin of adult ΔNC14A mouse. (**i**, **j**) Immunoelectron microscopy with ectodomain-specific antibody (EC-7) showed ColXVII localization (black arrows) in hemidesmosomes and at the dermo-epidermal junction in WT (**i**) and ΔNC14A (**j**) skin. Scale bars = 500 nm. ColXVII, collagen XVII; ECM, extracellular matrix; NC, noncollagenous; WT, wild type.

Healthy skin of adult ΔNC14A mice, remote from the scratching areas, *e.g.*, abdominal skin, did not differ from WT skin (data not shown).

Ultrastructural analysis of the healthy skin from newborn and adult ΔNC14A mice revealed several changes in the DEJ. ΔNC14A mice had rudimentary and malformed hemidesmosomes (Figure 3h). The number of hemidesmosomes also appeared to be lower than that in WT skin (Figure 3g and h). The basement membrane of ΔNC14A mice was loosened, and the space between the basement membrane and the basal keratinocytes was wider than in WT skin (Figure 3g and h). In addition, anchoring fibrils in ΔNC14A skin were short, unorganized, and, in some cases, abnormally clustered (Figure 3h).

Immunoelectron microscopic analysis with ectodomain-specific antibody showed localization of ColXVII in hemidesmosomes and basement membrane zone in both WT and ΔNC14A mouse skin (Figure 3i and j). Similarly to immunoblotting findings, more labeling was detected in WT skin relative to ΔNC14A mouse skin, supporting the difference in the total amount of ColXVII protein.

Inflammatory factors in blood and skin of ΔNC14A mice with itch

Infiltration of eosinophils and mast cells was seen in perilesional and lesional skin samples of ΔNC14A mice (Figure 3e and f). However, no statistically significant changes in the number of mast cells or their degranulation were observed in the ΔNC14A mouse skin compared with the WT samples (data not shown). Total blood cell count revealed increased number of monocytes, neutrophils, eosinophils, and basophils in the circulation of ΔNC14A mice (Supplementary Table S1 online).

IgG, IgG_1, and IgE protein levels were markedly increased in the healthy skin of itching ΔNC14A mice, but variation between individuals was high (Figure 4a–c). ΔNC14A mice without itch had IgG, IgG_1, and IgE levels comparable to the WT mice.

Direct IF with anti-IgG and anti-IgG_1 showed linear deposition in the DEJ of healthy skin of scratching ΔNC14A mice (IgG 11/14, IgG_1 9/11 positive; Figure 5b and c), which was not detected in either WT (Figure 5a) or newborn ΔNC14A mouse skin (data not shown). Direct IF also revealed linear IgA deposition in the DEJ of the ΔNC14A mouse skin (Figure 5d), whereas IgE deposition was not detected (data not shown). Fragmented ColXVII-specific staining in ΔNC14A skin (Figure 5b–d) further supports immunoblotting results (Figure 1c) of decreased amounts of ColXVII.

To analyze circulating autoantibodies, sera from scratching ΔNC14A mice were collected at the time of euthanasia (see Figure 2e). Indirect IF of frozen skin sections with sera and anti-IgG resulted in staining of the DEJ in the WT skin in 9 out of 13 tested cases (Figure 5e). The serum-specific staining colocalized with ColXVII-specific staining. Both the ΔNC14A mouse sera and ColXVII antibodies reacted to the epidermal side of salt-split WT mouse skin (Figure 5f). IgG deposition was not detected in direct or indirect IF with nonscratching ΔNC14A samples (data not shown). Moreover, serum IgE content analyzed by ELISA revealed significantly increased total IgE levels in the samples of ΔNC14A mice (Figure 4d). Neither IgE deposits nor serum-specific IgE labeling was detected in direct or indirect IF (data not shown).

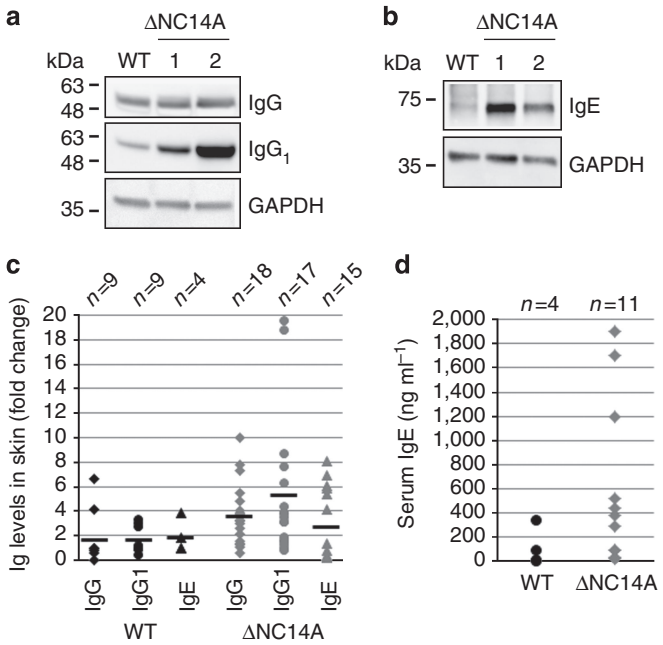

Figure 4. Increased immunoglobulin levels in ΔNC14A mice. (**a**, **b**) Skin extracts of WT and ΔNC14A mice were analyzed by immunoblotting with anti-IgG, anti-IgG_1, and anti-IgE-specific antibodies. GAPDH was used as a loading control. (**c**) Quantified immunoglobulin levels in skin compared with one WT sample and reported as fold-change values. (**d**) Total IgE concentration in serum samples analyzed by ELISA. NC, noncollagenous; WT, wild type.

Finally, scratching mouse sera were used to detect antigens in WT keratinocyte extract by immunoblotting (Figure 6a). Anti-IgG as a secondary antibody revealed a protein with a molecular weight of about 180 kDa that was eliminated with collagenase treatment. ColXVII-specific antibody gave a similar result, whereas WT (Figure 6a) and nonscratching ΔNC14A sera (data not shown) did not react with the 180-kDa protein. Scratching mice sera and anti-IgG bound also to the 180-kDa protein immunoprecipitated with ColXVII-specific antibody from WT mouse keratinocytes (Figure 6b).

DISCUSSION

Besides acting as the major pathogenic epitope for BP, the NC16A domain has a fundamental role in ColXVII trimerization and ectodomain shedding (Franzke *et al.*, 2009; Nishie *et al.*, 2010). Here, we have created a genetically modified mouse model with a deletion in the corresponding NC14A domain and demonstrate that, despite this modification, the ectodomain of ColXVII is shed *in vivo* and ColXVII is localized correctly to the cell surface. The most interesting finding in this study is that the majority of ΔNC14A mice begin to scratch themselves at the age of 10–16 weeks. Scratching is considered a consequence of itching, as it localizes to the same areas as scratching owing to histamine injection (Shimada and LaMotte, 2008). Even though pruritus is a

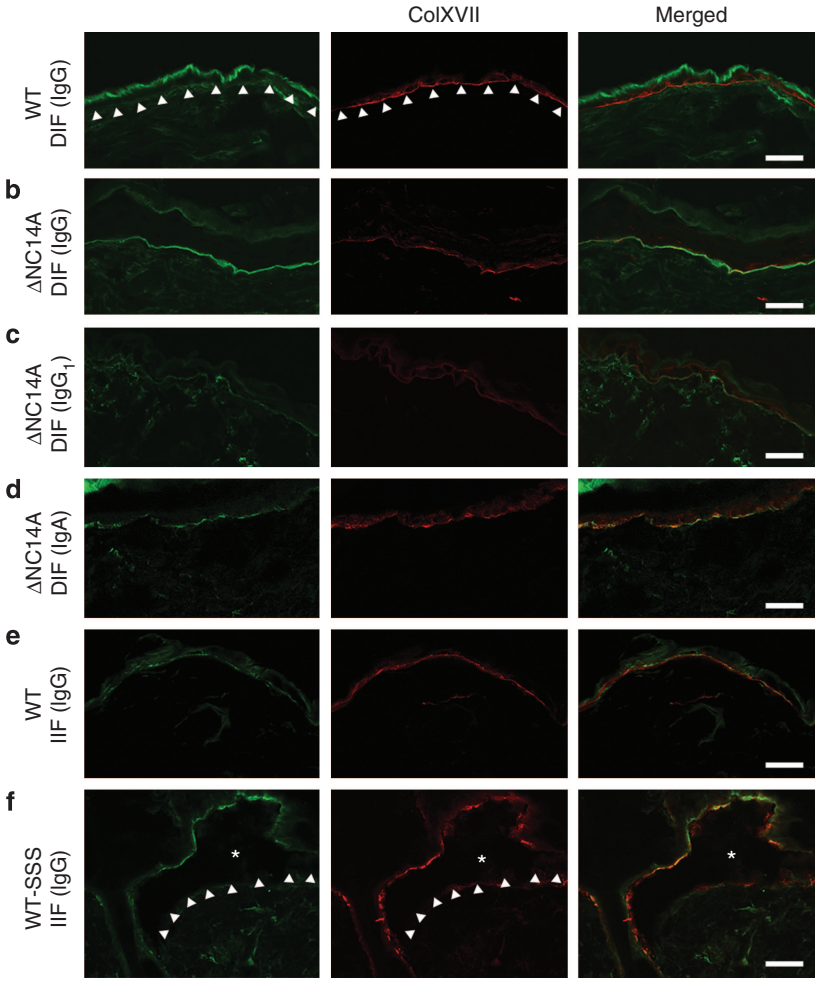

Figure 5. Scratching ΔNC14A mice have circulating autoantibodies. (**a**–**c**) Frozen skin sections were double-immunostained with anti-IgG, anti-IgG_1, and ColXVII-specific antibody (EC-7). IgG-specific staining was not seen in WT (age 9 weeks) (**a**), whereas linear IgG and IgG_1 deposition was detected in the DEJ of ΔNC14A skin (**b**, **c**) (**b** = 8 weeks, **c** = 35 weeks). (**d**) Direct IF (DIF) with anti-IgA showed similar DEJ deposition in the skin of ΔNC14A mice (8 weeks) as IgG. (**e**, **f**) Indirect IF (IIF) with scratching ΔNC14A mouse serum (**e** = 13 weeks, **f** = 8 weeks) and anti-IgG showed linear staining in the DEJ and colocalized with ColXVII in WT untreated (**e**) and salt-split (**f**) skin, both signals on epidermal side of the blister (asterisk). Arrowheads, basement membrane zone. Scale bars = 20 μm. ColXVII, collagen XVII; DEJ, dermo–epidermal junction; IF, immunofluorescence; NC, noncollagenous; *SSS*, salt-split skin; WT, wild type.

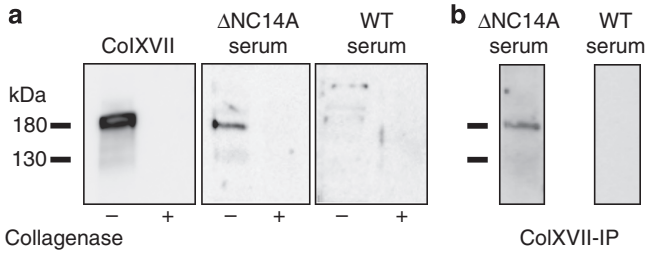

Figure 6. Antigen detection with scratching ΔNC14A mouse sera. (**a**) WT and scratching ΔNC14A mouse sera (age 62 weeks) were used as primary antibodies in immunoblotting to detect the autoantigen in WT mouse keratinocytes. Anti-mouse IgG was used as a secondary antibody. A 180-kDa protein was detected with scratching mouse serum and ColXVII-specific antibody (EC-7) but not with WT serum. The target protein was not detected in collagenase-treated cell extract. (**b**) ColXVII-specific antibody (EC-7) was used in the immunoprecipitation of WT keratinocyte extract. The immunoprecipitated 180-kDa protein was detected with scratching ΔNC14A mouse serum (age 62 weeks) and anti-IgG but not with WT serum. ColXVII, collagen XVII; NC, noncollagenous; WT, wild type.

prominent symptom of BP, to the best of our knowledge, none of the previous experimental BP models have itch as a manifestation (Leighty *et al.*, 2007; Ujiie *et al.*, 2010b; Nishie, 2014). Simultaneously with itching and scratching, erosions and crusts developed in the skin of ΔNC14A mice. Blistering was not observed, although subepidermal microblistering was detected in skin histology. Similar crusted erosions without visible blisters, as well as thickening of the epidermis, hyperkeratosis, and accumulation of eosinophils in skin biopsies, have previously been described in a BP model with repetitive peptide immunization of immunocompetent adult mice (Hirose *et al.*, 2011). On the other hand, blistering or epidermal detachment by gentle friction has been detected in BP models with passive transfer of autoantibodies or immune cells (Liu *et al.*, 1993; Nishie *et al.*, 2007; Ujiie *et al.*, 2010a; Chiriac *et al.*, 2013). Skin symptoms of ΔNC14A mice are localized in the same areas as in preimmunized mice with passive transfer of ColXVII-specific antibodies, where the

first signs of blistering appeared 3–5 days after immunization and required about 10 days to develop to a full-blown blistering disease (Oswald *et al.*, 2012). Owing to ethical reasons, ΔNC14A mice are euthanized when severe scratching is initiated; it is therefore not known whether clear blisters would develop later.

In mice, humoral immunity requires several weeks to mature after birth (Adkins *et al.*, 2004), which supports the assumption that humoral immune response would cause pruritus in the ΔNC14A mice. In addition, the lag period preceding the symptoms after birth indicates that it is not the maternal antibodies but rather the individual's own immune response that is responsible for the development of itch. The presence of IgG and IgA autoantibodies with subepidermal reactivity in the ΔNC14A scratching mice resembles closely the staining seen by direct and indirect IF of BP patients. In addition, binding of serum IgG antibodies to the 180-kDa keratinocyte protein that was sensitive to collagenase digestion, as well as to the ColXVII-immunoprecipitated protein, strongly suggests that ColXVII could be the target of the autoantibodies. It is known that the physiological shedding of ColXVII generates neoepitopes that could serve as a target of BP autoantibodies (Nishie *et al.*, 2010). Furthermore, in linear IgA dermatosis, IgA antibodies target the shed ectodomain more efficiently than the full-length ColXVII (Schumann *et al.*, 2000). The reasons why genetically modified ColXVII present in the ΔNC14A mice causes the breaking of self-tolerance remains largely elusive. At the moment, it is not known whether the generation of autoantibodies is provoked by the continuous expression of aberrantly processed ColXVII ectodomain, possible conformational changes in the triple helical structure of ColXVII, malformed hemidesmosomes, or other still unidentified triggers.

In BP, the binding of autoantibodies to ColXVII leads to the activation of complement and inflammatory pathways, but a complement-independent pathway, as well as pathways including IgE autoantibodies, are also suggested to be involved (Nishie, 2014). In a humanized BP mouse model, passive transfer of IgG_1 causes subepidermal blisters and deposition of IgG_1, C1q, and C3, in addition to infiltration of neutrophils and mast cell degranulation in the skin (Li *et al.*, 2010). Eosinophilic infiltration and eosinophilia are commonly observed in the majority of BP patients, but they are rarely found in BP mouse models (Hirose *et al.*, 2011; Nishie, 2014). The skin of scratching ΔNC14A mice contained linear deposition of IgG, whereas C3 deposition was not detected (data not shown). Although in BP patients direct IF analysis quite often shows simultaneous accumulation of IgG and C3 (Schmidt and Zillikens, 2013; Nishie, 2014), time-course studies with repetitive immunizations have indicated that deposition of C3 in mouse skin occurs only after IgG deposition is decreased within 6 weeks (Hirose *et al.*, 2011). Serum IgE autoantibodies are assumed to be an early pathogenic event of BP and to retract especially eosinophils into skin lesions (Ishiura *et al.*, 2008; Fania *et al.*, 2012). Similar to a majority of BP patients (Fania *et al.*, 2012; Nishie, 2014), total IgE levels in sera and skin of scratching ΔNC14A mice were highly increased, but tissue-bound or circulating antigen-specific IgE was not detected (data not shown). In addition, both eosinophils in perilesional skin and eosinophilia were detected, suggesting that IgE and eosinophils may be involved in the pruritus of ΔNC14A mice.

Besides pruritus and the development of autoantibodies, ΔNC14A mice have some features of inherited blistering skin disease associated with ColXVII mutations, i.e., junctional epidermolysis bullosa. Junctional epidermolysis bullosa patients carrying *COL17A1* mutations develop generalized or localized blisters and have hair, nail, and enamel defects (Kiritsi *et al.*, 2011; Fine *et al.*, 2014). To date, NC16A domain deletions have not been reported in humans (Kiritsi *et al.*, 2011). ΔNC14A mice do not develop large blisters, but microblisters are detected already in newborn skin. Junctional epidermolysis bullosa patients are also reported to have varying degrees of alopecia (Kiritsi *et al.*, 2011). ΔNC14A mice appear to have thinner fur than their WT littermates, and some develop patchy to total hair loss. Autoantibodies have not been reported in junctional epidermolysis bullosa, but some patients with recessive dystrophic EB generate circulating autoantibodies against mutated collagen VII (Tampoia *et al.*, 2013; Woodley *et al.*, 2014). Contrary to ΔNC14A mice, these autoantibodies do not bind to the patients' skin.

ΔNC14A mice are a BP-related mouse model in which the primary symptom is pruritus, as in the majority of human BP patients. Differing from some previous models (Nishie *et al.*, 2007; Liu *et al.*, 2008; Nishie *et al.*, 2010; Hirose *et al.*, 2011; Chiriac *et al.*, 2013), ΔNC14A mice are immunocompetent and mature, which enables long-term monitoring of natural immune responses. In addition, no injection of substances or other stress-causing experimental procedures are required, because symptoms develop spontaneously. Thus, ΔNC14A mice provide an excellent model to study the breakdown of self-tolerance, as well as the early stages and development of autoimmune blistering skin disease. Itching, subepidermal blistering, eosinophilia, eosinophilic infiltrations, and elevated IgE levels closely resemble the key features of BP patients. The presence of IgG and IgA autoantibodies with subepidermal reactivity and, especially, recognition of a 180-kDa collagenase-sensitive polypeptide suggest strongly that autoantibodies are ColXVII-specific. In our opinion, ΔNC14A mice represent a promising candidate among the existing BP mouse models.

MATERIALS AND METHODS

Generation and characterization of ΔNC14A transgenic mice

Generation of *Col17a1* knockout mice in C57BL/6 background was described in (Hurskainen *et al.*, 2012). Exon 18 and the surrounding intron sequences of the *Col17a1* gene were replaced by the PGK-neo cassette flanked by loxP sequences (*PGK-neoR*). Breeding with mice carrying the *Cre* recombinase gene (Sakai and Miyazaki, 1997) led to removal of the *PGK-neoR* cassette and restored the reading frame. This resulted in a viable ColXVII mutant mouse strain with a deletion in the NC14A region. The project has been approved by the University of Oulu Animal Ethics Committee and the Southern Finland Regional State Administrative Agency (license number ESAVI/5255/04.10.03/2011). The animal care principles and experimental

procedures are in accordance with national Finnish legislation, the European Convention for the protection of vertebrate animals used for experimental and other scientific purposes (ETS 123), and EU Directive 2010/63/EU. All efforts were made to minimize the suffering of experimental animals. The humane end point defined in the license for ΔNC14A mice is the initiation of scratching.

Genomic DNA was isolated from ear samples by routine methods and analyzed by PCR using *Col17a1* exon 17– and 22–specific primers (sense 5′-TGCGGCTCCTGCTGCAGCTGG-3′, antisense 5′-CTTTGGTCCTTCCGGGCCAGG-3′). The amplified PCR products were analyzed by agarose gel electrophoresis.

Isolation and cultivation of primary keratinocytes

Primary keratinocytes were isolated from newborn WT mice, as described in (Löffek *et al.*, 2014). Primary keratinocytes were immortalized by infecting with pseudotyped retroviruses carrying the *HPV16 E6* and *E7* genes. Retroviral particles were generated by co-transfecting Phoenix gag-pol cells with pLSXN16E6E7 (a generous gift from Dr Denise Galloway, Fred Hutchinson Cancer Research Center, Seattle, WA) and pVSV-G plasmids with Lipofectamine 2000 (Life Technologies, Grand Island, NY). Keratinocytes were infected with concentrated culture medium containing viral particles and 2 μg ml^{-1} polybrene for 24 hours. Thereafter, virus-containing medium was replaced by CnT-07 medium (CELLnTEC, Bern, Switzerland).

Immunoblotting analysis of mouse skin extracts and keratinocytes

Snap-frozen abdominal skin biopsies collected from euthanized mice were homogenized in RIPA buffer (50 mM Tris, pH 7.5, 150 mM NaCl, 0.5% sodium deoxycholate, 1% Triton X-100, 0.1% SDS, Protease inhibitor cocktail (Sigma-Aldrich, St. Louis, MO), 2 mM EDTA) and clarified by centrifugation. Ethanol-precipitated proteins were analyzed by immunoblotting with ColXVII domain–specific antibodies EC-7 (aa 1030–1134; Oswald *et al.*, 2012) and NC14A (aa 479–573; Franzke *et al.*, 2002). GAPDH (Santa Cruz Biotechnologies, Santa Cruz, CA) was used as a loading control, and horseradish peroxidase (HRP)–conjugated anti-rabbit IgG (Sigma-Aldrich) as a secondary antibody. HRP-conjugated anti-mouse IgG (Abliance, Compiegne, France), anti-mouse IgG1 (Life Technologies) and anti-mouse IgE (Bethyl Laboratories, Montgomery, TX) were used for quantification of immunoglobulins in skin extracts. Proteins were visualized with enhanced chemiluminescence substrates (ECL Prime, GE Healthcare, Buckinghamshire, UK) and LAS-3000 Image analyzer system (Fujifilm, Tokyo, Japan). Specific protein bands were quantified using the ImageJ software (NIH, Bethesda, MA) and normalized against GAPDH.

Immortalized keratinocytes were grown for 48 hours in CnT-07 medium containing 50 μg ml^{-1} ascorbic acid. Cells were lysed in RIPA buffer, as described above. Aliquots of cell extracts were treated with 40 U ml^{-1} highly purified bacterial collagenase (type III, Sigma-Aldrich) for 2 hours at +37 °C. ColXVII was immunoprecipitated from keratinocyte cell extract by using EC-7 antibody and Protein-A-Sepharose (GE Healthcare) overnight at +4 °C. Immunoprecipitated proteins were eluted in SDS-sample buffer. Sera (1:1000) collected from WT and ΔNC14A mice and HRP-conjugated anti-mouse IgG (Abliance) were used to detect the keratinocyte antigens by immunoblotting.

Morphologic analysis of the mouse skin

Skin biopsies were fixed in 10% buffered formalin and paraffin-embedded. Five-micrometer sections were stained with hematoxylin–eosin for histologic analysis by light microscopy (Leica DM3000, Wetzlar, Germany).

Indirect and direct IF analyses were performed in 5-μm frozen, nonfixed sections. Murine WT and ΔNC14A sera (1:50) and polyclonal antibody EC-7 (1:500) were used as primary antibodies, and Alexa Fluor 488–conjugated anti-mouse IgG or Alexa Fluor 594–conjugated anti-rabbit IgG (Life Technologies) were used as secondary antibodies. ImmuMount (ThermoScientific, Middletown, VA)-embedded sections were photographed with Olympus FluoView FV1000 confocal microscope using ×100 oil-immersion objective and appropriate filter settings. Direct IF with Alexa Fluor 488–conjugated anti-mouse IgG and IgG_1 and FITC-conjugated anti-mouse IgA antibodies (Life Technologies) was performed similarly to indirect IF but without sera.

To prepare salt-split skin samples, WT mouse skin biopsies were treated with 1 M NaCl for 48 hours at 4 °C. Epithelia were separated from the dermis with forceps, and biopsies were frozen.

For transmission and immunoelectron microscopy, specimens from mouse skin samples were processed and analyzed as previously described (Hurskainen *et al.*, 2012), except that skin cryosections were exposed to polyclonal EC-7 (1:100) antibody.

Blood analysis

Blood cell count was analyzed using a flow cytometer at NordLab Oulu, Finland. Blood samples were collected from terminally anesthetized mice by orbital bleeding in K-EDTA Microvette tubes (Sarstedt, Nümbrecht, Germany), and serum was separated by centrifugation and stored at −70 °C. Total IgE concentration in mouse sera was measured using the Mouse IgE ELISA MAX Deluxe Set (BioLegend, San Diego, CA) according to the manufacturer's instructions.

CONFLICT OF INTEREST

The authors state no conflict of interest.

ACKNOWLEDGMENTS

We thank Anja Mattila, Sirpa Kellokumpu, Seija Leskelä, Tarja Piispanen, and Riitta Vuento for their expert technical assistance, as well as Matti Kallioinen and Johannes Kern for their kind help with histopathological analysis. Denise Galloway is acknowledged for providing the pLXSN16E6E7-plasmid and Cassian Sitaru for the EC-7 antibody. This study was supported by Oulu University Hospital and Academy of Finland grants to KT and NK, and a German Research Foundation (DFG) grant (SFB-850/B6) to CWF and LBT.

SUPPLEMENTARY MATERIAL

Supplementary Material is linked to the online version of the paper at http://www.nature.com/jid

REFERENCES

Adkins B, Leclerc C, Marshall-Clarke S (2004) Neonatal adaptive immunity comes of age. *Nat Rev Immunol* 4:553–64

Chiriac MT, Licarete E, Sas AG *et al.* (2013) Passive transfer of collagen XVII-specific antibodies induces sustained blistering disease in adult mice. *Orphanet J Rare Dis* 8:17

Di Zenzo G, Della Torre R, Zambruno G *et al.* (2012) Bullous pemphigoid: from the clinic to the bench. *Clin Dermatol* 30:3–16

Fania L, Caldarola G, Muller R *et al.* (2012) IgE recognition of bullous pemphigoid (BP)180 and BP230 in BP patients and elderly individuals with pruritic dermatoses. *Clin Immunol* 143:236–45

Fine JD, Bruckner-Tuderman L, Eady RA *et al.* (2014) Inherited epidermolysis bullosa: updated recommendations on diagnosis and classification. *J Am Acad Dermatol* 70:1103–26

Franzke CW, Bruckner P, Bruckner-Tuderman L (2005) Collagenous transmembrane proteins: recent insights into biology and pathology. *J Biol Chem* 280:4005–8

Franzke CW, Bruckner-Tuderman L, Blobel CP (2009) Shedding of collagen XVII/BP180 in skin depends on both ADAM10 and ADAM9. *J Biol Chem* 284:23386–96

Franzke CW, Tasanen K, Schäcke H *et al.* (2002) Transmembrane collagen XVII, an epithelial adhesion protein, is shed from the cell surface by ADAMs. *EMBO J* 21:5026–35

Franzke CW, Tasanen K, Schumann H *et al.* (2003) Collagenous transmembrane proteins: collagen XVII as a prototype. *Matrix Biol* 22:299–309

Garibyan L, Chiou AS, Elmariah SB (2013) Advanced aging skin and itch: addressing an unmet need. *Dermatol Ther* 26:92–103

Giudice GJ, Emery DJ, Zelickson BD *et al.* (1993) Bullous pemphigoid and herpes gestationis autoantibodies recognize a common non-collagenous site on the BP180 ectodomain. *J Immunol* 151:5742–50

Hirose M, Recke A, Beckmann T *et al.* (2011) Repetitive immunization breaks tolerance to type XVII collagen and leads to bullous pemphigoid in mice. *J Immunol* 187:1176–83

Hurskainen T, Moilanen J, Sormunen R *et al.* (2012) Transmembrane collagen XVII is a novel component of the glomerular filtration barrier. *Cell Tissue Res* 348:579–88

Ishiura N, Fujimoto M, Watanabe R *et al.* (2008) Serum levels of IgE anti-BP180 and anti-BP230 autoantibodies in patients with bullous pemphigoid. *J Dermatol Sci* 49:153–61

Kiritsi D, Kern JS, Schumann H *et al.* (2011) Molecular mechanisms of phenotypic variability in junctional epidermolysis bullosa. *J Med Genet* 48:450–7

Leighty L, Li N, Diaz LA *et al.* (2007) Experimental models for the autoimmune and inflammatory blistering disease, bullous pemphigoid. *Arch Dermatol Res* 299:417–22

Li K, Tamai K, Tan EM *et al.* (1993) Cloning of type XVII collagen. Complementary and genomic DNA sequences of mouse 180-kilodalton bullous pemphigoid antigen (BPAG2) predict an interrupted collagenous domain, a transmembrane segment, and unusual features in the 5′-end of the gene and the 3′-untranslated region of the mRNA. *J Biol Chem* 268:8825–34

Li Q, Ujiie H, Shibaki A *et al.* (2010) Human IgG1 monoclonal antibody against human collagen 17 noncollagenous 16A domain induces blisters via complement activation in experimental bullous pemphigoid model. *J Immunol* 185:7746–55

Liu Z, Diaz LA, Troy JL *et al.* (1993) A passive transfer model of the organ-specific autoimmune disease, bullous pemphigoid, using antibodies generated against the hemidesmosomal antigen, BP180. *J Clin Invest* 92:2480–8

Liu Z, Sui W, Zhao M *et al.* (2008) Subepidermal blistering induced by human autoantibodies to BP180 requires innate immune players in a humanized bullous pemphigoid mouse model. *J Autoimmun* 31:331–8

Löffek S, Hurskainen T, Jackow J *et al.* (2014) Transmembrane collagen XVII modulates integrin dependent keratinocyte migration via PI3K/Rac1 signaling. *PLoS One* 9:e87263

Metz M, Ständer S (2010) Chronic pruritus-pathogenesis, clinical aspects and treatment. *J Eur Acad Dermatol Venereol* 24:1249–60

Nishie W (2014) Update on the pathogenesis of bullous pemphigoid: an autoantibody-mediated blistering disease targeting collagen XVII. *J Dermatol Sci* 73:179–86

Nishie W, Lamer S, Schlosser A *et al.* (2010) Ectodomain shedding generates neoepitopes on collagen XVII, the major autoantigen for bullous pemphigoid. *J Immunol* 185:4938–47

Nishie W, Sawamura D, Goto M *et al.* (2007) Humanization of autoantigen. *Nat Med* 13:378–83

Oswald E, Sesarman A, Franzke CW *et al.* (2012) The flavonoid luteolin inhibits fcgamma-dependent respiratory burst in granulocytes, but not skin blistering in a new model of pemphigoid in adult mice. *PLoS One* 7:e31066

Sakai K, Miyazaki J (1997) A transgenic mouse line that retains cre recombinase activity in mature oocytes irrespective of the cre transgene transmission. *Biochem Biophys Res Commun* 237:318–24

Schmidt E, Zillikens D (2013) Pemphigoid diseases. *Lancet* 381:320–32

Schmidt T, Sitaru C, Amber K *et al.* (2014) BP180 and BP230 specific IgG autoantibodies in pruritic disorders of the elderly-a pre-clinical stage of bullous pemphigoid? *Br J Dermatol* 171:212–9

Schumann H, Baetge J, Tasanen K *et al.* (2000) The shed ectodomain of collagen XVII/BP180 is targeted by autoantibodies in different blistering skin diseases. *Am J Pathol* 156:685–95

Shimada SG, LaMotte RH (2008) Behavioral differentiation between itch and pain in mouse. *Pain* 139:681–7

Tampoia M, Bonamonte D, Filoni A *et al.* (2013) Prevalence of specific anti-skin autoantibodies in a cohort of patients with inherited epidermolysis bullosa. *Orphanet J Rare Dis* 8:132

Ujiie H, Shibaki A, Nishie W *et al.* (2010a) A novel active mouse model for bullous pemphigoid targeting humanized pathogenic antigen. *J Immunol* 184:2166–74

Ujiie H, Shibaki A, Nishie W *et al.* (2010b) What's new in bullous pemphigoid? *J Dermatol* 37:194–204

Van den Bergh F, Giudice GJ (2003) BP180 (type XVII collagen) and its role in cutaneous biology and disease. *Adv Dermatol* 19:37–71

Woodley DT, Cogan J, Wang X *et al.* (2014) *De novo* anti-type VII collagen antibodies in patients with recessive dystrophic epidermolysis bullosa. *J Invest Dermatol* 134:1138–40

SUPPLEMENTARY MATERIALS

Movie S1. 10-month-old ΔNC14A mice were followed for 24 hours using a video camera. The video clip is a 1-minute summary of scratching events. Continuous scratching in both of the monitored mice is obvious.

Table S1. Flow cytometric analysis of circulating inflammatory cells in adult WT and scratching ΔNC14A mice.

	WT (n=7) 10^9/L	**ΔNC14A** (n=9) 10^9/L
Neutrophils	0.51	0.93
Lymphocytes	3.77	3.12
Monocytes	0.03	0.11
Eosinophils	0.003	0.012
Basophils	0.008	0.049