AMERICAN ACADEMY OF OTOLARYNGOLOGY–HEAD AND NECK SURGERY FOUNDATION

Otolaryngology–Head and Neck Surgery
2016, Vol. 154(4) 759–764
© American Academy of Otolaryngology—Head and Neck Surgery Foundation 2016
Reprints and permission:
sagepub.com/journalsPermissions.nav
DOI: 10.1177/0194599815627786
http://otojournal.org
SAGE

Acute Invasive Fungal Rhinosinusitis: A 15-Year Experience with 41 Patients

Sakeena J. Payne, MD[1], Ron Mitzner, MD[2], Sudhir Kunchala[1], Lauren Roland, MD[3], and Johnathan D. McGinn, MD[1]

No sponsorships or competing interests have been disclosed for this article.

Received September 17, 2015; revised December 18, 2015; accepted December 30, 2015.

Abstract

Objectives. To describe a 15-year single-institution experience of 41 cases of acute invasive fungal sinusitis (AIFRS), identify clinical indicators predictive of AIFRS, and discuss our approach to these high-acuity patients.

Study Design. Case series with chart review.

Setting. Tertiary referral center; The Pennsylvania State University Hershey Medical Center.

Subjects and Methods. A retrospective review was performed for AIFRS consultations between September 1999 and March 2014. Variables reviewed included underlying condition, presenting symptoms, absolute neutrophil count, disease extent on examination, radiographic findings, medical treatment, biopsy results, surgical treatment, and outcomes. Univariate analysis was performed to determine variables significantly associated with AIFRS. Outcome measures were assessed and patient assessment algorithm developed.

Results. Of 131 patients evaluated, 41 were diagnosed with AIFRS; 92.7% had an underlying hematologic malignancy. Disease predictive variables included absolute neutrophil count $<500/\mu L$ ($P < .0001$; sensitivity = 78%), mucosal abnormalities of middle turbinate ($P < .0001$; specificity = 88%) and septum ($P < .0001$; specificity = 97%), and specifically, necrosis of the middle turbinate ($P < .0001$; specificity = 97%). Twenty-five AIFRS patients (61%) survived until discharge; 25% (n = 10) expired secondary to AIFRS infection explicitly.

Conclusion. This series represents one of the largest single-institution experiences of AIFRS published to date. Timely diagnosis is necessary to improve patient outcomes and limit morbidity. Maintaining a high index of suspicion in at-risk patient populations, followed by prompt evaluation and management, is crucial in suspected AIFRS. The presence or absence of certain findings appear to correlate with biopsy results and may aid in appropriately gauging clinical suspicion for the presence of AIFRS.

Keywords

invasive fungal sinusitis, middle turbinate biopsy, neutropenia, mucormycosis, clinical indicators, algorithm

Acute invasive fungal rhinosinusitis (AIFRS) is a potentially deadly fulminant disease entity that primarily occurs in the immunocompromised patient. AIFRS most commonly occurs in individuals with hematologic malignancies, particularly in patients who have received bone marrow transplantation.[1,2] Other compromised patient populations at risk are those on chronic steroids, poorly controlled diabetics, patients with AIDS, and those undergoing chemoradiation therapy.[3-5] The most common predisposing factor is severe neutropenia (an absolute neutrophil count [ANC] $<500/\mu L$) and/or functional neutropenia.[6]

Multiple fungal organisms have been reported as causative agents in AIFRS; however, *Aspergillus* and *Mucor* are the most common genera identified.[4,6,7] Histopathologic features required to diagnose AIFRS include fungi breaching mucosal barriers and tissue necrosis. The fungi may be noted to invade blood vessels, generating angiocentric necrosis.[8,9] Early presenting symptoms are often nonspecific and may include fever, nasal obstruction, and rhinorrhea. More concerning symptoms, such as vision changes, paresthesias, and other cranial neuropathies, often represent late findings in patients with more advanced disease. Endoscopic physical examination findings can range from innocuous edematous, dry, or pale nasal mucosa in the early phase to crusting and frank necrosis. Some patients present with obvious extension beyond the sinonasal cavity.

[1]Division of Otolaryngology–Head and Neck Surgery, Department of Surgery, The Pennsylvania State Milton S. Hershey Medical Center, Hershey, Pennsylvania, USA
[2]ENT and Allergy Associates, LLP, Lake Success, New York, USA
[3]Department of Otolaryngology–Head and Neck Surgery, Washington University in St Louis, St Louis, Missouri, USA

This article was presented at the 2015 AAO-HNSF Annual Meeting & OTO EXPO; September 27-30, 2015; Dallas, Texas.

Corresponding Author:
Sakeena J. Payne, MD, Division of Otolaryngology–Head and Neck Surgery, Department of Surgery, The Pennsylvania State Milton S. Hershey Medical Center, 500 University Drive H-091, Hershey, PA 17033, USA.
Email: spayne1@hmc.psu.edu

Downloaded from oto.sagepub.com at University of Liverpool on September 7, 2016

AIFRS can be a rapidly progressing infection that exhibits high rates of morbidity and mortality despite advancements in medical and surgical management. In a systematic review of literature published between 1995 and 2012, Turner et al found the overall survival rate of patients treated for AIFRS to be 49.7%.[10] Management of these patients is multidisciplinary, with both medical and surgical interventions needed. Surgical debridement of grossly involved tissue is required for treatment of AIFRS, with more advanced cases requiring serial and extensive resections often leading to significant morbidity. Early diagnosis and aggressive surgical debridement have been identified as positive prognostic factors.[1,6,11,12] Therefore, maintaining a high index of suspicion in at-risk patient populations, followed by prompt biopsy and pathologic evaluation, is critical in accomplishing this. In addition, it is important to have a clear understanding on the predictive and prognostic factors that underlie this condition to come up with more effective management strategies.

Accordingly, our institution employs a high-priority approach to patients with concern for possible AIFRS to expedite diagnosis and, as a result, optimize management. We believe our criteria have in turn led to overall improved patient outcomes when compared with what is described in the literature. In this study, we present 15 years of experience at a single institution of 41 cases of acute invasive fungal sinusitis, which represents one of the largest series published to date. We aim to identify clinical indicators predictive of AIFRS and discuss our approach to these high-acuity patients.

Methods

A retrospective chart review was performed for all suspected cases of AIFRS in patients at The Pennsylvania State University Hershey Medical Center from 1999 to 2014. The suspicion arose from the otolaryngology consult service and was based on immunocompetence of the patient and concern for sinusitis. Approval was obtained from the Penn State Hershey Institutional Review Board (STUDY00001011). Forty-three variables were analyzed for each patient. These included demographics, presenting symptoms, physical examination findings, radiographic findings, procedures performed, culture specimens, pathology, and patient outcomes. The patients were then divided into 2 groups based on whether they had biopsy positive AIFRS or not and were compared to identify clinical indicators predictive of AIFRS. Statistical analysis was performed between the 2 groups through both univariate and multivariate analysis. The univariate analysis consisted of performing a chi-square test for categorical variables and a Wilcoxon test for continuous variables. A Bonferroni correction was applied for all tests to hold the overall type I error rate at 5%. Thus, statistical significance was defined as $P < .0024$ to account for post hoc tests. Multivariate analysis was not performed given limitations in sample size. Descriptive analysis was performed to assess clinical decision making and patient outcomes.

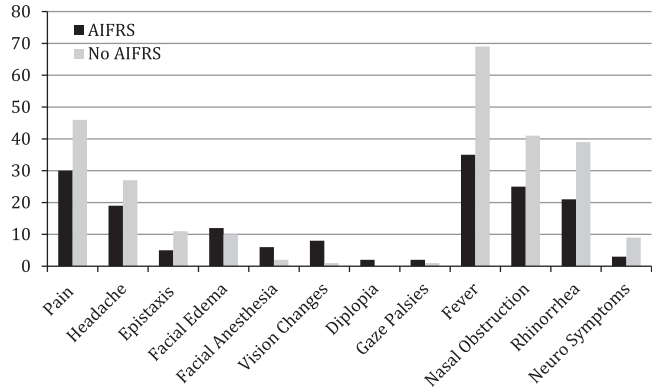

Figure 1. Stratified presenting symptoms in patients evaluated with suspected acute invasive fungal rhinosinusitis (AIFRS).

Results

Between 1999 and 2014, a total of 131 patients were evaluated by the otolaryngology service with suspected AIFRS. The mean age at time of evaluation was 49.4 ± 16.38 years, with 60.3% being males and 39.7% female. The majority of patients had an underlying hematologic malignancy (90.1%), and the remainder had immunosuppression in the form of history of organ transplantation (3.1%), chronic steroid use (2.2%), diabetes mellitus (1.5%), AIDS (1.5%), chemoradiation for solid organ malignancy (0.8%), and aplastic anemia (0.8%).

Of the 131 patients evaluated with immunosuppression and fever of unknown origin, 110 underwent endoscopic tissue biopsy. The remaining 21 patients were not biopsied owing to low clinical suspicion for AIFRS. None of these patients subsequently developed AIFRS. Of the patients with negative biopsies, 78.2% had no nasal endoscopy findings concerning AIFRS. Clinical concern prompting biopsy in 52.1% of these patients was an ANC <500/μL and in 27.5% positive computed tomography (CT) scan findings, with the mean Lund-Mackay score of 11.8 (95% confidence interval [95% CI], 8.4-15.7).

A total of 41 patients were found to have AIFRS according to histopathologic criteria. Among these patients, 40 (97.5%) had a hematologic malignancy as their underlying disease, and the remainder had a history of chronic steroid use. At the time of diagnosis, the ANC was <500/μL in 34 (82.9%) patients, and 39% had undergone bone marrow transplantation.

Fever was the predominant overall presenting symptom among all patients evaluated, followed by facial pain, nasal obstruction, and rhinorrhea. **Figure 1** compares symptoms present at the time of otolaryngology consultation between disease-positive and disease-negative patients. Facial edema, facial paresthesias, and ocular symptoms were seen more in patients positive for disease. Loss of visual acuity, gaze palsy, and diplopia were detected in 11 (26.8%) patients with AIFRS, as compared with 3 (3.3%) of the disease-free group. Likewise, facial anesthesia was seen in 6 (14.6%) AIFRS patients, compared with 2 (2.22%) non-AIFRS patients.

Downloaded from oto.sagepub.com at University of Liverpool on September 7, 2016

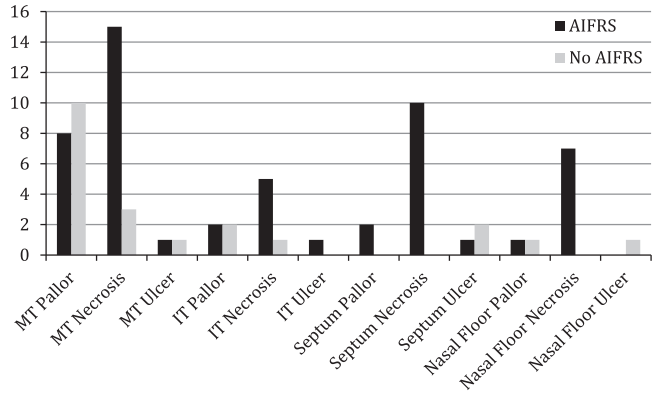

Figure 2. Stratified nasal endoscopy findings in patients evaluated with suspected acute invasive fungal rhinosinusitis (AIFRS). IT, inferior turbinate; MT, middle turbinate.

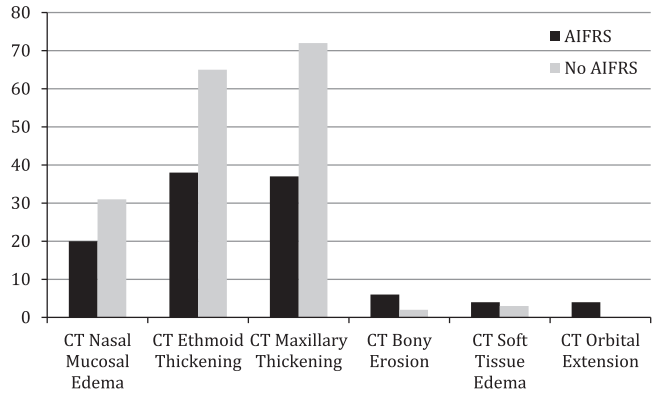

Figure 3. Stratified computed tomography (CT) scan findings in patients evaluated with suspected acute invasive fungal rhinosinusitis (AIFRS).

In our series, the most common nasal endoscopic examination finding in AIFRS patients was middle turbinate necrosis (36.6%), followed by septal necrosis (24.4%), middle turbinate pallor (19.5%), and nasal floor necrosis (17.1%). However, 12 (29.7%) patients with biopsy-proven AIFRS had no concerning findings on nasal endoscopy. **Figure 2** compares physical examination findings between the 2 groups. All patients received a sinus CT scan as part of their evaluation, and in general, findings were consistent with some form of sinonasal inflammatory process (**Figure 3**). Seven patients with AIFRS were not severely neutropenic; however, the mean Lund-Mackay score was 12.1 (95% CI, 9.3-16.4).

Univariate analysis of variables predictive of AIFRS revealed 5 variables significantly associated with AIFRS (**Table 1**). These included ANC <500/μL, mucosal abnormalities of middle turbinate and septum, and specifically, necrosis of the middle turbinate. The sensitivities and specificities for each were also calculated and are included in **Table 2**.

Of the patients diagnosed with AIFRS, 37 (90.2%) underwent endoscopic debridement, and the majority (92.7%) were found to have disease limited to the sinonasal

Table 1. Variables Stratified by IFS Status Tests.[a]

	No IFS (n = 90)	IFS (n = 41)	*P* Value
Age			.1423
No.	90	41	
Mean ± SD	47.9 ± 16.22	52.7 ± 16.46	
Median	50.0	54.0	
Range	11.0-78.0	8.0-84.0	
Sex			.2597
Female	32 (36)	19 (46.3)	
Male	57 (64)	22 (53.7)	
BMT			.9157
No	54 (60)	25 (61)	
Yes	36 (40)	16 (39)	
Pain			.0177
No	44 (48.9)	11 (26.8)	
Yes	46 (51.1)	30 (73.2)	
Headache			.0692
No	63 (70)	22 (53.7)	
Yes	27 (30)	19 (46.3)	
Epistaxis			.8573
No	78 (86.7)	36 (87.8)	
Yes	12 (13.3)	5 (12.2)	
Facial edema			.0099
No	80 (88.9)	29 (70.7)	
Yes	10 (11.1)	12 (29.3)	
Fever			.2537
No	21 (23.3)	6 (14.6)	
Yes	69 (76.7)	35 (85.4)	
Nasal obstruction			.1017
No	49 (54.4)	16 (39)	
Yes	41 (45.6)	25 (61)	
Rhinorrhea			.4009
No	51 (56.7)	20 (48.8)	
Yes	39 (43.3)	21 (51.2)	
ANC at diagnosis			**<.0001**
No.	90	41	
Mean ± SD	3.3 ± 10.51	0.5 ± 1.62	
Median	0.5	0.0	
Range	0.0-75.0	0.0-10.0	
MT involvement			**<.0001**
No	78 (87.6)	19 (46.3)	
Yes	11 (12.4)	22 (53.7)	
MT pallor			.2042
No	79 (88.8)	33 (80.5)	
Yes	10 (11.2)	8 (19.5)	
MT necrosis			**<.0001**
No	86 (96.6)	26 (63.4)	
Yes	3 (3.4)	15 (36.6)	
Septum			**<.0001**
No	86 (96.6)	29 (70.7)	
Yes	3 (3.4)	12 (29.3)	
CT side			.4907
Bilateral	70 (78.7)	30 (73.2)	
Unilateral	19 (21.3)	11 (26.8)	

(continued)

Downloaded from oto.sagepub.com at University of Liverpool on September 7, 2016

cavity. Patients underwent radical surgical debridement of the affected areas with wide margins until normal-appearing, vascularized tissue was encountered. Thirty-one patients required debridement limited to sinonasal cavity; 5 patients required maxillectomy; and 1 patient required intracranial debridement. No patients required orbital exenteration or facial soft tissue resection. Nine patients required >1 surgical debridement. Intraoperative sinonasal cultures were positive for *Aspergillus* in 16 patients and *Mucor* in 7. Other genera included *Curvularia, Alternaria*, and *Zygomycetes*.

Of the 41 patients with AIFRS, 25 (61%) survived until discharge, and 1 of these patients had extrasinus progression of disease. No patient relapsed after discharge from the hospital. The overall AIFRS-specific mortality rate was found to be 24.3% (10 patients). Of these, 4 patients chose palliative treatment based on poor overall prognosis. Two patients chose to terminate surgical management after initial debridement secondary to extension of disease and the long-term morbidity that removing affected tissue would imply.

Table 1. (continued)

	No IFS (n = 90)	IFS (n = 41)	*P* Value
CT nasal mucosal edema			.1187
No	59 (65.6)	21 (51.2)	
Yes	31 (34.4)	20 (48.8)	
CT ethmoid thickening			.0081
No	25 (27.8)	3 (7.3)	
Yes	65 (72.2)	38 (92.7)	
CT maxillary thickening			.1458
No	18 (20)	4 (9.8)	
Yes	72 (80)	37 (90.2)	
Prophylaxis treatment			.4539
No	27 (30)	15 (36.6)	
Yes	63 (70)	26 (63.4)	
GM-CSF treatment			**.0019**
No	72 (80)	22 (53.7)	
Yes	18 (20)	19 (46.3)	

Abbreviations: ANC, absolute neutrophil count; BMT, bone marrow transplantation; CT, computed tomography; GM-CSF, granulocyte macrophage colony-stimulating factor; IFS, invasive fungal sinusitis; MT, middle turbinate.
[a]Values in n (%) unless indicated otherwise. Bold indicates significance at Bonferroni-corrected *P* value (.0024).

Table 2. Sensitivity and Specificity of Each Variable Significantly Associated With IFS (in Percentages).

Variable	Sensitivity	Specificity
ANC, 500 vs >500/μL	78	64
Middle turbinate, yes vs no	54	88
MT necrosis, yes vs no	37	97
Septum, yes vs no	29	97
GM-CSF, yes vs no	46	80

Abbreviations: ANC, absolute neutrophil count; GM-CSF, granulocyte macrophage colony-stimulating factor; IFS, invasive fungal sinusitis; MT, middle turbinate.

Discussion

AIFRS is a potentially devastating opportunistic infection that affects immunocompromised hosts. The prognosis of AIFRS in the absence of treatment is very poor; it is rapidly fatal in 50% to 80% of untreated patients.[11] Treatment of AIFRS includes the use of antifungals and aggressive surgical debridement. Surgical debridement serves multiple purposes, including reducing fungal load, providing specimen for culture, and allowing increased penetration of antifungal medication by removing affected poorly vascularized tissue.[12] Timely diagnosis and aggressive surgical and medical therapy have been shown to improve outcomes and decrease the amount of debridement required and long-term morbidity.[5]

Accordingly, our divisional philosophy in managing these patients is that neutropenic patients are considered urgent consultations when they have fevers of unknown origin and symptoms of rhinosinusitis or CT findings demonstrating a sinonasal inflammatory process. Otolaryngology evaluation of all patients consists of a detailed history and pertinent physical examination, including nasal endoscopy. Frozen-section biopsies are obtained in patients with clinical suspicion for AIFRS, based on risk factors and/or endoscopic findings. The pathology department is alerted prior to obtaining biopsies, and specimens are hand-delivered to the laboratory to prevent delay in processing and review. If AIFRS is diagnosed on frozen section, the patient is urgently scheduled for operative intervention, and medical management is initiated. Patients who are not biopsied or who have initially negative biopsies but with clinical concern for probable AIFRS are followed with serial endoscopies until suspicion is alleviated.

It has been reported that middle turbinate biopsies have a sensitivity of 75% to 86% and a specificity of 100% for the diagnosis of AIRFS.[11,12] Additionally, the middle turbinate has been found to be the most common site of invasion, followed by the maxillary and ethmoid sinuses, making middle turbinate biopsy an effective means of diagnosis.[11,13] The symptoms of this invasive disease are very difficult to differentiate from those of bacterial or viral sinusitis, making it difficult to make an early accurate diagnosis. As a result, many disease-free patients are subjected to a full workup of AIFRS, including a middle turbinate biopsy procedure for diagnostic purposes.

In this study, we retrospectively report the experience at 1 tertiary care facility with this challenging disease over 15 years. We endeavored to gain information to make more accurate decisions regarding patient selection for biopsy for definitive diagnosis. Forty-one patients included in this series were diagnosed with AIFRS; this represents one the largest data sets published to date. Cho et al and Middlebrooks et al have published series with comparable case numbers; yet, patients with hematologic malignancies

Downloaded from oto.sagepub.com at University of Liverpool on September 7, 2016

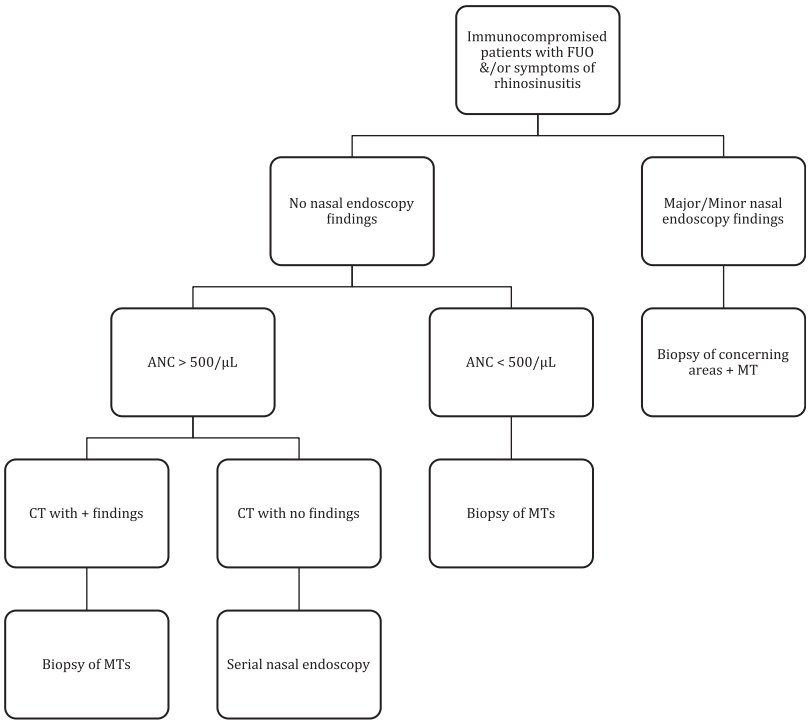

Figure 4. Algorithm of clinical suspicion for acute invasive fungal rhinosinusitis (AIFRS). ANC, absolute neutrophil count; CT, computed tomography; FUO, fever of unknown origin; MT, middle turbinate.

made up only 40% to 60% of their patient populations.[7,13] We believe our data set to be unique, however, as 90.1% of the total number of patients evaluated and all but 1 of our patients diagnosed with AIFRS had an underlying hematologic malignancy as their predisposing factor. These patients are not only neutropenic but typically thrombocytopenic as well. While middle turbinate biopsy is a relative safe procedure, it can be complicated by bleeding and hemorrhage in patients with low platelet levels. Therefore, avoiding procedures in patients with low clinical suspicion, especially in our patient population, is paramount. Additionally, we hope that our results will help to ensure that patients who have signs and symptoms highly correlated with a positive biopsy result will not be missed.

Review of our experience shows that while symptoms of facial paresthesias and ocular dysfunction are rare, these should alert clinicians, as these symptoms are more likely to be associated with AIFRS. In addition, patients with middle turbinate and/or septal mucosal abnormalities such as pallor and especially necrosis warrant a biopsy, as these findings were statistically significantly correlated with the presence of AIFRS. ANC plays a significant role in decision to perform a biopsy as well. Overall, 60% of patients (n = 66) biopsied had no significant nasal endoscopy findings. However, clinical suspicion of AIFRS was high secondary to severe neutropenia (ANC <500/μL) in 68.2% of these patients. Patients without physical examination findings who were not severely neutropenic but who had CT scan findings concerning for a sinonasal inflammatory process made up 23.6% of those biopsied, and 36.8% of these patients were positive for disease. This is consistent with previous studies, as Middlebrooks et al described a CT-based model as their screening method for AIFRS with high reliability (positive predictive value, 87%; negative predictive value, 95%).[13] In summary, the 3 criteria that procured biopsies in the patient population examined of prevalence were ANC <500/μL, mucosal abnormalities on nasal endoscopy, and CT scan findings concerning for a sinonasal inflammatory process. **Figure 4** outlines our assessment algorithm. Adhering to this approach has yielded no false-negative results in our experience. Our findings corroborate previous studies and further prove that, despite a larger series, there is no well-defined formula or protocol in the diagnosis of AIFRS, making judicial biopsying a key element to management of at-risk patients.

Our AIFRS-specific mortality rate was 24.3%. This figure includes the 4 patients who chose palliation versus management of their infection secondary to overall poor prognosis and not due to extent of disease. After this adjustment, our disease-specific mortality rate of patients who chose to undergo treatment was 14.6%; to our knowledge, this is one of the lowest published for a study of this size. We believe that this success is in part due to aggressive early diagnosis, as the majority of our patients had disease limited to the sinonasal cavity and approximately one-third with AIFRS were yet to develop gross mucosal aberrations at the time of diagnosis. Our overall survival rates are similar to those reported in recent similar size studies, but our large complement of hematologic malignancy patients is significantly higher.[7,13] Previous studies specifically examining AIFRS patients with an underlying hematologic malignancy reported overall survival rates between 40% to

Downloaded from oto.sagepub.com at University of Liverpool on September 7, 2016

60%.[1,11] Our lower mortality rate in this more challenging patient population indicates that the proposed algorithm appears to be a beneficial methodology in evaluating and treating patients at risk for AIFRS.

Conclusions

AIFRS is a potentially rapidly fatal disease, warranting timely diagnosis and management. Treatment of AIFRS requires surgical debridement. Diagnosis in early phases of infection lead to decreased patient morbidity and mortality; thus, maintaining a high index of suspicion in at-risk patient populations, followed by prompt evaluation and management, is crucial in suspected AIFRS. The presence or absence of certain findings correlate with biopsy results and may aid in appropriately gauging clinical suspicion for the presence of AIFRS. Severe neutropenia, septal and middle turbinate mucosal abnormalities, and particularly middle turbinate necrosis should raise suspicion of AIFRS in febrile patients with hematologic malignancies.

Acknowledgments

We thank Eric Shaeffer, MS, for his assistance in statistical analysis for this project.

Author Contributions

Sakeena J. Payne, data collection and analysis/interpretation, main manuscript author/editor; **Ron Mitzner**, study conception, data collection, manuscript editor; **Sudhir Kunchala**, data collection, manuscript author; **Lauren Roland**, data collection, manuscript editor; **Johnathan D. McGinn**, primary investigator, study conception, manuscript editor and final approval.

Disclosures

Competing interests: None.

Sponsorships: None.

Funding source: None.

References

1. Chen C-Y, Sheng W-H, Cheng A, et al. Invasive fungal sinusitis in patients with hematological malignancy: 15 years experience in a single university hospital in Taiwan. *BMC Infect Dis*. 2011;11:250.
2. Drakos PE, Nagler A, Or R, et al. Invasive fungal sinusitis in patients undergoing bone marrow transplantation. *Bone Marrow Transplant*. 1993;12(3):203-208.
3. Parikh SL, Venkatraman G, DelGaudio JM. Invasive fungal sinusitis: a 15-year review from a single institution. *Am J Rhinol*. 2004;18:75-81.
4. Monroe MM, McLean M, Sautter N, et al. Invasive fungal rhinosinusitis: a 15-year experience with 29 patients. *Laryngoscope*. 2013;123:1583-1587.
5. DelGaudio JM, Clemson LA. An early detection protocol for invasive fungal sinusitis in neutropenic patients successfully reduces extent of disease at presentation and long term morbidity. *Laryngoscope*. 2009;119:180-183.
6. Valera FCP, do Lago T, Tamashiro E, Yassuda CC, Silveira F, Anselmo-Lima WT. Prognosis of acute invasive fungal rhinosinusitis related to underlying disease. *Int J Infect Dis*. 2011; 15:e841-e844.
7. Cho H-J, Jang M-S, Hong SD, Chung S-K, Kim HY, Dhong H-J. Prognostic factors for survival in patients with acute invasive fungal rhinosinusitis. *Am J Rhinol Allergy*. 2015;29:48-53.
8. deShazo RD, O'Brien M, Chapin K, Soto-Aguilar M, Gardner L, Swain R. A new classification and diagnostic criteria for invasive fungal sinusitis. *Arch Otolaryngol Head Neck Surg*. 1997;123:1181-1188.
9. Chakrabarti A, Denning DW, Ferguson BJ, et al. Fungal rhinosinusitis: a categorization and definitional schema addressing current controversies. *Laryngoscope*. 2009;119:1809-1818.
10. Turner JH, Soudry E, Nayak JV, Hwang PH. Survival outcomes in acute invasive fungal sinusitis: a systematic review and quantitative synthesis of published evidence. *Laryngoscope*. 2013;123:1112-1118.
11. Saedi B, Sadeghi M, Seilani P. Endoscopic management of rhinocerebral mucormycosis with topical and intravenous amphotericin B. *J Laryngol Otol*. 2011;125:807-810.
12. Sun H-Y, Forrest G, Gupta KL, et al. Rhino-orbital-cerebral zygomycosis in solid organ transplant recipients. *Transplantation*. 2010;90:85-92.
13. Middlebrooks EH, Frost CJ, De Jesus RO, Massini TC, Schmalfuss IM, Mancuso AA. Acute invasive fungal rhinosinusitis: a comprehensive update of CT findings and design of an effective diagnostic imaging model. *AJNR Am J Neuroradiol*. 2015;36:1529-1535.

Downloaded from oto.sagepub.com at University of Liverpool on September 7, 2016