International Orthopaedics
https://doi.org/10.1007/s00264-018-4273-4

ORIGINAL PAPER

A case series of cementless revision total knee arthroplasty in patients with benzoyl peroxide allergy

Frank S. Fröschen[1] · Nadine Gravius[1] · Jan-Frederic Lau[2] · Thomas Martin Randau[1] · Eva Kaup[1] · Max J. Friedrich[1] · Sascha Gravius[1]

Received: 23 August 2018 / Accepted: 3 December 2018
© SICOT aisbl 2018

Abstract

Purpose The contact allergens nickel, cobalt, and chromium are often discussed as possible triggers of allergic reactions to orthopedic implants. Additionally, acrylates and polymerization additives in bone cement (e.g., benzoyl peroxide (BPO)) have been implicated as triggers of eczema, wound healing disorders, and aseptic implant loosening. We report about six patients with aseptic loosening after total knee arthroplasty (TKA), who underwent revision surgery after testing positive for BPO hypersensitivity.

Methods After clarification of possible other causes of implant failure, epicutaneous testing had been performed and the implants were replaced in a two-stage procedure with cementless, diaphyseal anchoring, hypoallergenic (TiNb-coated) revision endoprostheses.

Results Epicutaneous testing revealed a BPO allergy in all six patients and an additional nickel allergy in three of the six patients. There was no histopathological or microbiological evidence for a periprosthetic infection. The clinical follow-up showed a low level of pain with good function, a stable knee joint, and proper implant position. The Knee Society Score (KSS) with its subscales Knee Score and Functional Score improved post-operatively from 43 to 70 points and from 47.5 to 68.3 points, respectively. Two implant-specific complications occurred: femoral stress shielding two years post-operatively with no further need for action and aseptic loosening of the tibial stem with the need of revision three years post-operatively.

Conclusions The regression of complaints after replacement with cementless and nickel-free revision implants suggests allergic implant intolerance. Implantation of a cementless, hypoallergenic endoprosthesis might, therefore, be a surgical treatment strategy in patients with evidence of allergies.

Keywords Allergy · Benzoyl peroxide · Nickel · Metal · Bone cement · Total knee arthroplasty · Revision

Introduction

In recent years, the role of allergic reactions to implant materials in failed hip and knee arthroplasty has increasingly become a topic of debate [1–3]. Particularly, the alloy components of the implant materials contain the contact allergens nickel, chromium, and cobalt [4]. Although cutaneous metal sensitization rates of up to 13.1% for nickel and 8% for cobalt and chromium are not uncommon, so far, only a few cases of implant allergies have been published in a form of case reports and cohort studies [4–6].

Manifestations of allergic reactions to metal implants that have been described are localized or generalized eczema, urticarial swabs, persistent swelling, sterile osteomyelitis, wound healing disorders, or, in isolated cases, aseptic implant loosening [2, 4].

In contrast, only a few reports have documented bone cement–associated allergic reactions [2, 7]. The sensitizing capacity of acrylates, as well as the additives used for the polymerization of the acrylic bone cement (including BPO, *N*, *N*-dimethyl-p-toluidine [DMT], hydroquinones), and optional antibiotic supplements, was first detected in the context of intolerance reactions to dental materials [8].

Frank S. Fröschen and Nadine Gravius contributed equally to this work.

✉ Frank S. Fröschen
Frank.froeschen@ukbonn.de

[1] Department of Orthopaedics and Trauma Surgery, University Hospital Bonn, Sigmund-Freud-Straße 25, 53127 Bonn, Germany

[2] Department of Pathology, University Hospital Bonn, Bonn, Germany

Published online: 11 December 2018

Because allergological testing is rarely performed in the context of arthroplasty, the incidence of allergy-mediated implant incompatibilities cannot be estimated at the moment [2]. Histopathological examination of periprosthetic tissues from complication-related revision surgery has, however, revealed lymphocytic infiltrates with histological characteristics of late-type T cell–specific responses [4, 9].

In the present paper, we report about six consecutive patients who underwent cementless revision total knee arthroplasty (RTKA) after an evidence for a contact allergy to BPO was found.

Materials and methods

Six consecutive patients ($n = 3$ (50%) female, $n = 3$ (50% male)) following TKA were included in this case series. The criteria for inclusion were a positive testing for BPO allergy in an epicutaneous allergy test and the exclusion of other differential diagnosis and need for revision surgery with implantation of a hypoallergenic endoprosthesis.

All six patients had cemented knee prostheses, of which $n = 3$ (50%) had been implanted in primary TKA procedures without stems and $n = 3$ (50%) in RTKA procedures with cementless stem-guided shaft anchors. The mean age of the patients was 64.9 ± 11.1 years (min 54, max 82.3 years). The detailed patient data are summarized in Tables 1 and 2.

Differential diagnosis "painful endoprosthesis"

On the basis of the detailed patient anamneses (e.g., pain from previous and current implants, incompatibilities with dental materials, or metals, including costume jewelry on the skin, history of atopic diathesis, or known other allergies), and after clarification of possible other causes of a "painful endoprosthesis" (e.g., ligamentous instability in the case of incorrect implant positioning or insufficient soft tissue balancing; malposition of the components (assessed with CT); aseptic prosthesis loosening), a tentative diagnosis of a "contributing implant allergy" was made. The exclusion of a periprosthetic infection (PJI) was based on standardized procedures defined by the Musculoskeletal Infection Society (MSIS) [13, 14].

The tentative diagnosis of an implant allergy was further investigated by testing the patients with a standardized allergological test, as described in the study by Bircher et al. [15]. While this standardized test includes epicutaneous testing (standard and bone cement series), a lymphocyte transformation testing (LTT) is not standardly included.

The indication for open revision and tissue sampling was considered given when patients had a painful endoprosthesis and a positive allergy test to implant materials. During the operation, at least more than four samples of periprosthetic tissue were taken from representative areas for histopathological and microbiological processing. When loosening of the prosthesis was evident intra-operatively, the prosthesis was explanted, the explantation site was extensively surgically debrided, and the explanted components were sonicated.

All of the patients in this study underwent a two-stage procedure. In the prosthesis-free phase, the knee joint was stabilized by the application of external stabilization (dorsal plaster splint or external fixator). After histopathological and microbiological exclusion of an infection, the patient was prepared for the implantation of a cement-free custom-made prosthesis (Waldemar LINK GmbH, Hamburg, Germany; link rotational knee prosthesis with custom-made hypoallergenic cement-free grooved and diaphyseal anchored shafts). A thin-layer CT was used to acquire detailed planning shots. Figure 1 exemplifies the pre-operative planning procedure.

Table 1 Descriptive summary of patient data after retrospective evaluation

Pat. ID	Age (years)	Sex	BMI (kg/m^2)	Type of endoprosthesis (primary/revision)	Dermatological testing (strength of the skin reaction, time in h)	Operation time (cutting/suture time (min))	Length of hospital stay (days)
1	58.25	F	25.38	Revision TKA	BPO (+, 72 h); sandalwood (+, 72 h); fragrance (+, 72 h); wollwax (+, 48 h)	236	24
2	54.02	F	27.71	Primary TKA	Colophony (++, 72 h); propolis (+, 72 h); BPO (++, 72 h); Ti6Al4V (++, 72 h)	200	13
3	82.25	F	19.55	Revision TKA	BPO (+, 72); nickel sulfate (++, 72 h); copper sulfate (++, 72 h)	271	22
4	73.85	M	26.23	Revision TKA	Vanadium (++ 72 h); copper sulfate (++, 72 h); nickel sulfate (++, 72 h); BPO (+, 72 h)	171	31
5	64.11	M	27.76	Primary TKA	BPO (+, 72 h)	186	8
6	56.638	M	31.13	Primary TKA	BPO (++, 72 h); nickel sulfate (++, 72 h)	191	9
Average	63.80		26.28			209.16	17.83

F female, *M* male, *BMI* body mass index. Type of endoprosthesis before explantation; strongest skin reaction at certain exposure time: + erythema and low infiltrate, ++ erythema and papules, +++ erythema, papules, and vesicles, ++++ blisters and erosions [10]; *h* hours, *BPO* benzoyl peroxide

Table 2 Descriptive summary of patient data after retrospective evaluation; type of periprosthetic membrane according to Krenn and Morawitz [11]; assessment of loosening after intra-operative macroscopic finding; follow-up in months after replantation; Knee Society Score (KSS) pre-operative before explantation and at last follow-up [12]

Pat. ID	Type of periprosthetic membrane	Implant loosening (femoral and/or tibial)	Follow-up (months)	KSS pre-operative (Knee/Functional)	KSS post-operative (Knee/Functional)	Osseous integration	Revision
1	Type 1	Yes, femoral and tibial component	48.2	51/55	83/90	Proper	No
2	Type 4*	Yes, femoral and tibial component	26.2	38/45	74/80	Proper	Yes, open arthrolysis
3	Type 1	Yes, femoral and tibial component	43.6	48/55	78/60	Femoral proper	Yes, change of tibial stem due to aseptic loosening
4	Type 4*	Yes, femoral and tibial component	6.3	40/15	43/20	Proper	No
5	Type 1	Yes, femoral and tibial component	9.4	43/60	73/80	Proper	No
6	Type 4*	Yes, femoral and tibial component	12.4	38/55	74/80	Proper	No
Average			24.35	43/47.5	70.8/68.3		

*Intra-operative samples with extensive fibrosis and lymphocytic mediated perivascular infiltration

Microbiological and histopathological diagnosis

Microbiological processing of the samples followed standard methods described elsewhere [16]. In order to not compromise the diagnostic value of the microbiological assessment, the start of antibiotic therapy was delayed until the intra-operative samples had been obtained. The incubation time was extended to 14 days to achieve optimal bacterial outcome [16].

The histopathological workup included the assessment of periprosthetic membranes according to Morawietz et al. [11, 17]. Furthermore, special attention was paid to a possible occurrence of perivascular lymphocytic infiltration as an indication of an allergy-mediated type IV response.

For the immunohistochemical examination, the marker CD-3 [Leica Biosystems, product code: NCL-L-CD3-565] was used to characterize possible T cell–specific immune responses as a sign of a delayed hypersensitivity with increased perivascular lymphocytic infiltration.

The semiquantitative analysis of CD-3 expression was carried out microscopically [Leica Microscope, Leica Microsystems Wetzlar GmbH, Germany]. The images were acquired with a ProgRes SpeedXT core3 camera [Jenoptik AG, Jena, Germany].

Clinical and radiological follow-up

Clinical and radiographic follow-up assessments were performed post-operatively at six weeks, six months, and one year, and, thereafter, in one year intervals. The Knee Society Score (KSS) was assessed pre- and post-operatively for its two subscales, Knee and Function [12].

The evaluation of the pre- and post-operative radiological imaging was carried out by three independent examiners, in particular, in regard to new osteolysis, significant, or progressive, radiolucent lines in comparison with previous images, sintering of the tibial or femoral prosthesis component, and bone substance loss in the sense of stress shielding.

The definitions of the TKA complication workgroup were used to evaluate post-operative complications [18]. Moreover, a distinction was made between implant-specific and non-implant-specific causes of failure.

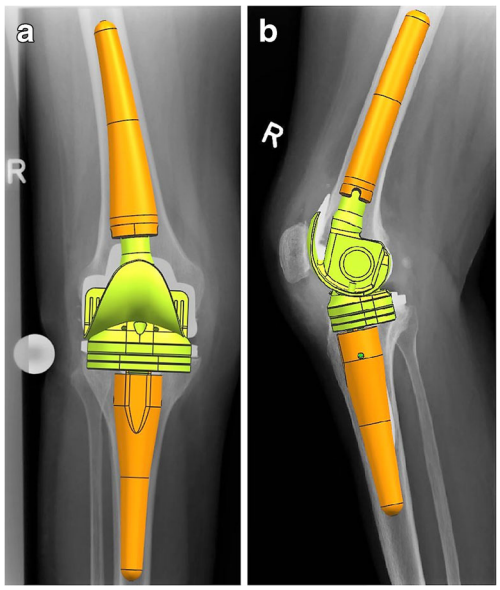

Fig. 1 Exemplary pre-operative planning in two planes (pat. no. 2)

Statistical analysis

Statistical analysis was performed with MS Excel 2016 for Windows (Microsoft Corporation, Richmond, USA), with a comparison of the arithmetic mean ± standard deviation.

Results

Differential diagnosis "painful endoprosthesis"

In the epicutaneous allergy tests, all six patients showed a positive skin reaction to BPO after a 72hour exposure ($n = 4$, strength 1 (66.67%) (erythema and low infiltrate), $n = 2$, strength 2 (erythema and papules)) [10].

In addition to the proven skin reaction to BPO, skin reactions to nickel (II), sulfate, and others such as cupric sulfate could be detected in three of the patients (see Table 1).

Tibial and femoral loosening of the prosthesis was apparent in all cases during the revision operation, and the prostheses could be removed without major surgical manipulation.

Microbiological and histopathological diagnosis

No signs for a PJI were macroscopically evident during surgery in any of the treated patients. The interval between explantation and replantation averaged 61.3 days (55 to 70 days). After removal of the prosthesis and debridement of the surgical site, ligamentous instability was seen in all patients, which necessitated the implantation of a hinged revision endoprosthesis.

Histological processing of the obtained tissue samples showed lymphocytic mediated perivascular infiltration as an indication of an allergy-mediated type IV reaction in three cases, with partly increased expression of CD 3. In all of these intra-operative samples, extensive fibrosis was also observed (Figs. 2 and 3). In three cases, a type 1 periprosthetic membrane as defined by Krenn and Morawitz was found [11].

Microbiological processing of the joint aspirates and periprosthetic tissue samples showed no evidence of a PJI; the MSIS criteria for defining PJI were negative in all cases.

Clinical and radiological follow-up

In one patient, a fracture of the medial femoral condyle occurred intra-operatively during the insertion of the definitive femoral component of the prosthesis. This fracture could be treated by cannulated screw osteosynthesis so that it was primarily stable (see Fig. 4). The average duration of the operation for implantation of the custom-made prostheses was 209.16 minutes (186 to 271 minutes). The mean length of the hospital stay was 17.83 days (8 to 31 days).

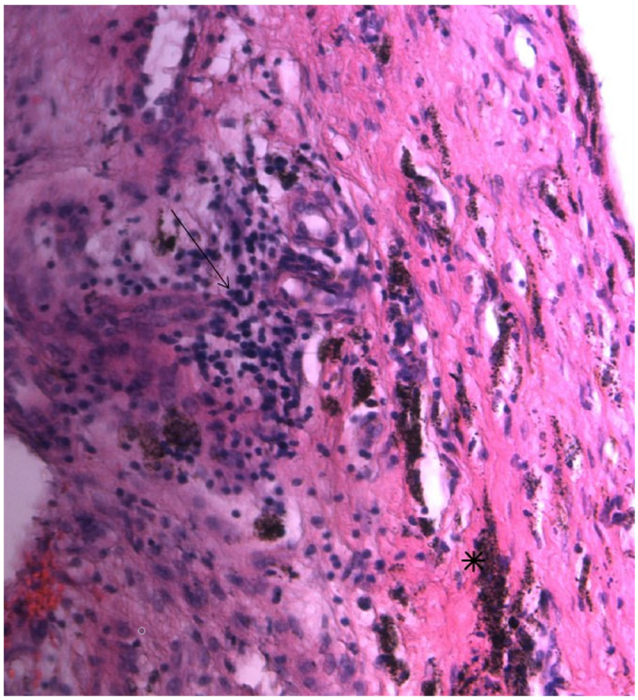

Fig. 2 HE, × 200; perivascular lymphocytes (arrow), with abundant adjacent abrasion material (star)

The individual test results for the patients are summarized in Tables 1 and 2.

Long-term clinical observation

The mean follow-up time after prosthesis exchange surgery was 24.4 ± 18.1 months (min 6.3 months, max 48.2 months).

In the clinical follow-up, and in comparison to the preoperative evaluation, a significant improvement of the Knee Society Score (subscale Knee Score and Functional Score) from 43, respectively, 47.5 points, to 70, respectively, 68.3 points was observed—this could be interpreted as an increase in the knee score from < 60 (poor) to 70–79 (good). In the clinical follow-up, the complaints were regressive in all patients. One patient (no. 4) attended only one of the follow-up appointments, about six months post-operatively, due to the onset of dementia. This patient later died of natural causes. At

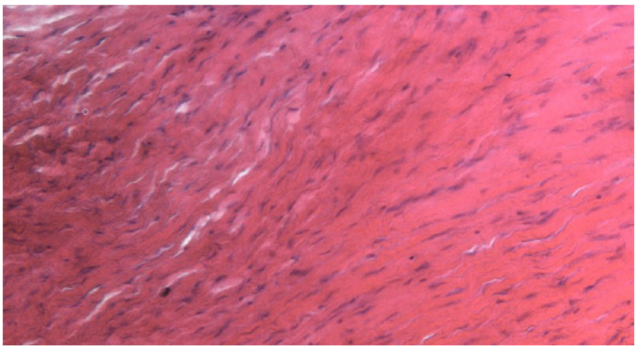

Fig. 3 HE, × 100; extensive fibrosis throughout the entire image

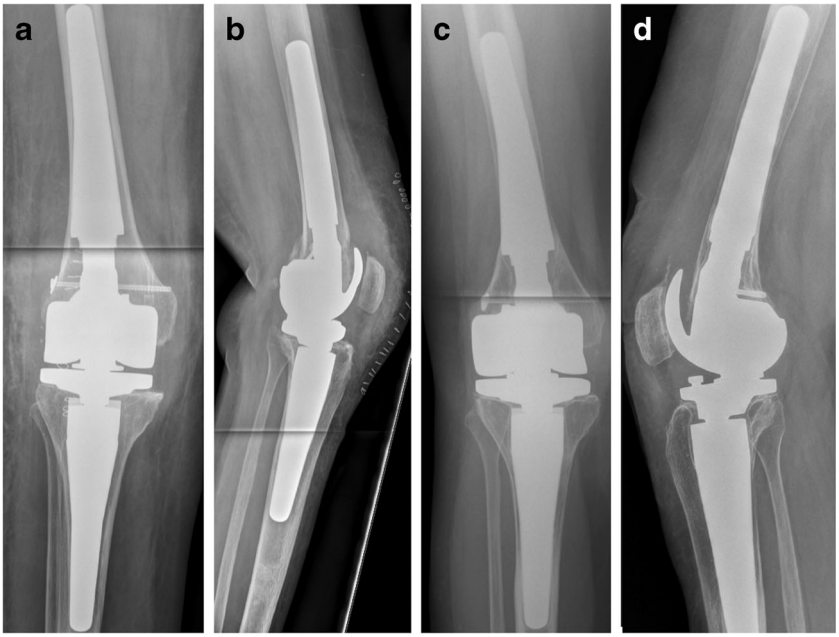

Fig. 4 Radiological follow-up of pat. no. 2 in two planes, directly after the operation (**a**, **b**) and 2 years post-operatively (**c**, **d**). Stress shielding of the distal femur, with a proximally well-integrated implant, can be clearly recognized

the time of the last post-operative follow-up examination, the knee joints of all six patients were free of irritation.

In four cases (pat. nos. 1, 4–6; 66.67%), the radiological evaluation over time showed osseointegration of the custom-made, cementless tibial and femoral shafts, which remained firmly attached, with no evidence of loosening or vertical migration (Fig. 5). In one case (pat. no. 3, 16.67%) vertical sintering occurred due to aseptic loosening of the tibial shaft. This was classified as an implant-specific complication, three years post-operatively. The tibial component was, therefore, exchanged 3.3 years after implantation of the cementless prosthesis. The microbiological and histopathological samples that had been collected intra-operatively showed no evidence of a PJI in this patient. In addition, one patient (pat. no. 2) showed a distal femoral stress shielding in the radiologic assessment during her last follow-up examination (see Fig. 4). This patient is currently on a three monthly clinical and radiological follow-up.

Patient no. 2 (16.67%) developed a deficit in knee flexion and extension that was refractory to conservative therapy,

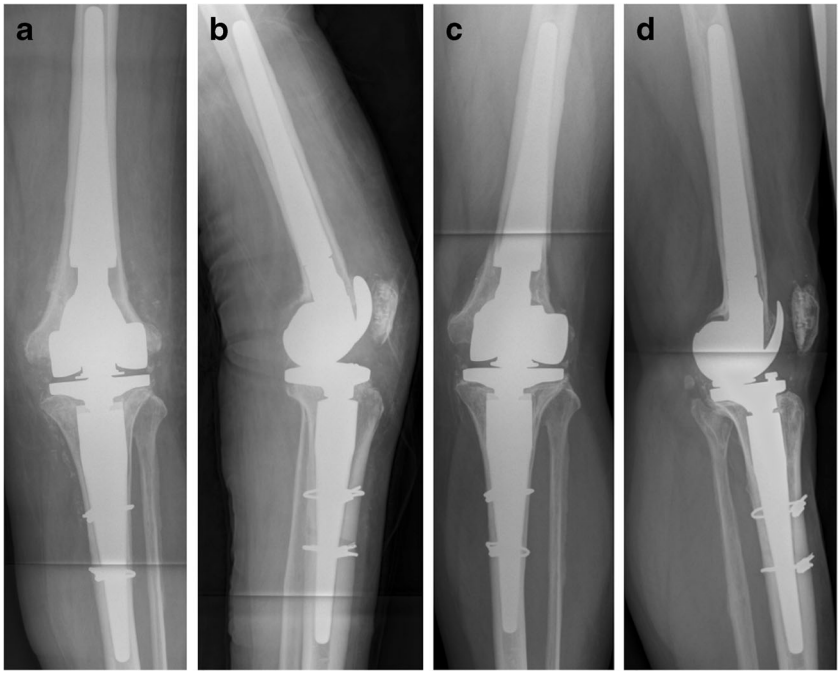

Fig. 5 Radiological follow-up of pat. no. 1 in two planes, directly after the operation (**a**, **b**), and 3 years postoperatively (**c**, **d**). The tibial cerclage wiring was necessary due to a tibial fissure after knee prosthesis explantation and attempt to attach an external fixator in the course of a two-step procedure

directly after the exchange operation, due to nonperformance of physiotherapeutic exercises and a refusal to participate in a rehabilitative procedure. Open arthrolysis thus had to be performed three months after the replantation of the prosthesis. This event was considered a non-implant-specific complication. With intensive physiotherapeutic exercise, the further post-operative course of the patient over the period up to the last post-operative examination, 26.2 months after the initial replantation, was uneventful.

Further reasons for revision, in terms of haematoma requiring surgical treatment, did not arise.

The total revision rate for implant failure was 16.67% (one out of six patients, no. 3, vertical sintering), and the total revision rate for non-implant-specific complications, i.e., revision surgery that did not require changing or removing prosthetic components, was also 16.67% (one out of six patients, no. 2, arthrolysis). All operations were considered clinically successful.

Discussion

Overall, only a few reports about implant-associated allergic reactions have been published so far [2, 5, 19]. There are also currently no guidelines for the further elucidation of complaints, in terms of a possible allergic genesis, in patients with a "painful endoprosthesis" [19, 20]. This circumstance is likely due to the difficulty of finding diagnostically sound evidence in cases of suspected implant allergy [21]. As demonstrated by the case series presented here, persistent complaints or premature implant loosening after TKA often lead to the tentative diagnosis of an implant allergy, via differential diagnosis. In light of the documented and predicted increase in the number of TKA, there is, however, an essential need to establish a high-validity means to allow diagnostic differentiation between prosthetic failure due to an allergic implant incompatibility and prosthetic failure due to other reasons [22]. The ability to straightforwardly diagnose implant allergies would not only be in the interest of patients, but it would also be of enormous economic importance for the health care system [23, 24].

To date, epicutaneous allergy testing is the standard diagnostic tool available to prove an implant allergy. The use of the standard and bone cement test series established by the German Contact Allergy Group is recommended in this context [2, 15]. There are, however, legitimate doubts whether the results observed in epicutaneous allergy testing can be transferred to the periprosthetic immune response [19]. Further, there is some debate as to whether the metallic and acrylic abrasion, degradation, and reaction products from prosthesis components can actually be properly reproduced, as encountered in the periprosthetic tissues, in epicutaneous testing patches [2, 15, 25]. Similarly, the standardized allergen exposure time of 48–96 h in patch testing differs markedly from the far longer exposure time to implant materials and their abrasion or decay products, where weeks, months, or even years may pass before subsequent allergic reactions to orthopaedic implants are described [2, 5, 26]. Other concerns in regard to patch tests include the development of dermal immunological tolerance, as well as the possibility of subsequent allergy induction in potentially sensitive, but still asymptomatic patients [19]. It is also still not understood to which extent periprosthetic hypersensitivity reactions may occur even without a concurrent positive epicutaneous test reaction [2].

BPO intolerance, in particular, is difficult to evaluate by patch testing [15]. Here, it is crucially important to distinguish between allergic and irritative skin reactions. This is of particular importance, as more highly concentrated BPO solutions (e.g., 1% compared to 0.5%) can cause skin reactions [27]. Moreover, a possible association of severe skin reactions to BPO has been described in the context of prior contact with topical acne therapeutics, especially in young women [28]. In view of the far-reaching consequences, BPO testing should, therefore, be repeated with a dilution series if the results are questionable [15].

The lymphocyte transformation test (LTT) is an in vitro alternative to the test methods described above. Here, the response of the lymphocytes from a patient's blood sample to an allergen is tested [29]. Advantages of this method are the avoidance of sensitization, the relatively high sensitivity of 55–95%, and the possibility of quantitatively evaluating the results [30]. Nevertheless, it is unclear whether a proven sensitivity in this test actually also manifests as a disease-causing hypersensitivity [31]. There is no general recommendation for the implementation of the LTT by the Robert Koch Institute [29]. The LTT test was not performed in our case series.

There are, currently, no recommendations for predictive allergy testing or even general pre-operative screening before (elective) TKA [5, 19, 32].

Histological and immunohistochemical examination of periprosthetic tissue can also provide further evidence for the diagnosis of implant-related hypersensitivity. In three of the cases reported here, perivascular lymphocytic infiltrates with CD3-expressing T lymphocytes, accompanied by extensive fibrosis of the periprosthetic membrane, were found present [1, 3, 33]. Delayed T cell–specific responses may occur either through a newly developed sensitization to implant materials or as a result of a contact allergy prior to arthroplasty [34]. The extent to which delayed T cell–specific immune responses to bone cement and its wear products can be regarded as the starting point for aseptic prosthetic loosening remains unclear [9, 35].

Although the positive epicutaneous tests, along with the detectable T cell–specific lymphocytic infiltrates and increased fibrosis in the periprosthetic tissues, suggest that an implant allergy was causal for the failure of the prostheses in

our cases, this could not be conclusively determined. It remains unclear whether the failure of the endoprostheses occurred due to a pre-existing hypersensitivity to implant materials, or if the sensitization was induced by the progressive failure of the prosthesis. It is well known that elevated metallic ion levels in TKA, without correlation with the implanted metallic volume or the BMI or physical activity, can be detected post-operatively [36]. Nonetheless, the possibility should be considered that a combination of progressive loosening of a prosthesis and a preexisting, or newly developed allergy may act together to, at least, accelerate the loosening cascade. It would, therefore, be extremely useful to be able to implement a validated diagnostic procedure prior to implantation of artificial joints, especially when risk factors such as a known, or suspected, hypersensitivity to implant materials have been described in the patient history. This could help detect and avoid possible adverse reactions that may lead to an early failure of the prosthesis.

In addition to the difficulty of diagnosing an implant allergy, it is still unclear to what extent BPO is released in the further course of time after polymerization of the bone cement, and, also, whether this is relevant in arthroplasty, in view of the fact that BPO is rapidly metabolized or decomposes within seconds [28, 37]. A long-term release of BPO has, however, been detected, especially in dental applications [15]. Long-term release of BPO could, thus, be a possible explanation for symptoms that arise after TKA and then subside after cementless RTKA.

Particularly in RTKA, anchoring of the prosthesis plays a decisive role. Shaft-anchored implants show a significantly lower revision rate despite the greater bone loss. Diaphyseal anchoring is possible through full cementation or in press-fit hybrid technique with pure undersurface cementation of the femoral and tibial component. The latter technique is increasingly being used, especially in young patients and in anticipation of future revision surgery [38]. Neither of these two options is available if cementless anchoring is required. There are currently only a few reports about entirely cementless RTKA in the literature [39, 40].

Despite improved values in the KSS, we detected femoral stress shielding in one case during radiological follow-up as a result of the entirely cementless diaphyseal anchoring of the implant. According to a study by Hackenberg et al., additional metaphyseal (zone 2) anchoring should be performed in addition to diaphyseal anchoring to avoid this problem [41].

Our study does have several limitations, not least due to the small number of cases and the heterogeneity of the patient group (diagnosed metal and BPO allergy in three patients, and BPO allergy only in the other three patients), which made it impossible to distinguish between a metal allergy and a BPO allergy as a possible underlying cause for a postulated subsequent allergic loosening. Nevertheless, this retrospective case series is, to our best knowledge, one of the largest in this thematic field.

The local and temporal association of the regression of complaints after replacement of the implanted components with cement-free and nickel-free revision implants makes an allergic implant intolerance appear likely as a contributing cause for the patients' painful endoprosthesis in our cases. The implantation of a cementless, diaphyseal anchoring, hypoallergenic knee endoprosthesis may, thus, possibly be a surgical treatment strategy in patients with painful endoprostheses and known cement or metal allergies. This strategy must however be carefully considered in view of the risk of post-operative stress shielding due to the distal prosthetic anchorage of such prostheses. An additional metaphyseal anchoring could solve this problem.

The case series presented here exemplifies how challenging it is to evaluate cases in which patients are suspected of having a hypersensitivity to implant materials after TKA. Studies to understand the underlying pathomechanisms—in particular, the cellular interactions in the context of orthopaedic implants—should be at the heart of intensified future research efforts. The establishment of valid test protocols that also take possible metal or polymer allergies into account in the pre- and post-operative differential diagnosis of a "painful endoprosthesis" is of particular importance.

Compliance with ethical standards

Conflict of interest S. Gravius has received a speaker honorarium from Waldemar LINK GmbH and financial support from Waldemar LINK GmbH to participate at a surgery course. The other authors declare that they have no conflict of interest. No benefits have been or will be received from a commercial party related directly or indirectly to the subject matter of this article.

Ethical approval All procedures performed in studies involving human participants were in accordance with the ethical standards of the institutional and/or national research committee and with the 1964 Helsinki declaration and its later amendments or comparable ethical standards. For this type of study, formal consent is not required.

References

1. Thomas P, Thomsen M (2008) Allergiediagnostik bei Metallimplantatunverträglichkeit. Orthopade 37:131–135. https://doi.org/10.1007/s00132-008-1194-8
2. Schuh A, Thomas P, Reinhold R, Holzwarth U, Zeiler G, Mahler V (2006) Allergie auf Knochenzementbestandteile nach Knieendoprothesenimplantation. Zentralblatt Für Chir 131:429–431. https://doi.org/10.1055/s-2006-949533
3. Thomas P, von der Helm C, Schopf C, Mazoochian F, Frommelt L, Gollwitzer H, Schneider J, Flaig M, Krenn V, Thomas B, Summer B (2015) Patients with intolerance reactions to total knee replacement: combined assessment of allergy diagnostics, periprosthetic histology, and peri-implant cytokine expression pattern. Biomed Res Int 2015:1–9. https://doi.org/10.1155/2015/910156
4. Thomas P (2003) Allergien durch Implantatwerkstoffe. Orthopäde 32:60–64. https://doi.org/10.1007/s00132-002-0413-y

5. Granchi D, Cenni E, Giunti A, Baldini N (2012) Metal hypersensitivity testing in patients undergoing joint replacement: a systematic review. J Bone Joint Surg Br 94:1126–1134. https://doi.org/10.1302/0301-620X.94B8.28135
6. Schäfer T, Böhler E, Ruhdorfer S, Weigl L, Wessner D, Filipiak B, Wichmann HE, Ring J (2001) Epidemiology of contact allergy in adults. Allergy 56:1192–1196
7. Kaplan K, Della Valle CJ, Haines K, Zuckerman JD (2002) Preoperative identification of a bone-cement allergy in a patient undergoing total knee arthroplasty. J Arthroplast 17:788–791
8. Dejobert Y, Piette F, Thomas P (2002) Contact dermatitis from benzoyl peroxide in dental prostheses. Contact Dermatitis 46:177–178
9. Willert H-G, Buchhorn GH, Fayyazi A, Flury R, Windler M, Köster G, Lohmann CH (2005) Metal-on-metal bearings and hypersensitivity in patients with artificial hip joints: a clinical and histomorphological study. JBJS 87:28–36
10. Klimek L (2015) Allergiediagnostik in der Praxis: Was der Hausarzt wissen sollte. Dtsch Aerzteblatt Online. https://doi.org/10.3238/PersPneumo.2015.10.02.03
11. Krenn V, Morawietz L, Kienapfel H, Ascherl R, Matziolis G, Hassenpflug J, Thomsen M, Thomas P, Huber M, Schuh C, Kendoff D, Baumhoer D, Krukemeyer MG, Perino G, Zustin J, Berger I, Rüther W, Poremba C, Gehrke T (2013) Revised consensus classification. Histopathological classification of diseases associated with joint endoprostheses. Z Rheumatol 72:383–392. https://doi.org/10.1007/s00393-012-1099-0
12. van Hove RP, Brohet RM, van Royen BJ, Nolte PA (2016) High correlation of the Oxford Knee Score with postoperative pain, but not with performance-based functioning. Knee Surg Sports Traumatol Arthrosc 24:3369–3375. https://doi.org/10.1007/s00167-015-3585-9
13. Parvizi J, Zmistowski B, Berbari EF, Bauer TW, Springer BD, Della Valle CJ, Garvin KL, Mont MA, Wongworawat MD, Zalavras CG (2011) New definition for periprosthetic joint infection: from the workgroup of the musculoskeletal infection society. Clin Orthop 469:2992–2994. https://doi.org/10.1007/s11999-011-2102-9
14. Wimmer MD, Randau TM, Petersdorf S, Pagenstert GI, Weißkopf M, Wirtz DC, Gravius S (2013) Evaluation of an interdisciplinary therapy algorithm in patients with prosthetic joint infections. Int Orthop 37:2271–2278. https://doi.org/10.1007/s00264-013-1995-1
15. Bircher A, Friederich NF, Seelig W, Scherer K (2012) Allergic complications from orthopaedic joint implants: the role of delayed hypersensitivity to benzoyl peroxide in bone cement. Contact Dermatitis 66:20–26. https://doi.org/10.1111/j.1600-0536.2011.01996.x
16. Hischebeth GTR, Randau TM, Molitor E, Wimmer MD, Hoerauf A, Bekeredjian-Ding I, Gravius S (2016) Comparison of bacterial growth in sonication fluid cultures with periprosthetic membranes and with cultures of biopsies for diagnosing periprosthetic joint infection. Diagn Microbiol Infect Dis 84:112–115. https://doi.org/10.1016/j.diagmicrobio.2015.09.007
17. Morawietz L (2006) Proposal for a histopathological consensus classification of the periprosthetic interface membrane. J Clin Pathol 59:591–597. https://doi.org/10.1136/jcp.2005.027458
18. Healy WL, Della Valle CJ, Iorio R, Berend KR, Cushner FD, Dalury DF, Lonner JH (2013) Complications of total knee arthroplasty: standardized list and definitions of the knee society. Clin Orthop Relat Res 471:215–220. https://doi.org/10.1007/s11999-012-2489-y
19. Roberts TT, Haines CM, Uhl RL (2017) Allergic or hypersensitivity reactions to orthopaedic implants. J Am Acad Orthop Surg 25:693–702. https://doi.org/10.5435/JAAOS-D-16-00007
20. Lohmann CH, Hameister R, Singh G (2017) Allergies in orthopaedic and trauma surgery. Orthop Traumatol Surg Res 103:75–81. https://doi.org/10.1016/j.otsr.2016.06.021
21. Zeng Y, Feng W, Li J, Lu L, Ma C, Zeng J, Li F, Qi X, Fan Y (2014) A prospective study concerning the relationship between metal allergy and post-operative pain following total hip and knee arthroplasty. Int Orthop 38:2231–2236. https://doi.org/10.1007/s00264-014-2367-1
22. Bozic KJ, Kamath AF, Ong K, Lau E, Kurtz S, Chan V, Vail TP, Rubash H, Berry DJ (2015) Comparative epidemiology of revision arthroplasty: failed THA poses greater clinical and economic burdens than failed TKA. Clin Orthop Relat Res 473:2131–2138. https://doi.org/10.1007/s11999-014-4078-8
23. Haddad FS, Cobb AG, Bentley G, Levell NJ, Dowd PM (1996) Hypersensitivity in aseptic loosening of total hip replacements. The role of constituents of bone cement. J Bone Joint Surg Br 78:546–549
24. Kurtz SM, Ong KL, Lau E, Bozic KJ (2014) Impact of the economic downturn on total joint replacement demand in the United States: updated projections to 2021. J Bone Jt Surg-Am 96:624–630. https://doi.org/10.2106/JBJS.M.00285
25. Boeckler A, Morton D, Poser S, Dette K (2008) Release of dibenzoyl peroxide from polymethyl methacrylate denture base resins: an in vitro evaluation. Dent Mater 24:1602–1607. https://doi.org/10.1016/j.dental.2008.03.019
26. Dudda M, Godau P, Al-Benna S, Schildhauer TA, Gothner M (2013) Vitiligo and allergic complications from orthopaedic joint implants: the role of benzoyl peroxide. Recent Patents Inflamm Allergy Drug Discov 7:176–182
27. Uter W, Rämsch C, Aberer W, Ayala F, Balato A, Beliauskiene A, Fortina AB, Bircher A, Brasch J, Chowdhury MM (2009) The European baseline series in 10 European countries, 2005/2006–results of the European Surveillance System on Contact Allergies (ESSCA). Contact Dermatitis 61:31–38
28. Geier J, Lessmann H, Becker D, Thomas P (2008) Allergologische Diagnostik bei Verdacht auf Implantatunverträglichkeit: Hinweise für die Praxis: Eine Stellungnahme der Deutschen Kontaktallergie-Gruppe (DKG). Hautarzt 59:594–597. https://doi.org/10.1007/s00105-008-1587-y
29. Eis D, Wolf U (2008) "Qualitätssicherung beim Lymphozytentransformationstest" – Addendum zum LTT-Papier der RKI-Kommission "Methoden und Qualitätssicherung in der Umweltmedizin": Mitteilung der Kommission "Methoden und Qualitätssicherung in der Umweltmedizin". Bundesgesundheitsbl Gesundheitsforsch Gesundheitsschutz 51:1070–1076. https://doi.org/10.1007/s00103-008-0641-3
30. Akil S, Newman JM, Shah NV, Ahmed N, Deshmukh AJ, Maheshwari AV (2018) Metal hypersensitivity in total hip and knee arthroplasty: current concepts. J Clin Orthop Trauma 9:3–6. https://doi.org/10.1016/j.jcot.2017.10.003
31. Thomas P (2014) Clinical and diagnostic challenges of metal implant allergy using the example of orthopaedic surgical implants. Allergo J Int 23:179–185. https://doi.org/10.1007/s40629-014-0023-3
32. Guenther D, Thomas P, Kendoff D, Omar M, Gehrke T, Haasper C (2016) Allergic reactions in arthroplasty: myth or serious problem? Int Orthop 40:239–244. https://doi.org/10.1007/s00264-015-3001-6
33. Witzleb W-C, Hanisch U, Kolar N, Krummenauer F, Guenther K-P (2007) Neo-capsule tissue reactions in metal-on-metal hip arthroplasty. Acta Orthop 78:211–220. https://doi.org/10.1080/17453670710013708
34. Holzwarth U, Thomas P, Kachler W, Göske J, Schuh A (2005) Metallkundliche Differenzierung von Kobalt-Chrom-Legierungen für Implantate. Orthopade 34:1046–1051. https://doi.org/10.1007/s00132-005-0849-y
35. Natu S, Sidaginamale RP, Gandhi J, Langton DJ, Nargol AVF (2012) Adverse reactions to metal debris: histopathological features of periprosthetic soft tissue reactions seen in association with failed

metal on metal hip arthroplasties. J Clin Pathol 65:409–418. https://doi.org/10.1136/jclinpath-2011-200398
36. Lons A, Putman S, Pasquier G, Migaud H, Drumez E, Girard J (2017) Metallic ion release after knee prosthesis implantation: a prospective study. Int Orthop 41:2503–2508. https://doi.org/10.1007/s00264-017-3528-9
37. Treudler R, Simon JC (2007) Benzoyl peroxide: is it a relevant bone cement allergen in patients with orthopaedic implants? Contact Dermatitis 57:177–180
38. Fleischman AN, Azboy I, Fuery M, Restrepo C, Shao H, Parvizi J (2017) Effect of stem size and fixation method on mechanical failure after revision total knee arthroplasty. J Arthroplast. https://doi.org/10.1016/j.arth.2017.04.055
39. Schwarzkopf R (2015) Total knee arthroplasty failure induced by metal hypersensitivity. Am J Case Rep 16:542–547. https://doi.org/10.12659/AJCR.893609
40. Thakur RR, Ast MP, McGraw M, Bostrom MP, Rodriguez JA, Parks ML (2013) Severe persistent synovitis after cobalt-chromium total knee arthroplasty requiring revision. Orthopedics 36:e520–e524. https://doi.org/10.3928/01477447-20130327-34
41. Hackenberg RK, Nessler J, König DP (2018) First application of segmental trabecular metal cones in a custom-made revision tumor prosthesis of the knee: a technical note. Technol Health Care 26:195–202. https://doi.org/10.3233/THC-170895