Allergy Asthma Immunol Res. 2022 Jan;14(1):59-72
https://doi.org/10.4168/aair.2022.14.1.59
pISSN 2092-7355·eISSN 2092-7363

Allergy, Asthma & Immunology Research AAIR

Original Article

Check for updates

Particulate Matter Exposure Aggravates IL-17-Induced Eye and Nose Inflammation in an OVA/Poly(I:C) Mouse Model

Jun-Sang Bae,[1,2,3†] **Soo Bin Oh**,[4,5†] **Jeongyun Kim**,[6] **Hoon Kim**,[4] **Ji Hye Kim**,[1,2] **Eun-Hee Kim**,[1,2] **Kyong Jin Cho**,[4*] **Ji-Hun Mo**[1,2,3*]

[1]Department of Otorhinolaryngology, College of Medicine, Dankook University, Cheonan, Korea
[2]Beckman Laser Institute Korea, Dankook University, Cheonan, Korea
[3]Medical Laser Research Center, Dankook University, Cheonan, Korea
[4]Department of Ophthalmology, College of Medicine, Dankook University, Cheonan, Korea
[5]Catholic Institute for Visual Science, College of Medicine, The Catholic University of Korea, Seoul, Korea
[6]Department of Physics, College of Natural Sciences, Dankook University, Cheonan, Korea

OPEN ACCESS

Received: Jul 8, 2021
Revised: Sep 23, 2021
Accepted: Oct 12, 2021
Published online: Dec 15, 2021

Correspondence to
Ji-Hun Mo, MD, PhD
Department of Otorhinolaryngology, College of Medicine, Dankook University, 119 Dandae-ro, Dongnam-gu, Cheonan 31116, Korea.
Tel: +82-41-550-3933
Fax: +82-41-556-1090
Email: jihunmo@gmail.com

Kyong Jin Cho, MD, PhD
Department of Ophthalmology, College of Medicine, Dankook University, 119 Dandae-ro, Dongnam-gu, Cheonan 31116, Korea.
Tel: +82-41-550-3945
Fax: +82-41-550-7649
Email: perfectcure@hanmail.net

†Jun-Sang Bae and Soo Bin Oh equally contributed to this work.

Copyright © 2022 The Korean Academy of Asthma, Allergy and Clinical Immunology · The Korean Academy of Pediatric Allergy and Respiratory Disease
This is an Open Access article distributed under the terms of the Creative Commons Attribution Non-Commercial License (https://creativecommons.org/licenses/by-nc/4.0/) which permits unrestricted non-commercial use, distribution, and reproduction in any medium, provided the original work is properly cited.

ORCID iDs
Jun-Sang Bae
https://orcid.org/0000-0003-2589-797X

ABSTRACT

Purpose: Data on the effects of direct particulate matter (PM) exposure on the eyes and the nose are limited. Here, an interleukin (IL)-17/neutrophil-dominant ovalbumin (OVA)/polyinosinic-polycytidylic acid (Poly(I:C)) mouse model was used to evaluate the effect of different-sized titanium dioxide (TiO_2) particles on the eyes and the nose. We also examined whether IL-17-neutralizing antibody (IL-17Ab) treatment could reverse TiO_2 effects.
Methods: The nasal cavities and conjunctival sacs of each mouse were challenged with OVA and Poly(I:C) to induce neutrophil-dominant inflammation and then exposed to micro- and nano-TiO_2. Subsequently, IL-17Ab was administered to investigate the role of IL-17 and inflammatory parameters.
Results: Micro- and nano-TiO_2 resulted in significant decreases in tear-break-up time and increases in corneal damage. Airborne micro-TiO_2 also increased nasal rubbing and sneezing counts compared with the OVA/Poly(I:C). Micro-TiO_2 exposure increased infiltration of neutrophils and IL-17A+ cells in the conjunctival tissues and the nasal mucosae. In addition, these increased symptoms and inflammation in the eyes and the nose by micro-TiO_2 exposure were inhibited by the IL-17Ab, suggesting IL-17 dependency.
Conclusions: TiO_2 aggravated IL-17-induced eye and nose inflammation and the IL-17Ab alleviated inflammation in the OVA/Poly(I:C) mouse model. These results may help develop a therapeutic modality for PM exposure and provide evidence for PM-associated diseases.

Keywords: Particulate matter; rhinitis; interleukin-17, conjunctivitis

INTRODUCTION

Air pollution induces various adverse health effects, including acute and chronic diseases of various organ systems. Furthermore, particulate matters (PMs), a complex mixture of solid and liquid particles suspended in air, are known to be the main contributor of air pollution.[1,2] The accumulation of PM might pose different health risks, depending on the

Generated by xmlinkpress

Soo Bin Oh
https://orcid.org/0000-0002-5150-5039
Jeongyun Kim
https://orcid.org/0000-0003-4085-5444
Hoon Kim
https://orcid.org/0000-0002-7932-1880
Ji Hye Kim
https://orcid.org/0000-0003-2516-774X
Eun-Hee Kim
https://orcid.org/0000-0002-9539-9928
Kyong Jin Cho
https://orcid.org/0000-0003-1468-467X
Ji-Hun Mo
https://orcid.org/0000-0003-1331-364X

Disclosure
There are no financial or other issues that might lead to conflict of interest.

size and exposure route to the body. PMs enter the body through the following 3 main routes: inhalation via the respiratory system, ingestion via the digestive system, and absorption via the integumentary system.[3,4] They are responsible for increased acute and chronic respiratory symptoms, cardiovascular conditions, and other related allergic reactions, resulting in more hospital admissions and emergency room visits.[5]

Among the health risks, acute and chronic diseases in the eyes and the nose, such as conjunctivitis and rhinitis, are the most common. They are both known to have inflammatory symptoms and be caused by different kinds of environmental factors. Recent studies suggested that PM could be a major factor exacerbating the inflammation in both conjunctivitis and rhinitis,[6,7] triggering inflammatory responses involving numerous cytokines and chemokines. Particularly, the cytokine interleukin-17 (IL-17) is known to be a strong inducer of inflammation in conjunctivitis and rhinitis.[8,9]

Several studies have attempted to reveal the correlation between PM-related air pollution and various health issues based on clinical data.[5,10] However, only a few *in vivo* studies have been conducted,[11,12] and therefore, the direct effect of PM exposure on the eyes and nose and its underlying mechanisms need to be studied.[13]

Titanium dioxide (TiO_2) is a metal oxide nanoparticle which usually used in commercial products such as paints, carpets cosmetics and textiles.[14,15] Due to its small size, TiO_2 can cause damage to the eye surface, resulting in ocular inflammation. Symptoms include dryness, burning, itching, conjunctival injection, conjunctival chemosis, and swelling of eyelids.[16] TiO_2 nanoparticles can also deposit to different parts of the respiratory system such as the nose and the lungs that causes inflammation.[17,18]

In this study, the IL-17/neutrophil dominant ovalbumin (OVA)/polyinosinic-polycytidylic acid (Poly(I:C)) mouse model was used to evaluate the effect of different-sized TiO_2 on the mucosa of the eyes and the nose to confirm the role of IL-17 in the inflammatory process. In addition, we examined whether treatment with the IL-17-neutralizing antibody (IL-17Ab) could reverse the effect of TiO_2 on the eyes and nose.

MATERIALS AND METHODS

Protocol for mouse conjunctivitis and rhinitis model and exposure of TiO_2

To evaluate the effects of TiO_2 on the OVA/Poly(I:C) mouse model, 20 female BALB/c mice were divided into 4 groups.; 1) negative control group ((−) control), 2) positive control group (OVA/Poly(I:C)), 3) micro size TiO_2 + OVA/Poly(I:C) group (micro-TiO_2 + Poly(I:C)), and 4) nano size TiO_2 + OVA/Poly(I:C) group (nano-TiO_2+Poly(I:C)) (**Fig. 1A**). Mice with positive control and TiO_2 + OVA/Poly(I:C) groups were locally sensitized with OVA (3.75 mg/mL)/Poly(I:C) (2.5 mg/mL) mixture in the conjunctival sac/or intranasally (20 μL) on day 1, 2, 3, 7 and 14. For the challenge, OVA (5 mg/mL, 20 μL/mouse) was administered into the same route from day 15 to day 20. In case of the micro size TiO_2 + OVA/Poly(I:C) group, the mice were exposed to micro-sized airborne TiO_2 (particulate matter less than 10 μm [PM_{10}], 600–700 μg/m^3) in a TiO_2 exposure chamber for 2 hours from day 14 to 20 (about 50 μg/m^3 based on 24 hours), which is similar to the short-term (24-hour) limit value (50 μg/m^3) of the Air Quality Guidelines set forth by the WHO for PM_{10}.[19] Nano size TiO_2 (50 μg/mL, 20 μL/mouse/day) was administered into the conjunctival sac or the nasal cavity from day

14 to 20. Mice were sacrificed via cervical dislocation on day 21. The Dankook University Institutional Animal Care & Use Committee on the use and care of animal approved all animal experiments (DKU-17-021). All animal experiments were repeated 3 times, and the number of mice in each group was 5.

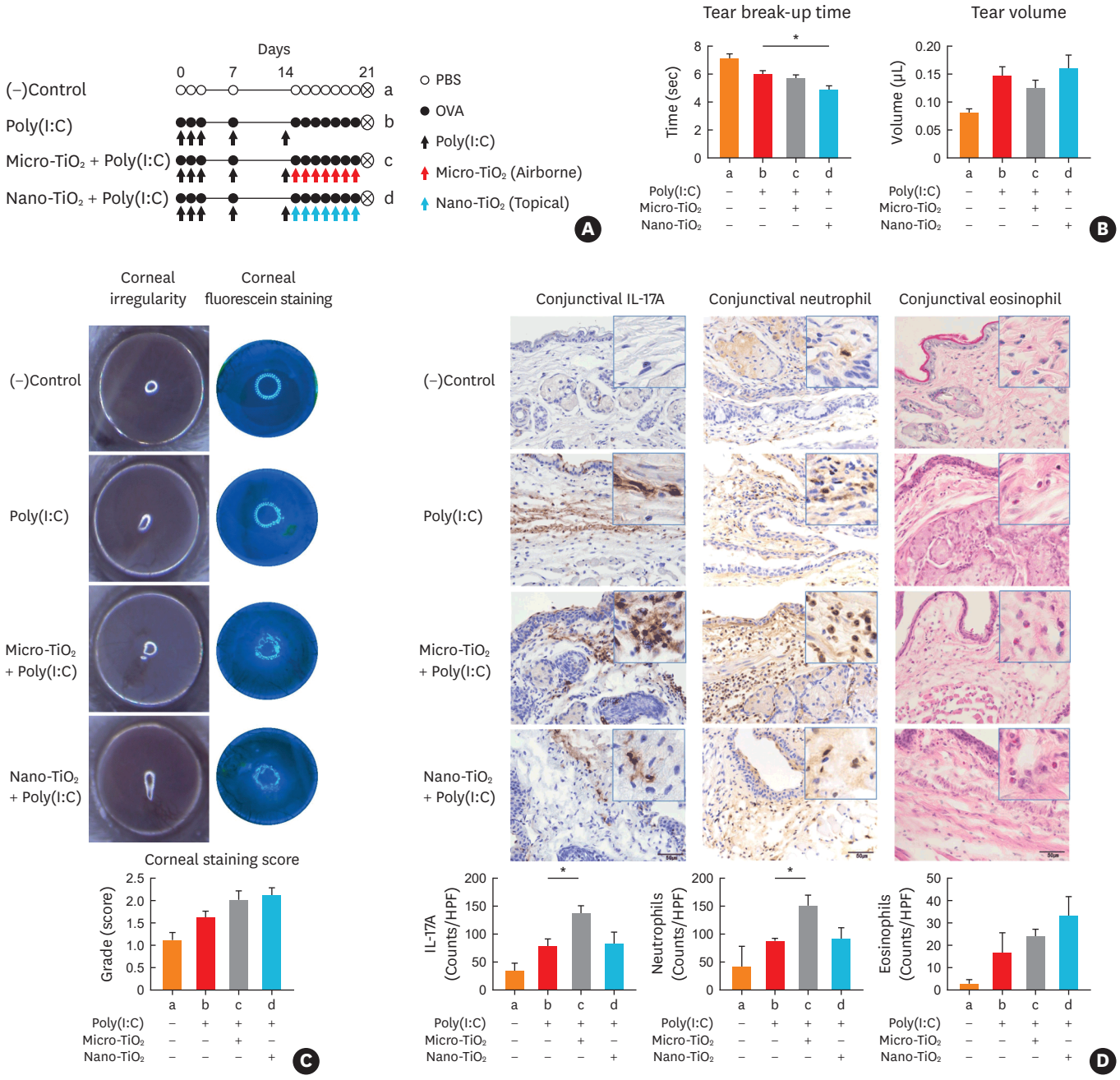

Fig. 1. The influences of exposed TiO_2 size on OVA/Poly(I:C) conjunctivitis mouse model. (A) Protocol for the induction of conjunctivitis and rhinitis with OVA/Poly(I:C) and micro or nano size TiO_2 in mice. (B) Tear-break-up time and tear volume measurements in all groups. (C) Corneal irregularities and corneal fluorescein staining images with corneal staining scores. (D) Histological staining for IL-17A-producing cells, conjunctival neutrophil, and conjunctival eosinophil. IL-17A producing cell counts (× 400 magnification, IHC with IL-17A antibody). Conjunctival neutrophil counts (× 400 magnification, IHC with NIMP-R14 antibody). Conjunctival eosinophil counts (× 400 magnification, IHC with hematoxylin and eosin staining).
TiO_2, titanium dioxide; OVA, ovalbumin; Poly(I:C), polyinosinic-polycytidylic acid; IL, interleukin; IHC, immunohistochemistry; PBS, phosphate buffered saline.
*$P < 0.05$.

Treatment of IL-17 neutralization antibody

An OVA/Poly(I:C) animal model and airborne micro size TiO_2 treatment were the same as in **Fig. 1A**, except that only airborne micro size TiO_2 treatment group and IL-17 neutralization antibody treatment group were added (n = 5/group). The micro TiO_2 group treated only airborne micro size TiO_2 without OVA/Poly(I:C) sensitization and OVA challenge, and IL-17 neutralization antibody administration was injected intraperitoneally for 7 days (day 14–20, 500 μg/mouse, 200 μL/mouse/day) in the same manner as OVA challenge and airborne micro size TiO_2 treatment.

TiO_2 exposure chamber

An exposure chamber with 6 fans was constructed for the exposure of TiO_2 particles on the ocular surface and nasal mucosa of mouse in this study. Titanium (IV) oxide, rutile, 99.5% (metal basis) with a mean diameter of 1.0 to 2.0 μm (Alfa Aesar; Johnson Matthey GmbH, Karlsruhe, Germany) was put in the exposure chamber, and airborne particle concentration in the exposure chambers was adjusted for PM_{10} as measured by a MetOne 831 Aerosol Mass Monitor (Met One, Grants Pass, OR, USA). The range of airborne TiO_2 particle concentration during the study period was 600–700 μg/m^3.

Assessment of the ocular and nasal inflammation

The inflammation in the eyes were assessed by the standard tear break-up time (BUT) measurement,[20] tear volume measurements,[21] corneal irregularities,[21] and corneal damage scores.[22] Corneal damage was evaluated using Oxford schema, and the grades were marked as follows: 0, normal; 1–2, mild to moderate; and > 3, severe.[23] The damages on the surface of the cornea were stained by the fluorescein dye and appeared green under the blue light.

For nasal symptoms, in a blind manner, the observer recorded the frequencies of sneezing and nasal rubbing for 15 minutes after the final OVA challenge.

Tissue preparations

Whole eyes of the mice were surgically excised and fixed in 4% formalin overnight. Next day, the eyes were transferred to 15% sucrose (Sigma-Aldrich, St. Louis, MO, USA) for 4 hours then, 30% sucrose overnight. They were embedded in Optimal Cutting Temperature (O.C.T.) compound (Tissue-Tek O.C.T. Compound; Sakura, Tokyo, Japan) for cryostat sectioning.

Half of the head was removed *en bloc* and fixed in 4% paraformaldehyde. The nasal mucosa was removed from the nasal cavity of the other half of the head using a small curette, immediately immersed in TRIzol reagent (Invitrogen, Carlsbad, CA, USA), and stored at −80°C until use for reverse transcription-quantitative polymerase chain reaction (RT-qPCR).

Eosinophils and cell aggregation in the conjunctival and nasal mucosa

Hematoxylin and eosin staining was performed to count the number of eosinophils in the conjunctival sac. The nasal septum histology was evaluated using standard Sirius red staining. The detailed procedure was described in our previous report.[24]

Immunohistochemistry (IHC)

Prepared conjunctival and nasal mucosa sections were immunostained with NIMP-R14 (neutrophil marker, ab2557, 1:100; Abcam, Cambridge, MA, USA), IL-17 (LS-B4912, 1:100; LSbio, Seattle, WA, USA), IL-1β (ab9722, 1:200, Abcam), TNF-α (ab6671, 1:200; Abcam), CD4 (sc-13573, 1:200; Santa Cruz Biotechnology, Santa Cruz, CA, USA), and B220 (B cell

https://doi.org/10.4168/aair.2022.14.1.59

marker,14-0452-82, 1:50, eBioscience, San Diego, CA, USA) antibodies using Avidin-Biotinylated-Horseradish Peroxidase (HRP) Kits (Vector Laboratories, Burlingame, CA, USA). The detailed procedure was described in our previous report.[24]

Assay of IL-4, IL-17, and interferon (IFN)-γ levels in nasal mucosa

Total RNA was prepared from nasal mucosa using TRIzol reagent (Invitrogen). cDNA was synthesized from 1 μg of RNA using the iScript cDNA Synthesis Kit (Bio-Rad, Hercules, CA, USA). For analysis of IL-4 (Mm00445258_g1), IL-17 (Mm00439618_m1), IFN-γ (Mm99999071_m1), and glyceraldehyde 3-phosphate dehydrogenase (GAPDH; Mm03302249_g1), pre-developed assay reagent kits were used (Applied Biosystems, Foster City, CA, USA). Quantitative reverse transcription-polymerase chain reaction (qRT-PCR) was performed on the ABI 7500 Real-Time PCR System (Applied Biosystems). Mean transcript levels were normalized to that of GAPDH.

Serum levels of total IgE and OVA-specific IgE, IgG1, and IgG2a

The serum levels of total and OVA-specific IgE, IgG1, and IgG2a were measured by solid-phase enzyme-linked immunosorbent assay. The detailed procedure was described in our previous report.[24]

Statistical analysis

Statistical analysis was performed using SPSS software version 22.0 (SPSS Inc., Chicago, IL, USA). Data were tested using the Kruskal-Wallis test with Dunn multiple comparison test. A P value < 0.05 was considered as statistically significant.

RESULTS

Effect of TiO_2 exposure on the OVA/Poly(I:C) conjunctivitis and rhinitis mouse models

OVA/Poly(I:C)-induced mouse models were exposed to TiO_2 of different sizes to investigate its size-dependent effects in the conjunctival sac and nasal cavity.

As a result, tear BUT decreased in all case groups, compared to the (−) control. Nano-TiO_2 + Poly(I:C) group had the shortest BUT, followed by micro-TiO_2 + Poly(I:C) and Poly(I:C) groups, indicating that the size of TiO_2 affected BUT (**Fig. 1B**). Tear volume measurement showed that Poly(I:C) and TiO_2-exposed groups had more amount of tear than control group, as a symptom of eye irritation. Although micro-TiO_2 + Poly(I:C) group had the lowest tear volume, there were no significant differences among all groups (**Fig. 1B**).

White ring irregularities on corneal surface were observed in all the groups except the (−) control (**Fig. 1C**). The degree of irregularity was more severe in nano-TiO_2 + OVA/Poly(I:C) group, followed by Poly(I:C) and micro-TiO_2 + OVA/Poly(I:C) groups, indicating that nano-TiO_2 caused more damage on the corneal surface than micro-TiO_2. In addition, corneal fluorescein staining, which represents corneal damage, showed more damage in both micro-TiO_2 + Poly(I:C) and nano-TiO_2 + Poly(I:C) group, however, there was no statistically significant difference between micro-TiO_2 + Poly(I:C) and nano-TiO_2 + Poly(I:C) groups (**Fig. 1C**).

IHC showed that the level of IL-17A, neutrophil, and eosinophil increased in Poly(I:C) and TiO_2-exposed groups (**Fig. 1D**). Especially, IL-17A and neutrophil level increased significantly

https://doi.org/10.4168/aair.2022.14.1.59

in micro-TiO_2 + Poly(I:C) group, indicating that micro-TiO_2 induced IL-17 and neutrophil related inflammatory process.

The nasal symptom score was significantly higher in the micro-TiO_2 + OVA/Poly(I:C) group than in the (−) control and nano-TiO_2 + OVA/Poly(I:C) groups (**Fig. 2A**). IL-17A mRNA expression was significantly higher in the micro-TiO_2 + OVA/Poly(I:C) group than in the

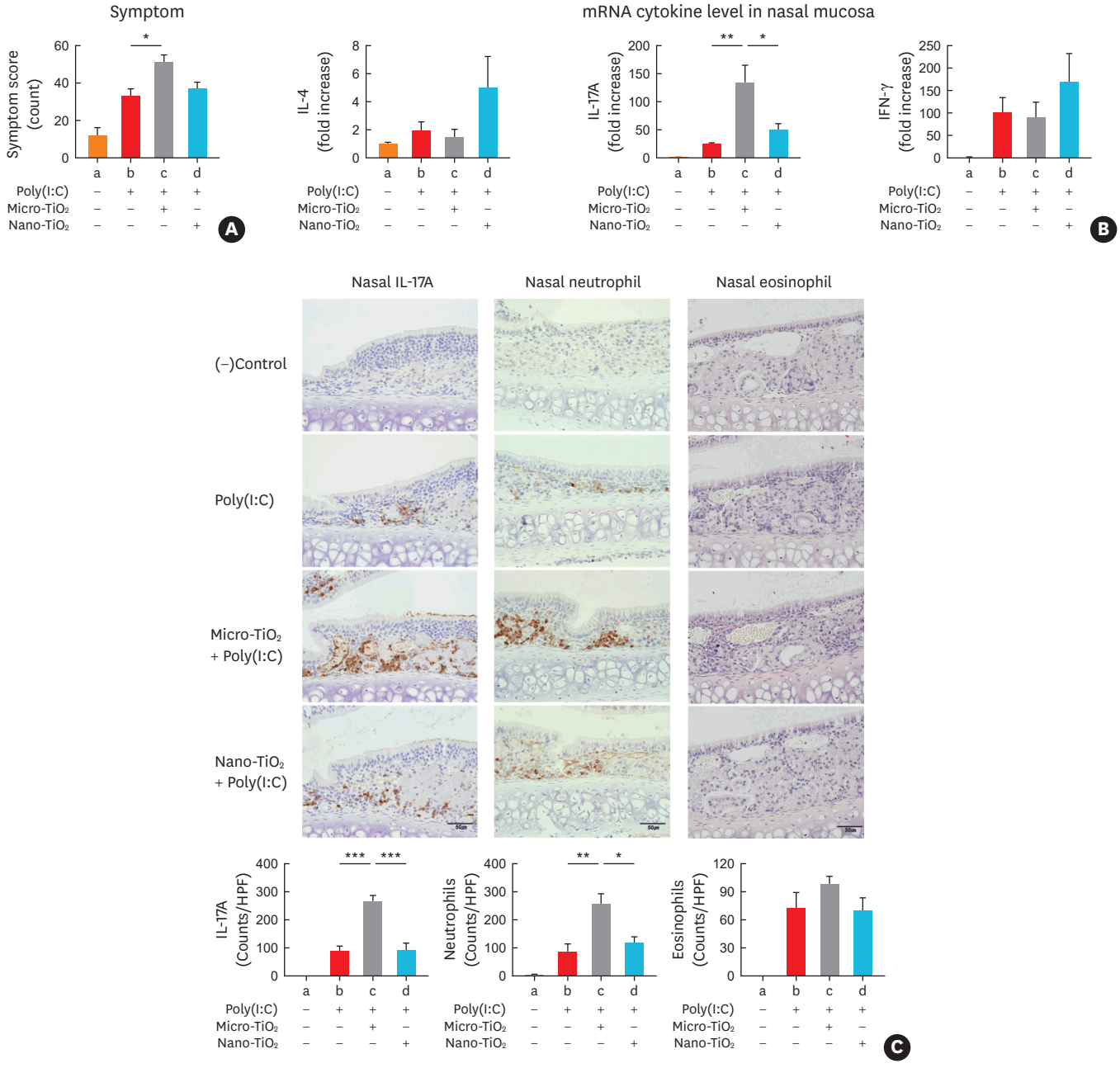

Fig. 2. The influences of exposed TiO_2 size on OVA/Poly(I:C) rhinitis mouse model. (A) Symptom score, frequencies of sneezing and nasal rubbing after the final OVA challenge. (B) Cytokine production in the nasal mucosa, mRNA expression (IL-4, IL-17A, and IFN-γ). (C) Histological staining for IL-17A-producing cells and inflammatory cells in the nasal mucosa. IL-17A producing cell counts (× 400 magnification, IHC with IL-17A antibody). Neutrophil counts (× 400 magnification, IHC with NIMP-R14 antibody). Eosinophil counts (× 400 magnification, Sirius red staining).
TiO_2, titanium dioxide; OVA, ovalbumin; Poly(I:C), polyinosinic-polycytidylic acid; IL, interleukin; IFN, interferon; IHC, immunohistochemistry.
$^{*}P < 0.05$; $^{**}P < 0.01$; $^{***}P < 0.001$.

OVA/Poly(I:C) and nano-TiO_2+OVA/Poly(I:C) groups, as determined by the qPCR (**Fig. 2B**). However, the IL-4, IL-17A, and IFN-γ mRNA expression in the group exposed to nano-TiO_2 was not statistically significant compared with that in the OVA/Poly(I:C) group (**Fig. 2B**).

Nasal mucosal histological changes were assessed by IHC and Sirius Red staining for IL-17A-producing cell infiltration, neutrophils, eosinophils, and cell aggregation (**Fig. 2C** and **Supplementary Fig. S1E**). Intense aggregation of inflammatory cells under nasal mucosa epithelial tissue was defined as cell aggregation and evaluated by Sirius Red staining. The group treated with only OVA/Poly(I:C) had, the higher numbers of IL-17A-producing cells, neutrophils, eosinophils, and cell aggregation in the nasal mucosa than the (−) control group. Meanwhile, in the nasal mucosa of groups exposed to TiO_2, the counts of eosinophils and cell aggregation were not significantly increased compared with those of the OVA/Poly(I:C) group. However, the IHC results revealed that the number of IL-17A-producing cells and neutrophils in the micro-TiO_2 group was statistically higher than that in the OVA/Poly(I:C) and nano-TiO_2 + OVA/Poly(I:C) groups. However, micro- and nano-TiO_2 were found to have no effect on serum total immunoglobulin (Ig)E, OVA-specific IgE, and IgG (**Supplementary Fig. S1A**).

The results of the influence of TiO_2 size revealed that IL-17A-expressing cells, neutrophils, and IL-17A mRNA levels were significantly higher in the nasal mucosa of mice exposed to airborne micro-TiO_2 than OVA/Poly(I:C) and nano-TiO_2.This is an additional effect of airborne micro-TiO_2 on the OVA/Poly(I:C) mouse model. On the contrary, nano-TiO_2 did not induce significant immunological and histological changes in the OVA/Poly(I:C) mouse model.

Effect of IL-17Ab in OVA/Poly(I:C) conjunctivitis and rhinitis mouse models with micro-sized TiO_2 airborne exposure

When the effects of micro- and nano-TiO_2 were compared, it was confirmed that micro size TiO_2 had a significant effect in IL-17 related inflammation both on the eyes and nose. To verify the role of IL-17 in the process, IL-17Abs were treated on the micro-TiO_2 + Poly(I:C) group.

Animal experiments with IL-17Ab were performed to investigate whether increased inflammatory response of nasal mucosa mediated by IL-17A and neutrophils is alleviated in the OVA/Poly(I:C) mouse model after exposure to micro-TiO_2 (**Fig. 3A**).

BUT significantly increased in IL-17Ab + micro-TiO_2 + Poly(I:C) group when compared with micro-TiO_2 + Poly(I:C) group, indicating that the decreased BUT was recovered after IL-17 blocking antibody treatment (**Fig. 3B**). Poly(I:C) and IL-17Ab + micro-TiO_2 + Poly(I:C) groups had the lowest tear volume, with no significant differences. Tear volume in IL-17Ab + micro-TiO_2 + Poly(I:C) group was lower than micro-TiO_2 + Poly(I:C) group, implying the recovery of eye irritation (**Fig. 3B**).

Corneal irregularities were observed in Poly(I:C), micro-TiO_2, and micro-TiO_2 + Poly(I:C) groups, while IL-17Ab + micro-TiO_2 + Poly(I:C) group had a white ring image just as seen as in (−) control group (**Fig. 3C**). Corneal fluorescein staining also showed the reduced green stains on corneal surface of IL-17Ab + micro-TiO_2 + Poly(I:C) group when compared with micro-TiO_2 + Poly(I:C) group, indicating a significant reduction in the damage after the IL-17 blocking antibody treatment (**Fig. 3C**). Although there were no significant differences of the corneal damage scores in all groups micro-TiO_2 + Poly(I:C) group were the most severe, and the corneal condition of IL-17Ab + micro-TiO_2 + Poly(I:C) group had even lower score than the negative control (**Fig. 3C**).

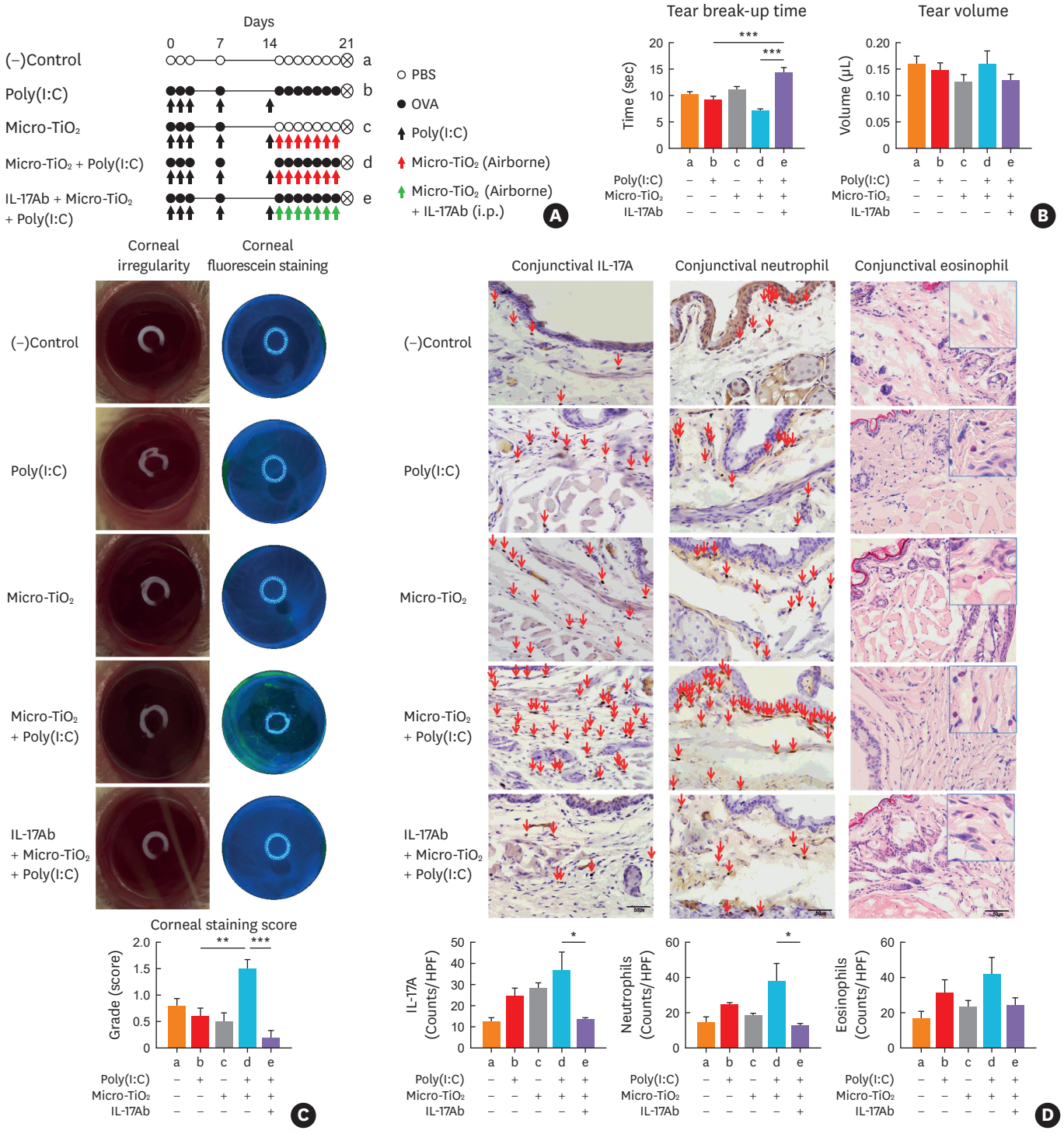

Fig. 3. The effects of IL-17Ab on the eyes of OVA/Poly(I:C) mouse model with micro size TiO_2 airborne exposure. (A) Protocol for the induction of conjunctivitis and rhinitis with OVA/Poly(I:C) and micro size TiO_2 in mice, with added IL-17Ab treatment group. (B) Tear break-up time and tear volume measurements in all groups. (C) Corneal irregularities and corneal fluorescein staining images with corneal damage scores. (D) Histological staining for IL-17A-producing cells, conjunctival neutrophil, and conjunctival eosinophil. IL-17A producing cell counts (× 400 magnification, IHC with IL-17A antibody). Conjunctival neutrophil counts (× 400 magnification, IHC with NIMP-R14 antibody). Conjunctival eosinophil counts (× 400 magnification, IHC with hematoxylin and eosin staining).
TiO_2, titanium dioxide; OVA, ovalbumin; Poly(I:C), polyinosinic-polycytidylic acid; IL, interleukin; IHC, immunohistochemistry; IL-17Ab, interleukin-17 neutralizing antibody.
$^{*}P < 0.05$; $^{**}P < 0.01$; $^{***}P < 0.001$.

IHC also confirmed that the inflammatory reaction was significantly increased in micro-TiO_2 and micro-TiO_2 + Poly(I:C) groups and decreased significantly in the IL-17Ab + micro-TiO_2 + Poly(I:C) group (**Fig. 3D**). The treatment of IL-17 blocking antibody significantly decreased the level of IL-17, neutrophil, and eosinophil, which was significantly increased with micro size TiO_2 exposure.

The symptom scores of nose scratching or sneezing after the last OVA challenge were the highest in the micro-TiO_2 + OVA/Poly(I:C)-treated group, which was significantly reduced by the IL-17Ab. The (−) control and micro-TiO_2 only groups showed similar symptom scores (**Fig. 4A**).

In mice treated with only micro-TiO_2, the levels of mRNA cytokines were relatively low similar to that of the (−) control group and IL-4 mRNA expression in the nasal mucosa was not different between the groups. The highest IL-17A mRNA expression in the group treated with micro-TiO_2 + OVA/Poly(I:C) was significantly reduced by the IL-17Ab treatment. However, the expression of mRNA IFN-γ was not statistically altered in the micro-TiO_2 + OVA/Poly(I:C) and IL-17Ab-treated groups compared with that in the OVA/Poly(I:C) group (**Fig. 4B**).

With regard to the histological changes of the nasal tissues (**Fig. 4C**), IL-17A-producing cells were the most abundant in the group treated with micro-TiO_2 + OVA/Poly(I:C), and this level decreased significantly in the IL-17Ab-treated group. The micro-TiO_2 + OVA/Poly(I:C) group was found to have the highest number of cell aggregation lesions, and its level was significantly decreased by IL-17Ab treatment. Similar to the number of IL-17A positive cells, the neutrophil count, which was significantly increased in the micro-TiO_2 + OVA/Poly(I:C) group compared with that in the OVA/Poly(I:C) group, was clearly reduced by IL-17Ab treatment. However, the number of eosinophils, B cells ($B220^+$ cells), and CD4 cells was similar in the OVA/Poly(I:C), micro-TiO_2 + OVA/Poly(I:C), and IL-17Ab treatment groups (**Fig. 4C** and **Supplementary Fig. S1D**). Cell aggregation was observed in the nasal mucosa epithelial tissue in the OVA/Poly(I:C) and micro-TiO_2 + OVA/Poly(I:C) groups by Sirius red staining (**Supplementary Fig. S1E**). The micro-TiO_2 + OVA/Poly(I:C) group was found to have the highest number of cell aggregation lesions, and its level was significantly decreased by IL-17Ab treatment. In the group treated with micro-TiO_2 only, there was negligible change in the nasal tissue compared with that in the (−) control group.

There was no statistically significant difference among the OVA/Poly(I:C), micro-TiO_2 + OVA/Poly(I:C), and IL-17Ab-treated groups in terms of total IgE, OVA-specific IgE, and IgG in the serum. The Ig level in the group treated with only TiO_2 was estimated to be similar to that of the (−) control group (**Supplementary Fig. S1B**).

The increase in the number of IL-17A positive cells and neutrophils in cell aggregates in OVA/Poly(I:C) mouse model exposed to micro-TiO_2 was significantly decreased by IL-17Ab. However, in all parameters examined, the group exposed to TiO_2 alone showed a similar pattern with the (−) control group.

DISCUSSION

Studies have reported that PMs cause respiratory and cardiovascular diseases and, in severe cases, even death.[5,25] Furthermore, PMs are known as a major cause of allergic conditions such as allergic conjunctivitis and allergic rhinitis, and the eyes and nose are the organs most

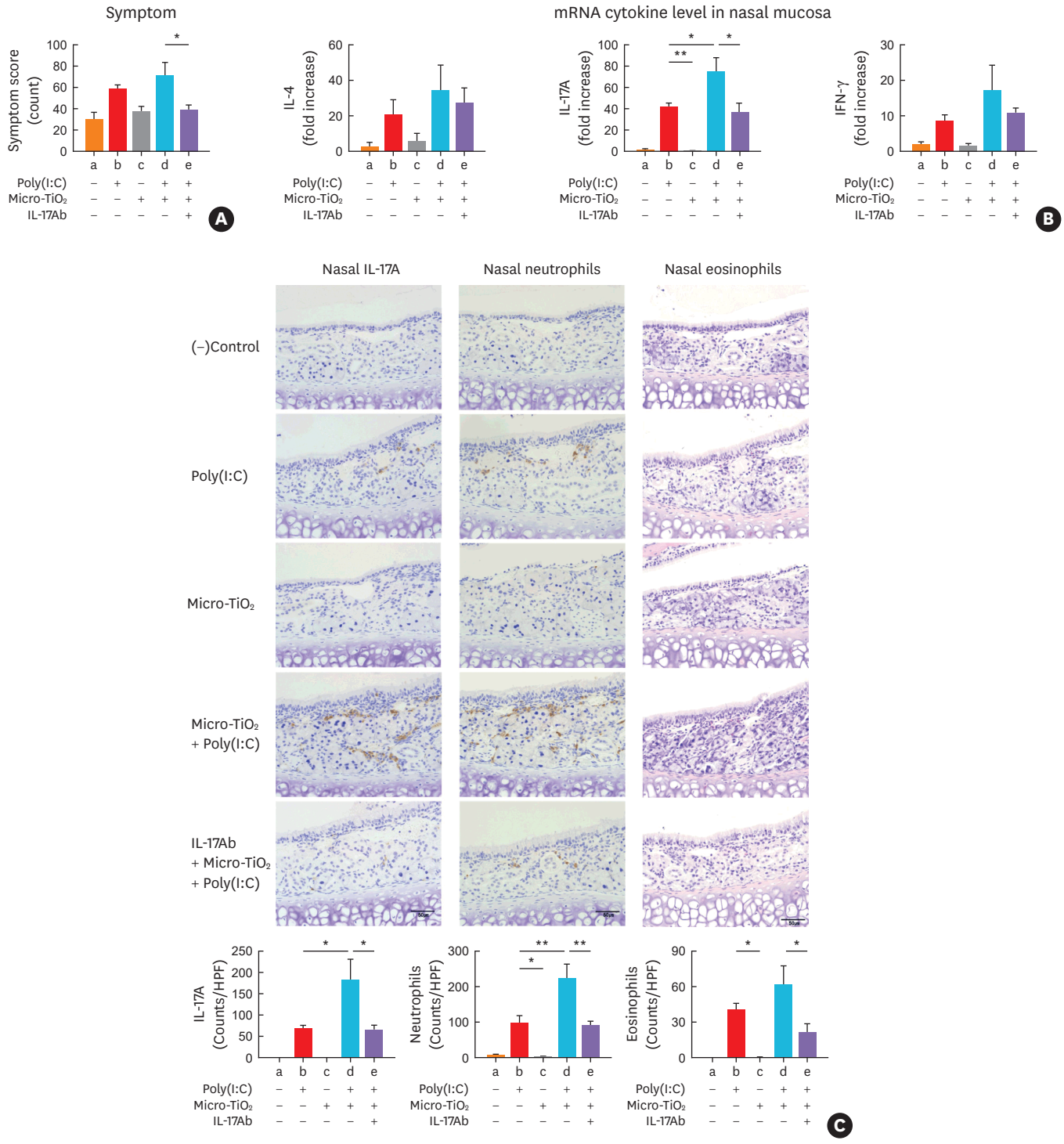

Fig. 4. The effects of IL-17Ab on the OVA/Poly(I:C) mouse model with micro size TiO_2 airborne exposure. (A) Symptom score, frequencies of sneezing and nasal rubbing after the final OVA challenge. (B) Cytokine production in the nasal mucosa, mRNA expression (IL-4, IL-17A, and IFN-γ). (C) Histological staining for IL-17A-producing cells and inflammatory cells in the nasal mucosa. IL-17A producing cell counts (× 400 magnification, IHC with IL-17A antibody). Neutrophil counts (× 400 magnification, IHC with NIMP-R14 antibody). Eosinophil counts (× 400 magnification, Sirius red staining).
TiO_2, titanium dioxide; OVA, ovalbumin; IL, interleukin; IHC, immunohistochemistry; IFN, interferon; IL-17Ab, interleukin-17 neutralizing antibody.
$^{*}P < 0.05$; $^{**}P < 0.01$.

affected by PMs.[26,27] To study the underlying mechanisms of these diseases, TiO_2 has been frequently used in *vivo* experiments as an effective approach to evaluate the effects of PMs in various cases.[28,29]

In this study, we identified the relationship between micro- and nano-TiO_2 exposure and IL-17 inflammation in the eyes and nose of the OVA/Poly(I:C) mouse model. Poly(I:C) is a synthetic analogue of double-stranded RNA, recognized by Toll-like receptor 3 and mimics the replication intermediates present in RNA virus-infected cells.[30] In a previous study, we developed an IL-17-dominant murine model of rhinitis via nasal instillation of OVA/Poly(I:C) associated with increased neutrophil counts. The OVA/Poly(I:C) mouse model had a lower Th-2 phenotype (eosinophil infiltration and Th-2 cytokine expression including IL-4 and IL-5) and a higher Th-17-associated inflammatory responses than the conventional OVA/alum model.[31]

In general, depending on the size of the particle, the location of the particle in the airway is different. However, unlike the airways, in the eyes, especially the conjunctival sacs, it is difficult to remove the substances or particles introduced from the outside, regardless of the size, remaining in the closed conjunctival sacs. Therefore, it is thought that both micro- and nano-sized TiO_2 induce inflammation of the conjunctival tissues to a similar degree regardless of particle size in the eyes.

In the nasal cavity, the nose is the initial part of the airway and is connected to the lower respiratory tract, and when external substances enter the nasal passages, the particle's size determines the particle's location in the airway. It is known that most of the micrometer-sized particles remain in the nasal mucosa, but most of the nanometer-sized particles pass through the nasal passages and remain in the lungs.[32-34] For this reason, micro-TiO_2 is thought to have a greater effect on the induction of inflammation in the nose than nano-TiO_2.

From the perspective of this experimental method, nano-TiO_2 was mixed with phosphate buffered saline (PBS) and treated by the intranasal route, and micro-TiO_2 was suspended in the chamber for a certain period of time and then exposed to mice. Compared with nano-TiO_2 mixed with PBS, micro-TiO_2 introduced in solid form could give more exposure to nasal mucosa.

This PM exposure has been shown to decrease BUT and increase tear volume as a symptom of eye irritation. When TiO_2 was administered to the eyes, inflammation and conjunctival hyperemia were observed and the frequency of blinking increased. BUT decrease and tear volume increase could be explained by corneal damage or imbalance in the tear film and increased blinking frequency, respectively. However, when the symptoms do occur, the tear film can be disrupted, reducing the amount of tears and eventually leading to dry eye.

IL-17, a cytokine related to T-cell activation and neutrophil mobilization and activation, is known to cause severe inflammatory diseases and maintain the condition by amplifying inflammation.[35,36] The results showed that the number of IL-17-producing cells and neutrophils significantly increased in both the eyes and nose in the OVA/Poly(I:C) model after micro-size TiO_2 exposure. Wu et al.[6] reported that micro-sized PM increased IL-17-secreting Th-17 cells and activated neutrophils to exacerbate allergic conditions, whereas nano-sized PM upregulated levels of IL-4 and IFN-γ in the respiratory system. As IL-17 and Th-17 cells are directly related to inflammatory diseases, they can be targeted to alleviate the disease symptoms.[37]

A significant decrease in IL-17 and neutrophils was observed after IL-17Ab treatment, indicating that IL-17 plays a significant role in the symptoms of TiO_2-induced allergic inflammation. Some studies have suggested that anti-IL-17 therapies, such as IL-17 neutralization, might be effective in reversing destructive inflammation and treating inflammatory diseases.[35,38]

In summary, this study is the first to our knowledge to compare and confirm the effects of PM exposure on both the eyes and nose using the OVA/Poly(I:C) mouse model. Micro–size PM had significant effects on the eyes and nose, resulting in IL-17 and neutrophil associated inflammation, and treatment with IL-17Ab reduced these levels of inflammation. This demonstrates that IL-17 regulation could play a key role in managing severe inflammatory symptoms in patients.

ACKNOWLEDGMENTS

This research was supported by Leading Foreign Research Institute Recruitment Program and Basic Science Research Program through the National Research Foundation through the National Research Foundation of Korea (NRF) funded by the Ministry of Science and ICT (MSIT) (NRF-2018K1A4A3A02060572 and 2020R1A2C1012105), by Basic Science Research Program through the National Research Foundation of Korea (NRF) funded by the Ministry of Education (NRF-2020R1A6A1A03043283) and by a grant of the Korea Health Technology R&D Project through the Korea Health Industry Development Institute (KHIDI), funded by the Ministry of Health Welfare, Republic of Korea (HI20C2088). And this work was supported by the Technology Innovation Program (20016884, Development of a multiband Laser Patch devices with micro needle type optical transmission structure for symptom improvement of allergic rhinitis) funded By the Ministry of Trade, Industry & Energy (MOTIE, Korea).

SUPPLEMENTARY MATERIAL

Supplementary Fig. S1

The total and OVA specific immunoglobulin (IgE, IgG1, and IgG2a) levels of serum from rhinitis mouse model with micro or nano size TiO_2 (A) and the treatment of IL-17Ab with micro size TiO_2 (B) on the OVA/Poly(I:C) mouse model. (C) IHC on the conjunctival IL-1β and TNF-α (× 400 magnification, IHC with IL-1β and TNF-α antibodies respectively). (D) Nasal CD4 positive cell and B cell on the OVA/Poly(I:C) mouse model with IL-17Ab with micro size TiO_2 (× 400 magnification, IHC with CD4 or B220 antibodies respectively). (E) Histological staining for cell aggregation cells in the nasal mucosa of each mouse model. Number of cell aggregation (× 400 magnification, Sirius red staining).

Click here to view

REFERENCES

1. Goodkind AL, Tessum CW, Coggins JS, Hill JD, Marshall JD. Fine-scale damage estimates of particulate matter air pollution reveal opportunities for location-specific mitigation of emissions. Proc Natl Acad Sci U S A 2019;116:8775-80.
PUBMED | CROSSREF

2. Adams K, Greenbaum DS, Shaikh R, van Erp AM, Russell AG. Particulate matter components, sources, and health: Systematic approaches to testing effects. J Air Waste Manag Assoc 2015;65:544-58.
PUBMED | CROSSREF
3. Du Y, Gao B, Zhou H, Ju X, Hao H, Yin S. Health risk assessment of heavy metals in road dusts in urban parks of Beijing, China. Procedia Environ Sci 2013;18:299-309.
CROSSREF
4. Hu X, Zhang Y, Ding Z, Wang T, Lian H, Sun Y, et al. Bioaccessibility and health risk of arsenic and heavy metals (Cd, Co, Cr, Cu, Ni, Pb, Zn and Mn) in TSP and PM2.5 in Nanjing, China. Atmos Environ 2012;57:146-52.
CROSSREF
5. Kim KH, Kabir E, Kabir S. A review on the human health impact of airborne particulate matter. Environ Int 2015;74:136-43.
PUBMED | CROSSREF
6. Wu JZ, Ge DD, Zhou LF, Hou LY, Zhou Y, Li QY. Effects of particulate matter on allergic respiratory diseases. Chronic Dis Transl Med 2018;4:95-102.
PUBMED | CROSSREF
7. Mimura T, Ichinose T, Yamagami S, Fujishima H, Kamei Y, Goto M, et al. Airborne particulate matter (PM2.5) and the prevalence of allergic conjunctivitis in Japan. Sci Total Environ 2014;487:493-9.
PUBMED | CROSSREF
8. Kang MH, Kim MK, Lee HJ, Lee HI, Wee WR, Lee JH. Interleukin-17 in various ocular surface inflammatory diseases. J Korean Med Sci 2011;26:938-44.
PUBMED | CROSSREF
9. Bayrak Degirmenci P, Aksun S, Altin Z, Bilgir F, Arslan IB, Colak H, et al. Allergic rhinitis and its relationship with IL-10, IL-17, TGF-β, IFN-γ, IL 22, and IL-35. Dis Markers 2018;2018:9131432.
PUBMED | CROSSREF
10. Roy D, Seo YC, Kim S, Oh J. Human health risks assessment for airborne PM_{10}-bound metals in Seoul, Korea. Environ Sci Pollut Res Int 2019;26:24247-61.
PUBMED | CROSSREF
11. Tang YJ, Chang HH, Chiang CY, Lai CY, Hsu MY, Wang KR, et al. A murine model of acute allergic conjunctivitis induced by continuous exposure to particulate matter 2.5. Invest Ophthalmol Vis Sci 2019;60:2118-26.
PUBMED | CROSSREF
12. Li Y, Zhou J, Rui X, Zhou L, Mo X. PM2.5 exposure exacerbates allergic rhinitis in mice by increasing DNA methylation in the IFN-γ gene promoter in CD4+T cells via the ERK-DNMT pathway. Toxicol Lett 2019;301:98-107.
PUBMED | CROSSREF
13. Baldacci S, Maio S, Cerrai S, Sarno G, Baïz N, Simoni M, et al. Allergy and asthma: effects of the exposure to particulate matter and biological allergens. Respir Med 2015;109:1089-104.
PUBMED | CROSSREF
14. Stephen L. Titanium dioxide versatile solid crystalline: an overview. In: Dongre R, Peshwe DR. Assorted dimensional reconfigurable materials. London: IntechOpen; 2020.
15. Han JY, Kang B, Eom Y, Kim HM, Song JS. Comparing the effects of particulate matter on the ocular surfaces of normal eyes and a dry eye rat model. Cornea 2017;36:605-10.
PUBMED | CROSSREF
16. Zhu S, Gong L, Li Y, Xu H, Gu Z, Zhao Y. Safety assessment of nanomaterials to eyes: an important but neglected issue. Adv Sci (Weinh) 2019;6:1802289.
PUBMED | CROSSREF
17. Kwon S, Yang YS, Yang HS, Lee J, Kang MS, Lee BS, et al. Nasal and pulmonary toxicity of titanium dioxide nanoparticles in rats. Toxicol Res 2012;28:217-24.
PUBMED | CROSSREF
18. Park EJ, Yoon J, Choi K, Yi J, Park K. Induction of chronic inflammation in mice treated with titanium dioxide nanoparticles by intratracheal instillation. Toxicology 2009;260:37-46.
PUBMED | CROSSREF
19. World Health Organization. WHO air quality guidelines for particulate matter, ozone, nitrogen dioxide and sulfur dioxide: global update 2005: summary of risk assessment. Geneva: WHO; 2006.
20. Kaido M, Kawashima M, Ishida R, Tsubota K. Severe symptoms of short tear break-up time dry eye are associated with accommodative microfluctuations. Clin Ophthalmol 2017;11:861-9.
PUBMED | CROSSREF

21. Yoon KC, Ahn KY, Choi W, Li Z, Choi JS, Lee SH, et al. Tear production and ocular surface changes in experimental dry eye after elimination of desiccating stress. Invest Ophthalmol Vis Sci 2011;52:7267-73.
PUBMED | CROSSREF

22. Bron AJ, Evans VE, Smith JA. Grading of corneal and conjunctival staining in the context of other dry eye tests. Cornea 2003;22:640-50.
PUBMED | CROSSREF

23. Labbé A, Terry O, Brasnu E, Van Went C, Baudouin C. Tear film osmolarity in patients treated for glaucoma or ocular hypertension. Cornea 2012;31:994-9.
PUBMED | CROSSREF

24. Kim EH, Kim JH, Samivel R, Bae JS, Chung YJ, Chung PS, et al. Intralymphatic treatment of flagellin-ovalbumin mixture reduced allergic inflammation in murine model of allergic rhinitis. Allergy 2016;71:629-39.
PUBMED | CROSSREF

25. Halonen JI, Lanki T, Yli-Tuomi T, Tiittanen P, Kulmala M, Pekkanen J. Particulate air pollution and acute cardiorespiratory hospital admissions and mortality among the elderly. Epidemiology 2009;20:143-53.
PUBMED | CROSSREF

26. Kimura K, Sakamoto T, Miyazaki M, Uchino E, Kinukawa N, Isashiki M. Effects of volcanic ash on ocular symptoms: results of a 10-year survey on schoolchildren. Ophthalmology 2005;112:478-81.
PUBMED | CROSSREF

27. Brożek JL, Bousquet J, Agache I, Agarwal A, Bachert C, Bosnic-Anticevich S, et al. Allergic Rhinitis and its Impact on Asthma (ARIA) guidelines-2016 revision. J Allergy Clin Immunol 2017;140:950-8.
PUBMED | CROSSREF

28. Brook RD, Rajagopalan S, Pope CA 3rd, Brook JR, Bhatnagar A, Diez-Roux AV, et al. Particulate matter air pollution and cardiovascular disease: an update to the scientific statement from the American Heart Association. Circulation 2010;121:2331-78.
PUBMED | CROSSREF

29. Chen EY, Garnica M, Wang YC, Chen CS, Chin WC. Mucin secretion induced by titanium dioxide nanoparticles. PLoS One 2011;6:e16198.
PUBMED | CROSSREF

30. Stowell NC, Seideman J, Raymond HA, Smalley KA, Lamb RJ, Egenolf DD, et al. Long-term activation of TLR3 by poly(I:C) induces inflammation and impairs lung function in mice. Respir Res 2009;10:43.
PUBMED | CROSSREF

31. Bae JS, Kim EH, Kim JH, Mo JH. Mouse model of IL-17-dominant rhinitis using polyinosinic-polycytidylic acid. Allergy Asthma Immunol Res 2017;9:540-9.
PUBMED | CROSSREF

32. Sager TM, Kommineni C, Castranova V. Pulmonary response to intratracheal instillation of ultrafine versus fine titanium dioxide: role of particle surface area. Part Fibre Toxicol 2008;5:17.
PUBMED | CROSSREF

33. Shi H, Magaye R, Castranova V, Zhao J. Titanium dioxide nanoparticles: a review of current toxicological data. Part Fibre Toxicol 2013;10:15.
PUBMED | CROSSREF

34. Löndahl J, Pagels J, Swietlicki E, Zhou J, Ketzel M, Massling A, et al. A set-up for field studies of respiratory tract deposition of fine and ultrafine particles in humans. J Aerosol Sci 2006;37:1152-63.
CROSSREF

35. Zenobia C, Hajishengallis G. Basic biology and role of interleukin-17 in immunity and inflammation. Periodontol 2000 2015;69:142-59.
PUBMED | CROSSREF

36. Ogura H, Murakami M, Okuyama Y, Tsuruoka M, Kitabayashi C, Kanamoto M, et al. Interleukin-17 promotes autoimmunity by triggering a positive-feedback loop via interleukin-6 induction. Immunity 2008;29:628-36.
PUBMED | CROSSREF

37. Kuwabara T, Ishikawa F, Kondo M, Kakiuchi T. The role of IL-17 and related cytokines in inflammatory autoimmune diseases. Mediators Inflamm 2017;2017:3908061.
PUBMED | CROSSREF

38. Song X, He X, Li X, Qian Y. The roles and functional mechanisms of interleukin-17 family cytokines in mucosal immunity. Cell Mol Immunol 2016;13:418-31.
PUBMED | CROSSREF

Supplementary figure 1

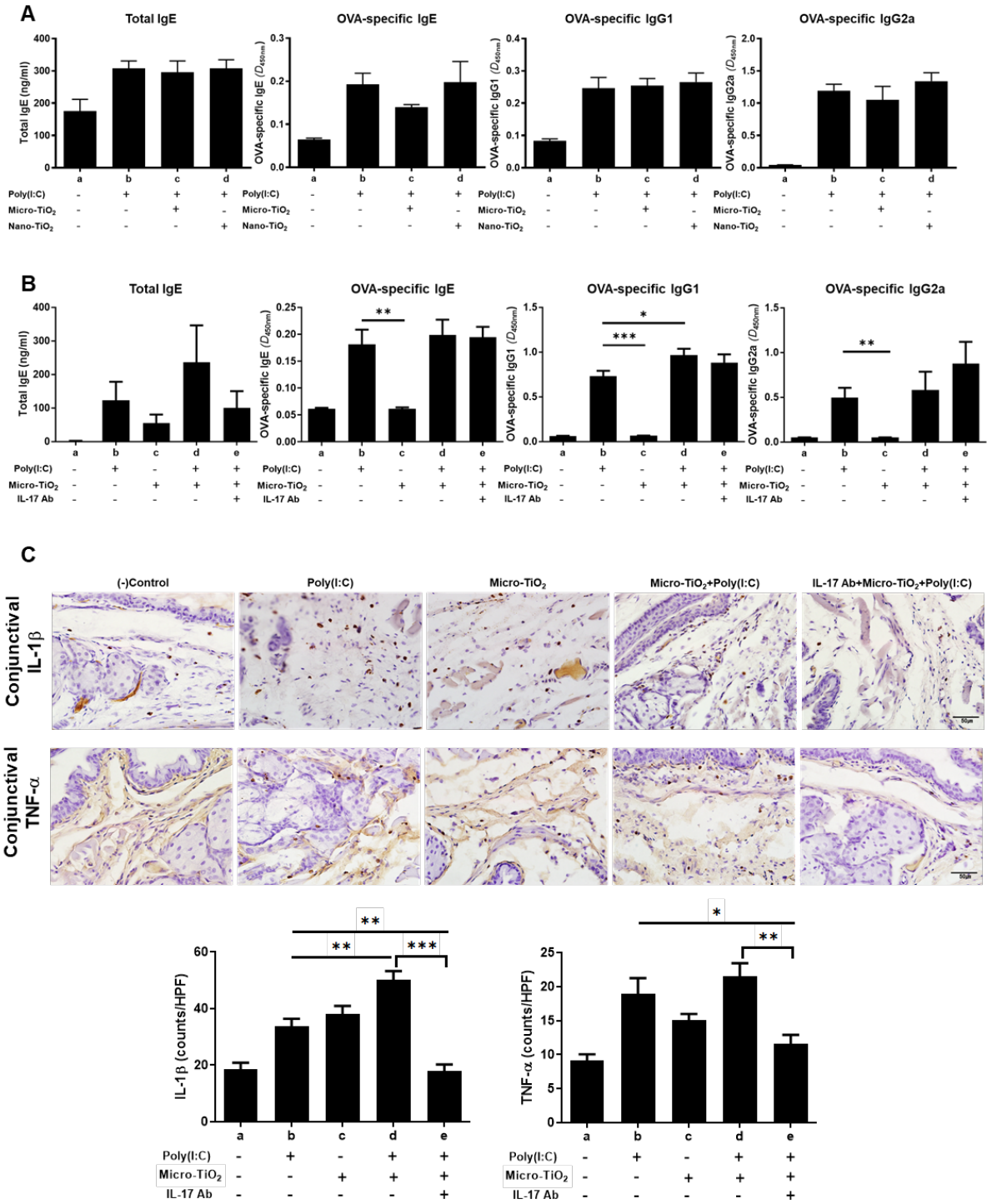

1

Supplementary figure 1

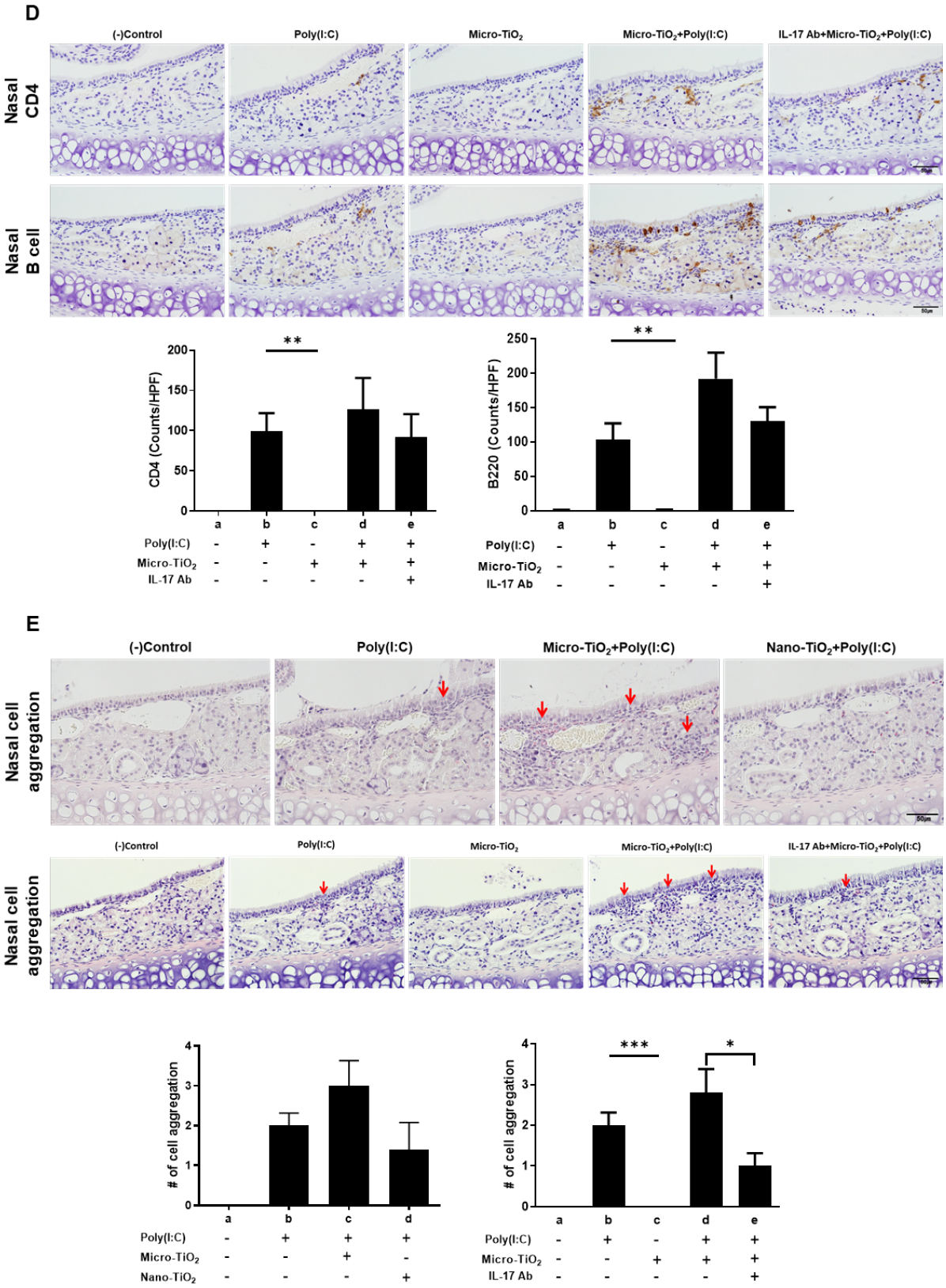

Supplementary Fig. S1. The total and OVA specific immunoglobulin (IgE, IgG1, and IgG2a) levels of serum from rhinitis mouse model with micro or nano size TiO_2 (A) and the treatment of IL-17Ab

with micro size TiO_2 (B) on the OVA/Poly(I:C) mouse model. (C) IHC on the conjunctival IL-1β and TNF-α (× 400 magnification, IHC with IL-1β and TNF-α antibodies respectively). (D) Nasal CD4 positive cell and B cell on the OVA/Poly(I:C) mouse model with IL-17Ab with micro size TiO_2 (× 400 magnification, IHC with CD4 or B220 antibodies respectively). (E) Histological staining for cell aggregation cells in the nasal mucosa of each mouse model. Number of cell aggregation (× 400 magnification, Sirius red staining).

OVA, ovalbumin; Ig, immunoglobulin; IL, interleukin; TiO_2, titanium dioxide; Poly(I:C), polyinosinic-polycytidylic acid; TNF, tumor necrosis factor; IHC, immunohistochemistry; IL-17Ab, interleukin-17 neutralizing antibody.

$^{*}P < 0.05$; $^{**}P < 0.01$; $^{***}P < 0.001$.