Clinic Rev Allerg Immunol
DOI 10.1007/s12016-014-8421-3

Crucial Role of Viral Reactivation in the Development of Severe Drug Eruptions: a Comprehensive Review

Tetsuo Shiohara · Yukiko Ushigome · Yoko Kano · Ryo Takahashi

© Springer Science+Business Media New York 2014

Abstract A growing number of cells, mediators, and pathways have been implicated in severe drug eruptions. Fifteen years ago, we published landmark studies that sparked the current advances in our understanding of the role of viral reactivations in severe drug eruptions. Viral reactivations then became critically important as diagnostic tools, but how precisely they participated in the pathogenesis remained less well-defined. The question of whether viral reactivations are pathogenic or are instead as epiphenomenon of severe tissue damage has plagued the field of drug allergy for some decades. Recent evidence points to a crucial role for tissue-resident memory T (TRM) cells in immune protection against viral infections. Yet immune protection against viral infections is but one side of a coin, the other side of which comprises effector cells capable of mediating severe immunopathology: Once drug antigen is cross-recognized by these T cells, they could be activated to kill surrounding epidermal cells, resulting in drug-induced tissue damage. Such TRM cells could persistently reside in the skin lesions of fixed drug eruptions (FDE) and are most likely a major cell type responsible for the development of FDE. We also discuss the role of regulatory T (Treg) cells in the setting of drug allergy, in which herpesviruses are reactivated in sequence. Although many details of the complicated interactions among viruses, anti-viral immune responses, TRM cells, and Treg cells remain to be elucidated, we review the current status of this rapidly advancing field.

T. Shiohara · Y. Ushigome · Y. Kano
Department of Dermatology, School of Medicine, Kyorin University, Mitaka, Tokyo 181-8611, Japan

T. Shiohara · R. Takahashi (✉)
Division of Flow Cytometry, School of Medicine, Kyorin University, Mitaka, Tokyo 181-8611, Japan
e-mail: ryo@ks.kyorin-u.ac.jp

Keywords Regulatory T cells · Herpesviruses · Resident memory T cells · Fixed drug eruption · Drug-induced hypersensitivity syndrome · Immune reconstitution syndrome · Graft-versus-host disease

Introduction

The long-standing question of why drug allergy develops in limited numbers of susceptible individuals who take drugs is still largely unresolved. Many studies have addressed this question: Clinical observations have indicated that drug allergy is often precipitated by viral infections [1, 2]. According to the viral hypothesis, viral infections could predispose genetically susceptible individuals to the subsequent development of drug allergy [3, 4]. The list of viruses triggering or exacerbating drug allergy in susceptible individuals is constantly growing and includes Epstein–Barr virus (EBV), herpes simplex virus (HSV), human herpesvirus 6 (HHV-6), cytomegalovirus (CMV), and varicella-zoster virus (VZV) [5–7]. Fifteen years ago, we [7] and Dr. Hashimoto's group [8] independently published landmark studies that sparked the current advances in our understanding of the role of viral infections in drug allergy. These initial studies have detected HHV-6 DNA by polymerase chain reaction (PCR) in blood and skin specimens from patients with a certain type of drug allergy over a predictable time course, namely 2–3 weeks after onset. However, because HHV-6 detection by PCR was limited to convenience blood samples obtained 2–3 weeks after onset of the drug allergy, there are difficulties in assigning the causality of drug allergy to the virus. What, then, is the meaning of the virus detection at 2–3 weeks after onset of the drug allergy? These findings could be interpreted as indicating the possibility that viruses are involved in acute exacerbations of drug allergy but not in the induction. On the other hand, there is also the growing body of evidence that drug allergy can be

Published online: 16 April 2014

profoundly influenced by viral infections that occurs before onset of drug allergy, as exemplified by ampicillin rashes in infectious mononucleosis (IM) [1]. Alternatively, virus infection may be additional event that is required for drug sensitization to progress to drug allergy. Thus, the complexity of assigning a pathogenic role to any virus in the development of drug allergy is underscored by the available evidence that the severity and clinical course of drug allergy can be influenced by viral infections that occur before, concurrent with, or subsequent to drug allergy. In this review, we focus primarily on how viral infections and virus-driven immune responses can evoke drug-specific immune responses that are presumably capable of eliciting cell and tissue damage.

Tissue Localization of Resident Memory T Cells After Infection with HSV

Elucidation of the events leading to clearance of infected viruses from skin could be key to our understanding of how a drug-specific immune response can develop after viral infection. Recent studies have clearly shown that after the clearance of viral infection such as HSV, a small fraction of memory T cells persist as a stable population to confer protection upon reencountering the same virus in peripheral tissues such as skin [9–12]. These HSV-specific T cells persist in the skin for at least 6 months after infection with HSV and express CD8, VLA-1, and CD103, molecules important for epithelial localization. These $CD8^+$ T cells, defined as tissue-resident memory T (TRM) cells, are different from $CD8^+$ T cells of the central memory phenotype (TCM) that largely recirculate between the secondary lymphoid organs, in that TRM cells are resident in the epidermis and are confined largely to the original site of infection [9, 10]. These $CD8^+$ TRM cells are phenotypically distinct from TCM cells with low expression of CD62L and CD122 but high expression of CD69 [9]. According to a recent report [11], they show a steady-state crawling behavior in between keratinocytes, and their migratory dendritic behavior allows the detection of antigen-expressing target cells in physiologically relevant time frames of minutes to hours. Interestingly, these $CD8^+$ TRM cells in distant skin sites markedly have been shown to reduce viral loads to levels comparable to those observed at the actual site of previous infection [12]. These $CD8^+$ TRM cells produce effector cytokines such as IFN-γ, persist at the site of infection for many months, and are highly effective at rapidly eliminating virus from the skin. After viral infection through the skin, these $CD8^+$ T cells distribute not only to the site of infection but also throughout the entire skin surface [12], providing long-lived protective T cell immunity against re-infection of the virus. Although these virus-specific $CD8^+$ TRM cells are also found in sensory ganglia, brain, intestinal mucosa, and salivary glands, common features of these differentially localized TRM cells are the expression of CD103 and of CD69. The salivary glands as well as the skin also harbor virus-specific $CD8^+$ TRM cells uniquely expressing E-cadherin at surprisingly high frequencies after systemic virus infection [13].

Thus, virus-specific $CD8^+$ TRM cells resident in the skin site are thought to regulate whether skin infection with the virus could result in viral control, asymptomatic persistence, or severe pathology. As demonstrated by Jiang et al. and Mackay et al. [12, 14], these skin-resident CD8 TRM cells are long-lived and non-recirculating and are superior to circulating TCM cells at providing rapid long-term protection against cutaneous viral infections ever in the absence of persisting local antigen presentation. Depending on the viral loads in the skin site, virus-specific TRM cells resident in the skin site could have either a beneficial or detrimental role in controlling virus-associated morbidity: At a medium dose of virus, TRM cell-mediated lysis of virus-infected cells contribute to sufficient control of viral burden, while, at a high dose of virus, TRM cells would act detrimentally by severely damaging virus-infected epidermal cells, ultimately resulting in severe T-cell-dependent immunopathology.

$CD8^+$ TRM Cells in the Lesions of Fixed Drug Eruption

The classic fixed drug eruption (FDE) lesions are characterized by a solitary or small number of well-circumscribed, round, and/or oval erythematous macules and plaques with dusky centers on the skin and/or mucous membrane: These lesions usually start abruptly an exactly the same site with each administration of the causative drug [15, 16]. Although the individual FDE lesions are 1–4 cm in diameter and rarely exceed 10 cm, these lesions become more numerous and more severe unless the causative drug is withdrawn. New FDE lesions often develop at the site of viral infection such as HSV and previously traumatized or inflamed skin such as insect bites, burn, and venipuncture sites [17]. A peculiar linear pattern of FDE lesions suggestive of previous herpes zoster (HZ) have been also reported, although it is unclear whether the patient had preceding HZ before onset of FDE [18]. An unusual cellulitis-like FDE has also been reported: An erythematous and edematous plaque with undetermined borders mimicking cellulitis was elicited by the subsequent administration of the causative drug at the same sites [19]. These findings, together with our previous report describing the development of typical FDE lesions at exactly the same site as the patient's previous HSV lesion, suggested to us the possibility that cells with "protective" function may be recruited from the circulation, either nonspecifically or specifically, upon primary insults, such as trauma and viral infections, and they could persist at relatively high frequencies in the lesional

skin and be responsible for the subsequent induction of FDE lesions (Fig. 1). Indeed, innate immune cells such as dendritic cells or $\gamma\delta^+$ T cells and antigen-specific $CD4^+$ and $CD8^+$ T cells are shown to be recruited from the circulation to the inflammatory site such as skin and persist in the epithelium in a number of diverse physiological and pathological settings.

To investigate the possibility that $CD8^+$ TRM cells could persist in FDE lesions, we immunohistochemically characterized resting FDE lesions long after clinical resolution. FDE lesions typically resolve after discontinuation of the causative drug, leaving hyperpigmentation localized to the sites of previous flare. Such resolved FDE lesions are characterized by a small number of $CD3^+$ $CD8^+$ T cells aligned along the epidermal site of the dermoepidermal junction: These T cells persist for a long time in the lesion, referred to as resting FDE lesions, after resolution as a phenotypically homogenous, stable population of T cells that constitutively express TCR-αβ, CD45RA, CD103, CLA, CD11b, CD69 but not CD27 and CD56 [15]. In contrast, these T cells are rarely found in the uninvolved epidermis of FDE patients and healthy individuals. This phenotype of T cells most closely resembles that of TRM cells. Our previous studies demonstrated that the $CD8^+$ T cells isolated from the resting FDE lesions and subsequently expanded in vitro displayed cytolytic activity against NK-sensitive or NK-resistant tumor cells and cultured keratinocytes when stimulated in an Ag-nonspecific fashion via CD3/TCR complex [20]. Nevertheless, they are not constitutively cytolytic, unlike NK cells and murine $\gamma\delta^+$ dendritic epidermal T cells (DETC). The intracellular cytokine assay with the use of $CD8^+$ T cells freshly isolated from the resting FDE lesions showed that the great majority (>80 %) of these $CD8^+$ T cells produced IFN-γ and TNF-α upon stimulation while the proportion of these T cells producing IL-4 was very low (<1 %). Our in situ PCR studies using FDE lesions obtained 3 h after challenge demonstrated that these $CD8^+$ TRM cells could be induced to express IFN-γ mRNA and protein upon clinical challenge with the causative drug [21]. Their induction of IFN-γ mRNA was much faster than that of their dermal and peripheral counterparts. Because their rapid production of large amounts of IFN-γ mRNA and protein upon stimulation with the causative drug in vivo was clearly followed by localized epidermal damage, these $CD8^+$ T cells residing in resting FDE lesions are most likely a major cell type responsible for the development of FDE [16, 21].

Despite our expectation, however, no convincing evidence is presently available to indicate that the ligands for these $CD8^+$ TRM cells resident in the resting FDE lesions are drug antigens or viral antigens. In this regard, our previous studies demonstrated that some of these $CD8^+$ TRM cells can recognize self-proteins [16] but not drug antigens either in a totally major histocompatibility complex (MHC)-dependent or MHC-independent fashion. However, in view of our previous quantitative PCR analysis demonstrating that these $CD8^+$ TRM cells utilized a very limited range of TCR Vα and Vβ gene families as compared with peripheral blood T cells obtained from the same patients [20], we can assume that they can recognize a limited Ag presented by MHC molecules. In this regard, it is noteworthy that a recent report indicates that heterologous virus infections of mice result in a narrow oligoclonal TCR repertoire specific to highly cross-reactive epitopes of different viruses [22]. What causes narrowing of the TCR repertoire in mice following heterologous virus infections remains poorly understood, but the profound narrowing of the TCR repertoire diversity after heterologous virus infections is likely a consequence of expansions of the highly cross-reactive T cell population. Thus, cross-reactivity of $CD8^+$ T cells generated after heterologous virus infections may explain why FDE lesions can be induced at exactly the same site as the patient's previous HSV infection or trauma. Such cross-reactivity of $CD8^+$ TRM cells resident in the epithelium may help to control a variety of pathogens early in infection. The most likely explanation for why $CD8^+$ TRM cells originally distributed to the site of infections can be activated by totally unrelated drug antigens is that these $CD8^+$ TRM cells could be broadly cross-reactive with some

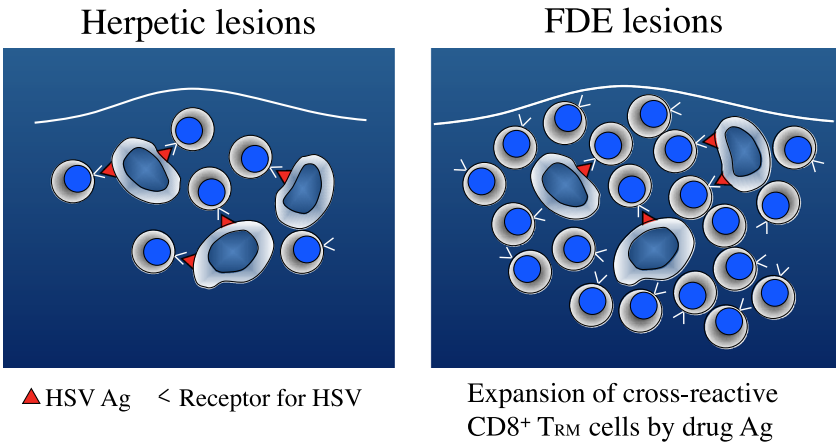

Fig. 1 HSV lesions evolve into FDE lesions. After infection with HSV, a small fraction of $CD8^+$ TRM cells specific for HSV persist as a stable population with antigen-presenting cells at the skin site of HSV infection to confer protection against the same virus. These T cells, once activated with cross-reactive drug antigen, can expand and become effector cells responsible for the induction of FDE

of drug antigens while preserving the fine specificity for a self-MHC-bound peptide such as viral antigen. In support of this possibility, there is now sufficient evidence to indicate that the specificity of a large proportion of antigen-specific self-HLA restricted T cells is also directed toward infectious agents, particularly herpesviruses [23–25]. Additional mechanisms for how cross-reactivity of T cells can be maintained in vivo have been reported in recent studies [26, 27]: These cross-reactive T cells can recognize self- and nonself HLA molecules while maintaining a strong antiviral immune response by recruiting non-cross-reactive T cells to control the virus. Thus, $CD8^+$ TRM cells enriched in resting FDE lesions could have originally evolved to protect epidermal tissue integrity from invading pathogens such as herpesviruses, and once drug antigen is cross-recognized by these T cells because of their broad cross-reactivity, they can be activated to kill surrounding keratinocytes, resulting in localized epidermal damage [15].

Role of Regulatory T Cells in FDE Lesions

The clinical spectrum of FDE is highly variable, ranging from the classic form to a generalized bullous variant with systemic symptoms initially indistinguishable from Stevens–Johnson syndrome (SJS)/toxic epidermal necrolysis (TEN). Despite such clinical similarities between a generalized form of FDE and SJS/TEN, subsequent evolution of the two conditions is quite different: The former resolves spontaneously upon discontinuation of the causative drug, while the latter often results in full-thickness epidermal detachment, rapidly spreading to the whole body. However, less is known about critical events that are needed for preventing further disease progression to SJS/TEN. In this regard, our previous studies demonstrated that recruitment of $FoxP3^+$ regulatory T (Treg) cells into the FDE lesions is crucial for preventing $CD8^+$ TRM and TCM cells from excessively activating at the inflammatory site [28]. These observations suggested that the defect in regulatory mechanisms for preventing further progression to SJS/TEN may reside either within the cutaneous milieu in the inflammatory site, particularly in the border of the lesion, or within migrating Treg cells themselves; this is because the individual erythematous lesions of FDE have well-defined border while the SJS/TEN lesions form poorly defined macules rapidly extending to the perilesional skin.

Our recent unpublished study has demonstrated that $FoxP3^+$ Treg cells obtained from FDE patients at the acute stage retain the suppressive capacity to inhibit proliferation of $CD8^+$ TRM and TCM cells while their function in SJS/TEN patients at the corresponding stage is severely impaired [29], indicating that Treg cells in FDE are fully functional and constitute an important component of protective immunity. We have further demonstrated that $FoxP3^+$ Treg cells preferentially accumulate beneath the epidermis and at the mid part of the dermis in the periphery of the FDE lesions while those are sparsely distributed in the upper part of the dermis of the periphery of SJS/TEN lesions. These results indicate that timely and selective accumulation of Treg cells in the periphery of FDE lesions could be crucial for preventing excessive activation and recruitment of $CD8^+$ TRM and TCM cells. Indeed, the frequency of Treg cells in the periphery of FDE and TEN lesions correlated well with the degree of protection conferred. These findings emphasize the importance of Treg cell recruitment to the extending edge of the inflammatory site for establishing the Treg response to the greater load of infiltrating Teff cells. We also provide evidence to indicate that mast cells accumulating in the FDE lesions may facilitate the rapid recruitment of Treg cells to the inflammatory sites thereby limiting tissue damage mediated by activation of $CD8^+$ TRM and TCM cells. Consistent with these data, mast cells and Treg cells have been shown to exhibit substantial colocalization in tissues and lymph nodes. Because IL-16 able to attract Treg cells was much more intensely expressed in mast cells detected in the FDE lesions and IL-16 was the only cytokine that increased rapidly in the serum of patients with FDE after clinical challenge (Y Mizukawa et al., unpublished data), we conclude that a timely and proper localization of Treg cells into the specific inflammatory site induced by mast cell-derived IL-16 in the FDE lesions could serve to limit excessive activation of potentially destructive $CD8^+$ TRM and TCM cells, resulting in spontaneous resolution of the FDE lesions.

The Effect of Viral Infections on the Subsequent Development of Drug Allergy

Available evidence strongly suggests that viral infections create a favorable milieu for the initiation and progression of adverse drug reactions [4]. It remains unknown, however, how preceding viral infections induce or contribute to the subsequent development of adverse drug reactions. When considering a complex interaction between viral infection and drug allergy, it is noteworthy that there must be mechanisms that protect the host from excessive immune responses to viruses, which could in themselves lead to greater pathological consequences than the invading viruses. Evidence is recently accumulating that $CD4^+FoxP3^+$ Treg cells, either natural or inducible, can inhibit the function of effecter T (Teff) cells at the site of viral infections, thereby inhibiting severe immunopathology. On the other hand, the Treg response may be potentially harmful to the host in terms of infection control because their activation and expansion secure survival of invading viruses for an extended period of time, thereby causing chronic infectious diseases. Numbers and function of Treg cells, therefore, should be controlled depending on the stage of viral

infections. During the early stage of infection, dampening Treg function would result in vigorous anti-viral responses that control infections. Some studies have demonstrated that Treg cells lose their suppressive capacity in response to engagement of virus-sensing mechanisms such as TLR signaling [30]. Alternatively, it has been proposed that, during viral infection, TCM and TRM cells responding to infection would become resistant to Treg-mediated suppression as a result of exposure to proinflammatory cytokines and increased costimulatory signals [31]. At later time points in infection, however, expansion of functional Treg cells is likely to occur to protect overstimulation of the immune system. Thus, a time-dependent balanced, rather than biased, Treg responses would be necessary for host protection and the resolution of infection. One must appreciate, however, the fact that most of previous studies on the role of Treg cells in the setting of viral infections were not extended beyond the acute period of infection to determine how Treg cells were involved in the pathogenesis of virus-induced diseases.

To investigate the role of Treg cells in the context of viral infections, we initially evaluated the frequencies of $CD4^{+}CD25^{+}FoxP3^{+}$ Treg cells in total PBMC of patients with viral infections, such as VZV and parvovirus B19. Although recent studies demonstrated an increase in Treg frequencies in acute dengue [32] and measles infection [33], our results showed no significant alterations in Treg frequencies and their absolute numbers in the setting of these viral infections. These apparently conflicting results suggest that there is more to be learned about the frequency of Treg cells during acute infections: The number of Treg cells during viral infections would be different depending on the virus, virulence, or dose. More importantly, we demonstrated that Treg cells obtained from patients with these viral infections, VZV and parvovirus B19, exhibited a significantly impaired capacity to suppress CD3-driven Teff cell proliferation, as compared with those from healthy controls. The degree of functional defect in patients at the acute stage of these viral infections was comparable to that in patients with TEN, which was previously described by us [29]. Their impaired capacity at the acute stage of these viral infections, however, had returned to a presumed baseline, which was indistinguishable from that of healthy controls, upon clinical resolution. The defect during the acute stage was not due to increased resistance of Teff cells obtained from these patients to Treg-mediated suppression. In contrast, functional activity of the Treg cells obtained from patients with Mycoplasma pneumoniae (MP) remained defective even 1 year after clinical resolution (R Takahashi et al., manuscript submitted). These results indicate that defective Treg function observed during the acute stage of the viral infections and both the acute and resolution stages of MP infections would serve to lower the activation threshold of drug-specific T cells or pathogen-specific T cells, thus facilitating the development of drug allergy. In these viral infections, a loss of Treg function was transient and the defective Treg cells regained their functional competence upon resolution, while MP infection persistently abrogated Treg functions even after clinical resolution. These results provide an explanation for why patients with MP-associated SJS displayed polysensitivity to multiple drugs with different structures that cannot be easily explained by drug antigen-driven T cell activation [34]. Thus, viral or MP infections are likely to be prime candidates for subsequently developing drug allergy in susceptible individuals, probably through a transient or persistent loss of Treg functions.

Viral Reactivation in Drug-Induced Hypersensitivity Syndrome

Several drug eruptions encompass several distinct clinical entities, the most serious being TEN/SJS. Drug-induced hypersensitivity syndrome (DiHS), also referred to as drug reaction with eosinophilia with systemic symptoms (DRESS), represents the opposite end of a spectrum of severe drug eruptions. DiHS/DERSS offers a unique opportunity to link between viral infections and the development of severe drug eruptions, due to its strong association with HHV-6 infection [7, 8]. This syndrome has several unique features that cannot be solely explained by a drug Ag-driven, oligoclonal T cell activation: The delayed onset in relation to the introduction of the causative drug is one of the important features of this syndrome that can be distinguished from other types of drug eruptions, which usually start 1–2 weeks after starting therapy. This syndrome typically occurs with fever and cutaneous lesions 3 weeks to 3 months after starting therapy with a limited numbers of drugs, mainly anticonvulsants. Importantly, more severe reactions often occur 3–4 days after withdrawal of the causative drugs: This paradoxical worsening is also characteristic of DiHS and may be mistaken for severe infectious diseases. Patients with DiHS often show unexplained cross-reactivity to multiple drugs with different chemical structures, including those starting after onset of symptoms. In addition, variable clinical symptoms, such as renal and liver symptoms, continue to deteriorate one after another even for weeks after stopping the causative drug. Although maculopapular or erythematous eruptions are initially observed on the face, upper trunk, and upper extremities, most erythematous macules do not evolve into blisters and no mucous membrane involvement is usually seen [15, 35, 36].

The peripheral blood usually shows marked leukocytosis with atypical lymphocytosis or eosinophilia of various degrees in most of cases, although in some cases leucopenia or lymphopenia may precede the leukocytosis. A dramatic decrease in serum IgG, IgA, and IgM levels is typically observed at onset, and the lowest levels are usually seen a week after withdrawal of the causative drug. Despite such variable

clinical presentations and courses, HHV-6 reactivations can be detected at a particular time point, 2–3 weeks after onset of rash in the vast majority of patients regardless of treatment [15, 36]: A strong association between HHV-6 reactivations and this syndrome has been supported by a large number of independent groups over the years in Japan [36, 37]. This is the reason why HHV-6 reactivations as evidenced by the rise in anti-HHV-6 IgG titers and HHV-6 DNA levels can be used to confirm a clinical diagnosis of DiHS [38]. Although HHV-6 was initially thought to be the only virus reactivated during the course of DiHS, recent studies of real-time measurements for viral loads have demonstrated that other herpesviruses, such as EBV, HHV-7, and CMV, are also reactivated in sequence during the course of the disease as demonstrated in graft-versus-host diseases (GVHD) [35, 39] (Fig. 2). According to our sequential analysis of viral loads in patients with DiHS, the cascade of reactivation events initiated by HHV-6 or EBV would extend, with some delay, to HHV-7 as well and eventually to CMV [39] (Figs. 2 and 3). Consistent with the previous observations that the severity of GVHD was correlated with the levels of HHV-6 DNA [40], the magnitude of HHV-6 reactivation as evidenced by the increase in HHV-6 DNA levels was correlated well with the severity of inflammatory responses that occur in vivo in patients with DiHS [15, 41]. These findings provide strong evidence to suggest the role of HHV-6 or other herpesviruses in the etiology of the disease, rather than a mere bystander, although reactivation of these viruses as a result of a transient immune dysfunction cannot be definitely excluded. Because of the unique biological properties of herpesviruses, particularly their "immunotropic" nature, and their possible interactions with other herpesviruses, they may have detrimental effects on the immune system once reactivated in the course of the disease. Investigators have been hampered by difficulty in assigning a pathogenic role to any herpesvirus in patients with DiHS who manifest clinically variable symptoms in different organs. Thus, despite rapid advances in the biology and genetics of herpesviruses, progress in understanding the pathogenic role of these herpesviruses has not come easily.

How, then, can the etiological role of herpesviruses be confirmed? One relevant observation from years of research on the role of immune responses against EBV is that cutaneous and visceral symptoms of DiHS/DRESS are mediated by activated $CD8^+$ Teff cells which are largely directed against herpesviruses, such as EBV, and that the causative drug can reactivate herpesviruses in vitro [42]. The result of this study indicates the possibility that herpesvirus reactivations triggered by the causative drug could have the immunopathogenic role in DiHS/DRESS but not a mere epiphenomenon of the underlying immunodeficiency.

Role of Treg Cells in DiHS

Our recent study clearly demonstrates that the acute stage of DiHS/DRESS is characterized by dramatic expansions of fully functional $CD4^+FoxP3^+$ Treg cells while their suppressive capacity is profoundly impaired in the acute stage of SJS/TEN [43]. Although it is difficult to determine when Treg expansions occur before the development of DiHS, this expansions of Treg cells would occur far before onset of DiHS, which would contribute to not only the delayed onset but also to viral reactivations [36]. In order to counterbalance activating Teff cells, expansions of Treg cells are likely to be key for maintaining a healthy balance between protection and immunopathology. However, once the balance has been disturbed toward activation of Teff cells, DiHS ensues (Fig. 4). Thus, the expanded Treg cells would also limit the severity of Teff cell-mediated immunopathology, which is reflected by the observation that epidermal damage can be rarely detected in the

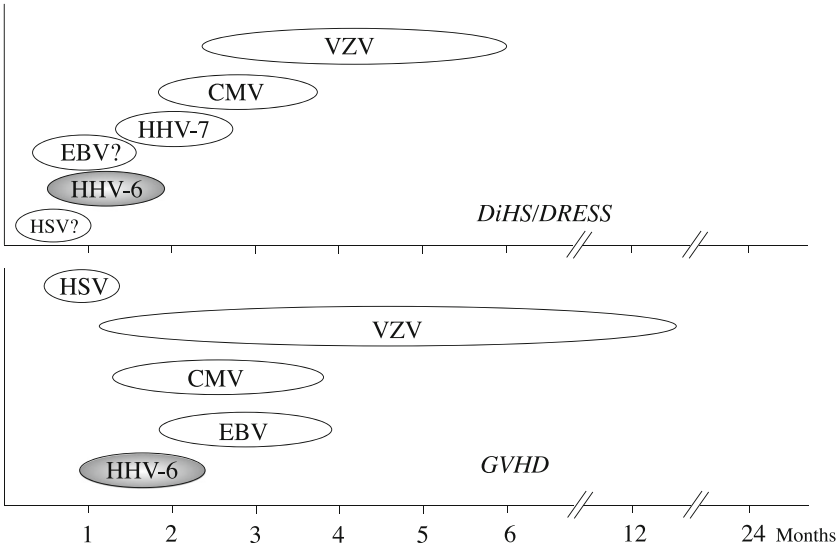

Fig. 2 Sequential reactivation of various herpesviruses during the courses of DiHS and GVHD. Importantly, herpesviruses are reactivated in DiHS in the fundamentally same order as in GVHD

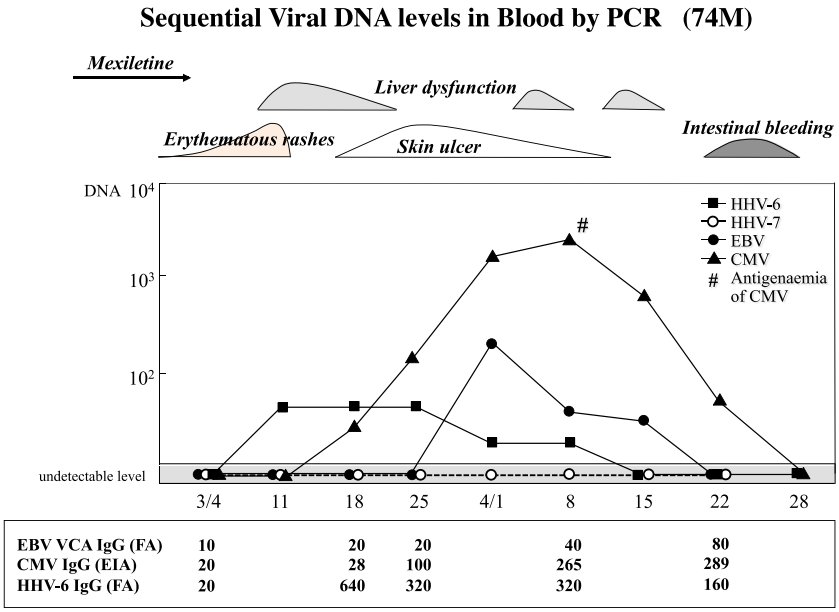

Fig. 3 Relation between clinical symptoms and herpesvirus viral DNA loads and anti-viral antibody titers in a representative case with DiHS due to phenobarbital

skin lesions of DiHS. The expanded population of Treg cells in the peripheral blood of DiHS patients during the acute stage is likely the inducible Treg (iTreg) cells that are induced in the periphery under specific conditions of cytokine and antigen [43]. iTreg cells can be produced from $CD4^{+}CD25^{-}$ T cells by culture with antigen and TGF-β or IL-10 and TGF-β, while IL-6 inhibits iTreg induction and promotes Th17 [44, 45]. Consistent with this view, our preliminary study shows that in vitro culture with the causative drug of peripheral blood lymphocytes from DiHS patients after resolution results in expansions of Treg cells (unpublished observation). Importantly, a gradual loss of Treg-cell function occurs after the resolution of DiHS, although it remains unknown when and how it occurs: Expanded Treg cells, upon their contraction, may become functionally exhausted and loss their essential functional activity necessary for immune protection. Such functional exhaustion is likely to result from repeated activation by Treg cells frequently occurring during the courses of DiHS and is a way of limiting the magnitude of Treg cell responses, which may compromise effective immunity against infections agents. Indeed, reflecting a loss of Treg-cell function after resolution, several autoimmune diseases such as type 1 diabetes mellitus, thyroiditis, SLE, and sclerodermoid GVHD-like disease [46] have been reported to develop at intervals of several months to years after clinical resolution of DiHS [35, 47] (Fig. 5). In view of the finding that the imbalance between the Treg and Teff-cell compartments has been shown to trigger the development of autoimmune disease, resolution of DiHS may be accompanied by a shift away from Treg differentiation and toward IL-17-

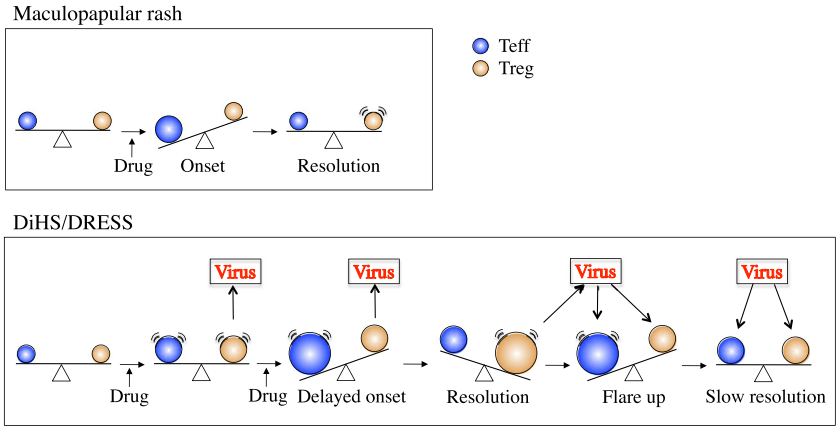

Fig. 4 A hypothetical model for the development of DiHS and maculopapular type of drug eruption. In maculopapular rash, Treg cells are overwhelmed with expansions of Teff cells. In DiHS, protracted use of the causative drug results in expansions of not only Teff but also Treg cells, thereby delaying onset and causing viral reactivation. Eventually, however, the delicate balance between Teff and Treg is disturbed toward activation of Teff cells, leading to onset of DiHS. Systemic corticosteroids can improve clinical symptoms, probably by potentiating Treg-cell function

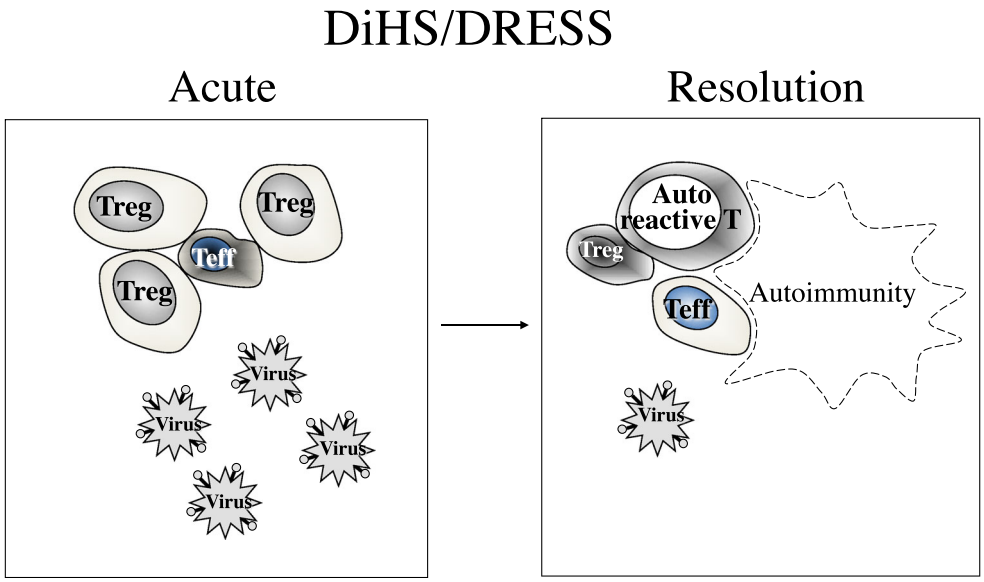

Fig. 5 Acute and resolution stages of DiHS. After resolution of clinical symptoms, Treg cells expanded during the acute stage are contracted and become exhausted in function, thereby triggering autoimmune diseases

producing (Th17) cell differentiation. We therefore measured the frequencies of Treg cells and Th17 cells within circulating $CD4^+$ T cells during the acute stage and again long after resolution. We found that Th17 cells were increased in frequency coincident with the decrease in Treg cell frequency upon resolution in DiHS. A significant increase in various autoantibody titers such as anti-nuclear antibody (ANA) and anti-thyroglobulin antibody was specifically observed in patients with DiHS after resolution, which likely reflects a shift to Th17 cell differentiation (unpublished data).

Longitudinal Analyses of Herpesvirus Loads in Severe Drug Eruptions

Although sequential reactivations of several herpesviruses have exclusively been demonstrated during the acute stage of DiHS, no previous studies were extended beyond the acute stage of the stage. We therefore sought to investigate whether herpesvirus reactivations could be observed in SJS/TEN and beyond the acute stage of both diseases. EBV, HHV-6, and CMV DNA loads were sequentially determined during a 2-year period after onset. Our quantitative PCR analysis revealed persistently elevated EBV loads in patients with SJS during the acute stage and long after clinical resolution [48]. In contrast, only a fraction of patients with DiHS/DRESS had increased levels of EBV DNA in the blood at onset. In many patients with SJS, increased EBV DNA persisted for up to 2 years after resolution. These results suggested that patients with high EBV DNA loads may be at risk of subsequently developing SJS, although we could not totally exclude the alternative possibility that the aggressive clinical course observed during the acute stage of SJS may be responsible for EBV reactivations. However, this alternative possibility is unlikely because the degree of the EBV loads in patients with SJS did not correlate with the severity of clinical symptoms and laboratory abnormalities. Surprisingly, we noted that no patients with TEN demonstrated elevated EBV loads during the acute stage and after clinical resolution [48]. In view of clinical similarities between SJS and TEN, differences in the pattern of the viral loads between them were surprising and could be interpreted as indicating the possibility that these two diseases may be distinct in the pattern of persistent viral infections although they may share important common pathophysiologic processes [49].

Increased EBV, CMV, and HHV-6 loads only occurred during the acute stage and a post 100-day period in patients with DiHS/DRESS [48]. Nevertheless, the dynamics of EBV, CMV, and HHV-6 reactivation varied considerably in these patients according to the use of systemic corticosteroids. Although CMV and HHV-6 DNA loads were higher in those receiving systemic corticosteroids than those not receiving them, EBV DNA loads were significantly higher in those without them [48]. Interestingly, the increase in various autoantibody titers, which was detected 1 year after the resolution of DiHS/DRESS, was associated with the elevated EBV loads during the acute stage of DiHS/DRESS and preferentially observed in patients not receiving systemic corticosteroids [50]. These results could be interpreted as indicating that the use of systemic corticosteroids during the acute stage of DiHS may serve to prevent the progression to autoimmune disease as long-term sequelae of DiHS/DRESS, probably through the decrease in EBV DNA loads. Similar observations have been also noted in the generation of autoantibodies to epidermal proteins, periplakin (unpublished data). Consistent with the results of autoantibodies such as ANA, the generation of autoantibodies to periplakin was preferentially observed in patients with DiHS/DRESS who were not treated with systemic corticosteroids. These findings suggest that immune responses

preventable with systemic corticosteroids and/or increased EBV DNA loads could trigger the subsequent generation of autoantibodies to periplakin and that early resolution by systemic corticosteroids may lead to better long-term outcomes for patients at risk of subsequently developing autoimmune disease.

Management of Patients with Severe Drug Eruptions Associated with Viral Reactivations

Physicians, when treated patients with severe drug eruptions, need to be aware of underlying viral infections, particularly herpesvirus infections, as one of the most important aspects of management of these patients. Because those patients often receive immunosuppressive agents either early or later in the course of their illness, a wealth of information on the interaction between herpesviruses and immune responses should be gathered to better manage those patients.

When we consider how to better manage those patients, one must appreciate the concept of immune reconstitution syndrome (IRS) [51–53]. IRS is an increasingly recognized disease concept and is observed with a broad spectrum of immunosuppressive therapy-related opportunistic infectious diseases and severe drug eruptions complicated by viral reactivations. Increased occurrence of opportunistic infections associated with defects in the immune system was generally recognized as a result of microbial damage afflicted by these pathogens. Contrary to this belief, an intriguing aspect that has received little attention so far is that restoration of hose immunity may also have adverse sequelae, particularly when it occurs abruptly and rapidly. Indeed, when the timing of onset of an adverse event was carefully assessed in patients infected with HIV, the onset of this event was concentrated within 6–14 days of starting antiretroviral therapy (ART) [54], coincident with restoration of host $CD4^+$ T cell number and reactivity. This clinical deterioration observed after starting HAART therapy was originally called IRS. This syndrome develops not only in patients with HIV infection but also in non-HIV immunocompetent hosts, such as patients with severe drug eruptions and those on immunosuppressive therapy, upon reduction or withdrawal of immunosuppressive agents or chemotherapy. Recently, IRS has also been reported to develop in lymphopenic and neutropenic patients [49] and patients receiving tumor necrosis factor (TNF) α inhibitors [55–58]. Clinical illness consistent with IRS includes tuberculosis, herpes zoster, herpes simplex, CMV infections, and sarcoidosis [53]. The manifestations of IRS are diverse and depend on the tissue burden of the preexisting infectious agents during the immunosuppressive state and the nature of the immune system being restored. Because in some cases IRS is self-limited within a week without any therapy while others are fatal or life-threatening, management of this syndrome should be decided on an individual basis (Table 1).

The clinical characteristics of IRS modified from criteria proposed by Shelburne et al. [59] are as follows: (1) paradoxical deterioration of preexisting infectious disease a attributable to the recovery of the immune system; (2) a decrease in the dose of pathogens, e.g., viral loads, with or without an increase in $CD4^+$ T cell counts; (3) clinical symptoms not explained by a newly acquired infection, by the expected clinical course of a previously recognized infectious agents, or by side effects of therapy; and (4) any event occurring after initiation of ART or after withdrawal or reduction of immunosuppressive agents including biologics, regardless of whether patients are HIV-positive or HIV-negative. In view of the observations that paradoxical worsening of clinical symptoms associated with reduction in viral loads is typically observed after withdrawal of the causative drug at onset of DiHS [15, 16, 35, 36], DiHS is likely a manifestation of the newly observed IRS [35, 51]. Various clinical observations in DiHS/DRESS could be explained by assuming that rapid restoration of pathogen-specific immunity after withdrawal of the causative drug with immunosuppressive properties, as described previously [15, 16, 53], would serve to reduce viral loads at onset, thereby rendering them undetectable in the blood. This consideration could explain why any herpesvirus DNA can be hardly detected at onset of DiHS/DRESS.

Systemic corticosteroids have been the mainstay of treatment for IRS and are the only treatment for which clinical trial data exist [53]. However, there have been no clear guidelines for how patients with IRS are treated with systemic corticosteroids. Because a mild form of IRS can respond to specific treatment for the underlying pathogens, immunosuppressive therapy is not generally needed, and the management is predominantly supportive. In patients with severe forms of IRS, however, immunosuppressive therapies in addition to anti-microbial therapies are necessary to ameliorate clinical symptoms [53]. In case of DiHS/DRESS, anti-microbial therapies should be avoided because they may increase the risk of

Table 1 Clinical illness consistent with IRS

Mycobacterium avium complex infection
Tuberculosis
Cryptococcosis
Herpes simplex
Herpes zoster
Hepatitis C virus infection
Hepatitis B virus infection
Cytomegalovirus infection
Sarcoidosis
Graves disease
Hashimoto thyroiditis
Drug-induced hypersensitivity syndrome

Modified from [53]

developing additional drug rashes due to cross-reactivity to multiple drugs, which has been reported to occur. During the course of DiHS/DRESS, systemic corticosteroids gave promising results in terms of ameliorating vigorous restoration of immune responses to pathogens, which is reflected in the clinical manifestations. Nevertheless, once systemic corticosteroids have started, drug dose should be reduced gradually upon resolution of clinical manifestation. We have to recognize that patients under immunosuppressive therapy, particularly those with DiHS/DRESS, are at greater risk of subsequently developing the wide spectrum of IRS ranging from herpes zoster to fatal CMV disease [41]. Our frequent monitoring of viral loads in the course of DiHS/DRESS revealed that the increase in CMV DNA loads coincided with a tapering of corticosteroid dose. This finding indicates that tapering corticosteroids more gradually over a prolonged period of time may help to limit the severity of IRS. The usual dose for the treatment of DiHS/DRESS is prednisolone 40–60 mg/kg. This dose needs to be tapered over 8–12 weeks to prevent the relapse of various symptoms as manifestation of IRS. The pattern of viral reactivations enhanced upon immune restoration would be different depending on the virus, immunosuppressive agents, or regimens. Given the ability of corticosteroids to reduce the EBV loads in patients with DiHS/DRESS, patients who are at risk of subsequently developing EBV-associated autoimmune disease may benefit from systemic corticosteroids.

Conclusion

Although we know that sequential reactivations of herpesviruses occur in many patients with DiHS/DRESS and that increased EBV loads during the course of the disease may lead to the generation of autoantibodies, the causal role of herpesviruses in the development of severe drug eruptions, if any, remains to be defined. Together with the current knowledge of anti-viral immune responses, we are now in a position to dissect the relative contribution of these responses to protective immunity and immunopathology.

Acknowledgments This work was supported in part by grants from the Ministry of Education, Culture, Sports, Science and Technology (to T.S.) and the Health and Labour Sciences Research Grants (Research on Intractable Diseases) from the Ministry of Health, Labour and Welfare of Japan (to T.S.).

References

1. Pullen H, Wright N, Murdoch JM (1967) Hypersensitivity reactions to antibacterial drugs in infectious mononucleosis. Lancet 2:1176–1178
2. Coopman SA, Johnson RA, Platt R, Stern RS (1993) Cutaneous disease and drug reactions in HIV. N Engl J Med 328:1670–1674
3. Levy M (1984) The combined effect of viruses and drugs in drug-induced diseases. Med Hypotheses 14:293–296
4. Shiohara T, Kano Y (2007) A complex interaction between drug allergy and viral infection. Clin Rev Allergy Immunol 33:124–133
5. Aota N, Hirahara K, Kano Y, Fukuoka T, Yamada A, Shiohara T (2009) Systemic lupus erythematosus presenting with Kikuchi–Fujimoto's disease as a long-term sequela of drug-induced hypersensitivity syndrome. A possible role of Epstein–Barr virus reactivation. Dermatology 218:275–277
6. Hirahara K, Kano Y, Mitsuyama Y, Takahashi R, Kimishima M, Shiohara T (2010) Differences in immunological alterations and underlying viral infections in two well-defined severe drug eruptions. Clin Exp Dermatol 35:863–868
7. Suzuki Y, Inagi R, Aono T, Yamanishi K, Shiohara T (1998) Human herpesvirus 6 infection as a risk factor for the development of severe drug-induced hypersensitivity syndrome. Arch Dermatol 134:1108–1112
8. Tohyama H, Yahata Y, Hashimoto K et al (1998) Severe hypersensitivity syndrome due to sulfasalazine associated with reactivation of human herpesvirus 6. Arch Dermatol 134:1113–1117
9. Gebhardt T, Wakim LM, Eidsmo L, Reading PC, Heath WR, Carbone FR (2009) Memory T cells in nonlymphoid tissue that provide enhanced local immunity during infection with herpes simplex virus. Nat Immunol 10:524–530
10. Gebhardt T, Whitney PG, Mueller SN et al (2011) Different patterns of peripheral migration by memory $CD4^+$ and $CD8^+$ T cells. Nature 477:216–219
11. Ariotti S, Beltman JB, Schumacher TN et al (2012) Tissue-resident memory $CD8^+$ T cells continuously patrol skin epithelia to quickly recognize local antigen. Proc Natl Acad Sci U S A 109:19739–19744
12. Jiang X, Clark PA, Liu L, Wagers AJ, Fuhlbrigge RC, Kupper TS (2012) Skin infection generates non-migratory memory $CD8^+$ T(RM) cells providing global skin immunity. Nature 483:227–231
13. Hofmann M, Pircher H (2011) E-cadherin promotes accumulation of a unique memory CD8 T-cell population in murine salivary glands. Proc Natl Acad Sci U S A 108:16741–16746
14. Mackay LK, Stock AT, Ma JZ et al (2012) Long-lived epithelial immunity by tissue-resident memory T (TRM) cells in the absence of persisting local antigen presentation. Proc Natl Acad Sci U S A 109:7037–7042
15. Shiohara T, Mizukawa Y (2012) Fixed drug eruption: the dark side of activation of intraepidermal $CD8^+$ T cells uniquely specialized to mediate protective immunity. Chem Immunol Allergy 97:106–121
16. Shiohara T (2009) Fixed drug eruption: pathogenesis and diagnostic tests. Curr Opin Allergy Clin Immunol 9:316–321
17. Mizukawa Y, Shiohara T (2002) Trauma-localized fixed drug eruption: involvement of burn scars, insect bites and venipuncture sites. Dermatology 205:159–161
18. Sigal-Nahum M, Konqui A, Gaulier A, Sigal S (1988) Linear fixed drug eruption. Br J Dermatol 118:849–851
19. Senturk N, Yanik F, Yildiz L, Aydin F, Canturk T, Turanli AY (2002) Topotecan-induced cellulitis-like fixed drug eruption. J Eur Acad Dermatol Venereol 16:414–416
20. Komatsu T, Moriya N, Shiohara T (1996) T cell receptor (TCR) repertoire and function of human epidermal T cells: restricted TCR Vα–Vβ genes are utilized by T cells residing in the lesional epidermis in fixed drug eruption. Clin Exp Immunol 104:343–350
21. Mizukawa Y, Yamazaki Y, Shiohara T et al (2002) Direct evidence for IFN-γ production by effector-memory-type intraepidermal T cells residing at an effector site of immunopathology in fixed drug eruption. Am J Pathol 161:1337–1347
22. Cornberg M, Chen AT, Selin LK et al (2006) Narrowed TCR repertoire and viral escape as a consequence of heterologous immunity. J Clin Invest 116:1443–1456
23. Burrows SR, Khanna R, Burrows JM, Moss DJ (1994) An alloresponse in humans is dominated by cytotoxic T lymphocytes

(CTL) cross-reactive with a single Epstein–Barr virus CTL epitope: implications for graft-versus-host disease. J Exp Med 179:1155–1161
24. Burrows SR, Silins SL, Moss DJ, Khanna R, Misko IS, Argaet VP (1995) T cell receptor repertoire for a viral epitope in humans is diversified by tolerance to a background major histocompatibility complex antigen. J Exp Med 182:1703–1715
25. Burrows SR, Silins SL, Moss DJ (1997) Cross-reactive memory T cells for Epstein–Barr virus augment the alloresponse to common human leukocyte antigens: degenerate recognition of major histocompatibility complex-bound peptide by T cells and its role in alloreactivity. Eur J Immunol 27:1726–1736
26. Koehn B, Gangappa S, Miller JD, Ahmed R, Larsen CP (2006) Patients, pathogens, and protective immunity: the relevance of virus-induced alloreactivity in transplantation. J Immunol 176: 26912696
27. Archbold JK, Macdonald WA, Rossjohn J et al (2009) Natural micropolymorphism in human leukocyte antigens provides a basis for genetic control of antigen recognition. J Exp Med 206:209–219
28. Mizukawa Y, Yamazaki Y, Shiohara T (2008) In vivo dynamics of intraepidermal $CD8^+$ T cells and $CD4^+$ T cells during the evolution of fixed drug eruption. Br J Dermatol 158:1230–1238
29. Takahashi R, Kano Y, Yamazaki Y, Kimishima M, Mizukawa Y, Shiohara T (2009) Defective regulatory T cells in patients with severe drug eruptions: timing of the dysfunction is associated with the pathological phenotype and outcome. J Immunol 182:8071–8079
30. Peng G, Guo Z, Wang R-F et al (2005) Toll-like receptor 8-mediated reversal of $CD4^+$ regulatory T cell function. Science 309:1380–1384
31. Pasare C, Medzhitov R (2003) Toll pathway-dependent blockade of $CD4^+CD25^+$ T cell-mediated suppression by dendritic cells. Science 299:1033–1036
32. Lühn K, Simmons CP, Rowland-Jones S et al (2007) Increased frequencies of $CD45^+$CD25 (high) regulatory T cells in acute dengue infection. J Exp Med 204:979–985
33. Yu XL, Cheng YM, Ghildyal R et al (2008) Measles virus infection in adults induces production of IL-10 and is associated with increased $CD4^+CD25^+$ regulatory T cells. J Immunol 181:7356–7366
34. Kubota Y, Nakaura J, Nakayama J (2005) Stevens–Johnson syndrome due to allopurinol with positive DLST to several other drugs. Jpn J Dermatol 116:927–934 (in Japanese)
35. Shiohara T, Kano Y (2012) Drug-induced hypersensitivity syndrome: recent advances in drug allergy. Expert Rev Dermatol 7:539–547
36. Shiohara T (2007) Drug-induced hypersensitivity syndrome and viral reactivation. In: Pichler WJ (ed) Drug hypersensitivity. Karger, Basel, pp 251–266
37. Tohyama M, Hashimoto K, Shear NH et al (2007) Association of human herpesvirus 6 reactivation with the flaring and severity of drug-induced hypersensitivity syndrome. Br J Dermatol 157:934–940
38. Shiohara T, Iijima M, Ikezawa Z, Hashimoto K (2007) The diagnosis of a DRESS syndrome has been sufficiently established on the basis of typical clinical features and viral reactivations. Br J Dermatol 156: 1083–1084
39. Kano Y, Hirahara K, Sakuma K, Shiohara T (2006) Several herpesviruses can reactivate in a severe drug-induced multiorgan reaction in the same sequential order as in graft-versus-host disease. Br J Dermatol 155:301–306
40. Agut H (1993) Puzzles concerning the pathogenicity of human herpesvirus 6. N Engl J Med 329:203–204
41. Asano Y, Kagawa H, Kano Y, Shiohara T (2009) Cytomegalovirus disease during severe drug eruption: report of 2 cases and retrospective study of 18 patients with drug-induced hypersensitivity syndrome. Arch Dermatol 145:1030–1036
42. Picard D, Janela B, Musette P et al (2010) Drug reaction with eosinophilia and systemic symptoms (DRESS): a multiorgan antiviral T cell response. Sci Transl Med 2:46–62
43. Takahashi R, Kano Y, Yamazaki Y, Kimishima M, Mizukawa Y, Shiohara T (2009) Defective regulatory T cells in patients with severe drug eruptions: timing of the dysfunction is associated with the pathological phenotype and outcome. J Immunol 182:8071–8079
44. Korn T, Mitsdoerffer M, Oukka M et al (2008) IL-6 controls Th17 immunity in vivo by inhibiting the conversion of conventional T cells into $Foxp3^+$ regulatory T cells. Proc Natl Acad Sci U S A 105:18460–18465
45. Hall BM, Verma ND, Tran GT, Hodgkinson SJ (2011) Distinct regulatory $CD4^+$ T cell subsets: differences between naïve and antigen specific T regulatory cells. Curr Opin Immunol 23:641–647
46. Kano Y, Sakuma K, Shiohara T (2007) Sclerodermoid graft-versus-host disease-like lesions occurring after drug-induced hypersensitivity syndrome. Br J Dermatol 156:1061–1063
47. Aota N, Shiohara T (2009) Viral connection between drug rashes and autoimmune diseases: how autoimmune responses are generated after resolution of drug rashes. Autoimmun Rev 8:488–494
48. Ishida T, Kano Y, Mizukawa Y, Shiohara T (2014) The dynamics of herpesvirus reactivations during and after severe drug eruptions: their relation to the clinical phenotype and therapeutic outcome. Allergy (in press)
49. Hirahara K, Kano Y, Mitsuyama Y, Takahashi R, Kimishima M, Shiohara T (2010) Differences in immunological alterations and underlying viral infections in two well-defined severe drug eruptions. Clin Exp Dermatol 35:863–868
50. Ushigome Y, Kano Y, Ishida T, Hirahara K, Shiohara T (2013) Short- and long-term outcomes of 34 patients with drug-induced hypersensitivity syndrome in a single institution. J Am Acad Dermatol 68: 721–728
51. Miceli MH, Maertens J, Anaissie EJ et al (2007) Immune reconstitution inflammatory syndrome in cancer patients with pulmonary aspergillosis recovering from neutropenia: proof of principle, description, and clinical and research implications. Cancer 110:112–120
52. Legrand F, Lecuit M, Lortholary O et al (2008) Adjuvant corticosteroid therapy for chronic disseminated candidiasis. Clin Infect Dis 46: 696–702
53. Shiohara T, Kurata M, Mizukawa Y, Kano Y (2010) Recognition of immune reconstitution syndrome necessary for better management of patients with severe drug eruptions and those under immunosuppressive therapy. Allergol Int 59:333–343
54. Smith KJ, Skelton HG, Yeager J, Ledsky R, Ng TH, Wagner KF (1997) Increased drug reactions in HIV-1 positive patients: a possible explanation based on patterns of immune dysregulation seen in HIV-1 disease. The Military Medical Consortium for the Advancement of Retroviral Research (MMCARR). Clin Exp Dermatol 22:118–123
55. Garcia Vidal C, Rodriguez Femandez S, Garau J et al (2005) Paradoxical response to antituberculous therapy in infliximab-treated patients with disseminated tuberculosis. Clin Infect Dis 40: 756–759
56. Arend SM, Leyten EM, Franken WP, Huisman EM, van Dissel JT (2007) A patient with de novo tuberculosis during anti-tumor necrosis factor-α therapy illustrating diagnostic pitfalls and paradoxical response to treatment. Clin Infect Dis 45:1470–1475
57. Belknap R, Reves R, Burman W (2005) Immune reconstitution to *Mycobacterium tuberculosis* after discontinuing infliximab. Int J Tuberc Lung Dis 9:1057–1058
58. Marais S, Wilkinson RJ, Pepper DJ, Meintjes G (2009) Management of patients with the immune reconstitution inflammatory syndrome. Curr HIV/AIDS Rep 6:162–171
59. Shelburne SA 3rd, Hamill RJ, Rodriguez-Barradas MC, Greenberg SB, Atmar RL, Musher DW, Gathe JC Jr, Visnegarwala F, Trautner BW (2002) Immune reconstitution inflammatory syndrome: emergence of a unique syndrome during highly active antiretroviral therapy. Medicine 81:213–227