CONTACT POINTS

CONTACT DERMATITIS 2005: 53: 52–64 • COPYRIGHT © BLACKWELL MUNKSGAARD 2005 • ALL RIGHTS RESERVED

• CONTRIBUTIONS TO THIS SECTION WILL NOT UNDERGO PEER REVIEW, BUT WILL BE REVIEWED BY THE EDITOR •

Contact sensitivity to cigarettes

Contact Dermatitis 2005: 53: 52–53

Atsuko Kato, Akinobu Shoji and Natsuko Aoki

Department of Dermatology, Osaka Kaisei Hospital, Toyosaki, Kita-ku, Osaka, Japan

Key words: airborne contact dermatitis; cigarette; fragrance; pigmented type; tobacco.

Allergic contact dermatitis from cigarettes is rare and few reports have been published (1, 2).

Case Report

A 54-year-old woman presented with a 10-month history of erythematous macules and brownish pigmentation on and above the upper lip (Fig. 1). She had itching on her lesions when she had contact with strong fragrance. She had smoked for 10 years.

Patch tests were performed with the cigarettes she smoked, a cosmetic she used, the Japanese standard series, a fragrance series, tar and nicotine. Patch tests showed a positive reaction to unsmoked tobacco from the cigarettes. Doubtful (?+) reactions were obtained to smoked tobacco and smoked filter. Unsmoked filter, cigarette paper, another kind of cigarette she did not smoke, tar, nicotine and the cosmetic were negative (Table 1). A patch test to tobacco was negative in five controls.

The patient recovered after she stopped smoking.

Comment

Contact dermatitis from tobacco has been described mainly as an occupational irritant contact dermatitis (3). In the present case, the positive patch test reaction to tobacco was considered to be allergic because of its appearance and the lack of irritability in controls.

Fig. 1. Clinical features on presentation.

Patch test results suggest that a major allergen among cigarette components is volatile, because unsmoked tobacco showed a stronger reaction than smoked tobacco on patch testing. We considered the allergen to be a specific volatile material in her cigarette, e.g. fragrance, because another kind of cigarette, tar and nicotine were negative on patch testing. The cigarettes she smoked contained a kind of chocolate fragrance. But the maker did not disclose the components, so we could not further identify an allergen. A significant positive correlation between positive tests to cigarette components and fragrances was reported by Dawn et al. (4).

Airborne contact dermatitis presents with eczema on shaded areas and in the upper lip area. Our case showed erythema and pigmentation on and above the upper lip, and seems to have been a pigmented type of airborne contact dermatitis.

Table 1. Patch test results

Materials	D2	D3
Cigarette she smoked		
Tobacco (as is)	?+	+
Smoked tobacco (as is)	–	?+
Smoked filter (as is)	–	?+
Unsmoked filter (as is)	–	–
Cigarette paper (as is)	–	–
Pix Betulae (birch tar) (3% petrolatum)	–	–
Pix Liquida (pine tar) (3% pet.)	–	–
Pix Lithanthracis (coal tar) (3% pet.)	–	–
Nicotine (4% aq.)	–	–
Cosmetic she used	–	–
Japanese standard series	–	–
Fragrance series	–	–
Chocolate	–	–
Cinnamon	–	–

References

1. Rycroft R J G. Tobacco dermatitis. *Br J Dermatol* 1980: 103: 225–229.

2. Neild V. Contact dermatitis from a cigarette constituent. *Contact Dermatitis* 1981: 7: 153–154.
3. Rycroft R J G, Smith N P, Stok E T, Middleton K. Investigation of suspected contact sensitivity to tobacco in cigarette and cigar factory employees. *Contact Dermatitis* 1981: 7: 32–38.
4. Dawn G, Fleming C J, Forsyth A. Contact sensitivity to cigarettes and matches. *Contact Dermatitis* 1999: 40: 236–238.

Address:
Atsuko Kato
Department of Dermatology
Osaka Kaisei Hospital
4-6-6 Toyosaki
Kita-ku
Osaka 531-0072
Japan
Tel: +81 6 6371 6234
Fax: +81 6 6372 8566
e-mail: kaisei@isis.ocn.ne.jp

Positive lymphocyte transformation test in a patient with allergic contact dermatitis of the scalp after short-term use of topical minoxidil solution

Contact Dermatitis 2005: 53: 53–55

Tobias Hagemann, Brigitte Schlütter-Böhmer, Jean-Pierre Allam, Thomas Bieber and Natalija Novak

Department of Dermatology, University of Bonn, Bonn, Germany

Topical 2,4-diamino-6-piperidino-pyrimidine-3-oxide (minoxidil) solution has been widely used for the treatment of androgenetic alopecia for over 15 years now and the substance is currently approved for this indication in 2% and 5% formulation. Typical side effects of this topical treatment include irritative dermatitis going along with pruritus, erythema, scaling and dryness, which occur especially at the onset of the therapy. In some cases, allergic contact dermatitis or exacerbation of seborrhoic dermatitis has been reported. While most of the patients with allergic contact dermatitis described in the literature showed a positive sensitization to the vehicle substance propylene glycol evaluated by patch testing, reactions to the active ingredient minoxidil are rare. Here, we report a case of allergic sensitization to minoxidil, which we evaluated and differentiated from an irritative reaction by a combination of patch testing and lymphocyte transformation test. The differentiation of allergic and irritative adverse effects and the identification of the causative allergen are of major relevance for the proceeding and adjustment of the therapy. Patients with sensitizations against propylene glycol are candidates for preparations with alternative solvents but can proceed treatment with minoxidil. In contrast, patients with allergies to the active ingredient itself are no longer candidates for treatment with minoxidil and should undergo alternative therapeutic options.

Key words: contact dermatitis; lymphocyte transformation test; minoxidil; propylene glycol.

Case Report

A 72-year-old woman with a history of androgenetic alopecia used topical 2,4-diamino-6-piperidinopyrimidine-3-oxide (minoxidil) solution 5%, which has been prescribed by her family doctor to treat her increased hair loss. After 8 days of treatment, she complained about increased pruritus and scaling of the scalp. 2 days later, she presented with weeping dermatitis of the scalp and inflammatory lesions and oedema of the forehead, periorbital region and neck.

On admission at our department, minoxidil solution therapy has been stopped and topical corticosteroid therapy twice a day has been started without any sufficient effect. Therefore, topical therapy has been combined with oral therapy with 1 mg prednisone per kilogram body weight and oral antihistamines. Thereby, rapid improvement of the skin lesions on the scalp has been achieved.

The patient had a positive family history of atopic diseases and reported a mild persistent rhinitis, but there was no positive history of any allergic contact sensitization. In addition, the patient had Type II diabetes mellitus and hypertension. Laboratory testing showed a total serum immunoglobulin (IgE) level of 229 kU/l with allergen-specific IgE against *Dermatophagoides pteronyssinus* 7.4 kU/l, *Dermatophagoides farinae* 16.5 kU/l and *Candida albicans* 1.46 kU/l.

After discontinuation of corticosteroid treatment, epicutaneous patch testing has been performed. While the application of the vehicle substances propylene glycol and ethanol alone did not show any positive patch test reaction, a strong allergic contact reaction to nickel and the compound Regaine® developed in our patient (Fig. 1). Furthermore, patch testing of the single compounds, i.e. the active ingredient minoxidil, propylene glycol and ethanol in addition to Regaine® 2% and Regaine® 5%, has been performed and showed a positive patch reaction to Regaine® 2%, Regaine® 5% and minoxidil after 48 hr with an increase of these reactions after 72 hr (Fig. 2a,b). To underscore the diagnosis, lymphocyte transformation tests (LTTs) of freshly isolated peripheral blood mononuclear cells (PBMCs) of the patient and a

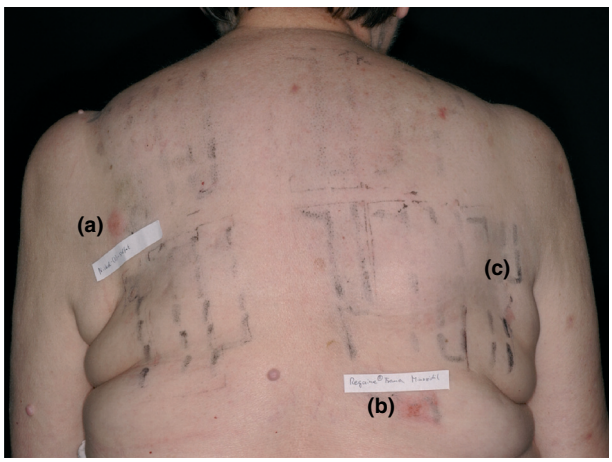

Fig. 1. Patch test result of our patient with positive reaction to nickel (a) and Regaine® 2% (b), while no reactions to propylene glycol occurred (c).

healthy control donor with increasing concentrations of Regaine®, minoxidil, propylene glycol and ethanol have been performed.

Human PBMCs were obtained from heparinized blood (50–100 ml) by density gradient centrifugation. Briefly, after the blood was diluted 3 times with phosphate-buffered saline (PBS), 25 ml of suspended cells were overlaid on 15 ml of Lymphoprep (Progen, Heidelberg, Germany). PBMCs were isolated as interface cells after density gradient centrifugation (20 min at 900 × ***g*** at room temperature). RPMI-1640 (Invitrogen, Karlsruhe, Germany) containing 5% heat-inactivated human AB Serum (Biowhittacker, Walkersville, MD, USA), 1% L-Glutamine, 100 IU ml Penicillin and 100 μg/ml Streptomycin (Invitrogen GmbH, Karlsruhe, Germany). The cells were cultured in U-bottomed 96-well plates (Costar, Cambridge, MA, USA), using 2×10^5 cells in 200 μl volume per well in triplicate. The cells were either cultured alone or stimulated with phytohaemagglutinin (Sigma Aldrich, Munich, Germany) 10 μg/well with and without various concentrations of the indicated drug dissolved in cell culture medium or PBS for 96 hr. For the last 18 hr, 0.6 μCi ^{3}H-thymidine (Amersham Pharmacia Biotech, Buckinghamshire, UK) was added to each well. Cells were then harvested and incorporated radioactivity reflecting T-cell proliferation was measured in a scintillation counter (1450 MicroBeta Trilux, Wallac, Turku, Finnland) as counts per minute (cpm). Stimulation index (SI) represents the ratio of average cpm, and an SI exceeding 2.0 (cut-off) was considered a significant positive result in relation to the international literature (Brander C et al., J Immunol 1995). LTT showed a 2.5- and 7.4-fold (Regaine® at a concentration of 100 μg/ml and 400 μg/ml) enhanced proliferation of the patient's PBMCs incubated with Regaine®, a 7-fold (minoxidil at a concentration of 100 μg/ml) and 16.1-fold (minoxidil at a concentration of 400 μg/ml) enhanced proliferation of PBMCs incubated with the active component minoxidil alone (Fig. 3 and Table 1). In contrast, PBMCs, of our patient and a control volunteer, incubated with increasing concentrations of propylene glycol and ethanol displayed no differences in their proliferation rate (Fig. 3 and Table 1). To exclude any toxic effect of the different substances, control experiments in which PBMCs have been stimulated additionally with phytohaemagglutinin-A (PHA) have been performed and showed an unaffected proliferation of PBMCs at any concentration used without any inhibition >15% of the PHA-induced stimulation by any drug (Fig. 4). Based on the results above, we diagnosed a sensitization to minoxidil in Regaine® as a cause of the allergic contact dermatitis in our patient.

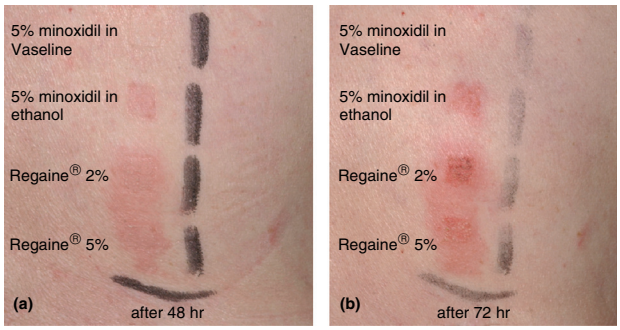

Fig. 2. Verification of the results with patch test of 5% minoxidil in Vaseline, 5% minoxidil in ethanol, Regaine® 2%, Regaine® 5% after 48 hr (a) and 72 hr (b) of application.

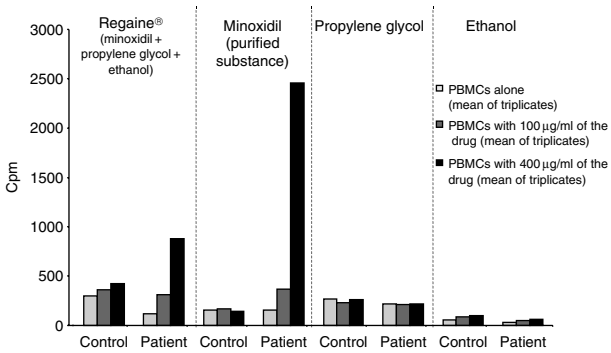

Fig. 3. Lymphocyte proliferation responses to different concentrations (100 μg/ml = dark grey bars; 400 μg/ml = black bars) of minoxidil, ethanol and propylene glycol or Regaine® in a healthy control (Control) and our patient (Patient) are shown in comparison to lymphocytes alone (light grey bars). The counts per minute (cpm) are depicted on the *y*-axis. The proliferative values are indicated as cpm on the *y*-axis and each condition has been performed in triplicate. An enhanced proliferative response has been observed in lymphocytes of our patient coincubated with Regaine® or minoxidil.

Table 1. The stimulation index (SI) calculated separately by proliferation in counts per minute (cpm) with drug/proliferation in cpm without drug for the healthy control and the patient

Donor	Drug	SI (100 μg/ml)	SI (400 μg/ml)
Control	Regaine	1.2	1.4
Patient	Regaine	2.5*	7.4*
Control	Minoxidil	1.0	0.9
Patient	Minoxidil	7*	16.1*
Control	Propylene glycol	1.0	1.0
Patient	Propylene glycol	1	1.8
Control	Ethanol	1.4	1.6
Patient	Ethanol	1.6	2.1

*An SI of >2.0 has been used to classify the test as positive. According to this classification, positive reaction to Regaine® at a concentration of 100 μg/ml and 400 μg/ml and strong positive reaction to minoxidil itself at both concentrations used has been observed in our patient, while no positive reaction occurred in our control volunteer.

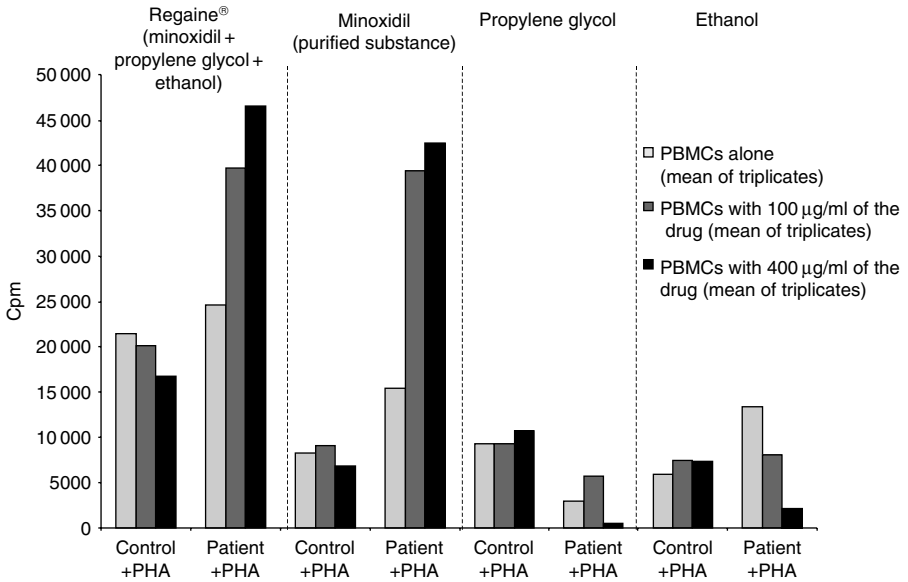

Fig. 4. Lymphocyte proliferation response to different concentrations (100 µg/ml = dark grey bars; 400 µg/ml = black bars) of minoxidil, ethanol and propylene glycol or Regaine® of a healthy control (Control) and our patient (Patient) stimulated with phytohaemagglutinin-A (PHA) are shown (light grey bars). The proliferative values are depicted as counts per minute (cpm) on the *y*-axis and each condition has been performed in triplicate. Again an enhanced proliferative response has been observed in lymphocytes of our patient coincubated with Regaine® or minoxidil.

Discussion

Regaine® consists of minoxidil, ethanol, propylene glycol and purified water and is used since several years very efficiently for the treatment of androgenetic alopecia (1, 2).

Regaine® is generally well tolerated (1), except for the development of local irritations in some of the patients. However, a small subset of patients develops allergic contact dermatitis, which is in most of the cases caused by the vehicle substance propylene glycol (3). In contrast, sensitizations to the active ingredient minoxidil are extremely rare but preclude these patients from any further treatments with preparations containing minoxidil (3). Most of the cases describing a sensitization against Regaine® refer to a long-time use of this agent (3). A reaction within only 10 days of use has not been observed before and might be caused by a general hyperactivity of atopic patients. In contrast to real allergic contact dermatitis, atopic patients tend to develop more often irritant contact dermatitis then non-atopics. Therefore, in case of eczematous reactions to Regaine®, besides irritative reactions, even allergic contact reactions should be considered and sensitization to both the vehicle substances and the active ingredient itself should be evaluated (1). We showed here that besides patch testing with the ingredients, LTT represents another diagnostic tool to specify the diagnosis of an allergic contact sensitization. The LTT measures proliferation of T cells to a drug *in vitro* and bases on a reaction to this drug due to a sensitization *in vivo* (5). Because some substances such as minoxidil also cause irritative reactions, which are very difficult to distinguish from allergic reactions in highly sensitized patients as in our case, the supplementary evaluation with the help of LTT is regarded as a useful complementary read-out device in the clinical practice. The differentiation of allergic and irritative adverse effects and the identification of the causative allergen are of major relevance for the proceeding and adjustment of the therapy, for patients with sensitizations against propylene glycol are candidates for preparations with alternative solvents (3, 6). On the other hand, patients with allergies to the active ingredient itself are no longer candidates for treatment with minoxidil and should undergo alternative therapeutic options (3).

References

1. Lucky A W, Piacquadio D J, Ditre C M, Dunlap F, Kantor I, Pandya A G, Savin R C, Tharp M D. A randomized, placebo-controlled trail of 5% and 2% topical minoxidil solutions in the treatment of female pattern hair loss. *J Am Acad Dermatol* 2004: 50: 541–553.
2. Price V H, Menefee E, Strauss P C. Changes in hair weight and hair count in men with androgenetic alopecia, after application of 5% and 2% topical minoxidil, placebo, or no treatment. *J Am Acad Dermatol* 1999: 41: 717–721.
3. Friedman E S, Friedman P M, Cohen D E, Washenik K. Allergic contact dermatitis to topical minoxidil solution: etiology and treatment. *J Am Acad Dermatol* 2002: 46: 309–312.
4. Ebner H, Muller E. Allergic contact dermatitis from minoxidil. *Contact Dermatitis* 1995: 32: 316–317.
5. Pichler W J, Tilch J. The lymphocyte transformation test in the diagnosis of drug hypersensitivity. *Allergy* 2004: 59: 809–820.
6. Scheman A J, West D P, Hordinksy M K, Osburn A H, West L E. Alternative formulation for patients with contact reactions to topical 2% and 5% minoxidil vehicle ingredients. *Contact Dermatitis* 2000: 42: 241.
7. Ellis J A, Sinclair R, Harrap S B. Androgenetic alopecia: pathogenesis and potential for therapy. *Expert Rev Mol Med* 2002: 19: 1–11.

Address:
Natalija Novak, MD
Department of Dermatology
University of Bonn
Sigmund-Freud-Str. 25
53105 Bonn
Germany
Tel: +49 228 287 4420
Fax: +49 228 287 4883
e-mail: natalija.novak@ukb.uni-bonn.de

Erythema multiforme induced by acetaminophen: a recurrence at distant sites following patch testing

Contact Dermatitis 2005: 53: 56–57

Se Woong Oh and Wook Lew

Department of Dermatology, Yonsei University College of Medicine, Seoul, Korea

Key words: erythema multiforme; patch testing; acetaminophen; epoxy resin.

Case Report

A 19-year-old woman visited the clinic with a history of recurrent rashes and vesicles for 2 years. The patient had several erythematous macules 0.5–1 cm in length and patches with target-like bulla in the centre mainly on her palms and upper extremities (Fig. 1). She had no mucosal lesions or other symptoms. She had taken the acetaminophen, alibendol, thymoxamine, serratiopeptidase and ofloxacin, 1 day before developing lesions. The patient's history included a case of severe erythema multiforme (EM), requiring hospitalization after taking the medication which contained acetaminophen. She was treated with systemic and topical steroids and antihistamine with a good response. 2 weeks after treatment, the lesions were completely resolved. A patch test with 0.1% acetaminophen pure powder in petrolatum was applied on the forearm and allowed to react for 2 days. However, there was no response on the patch test site for pure acetaminophen powder in petrolatum. Interestingly, 1 day after patch testing of the pure powder of acetaminophen in petrolatum, EM lesions started to develop on the palm-side of the patient's fingers and then spread centripetally. 4 months later, the standard patch test was performed. A weak-positive reaction to epoxy resin at the patch application site was observed and EM lesions developed at distant sites.

Fig. 1. Several 0.5–1 cm sized erythematous macules with target-like erythema in the centre were observed on the patient's palm.

Discussion

In this case, the standard patch test showed a positive reaction to epoxy resin and provoked the development of EM lesions. Acetaminophen pure powder induced EM lesions, following patch testing, on distant parts of the extremities. However, there was no reaction on the patch test site for pure acetaminophen powder. Therefore, it is suggested that certain metabolites of acetaminophen, rather than acetaminophen itself, may stimulate immune cells to develop EM at distant sites. It seems likely that epoxy resin may have cross-reacting potential with certain metabolites of acetaminophen, such as epoxide intermediates (1–3). This patient is frequently exposed to paint because of her profession as a painter and frequently gets EM lesions. During the follow-up period, we could observe that she had an erythema on her palm and wrist, which is a frequent contact area with paint. Although we could not detect a positive patch test reaction by several colours of paints she was using, it seems likely that the EM lesions develop after exposure to epoxy resins in certain paints.

It has been reported that EM may occur in association with patch testing (4, 5). Although it has lower sensitivity than an oral challenge, patch testing is advisable as the initial diagnostic method because of a reduced risk for the patient (5). Acetaminophen is commonly used, but previously reported cases of EM caused by acetaminophen use are relatively rare (6, 7). In addition, there have been no previous case reports of EM developing after acetaminophen patch testing.

References

1. Hinson J A, Pohl L R, Monks T J, Gillette J R, Guengerich F P. 3-Hydroxyacetaminophen: a microsomal metabolite of acetaminophen. *Drug Metab Dispos* 1980: 8: 289–294.
2. Hinson J A. Reactive metabolites of phenacetin and acetaminophen: a review. *Environ Health Perspect* 1983: 49: 71–79.

3. Notarianni L J, Oldham H G, Bennett P N, Southgate C C, Parfitt R T. Epoxides from paracetamol – a possible explanation for paracetamol toxicity. *Adv Exp Med Biol* 1981: 136: 1077–1083.
4. O'Donnell B F, Tan C Y. Erythema multiforme reaction to patch testing. *Contact Dermatitis* 1992: 27: 230–234.
5. de Frutos C, de Barrio M, Tornero P, Barranco R, Rodriguez A, Rubio M. Erythema multiforme from sulfaguanidine. *Contact Dermatitis* 2002: 46: 186–187.
6. Ting H C, Adam B A. Erythema multiforme: epidemiology, clinical characteristics and natural history in fifty-nine patients. *Australas J Dermatol* 1984: 25: 83–88.
7. Dubey N K, Jajoo D, Gupta A, Sharma D. Antipyretics induced erythema multiforme. *Indian Pediatr* 1995: 32: 1117–1119.

Address:
Wook Lew, MD, PhD
Department of Dermatology
Yonsei University College of Medicine
Yongdong Severance Hospital
146-92, Dogok-dong
Kangnam-gu
Seoul 135-720
Korea
Tel: +82 2 3497 3362
Fax: +82 2 3463 6136
e-mail: wlewderm@yumc.yonsei.ac.kr

Delayed-type hypersensitivity to protamine as a complication of insulin therapy

Contact Dermatitis 2005: 53: 57–58

Ulrike Raap, Tim Liekenbröcker, Alexander Kapp and Bettina Wedi

Department of Dermatology and Allergology, Hannover Medical University, Ricklingerstr. 5, 30449 Hannover, Germany

Key words: delayed-type hypersensitivity; diabetes mellitus; insulin; local reaction; protamine.

Reactions to insulin therapy have occurred since the introduction of animal insulin in 1922. However, since the introduction of human insulin (Humalog®, Lilly Pharma, Bad Homburg, Germany), the incidence of insulin-induced allergic reactions has decreased. Although the most common insulin-induced reactions are of local character at the injection site, systemic reactions may also occur, but rarely (1, 2). Reactions to protamine-containing insulins may be caused by the protamine component in the insulin preparation and not by the insulin itself (3). Protamine sulphate is a low-molecular weight polycationic protein purified commercially from the sperm of matured testes of salmon or related fish. It is complexed to insulin to delay absorption, thereby prolonging the pharmacologic effect, and is used in order to reverse the anticoagulant properties of heparin. Intravenous administration of protamine can cause acute reactions, such as anaphylaxis, urticaria, bronchospasm and hypotension due to non-immune-mediated histamine release (4). However, delayed reactions also have been described in rare cases (5).

Case Report

A 63-year-old man with insulin-dependent diabetes mellitus received daily doses of Protaphane insulin HM NovoLet® (Novo Nordisk Pharma, Mainz, Germany) subcutaneously. Two months after initiation of insulin therapy, the patient complained of itchy erythematous plaques at insulin injection sides 24 hr after injection. The plaques became eczematous after 48 hr and disappeared within a few days. The patient was admitted to our hospital to evaluate possible insulin allergy.

Total serum IgE (2080 kU/l) was increased, protamine-specific IgE was not detectable (<0.35 kU/l, Uni-Cap class 0) and IgE specific to human insulin was 2.47 kU/l (Uni-Cap class 2). Skin scratch test with

Table 1. Intradermal skin test of Novo Nordisk Protaphane HM NovoLet® ingredients (Novo Nordisk Allergy kit®)

Substance	20 min†	24 hr†	48 hr†
Protaphane Insulin HM NovoLet® 3 mL	–	+ +	+
Human insulin 5 IU/ml *Insulin Human, Biosynthetic 5 IU (0.17 mg), metacresol 3 mg, glycerol 16 mg and water for injections	–	–	–
Porcine insulin 5 IU/ml *Porcine monocomponent insulin 5 IU (0.17 mg), metacresol 3 mg, glycerol 16 mg and water for injections	–	–	–
Paraben medium *Methylparahydroxybenzoate 1 mg, sodium acetate 1.4 mg, sodium chloride 7 mg and water for injections	–	–	–
Phenol medium *Phenol 2 mg, glycerol 16 mg and water for injections	–	–	–
Metacresol medium *Metacresol 3 mg, glycerol 16 mg and water for injections	–	–	–
Zinc medium *Zinc chloride 0.05 mg, sodium acetate 1.4 mg, sodium chloride 7 mg, methylparahydroxybenzoate 1 mg and water for injections	–	–	–
Isophane medium *Disodium phosphate dihydrate 2.4 mg, glycerol 16 mg, metacresol 1.5 mg, phenol 0.65 mg and water for injections	–	–	–
Protamine medium *Protamine sulfate 0.35 mg, phenol 2 mg, glycerol 16 mg and water for injections	–	+ +	+
Water for injections	–	–	–

*Content of 1-ml solution of material tested.
†Test reading after displayed time.

Protaphane insulin HM NovoLet® and Novo Insulin Allergy Kit® (Novo Nordisk Pharma, Mainz, Germany) (human insulin, porcine insulin, paraben medium, phenol medium, metacresol medium, zinc medium, isophane medium, protamine medium, water for injections) showed neither immediate nor delayed-type reactions. However, intradermal test with Protaphane insulin HM NovoLet® showed an erythematous plaque with a diameter of 12 mm after 24 hr (Table 1). Intradermal test of the single ingredients of Protaphane insulin HM NovoLet® (Table 1) resulted in a similar positive reaction after 24 and 48 hr for protamine medium only.

It has been reported that serological investigation of insulin-specific IgE is not very helpful for the diagnosis and management of patients with insulin allergy as insulin-specific IgE antibodies develop in approximately half of insulin-treated patients (6, 7). Likewise, in our patient, IgE specific to human insulin was detectable, but without positive skin test reaction.

Non-specific immediate skin reactions to protamine at concentrations >0.3–10 μg/ml have been described (8), but immediate readings were negative in the case presented (Table 1). The clinical signs and the results of cutaneous and *in vitro* tests showed that delayed-type hypersensitivity to protamine caused the reaction in our patient, who now is successfully treated with Insuman Rapid® (Aventis Pharma, Bad Soden Am Taunus, Germany) without protamine. It is concluded that although allergic reactions to protamine in general are of immediate type (9), delayed-type cutaneous reactions may also complicate insulin therapy.

References

1. Blanco C, Castillo R, Quiralte J et al. Anaphylaxis to subcutaneous neutral protamine Hagedorn insulin with simultaneous sensitization to protamine and insulin. *Allergy* 1996: 51: 421–424.
2. Fernandez L, Duque S, Montalban C, Bartolome B. Allergy to human insulin. *Allergy* 2003: 58: 1317.
3. Porsche R, Brenner Z R. Allergy to protamine sulfate. *Heart Lung* 1999: 28: 418–428.
4. Shepherd G M. Hypersensitivity reactions to drugs: evaluation and management. *Mt Sinai J Med* 2003: 70: 113–125.
5. Bodtger U, Wittrup M. A rational clinical approach to suspected insulin allergy: status after five years and 22 cases. *Diabet Med* 2005: 22: 102–106.
6. Fineberg S E, Galloway J A, Fineberg N S, Rathbun M J, Hufferd S. Immunogenicity of recombinant DNA human insulin. *Diabetologia* 1983: 25: 465–469.
7. Grammer L C, Chen P Y, Patterson R. Evaluation and management of insulin allergy. *J Allergy Clin Immunol* 1983: 71: 250–254.
8. Lee A Y, Chey W Y, Choi J, Jeon J S. Insulin-induced drug eruptions and reliability of skin tests. *Acta Derm Venereol* 2002: 82: 114–117.
9. Bollinger M E, Hamilton R G, Wood R A. Protamine allergy as a complication of insulin hypersensitivity: a case report. *J Allergy Clin Immunol* 1999: 104: 462–465.

Address:
Ulrike Raap, MD
Department of Dermatology and Allergology
Hannover Medical University
Ricklingerstr. 5
30449 Hannover
Germany
Tel.: +49 511 9246 232
Fax: +49 511 9246 234
e-mail: mail@ulrike-raap.de

Phototoxic dermatitis due to *Chenopodium album* in a mother and son

Contact Dermatitis 2005: 53: 58–60

Ömer Çalka[1], Necmettin Akdeniz[1], Ahmet Metin[1] and Lütfi Behçet[2]

[1]Department of Dermatology, Yüzüncü Yil University Faculty of Medicine, Van, Turkey and [2]Department of Biology, Yüzüncü Yýl University Faculty of Science and Art, Van, Turkey

Chenopodium album L. subs. *album* (*Chenopodiaceae*) is an annual herb with fibrous roots. The plant grows worldwide and frequently in moist areas. Sometimes, the young parts of this plant can be cooked and eaten as a vegetable. In this article, we report a mother and her adult son, in whom phototoxic reaction developed on the sun-exposed body areas after eating this plant of *Chenopodiaceae* family because of rare presentation. We thought that this reaction was probably due to furocoumarins constituent within the plant.

Key words: *Chenopodium album*; phototoxic dermatitis; plant.

Chenopodium album L. subs. *album* (*Chenopodiaceae*) is an annual herb with fibrous roots. The plant grows worldwide and frequently in moist areas. Sometimes, the young parts of this plant can be cooked and eaten as a vegetable (1, 2). In this article, we report a mother and son, in whom phototoxic reaction developed on the sun-exposed body areas after eating this plant of *Chenopodiaceae* (CA) family because of rare presentation.

Case Report

Case 1

A 60-year-old woman was referred to our outpatient clinic with a 2-day history of swelling and redness on the face and the hands, which developed after eating meal consisting of cooked fresh plants. She also had the complaints of pain, mild pruritus and burning. The plants were picked by the family's neighbour and prepared by her son's wife. There was not a history of chronic disease, drug use and contact to irritant agent or insect bite. No causative agent except for the plant was detected. The family was engaged to farm and we learnt that all of the family members (the father, the mother, the son and his wife) exposed to the sun in outdoors after meal for at least 2 hr. Her complaints began 6–8 hr after meal, but the other members except her son had no any symptom. Previously, they ate this plant a few times, but no any symptom or sign was developed.

On physical examination, she had angioedema-like erythema and severe oedema on the face, the lips, the eyelids, the ears and the nose. She also had mild cyanosis and a few blisters on the hands and the wrists (Fig. 1a,b). The remainder physical examination findings were normal.

On laboratory investigation, she had glucosuria (2+), leucocytosis (16 700/mm^3) and hyperglycaemia (205 mg/dl). Repeated blood glucose levels were found to be high. Serum electrolytes, renal and liver function tests and blood gas analysis were within normal ranges. Magnetic resonance angiography of the hands was

Fig. 1. (a) Angioedema-like severe oedema and erythema on the face. (b) Cyanosis and blisters on the dorsa of the hands and the wrists.

also normal. Skin biopsy taken from face showed phototoxic dermatitis.

The plant was identified as *Chenopodium album* L. subs. *album* (CA) by the botanist (Fig. 2).

She was hospitalized. Aside from moist saline dressing to the face and the hands, the patient was administered oral loratadine (20 mg/day) and a dose of 40 mg intravenous methyl prednisolone. The dose of methyl prednisolone was not repeated because of hyperglycaemic status. On the 4th day of admission, skin lesions began to improve and fusidic acid ointment was added to the eroded lesions. Additionally, pentoxifylline and acetylsalicylic acid were initiated because of cyanosis on the hands. On the 8th day of admission, her oedema began to disappear and ulcerations and necrotic-crusting lesions developed on the areas of oedema; therefore, collagenase clostridiopeptidase-A ointment was prescribed. The necrotic lesions on the left hand were surgically treated. On the 4th week of admission, the lesions were mild crusted and hyperpigmented and she was discharged from the hospital in good health.

Case 2

A 41-year-old man, the adult son of case 1, was referred to our clinic with the similar complaints of her mother. Similarly, his symptoms also developed after eating meal consisting of cooked fresh plant.

On physical examination, he had erythema and moderate oedema on the face, the lips, the eyelids, the ears and the nose. The remainder physical examination findings were normal.

The laboratory investigations were unremarkable.

He was successfully treated with oral loratadine (10 mg/day) and topical mometasone furoate, which were administered for 10 days in outpatient clinic. After 2 weeks, the lesions improved with remaining mild hyperpigmentation.

Discussion

CA, known as wild spinach or silmask locally, grows in the Eastern Anatolia and is frequently consumed by people in our region. CA is an annual herb and has a usually erect, variously branched, yellowish to green stem (1). This subspecies is cosmopolitan, common in subtropical to temperate zone, more infrequent in the tropics and cooler region. It grows in either waste places or cultivated ground from the sea level to 3800-m altitude. The flowering time varies between 2 and 10 months. Plant includes nitrate, phosphate and oxalate salts, sugars, chlorophyll, oil, laxatives, iron salts, iodine, vitamins (B, C and D), betalain alkaloids, phenolic acids, betaine, oxalic acid, oleanolic acid, sitosterol, beta-carotene, saponin and furocoumarins (2–4). In our region, native people commonly cook and eat the plant as a food like spinach.

We think that angioedema-like clinical picture, a deep form of urticaria, in our cases might be due to the ingredients of the plant mentioned above. However, in fact, it is a probable phototoxic dermatitis, which was stimulated by furocoumarins as it was seen in the skin biopsy of the mother. Many plants, which have the same

Fig. 2. Chenopodium album L. subs. *album*.

ingredients, may cause such sunburn-like erythema, oedema, vesicle, blister formation and following hyperpigmentation when applied topically or administered systemically (5).

During follow-up of case 1, blood glucose level was not in normal range and she was diagnosed diabetes mellitus type 2. We thought that she had diabetes mellitus for a long time or silent diabetes mellitus might be manifested by the ingredients of CA (especially sugars) or stress factor of disease. Other studies on this issue should be required to clarify.

Although Lubieniecki (6) reported a case of photodermatitis following a contact with CA, our report on the cases who had phototoxic dermatitis after ingestion of CA is the first in the literature to the best of our knowledge. The reason why all of the family members were not affected may be due to individual histocompatibility or enzymatic differences between the members.

References

1. Davis P H. *Flora of Turkey and East Aegeans Islands*. Edinburgh: University Press, 1967: 300–305.
2. Baytop T. *Türkiye'de Bitkilerle Tedavi*. Istanbul: Istanbul University Pharmacology Faculty Press, 1984: 40.
3. Lavaud C, Voutquenne L, Bal P, Pouny I. Saponins from *Chenopodium album*. *Fitoterapia* 2000: 71: 338–340.
4. Yadav S K, Sehgal S. Effect of home processing and storage on ascorbic acid and beta-carotene content of Bathua (*Chenopodium album*) and fenugreek (*Trigonella foenum graecum*) leaves. *Plant Foods Hum Nutr* 1997: 50: 239–247.
5. Braun-Falco O, Plewing G, Wolff H H, Burgdorf W H C. Photodermatoses caused by exogenous sensitizers. In: *Dermatology*, Braun-Falco O, Plewing G, Wolf H H, Burgdorf W H C (eds), 2nd edn. New York: Springer Verlag, 2000: 554–560.
6. Lubieniecki S. A case of photodermatitis after a contact with *Chenopodium*. *Pol Tyg Lek* 1961: 16: 105–106.

Address:
Dr Ömer Çalka
Department of Dermatology
Yüzüncü Yil University Faculty of Medicine
65200 Van
Turkey
Tel.: +90 432 216 4706/1092
Fax: +90 432 216 7519
e-mail: omercal@hotmail.com

Contact sensitization in metalworkers

Contact Dermatitis 2005: 53: 60–62

Monica Corazza, Maria Michela Lauriola and Annarosa Virgili

Department of Clinical and Experimental Medicine, Section of Dermatology, University of Ferrara, Ferrara, Italy

Key words: contact dermatitis; hand eczema; metalworking fluids; occupational.

Occupational dermatitis of the hands affects 27–33% of metal-exposed workers (1). Despite automation, metalworking fluids (MWF) are the most important cause of hand contact dermatitis in the metal industry (1–5). Irritant contact dermatitis due to MWF seems to be more frequent than allergic contact dermatitis (6).

Cutting fluids are used for lubrication and cooling in metalworking operations. The fluids may be neat mineral oils or water-based (5); the latter, due to water vaporization during the working process, may become concentrated, the pH increases and some components become irritant (2). However, the extremely complex composition of water-based cutting fluids (emulsifiers, corrosion inhibitors, stabilizers, biocides, additives, antifoam agents, dyes and fragrances) exposes metalworkers to a great variety of potential sensitizers (5). Sensitization may occur to metal contaminants of the cutting fluids and non-occupational sources of exposure, such as cleaning detergents, solvents, degreasers, additives in barrier creams and after-work creams, rubber gloves (5, 7).

We performed patch tests to metalworkers in order to investigate the role of contact allergy.

Patients and Methods

42 metalworkers (39 men and 3 women; mean age: 33 years, range: 18–57) with hand eczema, strongly suspected to have been caused by cutting fluid, were investigated. The stop–restart test result was positive in 30 (71.4%) patients, doubtful in 1 (2.4%) and negative in 4 (9.5%); it was not performed in 7 (16.7%) cases. A personal history of atopy was present in 11 (26.2%) subjects.

29 (69%) metalworkers always used gloves, 3 (7.1%) sometimes and 10 (23.8%) never. Twenty (47.6%) subjects always used abrasive cleansing pastes at work, 1 (2.4%) sometimes and 21 (50%) never.

3 (7.1%) metalworkers had an acute eczema, 12 (28.6%) had a subacute form and 26 (61.9%) chronic. In 1 (2.4%) subject, with a history of recurrent hand eczema, the result of dermatological examination was negative at the moment of observation.

11 (26.2%) workers also showed involvement of other parts of the body: 6 (14.3%) upper limbs, 3 (7.1%) face, 2 (4.8%) feet, 1 (2.4%) pelvis, 1 (2.4%) arms, limbs and trunk.

Patch tests were performed with the Italian standard SIDAPA series, the antimicrobial preservative series, a 'cutting fluid series' (allergens commonly present in MWF: abietic acid, triethanolamine, bisphenol-A, resorcin, Zn-dithiocarbamate and benzoyl peroxide), and other possible allergens related to the patient's activity (rubbers and plastic materials, metals). Patient's own cutting fluids (neat oil and diluted to 10%) were tested in 32 patients. Patch test results have been summarized in Table 1.

Table 1. Patch test results

Substance	Positiveness
Standard Italian series	
Formaldehyde	1
Balsam of Perù	1
Cobalt chloride	3
Colophony	4
Nickel sulfate	3
Paraben mix	1
Potassium dichromate	3
Quaternium-15	2
Toluenesulfonamide–formaldehyde resin	1
Cocamidopropyl betaine	2
Thimerosal (merthiolate)	8
Antimicrobial preservative series	
Butyl-4-hydroxybenzoate	1
Ethyl-4-hydroxybenzoate	1
Methyl-4-hydroxybenzoate	1
Propyl-4-hydroxybenzoate	1
Phenylmercuric acetate	5
Hexahydro-1,3,5-*tris*(2-hydroxyethyl)triazine	1
Cutting fluid series	
Abietic acid	4
Benzoyl peroxide	2
Triethanolamine	2
Patient's own cutting fluids (32 patients)	
Neat oil as is	7
Diluted oil 10% aq	4
Other suspected allergens	
Leather glove pieces	1

Discussion

Cutting fluid dermatitis is usually irritant; however, we found a high percentage of sensitization (47.6%, 20 subjects), similar to the percentage (50%) observed by other authors (5).

Thimerosal was the most frequent positive allergen found in our series (8 positive reactions, 19%). Thimerosal is a potential additive in metalworking fluids; however, technical data sheets of cutting oils never reported the presence of this biocide. The relevance of positive reactions to thimerosal was, therefore, doubtful.

Colophony and its principal constituent, abietic acid, have been confirmed to be relevant occupational allergens in MWF allergic contact dermatitis; 4 (9.5%) patients presented a positive reaction to both these allergens. Colophony may be present in tall oil, as an emulsifier in MWF and in soap water sometimes used as a coolant (5, 6).

3 (7.1%) metalworkers had a positive patch test to nickel sulfate and 3 (7.1%) to cobalt chloride. Because contact with nickel salts is ubiquitous, sensitization may occur both at work from metal dissolved in cutting fluids and at home (1, 5, 6). 3 (7.1%) patients showed a positive reaction to potassium dichromate, a corrosion inhibitor that is also present in industrial oils and in cooling fluids.

Biocides are usually mentioned as allergens; among them, there are for maldehyde and formaldehyde releasers, such as quaternium-15. In our study, 2 patients had a positive patch test to quaternium-15 and 1 to formaldehyde. These biocides are commonly used in soluble oils; however, sensitization could derive from extraprofessional sources, such as cosmetics and paints (6).

Fragrances and balsam of Perù are used in MWF in order to cover up their unpleasant odour (6). We found a positive reaction to balsam of Perù in only 1 subject.

29 patients (69%) reported using rubber gloves, but patch test results with rubber allergens were always negative. 1 patient was positive to potassium dichromate as well as to a piece of his leather gloves tested as is.

Because our study confirms a high percentage of sensitization (47.6%) in patients affected with occupational hand dermatitis, we underline the utility of performing patch tests not only with the standard series but also with the patient's cutting oil, in accordance with data published recently by Geier et al. (8). In fact, in our study, a positive reaction to the oil, tested as is, was found in 7 (21.8%) metalworkers and to the oil diluted to 10% in 4 (12.5%).

No correlation was found between the pattern of dermatitis and the final diagnosis, even though it is commonly thought that irritant dermatitis involves the backs and web spaces of the hands, whereas allergic dermatitis affects the palmar skin (1). This led us to suggest that concomitant exposure to irritants and sensitizers induces 'overlapping' manifestations.

Attention should be paid to factors of excessive skin hygiene, which may worsen occupational dermatitis (7). A high percentage of our patients (47.6%) used abrasive pastes, whereas another 14.3% used cleaning detergents (liquid soaps, degreasers, solvents, etc.).

It is concluded that correct information about skin care and professional risk factors could decrease the incidence of contact dermatitis in metalworkers.

References

1. Koch P. Occupational contact dermatitis: recognition and management. *Am J Clin Dermatol* 2001: 2: 353–365.
2. Wigger-Alberti W, Hinnen U, Elsner P. Predictive testing of metalworking fluids: a comparison of 2 cumulative human irritation models and correlation with epidemiological data. *Contact Dermatitis* 1997: 36: 14–20.
3. Alomar A. Occupational skin disease from cutting fluids. *Dermatol Clin* 1994: 12: 537–546.
4. Goh C L, Gan S L. The incidence of cutting fluid dermatitis among metalworkers in a metalfabrication factory: a prospective study. *Contact Dermatitis* 1994: 31: 111–115.
5. Grattan C E H, English J S C, Foulds I S, Rycroft R J G. Cutting fluid dermatitis. *Contact Dermatitis* 1989: 20: 372–376.
6. De Boer E M, van Ketel W G, Bruynzeel D P. Dermatoses in metal workers (II). Allergic contact dermatitis. *Contact Dermatitis* 1989: 20: 280–286.
7. Berndt U, Hinnen U, Iliev D, Elsner P. Hand eczema in metalworker trainees – an analysis of risk factors. *Contact Dermatitis* 2000: 43: 327–332.
8. Geier J, Wolfgang U, Lessmann H, Frosch P J. Patch testing with metalworking fluids from the patient's workplace. *Contact Dermatitis* 2004: 51: 172–179.

Address:
Monica Corazza
Section of Dermatology
University of Ferrara
Via Savonarola 9
44100 Ferrara
Italy
Tel.: +39 0532 0532 205825
Fax: +39 0532 206791
e-mail: czm@unife.it

Allergic contact dermatitis caused by 6α-methylprednisolone aceponate

Contact Dermatitis 2005: 53: 62–63

Leticia Calzado, Francisco Javier Ortiz-Frutos, Carmen Galera, Prado Sánchez-Caminero and Francisco Vanaclocha

Dermatology Department, H.U. 12 de Octubre, Avda. de Córdoba s/n, 28041 Madrid, Spain

Key words: 6α-methylprednisolone aceponate; allergic contact dermatitis; budesonide; corticosteroids; cross-reaction; medicaments.

A possible sentitization to corticosteroids must be considered when they failed to improve a chronic dermatitis. Although it is a worldwide use, there are a few reports about allergic contact dermatitis due to 6α-methylprednisolone aceponate (MPA) (1–6). Here, we describe 2 new cases.

Case Reports

The first case is a 27-year-old man, allergic to several antibiotics (penicillin, cephalosporins, streptomycin) and pollen, with no previous dermatitis, who developed a disseminated eczema from a chronic dermatitis located on the dorsal aspect of his left foot. The latter had been treated with Adventan cream® (MPA, Schering España S.A., Madrid, Spain) over the last 4 months, as well as with several emollients. He presented with erythematous and scaly papules and plaques involving the trunk, arms and limbs, associated with a violaceous, dry, clearly outlined plaque on his left foot. He was treated with topical (mometasone furoate) and systemic (prednisone) corticosteroids, with complete resolution of the eczematous lesions. Laboratory findings showed a increased IgE value (388 UI/ml).

Patch tests were performed with the Spanish (G.E.I.D.C.) standard series, a cosmetic series, a corticosteroid series (Chemotechnique® Malmo, Sweden, and MPA 1% in petrolatum, kindly supplied by the laboratory) as well as with the products used, including Adventan cream®. Patch tests were applied on the upper part of the patient's back during 2 days and were read on days 3 and 7. Patch tests revealed positive reactions to budesonide (++D3, ++D7), alclometasone dipropionate (±D3, ++D7), MPA (++D3, ++D7) and fluocortolone monohidrate (++D3, ++D7). Adventan cream® produced a clear positive reaction (++D3, ++D7). A later patch test with methylprednisolone was negative.

The second case was a 43-year-old woman, also allergic to antibiotics (penicillin, cephalosporins and streptomycin), with hayfever and previously diagnosed with atopic dermatitis, allergic contact dermatitis to hair dyes and concomitant sensitization to nickel salts, thiomersal and 4-cloro-3-cresol. She presented with a chronic dermatitis on her hands and forearms, consisting of vesicles, erythematous and scaly papules and also fissures, over the last 10 months. She had been treated with prednisone and Clovate® (clobetasol), Claral® (difluocortolone valerate) and Menaderm® (beclometasone dipropionate) creams with uncomplete improvement of the lesions and with Adventan® cream, during 20 days, with worsening of her dermatitis. Patch tests with the Spanish standard series and corticosteroids series were performed and, after reading on days 3 and 7, positive reactions were observed to hidrocortisone butyrate (–D3, ++D7) and MPA (–D3, +D7). The patient has continued suffering from repeated rashes of vesicles and dyshidrotic eczema on her hands and feet.

Discussion

Patch tests positivities to corticosteroids, in spite of being drugs extensively used, are rarely found; budesonide and tixocortol pivalate are responsible for the majority of them (7). MPA is a non-halogenated diester of 6α-methylprednisolone: these ester groups increase the lipophilicity of the molecule in the skin, while a local fast inactivation explains its low systemic activity (2). MPA belongs to D2 group of the Coopman et al. (8) classification, based on different sustitutions on the D-ring or in the C20-C21 position of the side chain of the steroid molecule, which tries to explain cross-reactivity among corticosteroids.

There are only 6 case reports described of sensitization to MPA (1–6). Previous exposure to it and a present relevance were found in 5 of them (1, 2 3, 5, 6). 3 of the cases reported were interpreted as cross-reactions, delete positivities (1, 4, 5), as, except for the last case, there were concomitant and/or cross sensitization to other corticosteroids (6). Cross-reaction patterns were especially with other members of group D2 and budesonide, as it had been well established before (9).

Both of our cases presented with a chronic dermatitis resistant to corticosteroid therapy, which lead to suspect allergic contact dermatitis. Patch tests showed sensitization to MPA and the steroid cream employed, as well as positivities to other corticosteroids from

groups D2, B (budesonide) and/or C. These were considered as concomitant and/or cross-reactions, frequently described when patch tests with corticosteroids series are performed.

Acknowledgements

We thank Dr A. Varela-Cabo and Dr P. Carmona-García, from Department of Anaesthesia and Intensive Care (Gregorio Marañón General Hospital, Madrid) for their interest in these cases.

References

1. Balato N, Patruno C, Lembo G, Cuccurullo F M, Ayala F. Contact sensitization to 6-α methylprednisolone aceponate. *Am J Contact Dermat* 1997: 8: 24–25.
2. Corazza M, Virgili A. Allergic contact dermatitis from 6α-methylprednisolone aceponate and budesonide. *Contact Dermatitis* 1998: 38: 356–357.
3. Corazza M, Mantovani L, Maranini C, Bacilieri S, Virgili A. Contact sensitization to corticosteroids: increased risk in long-term dermatoses. *Eur J Dermatol* 2000: 10: 533–535.
4. Chow E T. Multiple corticosteroid allergies. *Australas J Dermatol* 2001: 42: 62–63.
5. Seok Oh C, Young Lee J. Contact allergy to various ingredients of topical medicaments. *Contact Dermatitis* 2003: 49: 49–50.
6. Cahill J, Nixon R. Allergic contact dermatitis to methylprednisolone aceponate in a topical corticosteroid. *Australas J Dermatol* 2004: 45: 192–193.
7. Dooms-Goossens A, Andersen K E, Brandao F M et al. Corticosteroid contact allergy: an EECDRG multicentre study. *Contact Dermatitis*, 1996: 35: 40–44.
8. Coopman S, Degreef H, Dooms-Goossens A. Identification of cross-reaction patterns in allergic contact dermatitis from topical corticosteroid. *Br J Dermatol* 1989: 121: 27–34.
9. Lepoittevin J-P, Drieghe J, Dooms-Goossens A. Studies in patients with corticosteroid contact allergy. *Arch Dermatol* 1995: 131: 31–37.

Address:
Leticia Calzado
Dermatology Department
Hospital 12 de Octubre
Avda. de Córdoba s/n
28041 Madrid
Spain
Tel: 34 91 3908302
Fax: 34 91 3908302
e-mail: leti_cv@yahoo.es

A series of four cases of allergic contact dermatitis to phthalic anhydride/trimellitic anhydride/glycols copolymer in nail varnish

Contact Dermatitis 2005: 53: 63–64

J. E. Gach, N. M. Stone* and T. M. Finch

Department of Dermatology, Birmingham Heartlands and Solihull Hospitals, Solihull, West Midlands, UK

Key words: allergic contact dermatitis; nail varnish; phthalic anhydride/trimellitic anhydride/glycols copolymer.

Phthalic anhydride is a low-molecular-weight compound with a wide variety of industrial uses. It is an allergen that causes contact dermatitis and urticaria, but if its fumes are inhaled it can also cause hypersensitivity pneumonitis. A few years ago, it was introduced into some formulations of nail polishes as an alternative to toluenesulfonamide formaldehyde resin.

Case Report

Case no. 1

A 21-year-old woman had a 12-month history of periorbital and fingertip eczema. She was patch-tested to the British Contact Dermatitis Society Standard Battery (BCDSB), cosmetic and medicament series (local series supplied by Chemotechnique and Trolab) (Chemotechnique, Crawford Pharmaceuticals, Milton Keynes, UK and Trolab, Bio-Diagnostics Ltd, Upton Upon Severn, UK) as well as her own cosmetics and at day 4 had a positive reaction (+) to her nail varnish (Boots No.7 Colour Lock Nail enamel) (as is). The nail varnish was applied to a Finn Chamber and allowed to dry before application. This method was used in all four cases. Subsequent patch testing to the ingredients of the nail varnish, which were sourced from the manufacturer, showed a positive reaction (+) at day 4 to phthalic anhydride/trimellitic anhydride/glycols copolymer (PA) (1% pet.). All readings were performed according to the ICDRG criteria.

Case no. 2

A 22-year-old woman had a 6-month history of perioral eczema and dry, fissured lips. She was patch-tested to the BCDSB, cosmetic and dental series (local series supplied by Chemotechnique and Trolab) as well as her own cosmetics and toiletries and at day 4 had a positive reaction (+) to her nail varnish (Boots No.7 Colour Lock Nail enamel) (as is). Subsequent patch testing to the ingredients of the nail varnish showed a positive reaction (+) at day 4 to PA (1% pet.). Her rash resolved with avoidance of the product and the short-term use of a mild topical steroid.

Case no. 3

A 33-year-old woman suffered from intermittent eczema of her face and fingers for 6 months. She was patch-tested to the BCDSB and cosmetic series (Chemotechnique) and her own cosmetics, and at day 2 and day 4 developed positive reactions (+) to her nail varnish (M&S enhance nail polish (clear)) (as is). Further testing to the ingredients of the nail varnish provided by the manufacturer showed a positive reaction (+) at day 4 to PA (1% in butyl acetate).

Case no. 4

A 55-year-old nurse suffered from periungual dermatitis affecting all her fingers. She had been wearing nail varnish and acrylic nails for several years. Patch testing to the BCDSB and acrylic series (Chemotechnique) showed positive reactions at day 2 and day 4 to several members of the acrylate series (++) in addition to toluenesulfonamide formaldehyde resin (+) and PA (1% in butyl acetate). Avoiding acrylic nails and all nail polish has led to the complete resolution of her symptoms.

Discussion

Phthalic anhydride/trimellitic anhydride/glycols copolymer is a copolymer of phthalic anhydride, trimellitic anhydride, ethylene glycol and neopentyl

*Present address: Department of Dermatology, Royal Gwent Hospital, Cardiff Road, Newport, South Wales, NP20 2UB, UK

glycol monomers. This synthetic polymer is a non-aqueous agent, which increases viscosity and is responsible for forming a film when used in nail polish and enamel (1). It is also used in the manufacture of dyes, pharmaceuticals, insecticides and as a hardener for resins. Allergic contact dermatitis to PA in nail varnish was first described by Moffit and Sansom in 2002 (2). Recently, 3 further cases of allergic contact dermatitis to PA in nail varnish occurring in France were presented as a poster at the European Society of Contact Dermatitis meeting (3). With this largest reported series of cases, we would, therefore, like to remind colleagues of the importance of this newly emerging allergen.

Acknowledgement

We thank Boots and M & S for supplying ingredients of their nail varnishes for patch testing and Mr Stephen Kirk for his helpful comments.

References

1. Gottschalck T E, McEwen G N. *International Cosmetic Ingredient Dictionary and Handbook*, 10th edition, Washington. The Cosmetic, Toiletry, and Fragrance Association, 2004.
2. Moffit D L, Sansom J E. Allergic contact dermatitis from phthalic anhydride/trimellitic anhydride/glycols copolymer in nail varnish. *Contact Dermatitis* 2002: 46: 236.
3. Le Coz C J, Nassif A, Collet E. Allergy to phthalic anhydride/trimellitic anhydride/glycols copolymer in nail varnishes. *Contact Dermatitis* 2004: 50: 169. [abstract FC04.3]

Address:
Dr J. E. Gach
Department of Dermatology
Birmingham Heartlands and Solihull Hospitals
Lode Lane
Solihull
West Midlands B91 2JL
UK
Tel.: +44 121 424 4540
Fax: +44 121 424 5052
e-mail: asia@jgach.freeserve.co.uk