Heparin-induced skin lesions

*Marc Schindewolf, Edelgard Lindhoff-Last, Ralf J Ludwig, Wolf-Henning Boehncke**

Heparins are widely used for prophylaxis and treatment of thromboembolic diseases. Besides bleeding complications, heparin-induced skin lesions are the most frequent unwanted adverse effects of subcutaneous heparin treatment. Evidence suggests that these lesions are more common than previously thought. Lesions are most frequently due to either allergic reactions or to possibly life-threatening heparin-induced thrombocytopenia. Early recognition and adequate treatment are highly important, because although both complications initially show a similar clinical picture, their treatment should be fundamentally different. Furthermore, risk factors associated with the patient, drug, and treatment regimen have been identified. We review the clinical range of heparin-induced skin lesions, emphasise evidence and controversies in epidemiology, diagnosis, and differential diagnosis, and discuss the management of patients with these skin lesions.

Published Online
May 28, 2012
DOI:10.1016/S0140-6736(12)60409-7

*All authors contributed equally to this work

Division of Vascular Medicine and Haemostaseology, Department of Internal Medicine (M Schindewolf MD, Prof E Lindhoff-Last MD) **and Department of Dermatology** (Prof W H Boehncke MD), **Hospital of the Johann Wolfgang Goethe University, Frankfurt am Main, Germany; and Department of Dermatology, University of Lübeck, Lübeck, Germany** (Prof R J Ludwig MD)

Correspondence to:
Prof Ralf Ludwig,
Department of Dermatology,
University of Lübeck,
D-23562 Lübeck, Germany
ralf.ludwig@uksh.de

Introduction

For decades, heparin has been used successfully for the prophylaxis and treatment of thromboembolic diseases; it remains one of the most prescribed drugs worldwide.[1] However, use of unfractionated heparin is hampered by its inactivity against thrombin bound to fibrin, factor Xa bound to platelets, non-specific binding reactions,[2] and its fairly short half-life.[1,2] Consequently, the discovery that the anti-factor Xa and anti-thrombin activities of heparin were separable led to the development of low molecular-weight heparins, which have a more predictable anticoagulant response than unfractionated heparin. Furthermore, the ultra-low molecular-weight (1·728 kDa) pentasaccharide fondaparinux—a selective inhibitor of factor Xa—has been synthesised and approved for clinical use.[3] The antithrombin binding site of this inhibitor resembles the natural pentasaccharide sequence of heparins.[4]

Heparins are composed of a complex mixture of polysaccharide chains of different lengths and molecular weights (unfractionated heparin 3–30 kDa, low molecular-weight heparin 2–9 kDa). Low molecular-weight heparins are derived from unfractionated heparin by chemical or enzymatic depolymerisation. Up to 30% of these polysaccharide chains contain a pentasaccharide sequence that binds to the serine protease inhibitor antithrombin, which indirectly accelerates the inactivation of the coagulation factors thrombin (IIa), Xa, IXa, XIa, and XIIa.[3] Some of the most frequent unwanted adverse effects of subcutaneous heparin treatment are haemorrhagic complications, heparin-induced thrombocytopenia, osteoporosis, alopecia, benign elevation of serum transaminases, and skin reactions.[3]

For cutaneous reactions, evidence suggests that heparin-induced skin lesions are more common than previously thought. These lesions are most often due to allergic reactions, perhaps because of interactions with other molecules that might induce sensitisation. However, inhibition of factor Xa is specific and catalysed by heparin molecules of any length containing the pentasaccharide sequence; polysaccharide chains with an essential length of at least 18 saccharides bind to thrombin less specifically.[4] Therefore, a range of non-specific binding reactions of the variable, negatively-charged chains with other molecules are conceivable.[2] The natural origin of heparins from porcine gut or from processing of bovine lung might further contribute to sensitisation. Irrespective, the antigenic epitope has not yet been identified. Overlap in the polysaccharide composition of different low molecular-weight and unfractionated heparins might explain the high degree of cross-allergenicity among the different heparins.[5,6]

In addition to allergic cutaneous reactions, the most important differential diagnosis of heparin-induced skin lesions is life-threatening immune heparin-induced thrombocytopenia.[5] Thus, early recognition and adequate treatment are of great importance because the treatment of both complications should be fundamentally different. Furthermore, risk factors for lesions associated with the patient, drug, and treatment regimen have been identified.

We review the clinical range of heparin-induced skin lesions and emphasise evidence and controversies in epidemiology, diagnosis, differential diagnosis, and management of patients with these lesions.

Search strategy and selection criteria

We searched PubMed from January, 1952, to February, 2011, for relevant publications with the search terms "heparin", "skin", "allergy", "hypersensitivity", and "heparin-induced thrombocytopenia". We reviewed reference lists of publications identified by this search strategy (appendix). We included publications not written in English and case reports if they were of a seminal character, if we could not find larger studies of the topic, or if they provided important information for disease management. We excluded publications either on the basis of title and abstract, or after reading the whole publication.

See Online for appendix

Incidence in different patient populations

Cutaneous unwanted adverse events induced by heparins have long been considered infrequent with an estimated incidence of 0·2%.[7] Data are available from three reviews, several prospective studies, and one retrospective study assessing general unwanted adverse

events of long-term treatment with low molecular-weight heparins during pregnancy (table 1).[8–15] Investigators observed allergic skin reactions in three (<1%) of 486 pregnant women treated with enoxaparin, dalteparin, nadroparin, tinzaparin, or reviparin.[8] Another group of investigators independently confirmed these findings, reporting local or generalised skin reactions in 18 (3%) of 728 pregnant patients treated with low molecular-weight heparins, mainly dalteparin (47%), enoxaparin (26%), or certoparin (15%).[9] The third review noted an intermediate incidence of 1·8% of heparin-induced skin lesions.[10] However, data for these studies were obtained retrospectively and the mode of skin assessment was not reported. In line with the three reviews, the prospective LIVE-ENOX study,[12] which was designed for the outcome of pregnant women with thrombophilic disorders during treatment with enoxaparin, reported allergic skin reactions in up to 3% of patients; however, the mode of assessment was not specified. Nevertheless, with growing use of heparins, reports of heparin-induced skin lesions have increased;[5,18] therefore, their incidence might have previously been under-reported and underestimated. Although these reports imply that the risk of lesion development seems to differ among patient populations, prospective data have been rare or have had different primary outcome measures.

A prospective clinical trial of the improvement of live-birth rate with aspirin and nadroparin treatment in women with unexplained recurrent miscarriage reported "swelling or itching" at the nadroparin injection sites in 49 (40%) of 123 patients.[13] A prospective trial[14] in pregnant women reported an incidence of 29% of "itching, local redness, or subcutaneous infiltrates" at injection sites, whereas a retrospective investigation[11] in pregnant women reported an incidence of 29·7% of "haematoma, cyst, and pain" at injection sites. In these trials, no further

	Study type	Period	Cohort	Preparation	Incidence	Causes	Assessment of skin lesions	Primary outcome measure
Incidence and causes of heparin-induced skin lesions in pregnant patients								
Sanson et al,[8] 1999	Review	NS–1997	Pregnant	LMWH (dalteparin, enoxaparin, nadroparin, reviparin, tinzaparin)	3/486 (<1%)	Allergic skin reactions	Not reported	Safety of LMWHs
Ensom et al,[9] 1999	Review	1966–99	Pregnant	LMWH (certoparin, dalteparin, enoxaparin, nadroparin, NS)	18/728 (3%)	Local or generalised skin reactions	Not reported	Efficacy and safety of LMWHs
Greer et al,[10] 2005	Review	NS–2003	Pregnant	LMWH (certoparin, dalteparin, enoxaparin, nadroparin, reviparin, tinzaparin, NS)	50/2777 (2%)	Allergic skin reactions	No assessment or not reported	Efficacy and safety of LMWHs
Deruelle et al,[11] 2006	Retrospective	1997–2001	Pregnant	LMWH (dalteparin, enoxaparin, nadroparin, tinzaparin)	33/111 (30%)	Local cutaneous reactions	No assessment	Efficacy and safety of LMWHs
Brenner et al,[12] 2005	Randomised trial	2000–02	Pregnant and postpartal	LMWH (enoxaparin)	5/166 (3%)	Allergic skin reactions	No assessment	Efficacy and safety of enoxaparin in women with thrombophilia and recurrent pregnancy loss
Kaandorp et al,[13] 2010	Randomised trial	2004–08	Pregnant	LMWH (nadroparin)	49/123 (40%)	Swelling or itching at injection site; possibly DTH	No assessment	Live-birth rate in women with recurrent miscarriage who were treated with aspirin plus heparin, or with aspirin alone or placebo
Bank et al,[14] 2003	Prospective observational study	NS–2002	Pregnant and postpartal	LMWH (dalteparin, enoxaparin, nadroparin, tinzaparin, danaparoid)	19/66 (29%)	Local redness, subcutaneous infiltrates, itching; most likely DTH	No assessment	Efficacy and safety of LMWHs
Schindewolf et al,[15] 2010	Prospective observational study	2009–10	Pregnant and postpartal	LMWH (dalteparin, enoxaparin, nadroparin, tinzaparin, UFH)	22/111 (20%)	DTH	Clinical follow-up, histology, subcutaneous provocation	Incidence and causes of skin lesions
Incidence and causes of heparin-induced skin lesions in medical patients								
Schindewolf et al,[16] 2009	Prospective observational study	2007–08	Medical	LMWH (certoparin, dalteparin, enoxaparin, nadroparin, tinzaparin, UFH)	24/320 (8%)	DTH	Clinical follow-up, histology, subcutaneous provocation	Incidence and causes of skin lesions
Incidence and causes of pentasaccharide-induced skin lesions in medical or surgical patients								
Schindewolf et al,[17] 2010	Prospective observational study	2008–09	Medical or surgical	Fondaparinux	1/231 (<1%)	DTH	Clinical follow-up, histology, subcutaneous provocation	Incidence and causes of skin lesions

NS=not specified. LMWH=low molecular-weight heparin. DTH=delayed-type hypersensitivity. UFH=unfractionated heparin.

Table 1: **Incidence and causes of heparin-induced and fondaparinux-induced skin lesions in different patient populations**

www.thelancet.com Published online May 28, 2012 DOI:10.1016/S0140-6736(12)60409-7

assessments were done to discriminate between possible differential diagnoses of lesions. Again, the mode of skin assessment was not specified.

Only two studies have prospectively investigated the incidence and causes of heparin-induced skin lesions. One[15] noted an incidence of skin reactions in almost 20% of the population of pregnant women. Further investigations identified allergic delayed-type hypersensitivity as the sole underlying cause of all reactions. Because nadroparin was the only[13] or the main[14,15] anticoagulant used, an elevated allergenic potential for this drug cannot be inferred. Another prospective epidemiological investigation[16] assessed the incidence and causes of heparin-induced skin reactions in medical patients (table 1). Skin reactions were noted in 24 of 320 patients given low molecular-weight heparin (mostly enoxaparin [60%] or nadroparin [31%]) for 7 days or more, amounting to an incidence of 7·5%, with female sex being a greater risk factor for hypersensitivity responses than male sex (10·3% *vs* 4·1%).[16] On the basis of these findings, heparin-induced skin lesions should be regarded as a common adverse event of subcutaneous heparin treatment.

Pathogenesis

Various underlying diseases can lead to heparin-induced skin lesions. Lymphocyte-mediated delayed-type hypersensitivity reactions (so-called type IV allergic reactions) are the most common cause,[5,16,19] but lesions can too be the only clinical presentation of heparin-induced thrombocytopenia.[20–23] Lesions caused by a delayed-type hypersensitivity reaction or by heparin-induced thrombocytopenia show an initially similar clinical picture that typically shows erythemas mostly located at the injection sites; thus, they are difficult to distinguish. Quick and correct diagnosis is mandatory because heparin-induced thrombocytopenia requires conversion to an alternative non-heparin anticoagulant to prevent potentially fatal thromboembolic events.[24] Therefore, the presence of lesions in patients given heparin is considered in a clinical scoring system to identify pretest probability of heparin-induced thrombocytopenia.[25,26]

Cutaneous delayed-type hypersensitivity response to heparin

Cutaneous delayed-type hypersensitivity reactions are a common cause of heparin-induced skin lesions. This finding has been shown in retrospective and prospective investigations in which lesions were caused only by a delayed-type hypersensitivity reaction in more than 220 patients.[8–16] These data have been confirmed in 87 patients with heparin-induced skin lesions in whom the sole cause of skin lesions was a delayed-type hypersensitivity response diagnosed by skin biopsy or provocation.[19] Although mostly these reactions first present with an erythema at the sites of heparin injection, the clinical range can vary from mild erythemas to infiltrated, sometimes scaling, blistering, or papulovesicular erythematous plaques, or to generalised eczemas or maculopapular exanthemas (figure 1).[16,27–29] Generalisation occurs in about 3–10% of patients.[14,16,27] Such a response to heparin is usually associated with itching, and lesions usually develop within the first 2 weeks of heparin treatment. However, late-onset responses occurring several weeks to sometimes months after start of anticoagulant treatment have been reported.[6,30,31] On the basis of our observations, the clinical presentation of an individual lesion can vary dependent on the stage of a developing lesion; furthermore, some patients have reported itching with no visible skin manifestation.

Histologically, delayed-type hypersensitivity reactions are characterised by a mostly perivascular mononuclear cell

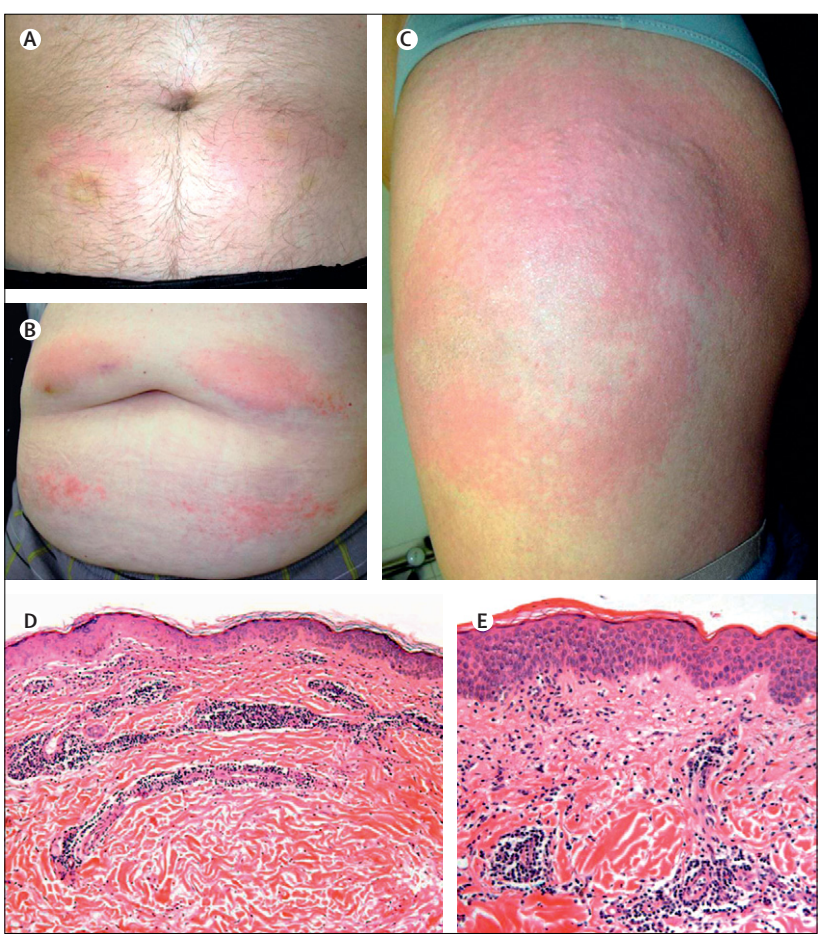

Figure 1: **Clinical and histological features of heparin-induced delayed-type hypersensitivity reactions**
In most cases, skin lesions are confined to the sites of heparin injection; however, generalisation can occur in 3–10% of cases. (A) Localised, itching erythematous maculae on the abdomen at the nadroparin injection sites. (B) Generalised, itching red plaques on the abdomen at the enoxaparin injection sites. (C) Burning, widespread, blistering red plaque with surrounding papules at the enoxaparin injection site on the thigh, and secondary exanthematous generalisation. (D, E) Skin biopsy specimens of two patients with delayed-type hypersensitivity reactions to nadroparin (D) and to enoxaparin (E) show a characteristic, mainly perivascular dermal infiltration, mainly with lymphocytes and to a low degree with eosinophils. No microthromboses in dermal vessels, which would be suggestive of heparin-induced thrombocytopenia, were detected. E reproduced from Schindewolf and colleagues,[32] by permission of Mayo Foundation for Medical Education and Research.

infiltration of CD3 cells that mostly belong to the CD4 T-helper cell subpopulation. Oedema in the intercellular space between keratinocytes (so-called spongiosis) and in the dermis, accompanied by infiltrating neutrophils and eosinophils, are additional variable features of these reactions (figure 1).[6]

Cutaneous effects of heparin-induced thrombocytopenia

Heparin-induced thrombocytopenia is a rare complication of treatment with unfractionated or low molecular-weight heparins, which form a complex with the platelet-derived positively charged tetrameric CXC chemokine ligand 4, also known as platelet factor 4. This leads to conformational changes with the appearance of antigenic neoepitopes that trigger the formation of IgG antibodies to the heparin-platelet factor 4 complex.[32] Subsequent binding of the ternary complexes of antibody-heparin-platelet factor 4 with FcγRIIa receptors on platelets causes further activation of platelets and coagulation. The incidence of heparin-induced thrombocytopenia is ten times higher with unfractionated heparin than with low molecular-weight heparin and is dependent on the patient population, with patients who have undergone surgery bearing a higher risk than medical patients, and medical patients bearing a higher risk than obstetrical patients. This incidence ranges from less than 0·1% to 5%. The mortality rate is 20–30%.[24,33]

Clinical sequelae

Thrombocytopenia occurs in at least 85–90% of patients with heparin-induced thrombocytopenia and manifests as a decrease in platelet count of at least 50% in more than 90% of patients.[24,33] Characteristically, heparin-induced thrombocytopenia occurs between 5 and 14 days after start of heparin treatment, or in 24 h in patients with preformed antibodies.[24] Furthermore, delayed-onset heparin-induced thrombocytopenia occurring up to 3 weeks after discontinuation of treatment has been described in 5% of patients; therefore, this disorder remains a differential diagnosis even after the typical timepoint for onset has elapsed.[34]

Venous or arterial thromboembolism can develop at almost any vascular region (in a 4:1 ratio) with an absolute thrombosis risk of 35–75%. Even after cessation of heparin treatment alone, new thromboses develop in more than 50% of patients.[33,35] Acute systemic (anaphylactoid) reactions—eg, fever and chills, tachycardia, hypertension, dyspnoea, and cardiopulmonary arrest—typically occur in 30 min of receipt of intravenous heparin in about 5% of patients with heparin-induced thrombocytopenia.[36] Skin lesions occur in 10–20% of patients with heparin-induced thrombocytopenia.[33] These lesions are due to intradermal microvascular thromboses; however, similar to a delayed-type hypersensitivity reaction, they begin as erythematous lesions and can then become cutaneous necroses that generally have a central black eschar surrounded by an indurated erythema (figure 2). These painful lesions can also develop at a distance from the heparin injection sites, even in the absence of thrombocytopenia.[20,33] An appearance resembling livedo reticularis has been described in some cases.[33] Besides platelets, only microvascular endothelial cells of the superficial (but not the deep) dermal vascular plexus bear FcγRIIa receptors, which might explain why mainly the microvasculature of the skin is affected.[38]

Although findings from previous studies have indicated an association of skin lesions, which were mainly caused by use of unfractionated heparin, and heparin-induced thrombocytopenia in a minimum of 22% of patients,[22,23] a more recent study suggests that non-necrotising heparin-induced skin lesions caused by low molecular-weight heparins are not, or only weakly, associated with either heparin-induced thrombocytopenia or anti-heparin-platelet factor 4 IgG antibody formation.[19] In this study, only one of 87 patients with heparin-induced skin lesions had heparin-induced thrombocytopenia. Nevertheless, with no histological detection of dermal microvascular thromboses suggestive of heparin-induced thrombocytopenia, these lesions could be clearly classified as a delayed-type hypersensitivity reaction in this patient. The discrepancy between these studies in numbers of skin lesions associated with heparin-induced thrombocytopenia might be due to differences in patient recruitment, or to a higher use of unfractionated heparin in the two previous studies,[22,23] and thus a higher rate of seroconversion in the early to mid-1990s when these

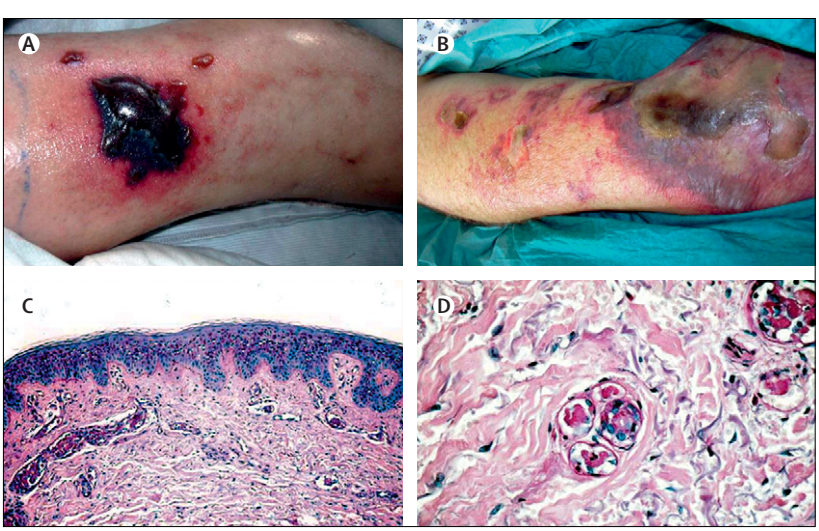

Figure 2: **Clinical and histological presentation of patients with cutaneous necroses due to heparin-induced thrombocytopenia**

(A) Black, necrotic eschar surrounded by an indurated erythema on the right calf. (B) Extended necrotic skin lesion on the left arm, reproduced from Schindewolf and colleagues,[17] by permission of Mayo Foundation for Medical Education and Research. (C, D) Microthromboses in dermal vessels (periodic acid Schiff staining). Reproduced from Peitsch and colleagues,[37] by permission of Springer.

www.thelancet.com Published online May 28, 2012 DOI:10.1016/S0140-6736(12)60409-7

studies were done.[19] However, these findings have led to a refinement of clinically well-established pretest probability scores for heparin-induced thrombocytopenia,[25] such that heparin-induced, erythematous, non-necrotising skin lesions are weighted less strongly than previously, at least when they occur during treatment with low molecular-weight heparins, which assures them a low pretest probability for the presence of heparin-induced thrombocytopenia.[26] Skin necrosis, which is much more indicative of heparin-induced thrombocytopenia than are non-necrotising skin lesions, is unaffected by this refinement and would count for a high pretest probability for heparin-induced thrombocytopenia.[19,26]

Unlike antibody-mediated immune heparin-induced thrombocytopenia, a non-antibody-mediated non-immune heparin-induced thrombocytopenia (type 1), presumably caused by effects of direct platelet-activating and proaggregating heparin, must be clearly distinguished. This form shows only a moderate decrease (10–30%) of platelet counts with a nadir of more than 100×10^9/L in the first 2 days of treatment, a spontaneous platelet count recovery in the next 3–4 days during continuation of heparin treatment and, in particular, no other clinical symptoms, such as thrombosis or skin reactions.[39]

Other causes of heparin-induced skin lesions

Immediate hypersensitivity reactions to heparin can occur as anaphylactic (IgE mediated) or anaphylactoid (non-IgE mediated) reactions, but have been described only rarely, possibly because of improved purification, avoidance of preservatives and additives,[40] or the anti-inflammatory properties of heparins.[41] These reactions can occur as systemic[42] or local cutaneous manifestation.[43–47] Clinical symptoms range from localised to generalised urticaria, hypotension, angioedema, allergic rhinoconjunctivitis, tachycardia, and bronchospasm. For cutaneous reactions, fewer than 20 patients with this disorder have been reported. Of note, a cumulation of severe anaphylactoid reactions in more than 900 patients in the USA and Europe that led to fatal outcomes in more than 80 patients has helped to identify the function of oversulphated chondroitin sulphates, which could have a role as contaminants in various heparins. Via activation of factor XII, these sulphates were shown to trigger the contact system, with the generation of C3a and C4a anaphylatoxins, and prekallikrein, with the generation of kallikrein and bradykinin, causing a severe hypotensive anaphylactoid response.[48]

As previously discussed, heparin-induced thrombocytopenia can become manifest in anaphylactoid reactions in about 5% of these patients after treatment with an intravenous bolus of unfractionated heparin. Clinically distinctive features of the immediate reactions of heparin-induced thrombocytopenia are hypertension and a decline in platelet count.[36]

Allergologic testing is not established in type-1 allergic cutaneous reactions to heparins; immediate readings in prick tests (t=20 min) are usually false-positive and do not correlate with immediate hypersensitivity reactions.[27] Figure 3 shows further rare causes of heparin-induced skin lesions and table 2 lists these causes as described in case reports alone.[49–68]

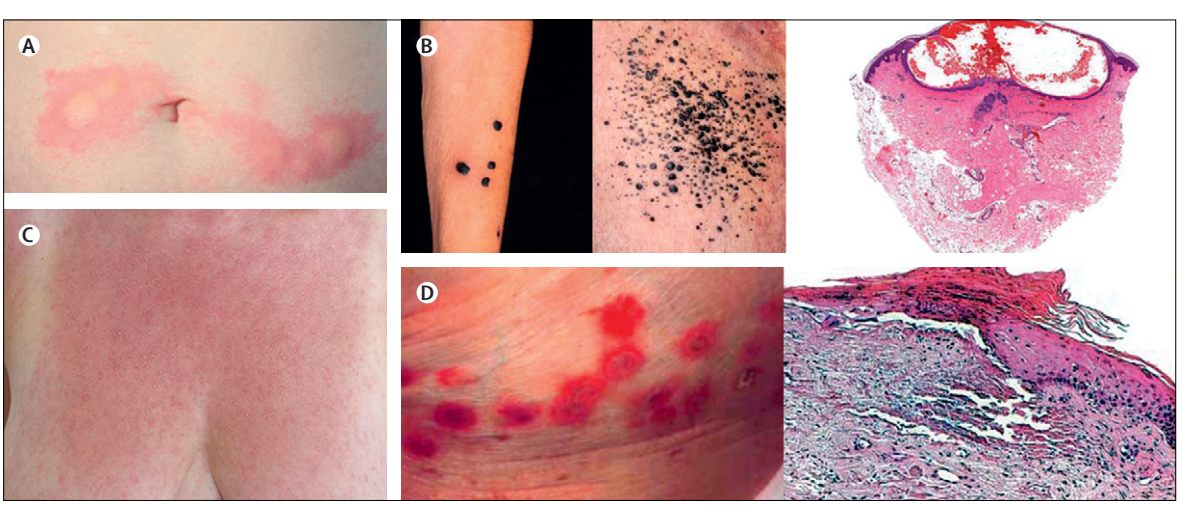

***Figure 3*: Rare other causes of heparin-induced skin lesions**
(A) Immediate-type hypersensitivity reaction—ie, recall urticaria. Weals on the lower left and right quadrants of the abdomen 20 min after skin tests with dalteparin at the forearm, reproduced from Weber HO and colleagues,[47] by permission of John Wiley and Sons. (B) Haemorrhagic bullosis. From left to right: haemorrhagic lesions on the arm; cluster of haemorrhagic lesions on the inguinal region; histological specimen with an intraepidermal, subcorneal blister filled with red blood cells, reproduced from Beltraminelli H and colleagues,[49] by permission of John Wiley and Sons. (C) Pustulosis. Generalised exanthema with small non-follicular and follicular pustules mainly on upper aspect of trunk, reproduced from Komericki P and colleagues,[50] by permission of Elsevier. (D) Calcinosis cutis. From left to right: multiple cutaneous plaques and nodules localised on the patient's abdomen after nadroparin calcium administration; prominent hyperkeratosis and mild epidermal acanthosis overlying an area of degenerative-regressive changes of the collagen fibres within the superficial and mid dermis that contain several, small globular depositions of calcium salts, reproduced from Giorgini S and colleagues,[51] by permission of John Wiley and Sons.

Risk factors of delayed-type hypersensitivity reactions

Heparin related

A heparin with a high molecular weight might increase the risk of lesion development.[28] As such, the ultra-low molecular-weight pentasaccharide fondaparinux has a low allergenic potential, causing delayed-type hypersensitivity reactions in less than 1% of patients (table 1).[17] By contrast, the overall incidence of delayed-type hypersensitivity reactions to heparins is 7·5% in medical patients (table 1).[16] This association is not as clear for the group of low molecular-weight heparins, which have similar molecular weights in a narrow range,[69] and subgroup analyses from epidemiological trials indicate a risk dependent on the individual heparin preparation (table 1). For example, the incidence of delayed-type hypersensitivity reactions is substantially different in patients treated with enoxaparin (4%) or nadroparin (17%), although both have similar molecular weights.[16] An increased incidence of heparin-induced skin lesions in patients given nadroparin is likewise noted in pregnant patients undergoing treatment with low molecular-weight heparins: the incidence of lesions with nadroparin treatment can be as high as 54%,[13,15] which is much higher than the incidence of 4% in patients given dalteparin.[15] These differences might be because of a more allergenic epitope in the nadroparin molecule which might be explained by the different manufacturing processes of the separate heparin preparations.[1] However, in these observational trials, detection of a difference between the heparins for the incidence of skin lesions was not an endpoint. Hence, a selection bias cannot be excluded for the differences in several low molecular-weight heparins regarding the incidence of lesions.

The low allergenic potential of fondaparinux to cause allergic skin reactions suggests that it might not act as a potent hapten during sensitisation. The synthetic origin of this drug, which provides a high intracharge and intercharge consistency, the exclusive antithrombin binding (>94%), the low charge density resulting from a lower degree of sulphation than heparins, and its short length might hamper binding reactions with thrombin and other proteins, and thus, sensitisation.[4,17] Therefore, the allergenic epitope in heparins might not consist of the pentasaccharide sequence that fondaparinux shares with heparins.

Patient related

In a review of case reports and series, the mean age of 223 patients with an increased risk of developing delayed-type hypersensitivity reactions was 56 (SD 13) years.[5] In a prospective assessment, of 320 patients, 24 (8%) with a cutaneous delayed-type hypersensitivity response to heparin were aged 53 (SD 15) years; by contrast, the 296 (92%) patients treated with heparin who had no skin lesions were substantially older (61 [SD 16] years).[16] Thus, young rather than old age seems to be a risk factor for delayed-type hypersensitivity reactions.

Female sex is a well-established risk factor for delayed-type hypersensitivity reactions. Retrospective analyses show that more than 75–90% of reported patients are female.[5,16] Prospective data confirmed the increased risk of women to develop cutaneous delayed-type hypersensitivity responses to heparin,[16] especially during pregnancy.[13–15]

Finally, obesity has long been considered as a risk factor for delayed-type hypersensitivity to heparin.[5,18] This assumption could be confirmed in a prospective study[16] of the incidence and causes of heparin-induced skin lesions in medical patients: the body-mass index (BMI) of patients with a delayed-type hypersensitivity response (BMI 30 [SD 6]) was significantly higher (odds ratio 4·6, 95% CI 1·7–15·3; p<0·001) than that of those who were

	Clinical presentation	Cases reported
Immediate hypersensitivity reaction[43–45]	Anaphylactic (IgE mediated) or anaphylactoid (non-IgE mediated) reactions; localised to generalised urticaria	<20
Recall urticaria[46,47]	Weals upon re-exposure at sites of first manifestation, but not at the site of recent heparin injection	2
Pustulosis[50]	Localised or generalised, small, mostly non-follicular pustules on erythematous skin; exocytosis of polynuclear neutrophils	1
Necrosis (not HIT-associated)[52–54]	Epidermal or dermal necrosis; unclear pathogenesis	3
Haemorrhagic bullosis[49,55,56]	Small intraepidermal blisters filled with erythrocytes	6
Toxic epidermal necrolysis[57,58]	Acute macular erythematous rash with subepidermal blistering, epidermal necrosis, skin detachment; Nikolsky sign positive	2
Arthus reaction[59,60]	Inflammation, erythematous induration, and subsequent necrosis due to a type-3 hypersensitivity reaction, with endothelial deposit of immune complexes	2
Baboon syndrome[61]	Erythematous skin lesions typically involving flexural sites and the buttocks	1
Hypereosinophilia[62,63]	Association of heparin-induced skin lesions with hypereosinophilia, possibly induced by secretion of interleukins 3 and 5 by CD4 lymphocytes	5
Calcinosis cutis[51,64–68]	Variable clinical presentation (erythema, bullae, papules, subcutaneous nodules, ulcerated plaques); globular, basophilic depositions of calcium within the dermis	13

HIT=heparin-induced thrombocytopenia.

Table 2: **Rare other causes of heparin-induced skin lesions**

www.thelancet.com Published online May 28, 2012 DOI:10.1016/S0140-6736(12)60409-7

treated with low molecular-weight heparin and did not present with skin lesions (BMI 26 [SD 6]).

Treatment associated

Treatment-associated risk factors for a cutaneous delayed-type hypersensitivity reaction to heparin include a prolonged treatment period. In patients with a delayed-type hypersensitivity response, the median duration of subcutaneous heparin treatment was 19 days (range 7–336) compared with 9 days (7–1095) in those with no skin lesions.[16] Interestingly, previous exposure to heparin had no effect on the risk of patients developing a delayed-type hypersensitivity reaction. Of note, however, previous exposure was determined on the basis of the patient's self-reported medical history. Prospective trials will be necessary to identify the real effect of past exposure on the risk of development of a delayed-type hypersensitivity response to heparin.[16]

Diagnosis

Medical history and clinical presentation

The major challenge in the diagnosis of heparin-induced skin lesions is the early recognition of lesions caused by heparin-induced thrombocytopenia and their accurate distinction from cutaneous delayed-type hypersensitivity responses. This recognition is important because underlying heparin-induced thrombocytopenia can lead to fatal thromboembolism and skin necrosis, whereas delayed-type hypersensitivity reactions are not life-threatening, but can result in severe secondary generalisation of skin reactions (table 3).[5,8–16,19,24,27,32–35,70–73] Quick assessment is important because the management of both complications differs greatly—eg, intravenous unfractionated heparin can be used in patients with delayed-type hypersensitivity,[73] but is contraindicated in those with heparin-induced thrombocytopenia (figures 4 and 5).[24]

Because of the high incidence of heparin-induced skin lesions, routine inspection of injection sites is recommended, especially in patients with identified risk factors.[16] A clinical distinction between delayed-type hypersensitvity and heparin-induced thrombocytopenia might be difficult because early cutaneous erythematous reactions of both entities can be similar and typically occur within 2 weeks after start of treatment.[5,16,19,33] When lesions appear later than 28 days after start of treatment, heparin-induced thrombocytopenia becomes more unlikely, although delayed-onset heparin-induced thrombocytopenia might occur in 3–5% of all cases.[24] Even with rapid onset of skin lesions in 24 h, both complications are possible if patients had previous sensitisation to heparin. Clinically distinctive features of cutaneous symptoms are skin necrosis in heparin-induced thrombocytopenia, whereas itching (even in the absence of skin lesions) and scaling are commonly observed in delayed-type hypersensitivity, and generalisation can occur. Itching is usually absent in patients with heparin-induced thrombocytopenia. Of note, in patients with erythematous non-necrotising skin reactions during use of low molecular-weight heparins, these reactions seem to be only rarely associated with heparin-induced thrombocytopenia (<1·2%), if at all.[19]

Laboratory tests for heparin-induced thrombocytopenia

Because skin lesions might be the only clinical presentation of heparin-induced thrombocytopenia,[20,21] this complication must be excluded on the basis of the combination of clinical features and laboratory testing. Clinically, heparin-induced thrombocytopenia can be assessed with the refined 4-T's pretest probability score, which assesses characteristic features of the complication (ie, thrombocytopenia; timing of decrease in platelet count; thromboembolic complications or other sequelae, such as skin lesions; and other causes for thrombocytopenia; table 4).[25,26] If heparin-induced thrombocytopenia is a probability, or if necrotic skin lesions occur, further assessment is necessary, such as platelet count monitoring, functional platelet activation assays (ie, serotonin release assay or heparin-induced platelet activation assay), and platelet factor 4-dependent enzyme immunoassays.[24]

	Heparin-induced thrombocytopenia	Delayed-type hypersensitivity
Incidence		7·5%[16]
Without skin lesion		
Unfractionated heparin	0·5–5·0%[24]	..
LMWH	0·1–1·0%[24]	..
With skin lesion		
Unfractionated heparin	0·05–1·0%	..
LMWH	0·01–0·04%	..
Ratio female:male	1·4–2:1[70,71]	7–9:1[5,16]
Time of onset (days)		
After first exposure	5–14 (28)*[24,34]	1–14 (336)†[5,16]
After previous exposure (within the past 100 days)	1–5[24]	1–5[5]
Localisation	Almost always at injection site, might rarely be distant[33]	Begins at injection site, generalisation possible in 3–10% of patients[5,14,16,27]
Pathophysiology	Anti-heparin-platelet factor 4 antibodies[32]	T-cell mediated delayed-type hypersensitivity[72]
Histology	Microthrombi in dermal vessels[33]	Perivascular, mononuclear cell infiltrate[27]
Course	Increased risk of thrombosis[35]	Lesions can aggravate; course can sometimes be self-limiting[5]
Skin necrosis	Yes, in 10–20% of patients with heparin-induced thrombocytopenia[33]	No[19]
Occurrence in pregnancy	Extremely rare[24]	19·8%[8-15]‡
Intravenous unfractionated heparin in emergency	Contraindicated[24]	Possible[30,73]
Skin allergy testing	Contraindicated[5]	Possible for special indications[27]

LMWH=low molecular-weight heparin. *5–14 days is the typical time of onset; lesions can occur up to 28 days after first exposure. †1–14 days is the typical time of onset; lesions can occur up to 336 days after first exposure. ‡See table 1 for further details.

Table 3: **Differences between skin lesions induced by a delayed-type hypersensitivity reaction and by heparin-induced thrombocytopenia**

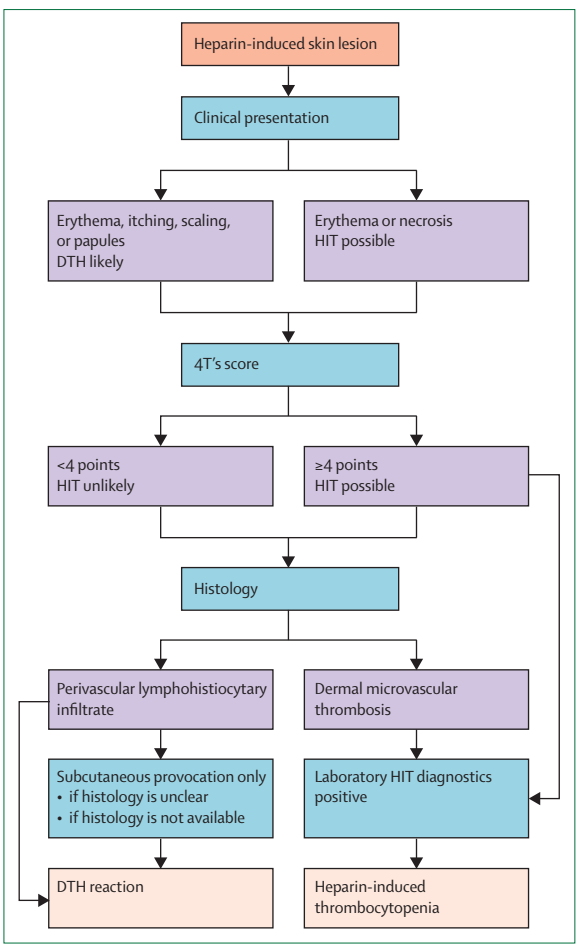

Figure 4: **Suggested algorithm for diagnosis of heparin-induced skin lesions**
DTH=delayed-type IV hypersensitivity reaction. HIT=heparin-induced thrombocytopenia.

However, platelet count monitoring is not only important when skin lesions occur, because it is most useful for providing the key information for prompt diagnosis of heparin-induced thrombocytopenia and in case of medicolegal litigations. Routine platelet monitoring between days 4 and 14 is strongly recommended in all patients with a risk for heparin-induced thrombocytopenia of more than 0·1% (this risk applies to all patient groups treated with unfractionated or low molecular-weight heparins, except for medical or obstetric patients given low molecular-weight heparin),[24] although national guidelines differ slightly in intensity and duration of monitoring, and risk to benefit estimations.

Histology

Unlike previous recommendations favouring skin allergy testing,[5,74] the diagnosis of a delayed-type hypersensitivity reaction should be based on a biopsy from lesional skin when history and clinical presentation alone are insufficient to diagnose the cause of the lesion.[27] Histology of a lesional skin biopsy allows the clinician to distinguish between most differential causes of heparin-induced skin lesions; histology is readily available in 1–3 days. Prospective data for the sensitivity and specificity of diagnostic tests for the diagnosis of heparin-induced skin lesions are available only for delayed-type hypersensitivity responses. In 23 patients with lesions caused by delayed-type hypersensitivity responses, histology showed 100% sensitivity.[27] Although histology can detect occlusion of dermal vessels (figure 2) due to heparin-induced thrombocytopenia,[33] this method has not been investigated prospectively. Histological examination of heparin-induced skin lesions should be done in all patients for differential diagnosis; however, the initial and basic assessment always involves a clinical diagnosis algorithm (figure 4 and table 4). If necessary, this algorithm should be complemented with laboratory diagnostic tests for heparin-induced thrombocytopenia, and tentative alternative anticoagulation until final histological diagnosis of delayed-type hypersensitivity.

Allergy testing

With the exception of subcutaneous provocation tests, allergologic testing is not specific (immediate hypersensitivity) or sensitive.[27,75] Therefore, routinely done skin allergy tests can no longer be recommended.[27] Use of these tests is further restricted because they can introduce new antigens with subsequent sensitisation, are contraindicated if heparin-induced thrombocytopenia is not ruled out, and are unfeasible when clinical decisions have to be made. In patients with heparin-induced skin lesions, allergologic testing can be done only 6 weeks after the clearance of all lesions and only when heparin-induced thrombocytopenia is excluded.[76] Hence, subcutaneous provocation tests to diagnose a delayed-type hypersensitivity reaction to heparin should be done only if the diagnosis is unclear, histology is not available, or when alternative anticoagulants need to be identified.

Lymphocyte proliferation assay

Until now, the only reported laboratory test for a delayed-type hypersensitivity response to heparin is a lymphocyte proliferation assay. A heparin-induced delayed-type hypersensitvity reaction was detected ex vivo by lymphocyte proliferation via ^{3}H-thymidine incorporation after heparin incubation in six of seven patients. Validation in a larger study is needed for this assay to become a useful technique for the diagnostic assessment of delayed-type hypersensitvity reactions to heparin, especially in patients at risk for such reactions, or for identifying possible cross-allergies.[31,77]

Because other causes of heparin-induced skin lesions are very rare, no recommendations can be made for their diagnosis. An individual diagnostic approach, also including skin biopsies, seems most appropriate.

www.thelancet.com Published online May 28, 2012 DOI:10.1016/S0140-6736(12)60409-7

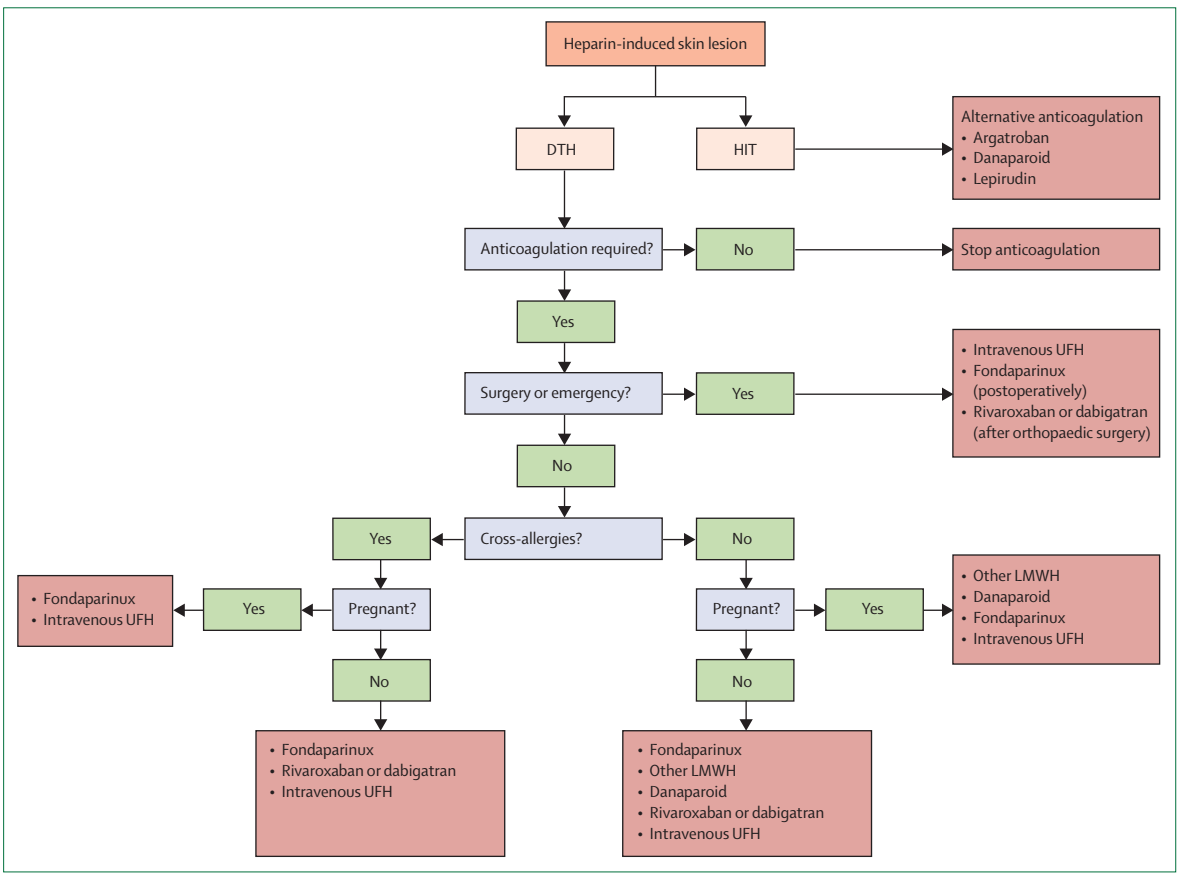

Figure 5: **Suggested algorithm for management of heparin-induced skin lesions**
DTH=delayed-type IV hypersensitivity reaction. HIT=heparin-induced thrombocytopenia. UFH=unfractionated heparin. LMWH=low molecular-weight heparin.

	Score 2	Score 1	Score 0
Thrombocytopenia	>50% decrease in platelet count, nadir of ≥20×10⁹/L, and no surgery in the past 3 days	>50% decrease in platelet count, but surgery in the past 3 days, or any combination of decreases in platelet count and nadir that does not fit criteria for a 4T's score of 2 or of 0 (ie, 30–50% decrease in platelet count or nadir of 10–19×10⁹/L)	<30% decrease in platelet count Any platelet-count decrease with nadir <10×10⁹/L
Timing of platelet-count decrease or thrombosis*	Decrease in platelet count at days 5–10 after start of heparin Decrease within one day of start of heparin and exposure to heparin in the past 5–30 days	Consistent with platelet decrease at day 5–10, but not clear (ie, missing counts) Platelet-count decrease in one day of start of heparin, and exposure to heparin in past 31–100 days Decrease in platelet count after day 10	Decrease in platelet count on or before day 4, with no exposure to heparin in the past 100 days
Thrombosis or other clinical sequelae	Confirmed new thrombosis (venous or arterial) Skin necrosis at injection site Anaphylactoid reaction to intravenous heparin bolus Adrenal haemorrhage	Recurrent venous thrombosis in a patient receiving therapeutic anticoagulants Suspected thrombosis (awaiting confirmation with imaging) Erythematous skin lesions at heparin injection sites	Thrombosis not suspected
Other cause for thrombocytopenia†	No alternative explanation for decrease in platelet count	Possible other cause is evident (ie, sepsis with no proven microbial source)‡	Probable other cause present (ie, sepsis with proven microbial source, drug-induced thrombocytopenia, non-necrotising skin lesions at injection sites of low molecular-weight heparins [presumed delayed-type hypersensitivity])‡

Pretest probability of heparin-induced thrombocytopenia by total scores: low=0–3, medium=4–5, high=6–8. Each category scores only once with either no, one, or two points. *In some cases, timing might be appropriately judged on the basis of clinical sequelae (ie, timing of onset of heparin-induced skin lesions). †Category of other causes usually scores 0 points if thrombocytopenia is not present; however, this score might be appropriately judged on the basis of clinical sequelae (ie, necrotising heparin-induced skin lesions score 2 points because an explanation not related to heparin-induced thrombocytopenia is unlikely; non-necrotising lesions score 0 points because an explanation not related to heparin-induced thrombocytopenia is likely). ‡For a full list of other causes see reference 26; adapted from Warkentin TE and colleagues, by permission of John Wiley and Sons.

Table 4: **Clinical pretest probability score (4 T's score) for heparin-induced thrombocytopenia**[26]

Management

When skin lesions caused by heparin-induced thrombocytopenia are suspected

Any patients with heparin-induced skin lesions, which after being clinically assessed (figure 4) are suspected to be caused by underlying heparin-induced thrombocytopenia, must be immediately treated with an alternative non-heparin anticoagulant, such as the heparinoid danaparoid or the direct thrombin inhibitors lepirudin, argatroban, or, with limitations bivalirudin.[24] However, erythematous non-necrotising skin lesions induced by low molecular-weight heparins should be considered in a differentiated way.[19,26]

When a delayed-type hypersensitivity reaction is already diagnosed

In cases of delayed-type hypersensitivity reactions, early detection followed by appropriate changes in anticoagulant treatment with only short exposure to the sensitising heparin will hamper development of cross-allergies[16] that are frequently noted during prolonged exposure.[6,18,28] When heparin-induced thrombocytopenia is excluded, but anticoagulation cannot be discontinued, the most pragmatic option seems to be a switch to another anticoagulant drug without allergy testing, preferentially to the low allergenic fondaparinux,[17,29,44,76] intravenous unfractionated heparin,[30,44,73] or possibly to rivaroxaban or dabigatran,[78] because frequent cross-allergies exist among different heparins or danaparoid. Symptomatic treatment can consist of topical class 2–3 corticosteroids, or antihistamines.

In surgical or emergency patients with delayed-type hypersensitivity reactions

Surgical patients with delayed-type hypersensitvity reactions needing intraoperative anticoagulant treatment can be successfully treated with intravenous unfractionated heparin.[30,44,73,79] In emergency patients with formerly diagnosed delayed-type hypersensitivity who are unlikely to have heparin-induced thrombocytopenia, heparin might be given intravenously with no prior testing,[73] although two cases of intravenous heparin intolerance with subsequent generalisation of the cutaneous reactions have been reported.[80,81] The high tolerance to intravenous unfractionated heparin compared with subcutaneous heparins in patients with known delayed-type hypersensitivity to heparins might be because of differences in the immunologically separate compartment, skin, also described as compartment allergy.[18] Such differences might include subcutaneous drug binding and alteration reactions, antigenic presentation and processing by epidermal Langerhans and dermal dendritic cells, and differential homing of sensitised T lymphocytes.[72] In these rare cases of intolerance to intravenous unfractionated heparin, non-heparin anticoagulants, such as argatroban, hirudins, bivalirudin or danaparoid, can be an alternative treatment option;[75,82–84] cutaneous adverse reactions with these drugs are comparatively rare.[83,85] Fondaparinux is a suitable alternative postoperatively,[17] as are rivaroxaban and dabigatran after orthopaedic surgery. Furthermore, off-label intravenous administration of dalteparin has been reported as successful in one patient.[86]

However, unlike IgE-mediated heparin type I-allergic reactions, rush desensitisation protocols[45,87–89] are not a treatment option in patients with delayed type-IV hypersensitivity reactions. Whether supplementary treatment with steroids and antihistamines is needed remains controversial.[30,86] In some emergency cases when uncertainty exists about the pathogenesis of flaring skin lesions (delayed-type hypersensitivity *vs* heparin-induced thrombocytopenia) and diagnostic results, such as histology, diagnostic tests for heparin-induced thrombocytopenia, cannot be waited for, the patient should be treated as having heparin-induced thrombocytopenia until final diagnosis.

In pregnant patients with delayed-type hypersensitivity reactions

No consensus exists regarding the optimum diagnostic strategy in pregnant patients,[14,90] who might need anticoagulant treatment for prophylaxis or for treatment of thromboembolic diseases. Although uneventful skin allergy testing has been documented,[91] testing should preferably not be done during pregnancy; however, pregnancy does not formally represent a contraindication.[92] On the basis of the low sensitivity of allergy testing,[27] we propose to refrain from these tests. To identify tolerable heparins, the treatment should be switched to a different heparin preparation, thus performing a subcutaneous provocation of fair sensitivity.[27] Cross-reactivity among different low

	Target	Cofactor	Origin	Application
Parenteral				
Unfractionated heparin (ratio)	Factor Xa, factor IIa (1:1)	Antithrombin	Biological	Subcutaneous, intravenous
Low molecular-weight heparin (ratio)	Factor Xa, factor IIa (10:1)	Antithrombin	Biological	Subcutaneous
Fondaparinux	Factor Xa	Antithrombin	Synthetic	Subcutaneous
Danaparoid (ratio)	Factor Xa, factor IIa (22:1)	Antithrombin	Biological	Subcutaneous, intravenous
Recombinant hirudin	Factor IIa	None	Biological	(Subcutaneous*), intravenous
Oral				
Dabigatran	Factor IIa	None	Synthetic	Oral administration
Rivaroxaban	Factor Xa	None	Synthetic	Oral administration
Apixaban	Factor Xa	None	Synthetic	Oral administration
Edoxaban	Factor Xa	None	Synthetic	Oral administration

*Subcutaneous use is possible, but is off-label.

Table 5: **Selection of anticoagulants with targets and application mode**

www.thelancet.com Published online May 28, 2012 DOI:10.1016/S0140-6736(12)60409-7

Panel: Risk-to-benefit profiles of different heparin preparations and fondaparinux

- Fondaparinux might be particularly advantageous[17] in patients with risk factors for delayed-type hypersensitivity reactions; current or previous reactions to heparins, including cross-allergies; those with immediate hypersensitivity reactions; osteoporosis; or those with orthopaedic or trauma surgery (fondaparinux does not inhibit osteoblast proliferation;[97] heparins show impaired fracture healing)
- Fondaparinux might have advantages in the high-risk cohort for delayed-type hypersensitivity reactions of pregnant women (although for now, this would be an off-label use)[93]
- The antagonisable unfractionated heparin has advantages in patients with renal insufficiency or a high risk of bleeding
- In oncology, different low molecular-weight heparins have prolonged survival in patients with cancer,[98] which might be because of the ability of some heparins to modulate pathways involved in haematogenous metastasis experimentally—eg, inhibition of selectins[99,100]

molecular-weight heparins has been reported in 33–73% of patients.[6,14] In case of several cross-reactions, intravenous unfractionated heparin or non-heparin anticoagulants should be considered.

Most evidence exists for danaparoid,[54,83] which does not cross the placenta and does not cause fetal toxic effects.[93] Composed of a mixture of heparin sulphate (84%), dermatan sulphate (12%), and chondroitin sulphate (4%), danaparoid can have cross-allergies with various heparins.[6,22] Another option is fondaparinux,[15,94] which showed no placental transfer in a perfused human cotyledon model in vitro,[95] and only marginal transfer in vivo, with no therapeutic systemic effect.[96] Hirudin cannot be recommended during pregnancy because of possible anaphylactic reactions, placental transfer, and embryotoxic effects.[93] Therefore, fondaparinux is preferable in patients with intolerance to numerous heparins and danaparoid.[93]

Novel anticoagulant drugs

Novel oral thrombin inhibitor dabigatran and factor Xa inhibitors, including rivaroxaban and apixaban, are presently, or have been investigated for treatment of various diseases, such as non-valvular atrial fibrillation, treatment of deep-vein thrombosis or pulmonary embolism, and acute coronary syndrome. As non-heparin anticoagulants, these inhibitors might become treatment alternatives in patients with delayed-type hypersensitvity reactions (table 5).[78] The phase 3 trials MAGELLAN and ADOPT have investigated rivaroxaban and apixaban for thrombosis prophylaxis in patients with acute medical illness who represent a high-risk cohort for delayed-type hypersensitivity reactions.[16]

Conclusions

Further prospective clinical trials are needed to identify the incidence of heparin-induced skin lesions in additional patient cohorts—eg, in surgical patients. Different patient populations probably carry distinct risks for development of delayed-type hypersensitivity reactions. Pregnant women seem to have the highest risk;[13,15] however, this risk might be due to the prolonged duration of treatment during pregnancy. Furthermore, the choice of heparin preparation seems to be important, but this assumption is based on the results of trials not specifically designed to detect differences among several heparin preparations. Diagnosis of heparin-induced skin lesions needs improvement because it mostly relies on invasive skin biopsies or allergy testing. The lymphocyte proliferation assay might be valuable if standardised.

Different heparin preparations show distinct risk to benefit profiles (panel), such as in anti-inflammatory and antimetastatic effects, osteoporosis rate, and renal clearance. These features should lead to a differentiated approach towards anticoagulation in distinct patient populations.[101]

Contributors

MS and ELL are the first authors and contributed equally to this work. RJL and WHB are the last authors and contributed equally to this work. WHB, MS, and RJL conceived the idea for the Review. MS and RJL searched for and reviewed published work. All authors outlined the structure of the report and were involved in writing, reviewing, and editing. All authors have seen and approved the final version. MS and RJL had full access to all data in the work and had final responsibility for the decision to submit for publication.

Conflicts of interest

MS has received a speaking fee from GlaxoSmithKline. ELL has received consulting fees from Bayer, Boehringer Ingelheim, GlaxoSmithKline, and Sanofi-Aventis. RJL has received consulting fees and grants from Biogen-Idec, Biotest AG, Abbott-Germany, and grants from Dompe pharma and Eroimmun AG. WHB declares that he has no conflicts of interest.

References

1 Alban S. From heparins to factor Xa inhibitors and beyond. *Eur J Clin Invest* 2005; **35** (suppl 1): 12–20.
2 Hirsh J, Warkentin TE, Shaughnessy SG, et al. Heparin and low-molecular-weight heparin: mechanisms of action, pharmacokinetics, dosing, monitoring, efficacy, and safety. *Chest* 2001; **119** (suppl): 64S–94S.
3 Hirsh J, Bauer KA, Donati MB, Gould M, Samama MM, Weitz JI. Parenteral anticoagulants: American College of Chest Physicians Evidence-Based Clinical Practice Guidelines (8th edition). *Chest* 2008; **133:** 141S–59S.
4 van Boeckel CA, Petitou M. The unique antithrombin III binding domain of heparin: a lead to new synthetic antithrombotics. *Angew Chem Int Ed Engl* 1993; **32:** 1671–90.
5 Ludwig RJ, Schindewolf M, Utikal J, Lindhoff-Last E, Boehncke WH. Management of cutaneous type IV hypersensitivity reactions induced by heparin. *Thromb Haemost* 2006; **96:** 611–17.
6 Grassegger A, Fritsch P, Reider N. Delayed-type hypersensitivity and cross-reactivity to heparins and danaparoid: a prospective study. *Dermatol Surg* 2001; **27:** 47–52.
7 Harenberg J, Schulze F, Sheikh H, Zimmermann R, Weber E. Allergische Hautreaktionen auf Heparin. *Phlebol Proktol* 1982; **11:** 195–96 (in German).
8 Sanson BJ, Lensing AW, Prins MH, et al. Safety of low-molecular-weight heparin in pregnancy: a systematic review. *Thromb Haemost* 1999; **81:** 668–72.

9 Ensom MH, Stephenson MD. Low-molecular-weight heparins in pregnancy. *Pharmacotherapy* 1999; **19:** 1013–25.

10 Greer IA, Nelson-Piercy C. Low-molecular-weight heparins for thromboprophylaxis and treatment of venous thromboembolism in pregnancy: a systematic review of safety and efficacy. *Blood* 2005; **106:** 401–07.

11 Deruelle P, Denervaud M, Hachulla E, et al. Use of low-molecular-weight heparin from the first trimester of pregnancy: a retrospective study of 111 consecutive pregnancies. *Eur J Obstet Gynecol Reprod Biol* 2006; **127:** 73–78.

12 Brenner B, Hoffman R, Carp H, Dulitsky M, Younis J, and the LIVE-ENOX Investigators. Efficacy and safety of two doses of enoxaparin in women with thrombophilia and recurrent pregnancy loss: the LIVE-ENOX study. *J Thromb Haemost* 2005; **3:** 227–29.

13 Kaandorp SP, Goddijn M, van der Post JA, et al. Aspirin plus heparin or aspirin alone in women with recurrent miscarriage. *N Engl J Med* 2010; **362:** 1586–96.

14 Bank I, Libourel EJ, Middeldorp S, Van Der Meer J, Büller HR. High rate of skin complications due to low-molecular-weight heparins in pregnant women. *J Thromb Haemost* 2003; **1:** 859–61.

15 Schindewolf M, Gobst C, Kroll H, et al. Pregnant women have an increased risk for heparin-induced allergic skin reactions—results of a prospective investigation. *Vasa* 2010; **39:** 61–62 (abstract).

16 Schindewolf M, Schwaner S, Wolter M, et al. Incidence and causes of heparin-induced skin lesions. *CMAJ* 2009; **181:** 477–81.

17 Schindewolf M, Scheuermann J, Kroll H, et al. Low allergenic potential with fondaparinux: results of a prospective investigation. *Mayo Clin Proc* 2010; **85:** 913–19.

18 Jappe U. Allergy to heparins and anticoagulants with a similar pharmacological profile: an update. *Blood Coagul Fibrinolysis* 2006; **17:** 605–13.

19 Schindewolf M, Kroll H, Ackermann H, et al. Heparin-induced non-necrotizing skin lesions: rarely associated with heparin-induced thrombocytopenia. *J Thromb Haemost* 2010; **8:** 1486–91.

20 Warkentin TE, Roberts RS, Hirsh J, Kelton JG. Heparin-induced skin lesions and other unusual sequelae of the heparin-induced thrombocytopenia syndrome: a nested cohort study. *Chest* 2005; **127:** 1857–61.

21 Bertrand PM, Perbet S, Sapin AF, et al. Heparin-induced skin necrosis: HIT-2 without thrombocytopenia. *Intensive Care Med* 2011; **37:** 172–73.

22 Harenberg J, Huhle G, Wang L, Hoffmann U, Bayerl C, Kerowgan M. Association of heparin-induced skin lesions, intracutaneous tests, and heparin-induced IgG. *Allergy* 1999; **54:** 473–77.

23 Warkentin TE. Heparin-induced skin lesions. *Br J Haematol* 1996; **92:** 494–97.

24 Warkentin TE, Greinacher A, Koster A, Lincoff AM. Treatment and prevention of heparin-induced thrombocytopenia: American College of Chest Physicians Evidence-Based Clinical Practice Guidelines (8th edition). *Chest* 2008; **133:** 340S–80S.

25 Lo GK, Juhl D, Warkentin TE, Sigouin CS, Eichler P, Greinacher A. Evaluation of pretest clinical score (4 T's) for the diagnosis of heparin-induced thrombocytopenia in two clinical settings. *J Thromb Haemost* 2006; **4:** 759–65.

26 Warkentin TE, Linkins LA. Non-necrotizing heparin-induced skin lesions and the 4T's score. *J Thromb Haemost* 2010; **8:** 1483–85.

27 Schindewolf M, Ludwig RJ, Wolter M, et al. Diagnosis of heparin-induced delayed-type hypersensitivity. *Phlebologie* 2010; **39:** 226–31.

28 Ludwig RJ, Schindewolf M, Alban S, Kaufmann R, Lindhoff-Last E, Boehncke WH. Molecular weight determines the frequency of delayed type hypersensitivity reactions to heparin and synthetic oligosaccharides. *Thromb Haemost* 2005; **94:** 1265–69.

29 Schindewolf M, Ludwig RJ, Wolter M, et al. Tolerance of fondaparinux in patients with generalized contact dermatitis to heparin. *J Eur Acad Dermatol Venereol* 2008; **22:** 378–80.

30 Boehncke WH, Weber L, Gall H. Tolerance to intravenous administration of heparin and heparinoid in a patient with delayed-type hypersensitivity to heparins and heparinoids. *Contact Dermat* 1996; **35:** 73–75.

31 Bircher AJ, Itin PH, Tsakiris DA, Surber C. Delayed hypersensitivity to one low-molecular-weight heparin with tolerance of other low-molecular-weight heparins. *Br J Dermatol* 1995; **132:** 461–63.

32 Greinacher A, Pötzsch B, Amiral J, Dummel V, Eichner A, Mueller-Eckhardt C. Heparin-associated thrombocytopenia: isolation of the antibody and characterization of a multimolecular PF4-heparin complex as the major antigen. *Thromb Haemost* 1994; **71:** 247–51.

33 Warkentin TE. Clinical picture of heparin-induced thrombocytopenia. In: Warkentin TE, Greinacher A, eds. Heparin-induced thrombocytopenia, 3rd edn. New York: Marcel Dekker, 2004: 53–106.

34 Warkentin TE, Kelton JG. Delayed-onset heparin-induced thrombocytopenia and thrombosis. *Ann Intern Med* 2001; **135:** 502–06.

35 Warkentin TE, Kelton JG. A 14-year study of heparin-induced thrombocytopenia. *Am J Med* 1996; **101:** 502–07.

36 Warkentin TE, Greinacher A. Heparin-induced anaphylactic and anaphylactoid reactions: two distinct but overlapping syndromes. *Expert Opin Drug Saf* 2009; **8:** 129–44.

37 Peitsch WK, Glorer E, Dempfle CE, Back W, Bayerl C, Goerdt S. Cutaneous necrosis mainly on the extremities. *Hautarzt* 2004; **55:** 410–13 (in German).

38 Gröger M, Sarmay G, Fiebiger E, Wolff K, Petzelbauer P. Dermal microvascular endothelial cells express CD32 receptors in vivo and in vitro. *J Immunol* 1996; **156:** 1549–56.

39 Greinacher A, Warkentin TE. Treatment of heparin-induced thrombocytopenia: an overview. In: Warkentin TE, Greinacher A, eds. Heparin-induced thrombocytopenia, 3rd edn. New York: Marcel Dekker, 2004: 335–370.

40 Dux S, Pitlik S, Perry G, Rosenfeld JB. Hypersensitivity reaction to chlorbutol-preserved heparin. *Lancet* 1981; **1:** 149.

41 Hochart H, Jenkins PV, Smith OP, White B. Low-molecular weight and unfractionated heparins induce a downregulation of inflammation: decreased levels of proinflammatory cytokines and nuclear factor-kappaB in LPS-stimulated human monocytes. *Br J Haematol* 2006; **133:** 62–67.

42 Berkun Y, Haviv YS, Schwartz LB, Shalit M. Heparin-induced recurrent anaphylaxis. *Clin Exp Allergy* 2004; **34:** 1916–18.

43 Bernstein IL. Anaphylaxis to heparin sodium; report of a case, with immunologic studies. *J Am Med Assoc* 1956; **161:** 1379–81.

44 Harr T, Scherer K, Tsakiris DA, Bircher AJ. Immediate type hypersensitivity to low molecular weight heparins and tolerance of unfractioned heparin and fondaparinux. *Allergy* 2006; **61:** 787–88.

45 Patriarca G, Rossi M, Schiavino D, et al. Rush desensitization in heparin hypersensitivity: a case report. *Allergy* 1994; **49:** 292–94.

46 Caliskaner Z, Karaayvaz M, Oztürk S. Recurrent urticaria lesions in a heparin-allergic patient: most likely another form of "recall urticaria". *J Investig Allergol Clin Immunol* 2005; **15:** 78–80.

47 Weber HO, Fischer J, Kneilling M, Caroli U, Rocken M, Biedermann T. Recall urticaria induced by skin tests with heparin. *Br J Dermatol* 2009; **161:** 187–89.

48 Kishimoto TK, Viswanathan K, Ganguly T, et al. Contaminated heparin associated with adverse clinical events and activation of the contact system. *N Engl J Med* 2008; **358:** 2457–67.

49 Beltraminelli H, Itin P, Cerroni L. Intraepidermal bullous haemorrhage during anticoagulation with low-molecular-weight heparin: two cases. *Br J Dermatol* 2009; **161:** 191–93.

50 Komericki P, Grims R, Kränke B, Aberer W. Acute generalized exanthematous pustulosis from dalteparin. *J Am Acad Dermatol* 2007; **57:** 718–21.

51 Giorgini S, Martinelli C, Massi D, Lumini A, Mannucci M, Giglioli L. Iatrogenic calcinosis cutis following nadroparin injection. *Int J Dermatol* 2005; **44:** 855–57.

52 Nadir Y, Mazor Y, Reuven B, Sarig G, Brenner B, Krivoy N. A fatal case of enoxaparin induced skin necrosis and thrombophilia. *Eur J Haematol* 2006; **77:** 166–68.

53 Singh S, Verma M, Bahekar A, et al. Enoxaparin-induced skin necrosis: a fatal outcome. *Am J Ther* 2007; **14:** 408–10.

54 Taylor AA. Successful use of heparinoids in a pregnancy complicated by allergy to heparin. *BJOG* 2001; **108:** 1011–12.

55 Thuillier D, Chaby G, Dadban A, et al. [Low-molecular-weight heparin-induced bullous haemorrhagic dermatosis associated with cell-mediated hypersensitivity]. *Ann Dermatol Venereol* 2009; **136:** 705–08 (in French).

56 Perrinaud A, Jacobi D, Machet MC, Grodet C, Gruel Y, Machet L. Bullous hemorrhagic dermatosis occurring at sites distant from subcutaneous injections of heparin: three cases. *J Am Acad Dermatol* 2006; **54** (suppl): S5–7.

57 Gallais V, Bredoux H, Rancourt MF, Dallot A, Salama J, Laroche L. [Toxic dermatitis caused by heparin]. *Presse Med* 1996; **25:** 1040 (in French).

58 Leung A. Toxic epidermal necrolysis associated with maternal use of heparin. *JAMA* 1985; **253:** 201.

59 Jackson AM, Pollock AV. Skin necrosis after heparin injection. *BMJ (Clin Res Ed)* 1981; **283:** 1087–88.

60 Phillips JK, Majumdar G, Hunt BJ, Savidge GF. Heparin-induced skin reaction due to two different preparations of low molecular weight heparin (LMWH). *Br J Haematol* 1993; **84:** 349–50.

61 Pfeiff B, Pullmann H. Baboon's syndrome due to heparin. *Deutsch Dermatologe* 1991; **39:** 559–60 (in German).

62 Giustolisi R, Guglielmo P, di Raimondo F, Cacciola E, Stagno F. Hypereosinophilia and subcutaneous heparin. *Lancet* 1993; **342:** 1371.

63 Bircher AJ, Itin PH, Büchner SA. Skin lesions, hypereosinophilia, and subcutaneous heparin. *Lancet* 1994; **343:** 861.

64 Boccara O, Prost-Squarcioni C, Battistella M, Brousse N, Rongioletti F, Fraitag S. Calcinosis cutis: a rare reaction to subcutaneous injections of calcium-containing heparin in patients with renal failure. *Am J Dermatopathol* 2010; **32:** 52–55.

65 Bonnecarrère L, Templier I, Carron PL, et al. [Two cases of iatrogenic cutis and subcutis calcinosis after calcium-containing heparin injection]. *J Mal Vasc* 2009; **34:** 366–71 (in French).

66 Eich D, Scharffetter-Kochanek K, Weihrauch J, Krieg T, Hunzelmann N. Calcinosis of the cutis and subcutis: an unusual nonimmunologic adverse reaction to subcutaneous injections of low-molecular-weight calcium-containing heparins. *J Am Acad Dermatol* 2004; **50:** 210–14.

67 Campanelli A, Kaya G, Masouyé I, Borradori L. Calcifying panniculitis following subcutaneous injections of nadroparin-calcium in a patient with osteomalacia. *Br J Dermatol* 2005; **153:** 657–60.

68 van Haren FM, Ruiter DJ, Hilbrands LB. Nadroparin-induced calcinosis cutis in renal transplant recipients. *Nephron* 2001; **87:** 279–82.

69 Grims RH, Weger W, Reiter H, Arbab E, Kränke B, Aberer W. Delayed-type hypersensitivity to low molecular weight heparins and heparinoids: cross-reactivity does not depend on molecular weight. *Br J Dermatol* 2007; **157:** 514–17.

70 Greinacher A, Farner B, Kroll H, Kohlmann T, Warkentin TE, Eichler P. Clinical features of heparin-induced thrombocytopenia including risk factors for thrombosis. A retrospective analysis of 408 patients. *Thromb Haemost* 2005; **94:** 132–35.

71 Warkentin TE, Sheppard JA, Sigouin CS, Kohlmann T, Eichler P, Greinacher A. Gender imbalance and risk factor interactions in heparin-induced thrombocytopenia. *Blood* 2006; **108:** 2937–41.

72 Posadas SJ, Pichler WJ. Delayed drug hypersensitivity reactions—new concepts. *Clin Exp Allergy* 2007; **37:** 989–99.

73 Gaigl Z, Pfeuffer P, Raith P, Bröcker EB, Trautmann A. Tolerance to intravenous heparin in patients with delayed-type hypersensitivity to heparins: a prospective study. *Br J Haematol* 2005; **128:** 389–92.

74 Bircher AJ, Harr T, Hohenstein L, Tsakiris DA. Hypersensitivity reactions to anticoagulant drugs: diagnosis and management options. *Allergy* 2006; **61:** 1432–40.

75 Koch P, Münssinger T, Rupp-John C, Uhl K. Delayed-type hypersensitivity skin reactions caused by subcutaneous unfractionated and low-molecular-weight heparins: tolerance of a new recombinant hirudin. *J Am Acad Dermatol* 2000; **42:** 612–19.

76 Ludwig RJ, Beier C, Lindhoff-Last E, Kaufmann R, Boehncke WH. Tolerance of fondaparinux in a patient allergic to heparins and other glycosaminoglycans. *Contact Dermat* 2003; **49:** 158–59.

77 Lopez S, Torres MJ, Rodríguez-Pena R, et al. Lymphocyte proliferation response in patients with delayed hypersensitivity reactions to heparins. *Br J Dermatol* 2009; **160:** 259–65.

78 Garcia-Ortega P, Asencio J. Dabigatran offers the simplest solution for thromboprophylaxis after orthopaedic surgery in patients allergic to low-molecular-weight heparins. *Br J Haematol* 2010; **151:** 84–85.

79 Trautmann A, Bröcker EB, Klein CE. Intravenous challenge with heparins in patients with delayed-type skin reactions after subcutaneous administration of the drug. *Contact Dermat* 1998; **39:** 43–44.

80 Schiffner R, Glässl A, Landthaler M, Stolz W. Tolerance of desirudin in a patient with generalized eczema after intravenous challenge with heparin and a delayed-type skin reaction to high and low molecular weight heparins and heparinoids. *Contact Dermat* 2000; **42:** 49.

81 Ojukwu C, Jenkinson SD, Obeid D. Deep vein thrombosis in pregnancy and heparin hypersensitivity. *Br J Obstet Gynaecol* 1996; **103:** 934–36.

82 Liew G, Campbell C, Thursby P. Delayed-type hypersensitivity to subcutaneous heparin with tolerance of i.v. administration. *Aust N Z J Surg* 2004; **74:** 1020–21.

83 Schindewolf M, Magnani HN, Lindhoff-Last E. [Danaparoid in pregnancy in cases of heparin intolerance—use in 59 cases]. *Hamostaseologie* 2007; **27:** 89–97 (in German).

84 Koch P, Reinhold S, Busch C. Delayed allergic skin reactions to subcutaneous heparins. Tolerance of 2 recombinant hirudins. *Contact Dermat* 2000; **42:** 278–79.

85 Smith KJ, Rosario-Collazo J, Skelton H. Delayed cutaneous hypersensitivity reactions to hirudin. *Arch Pathol Lab Med* 2001; **125:** 1585–87.

86 Koch P, Bahmer FA, Schäfer H. Tolerance of intravenous low-molecular-weight heparin after eczematous reaction to subcutaneous heparin. *Contact Dermat* 1991; **25:** 205–06.

87 Dave S, Park MA. Successful heparin desensitization: a case report and review of the literature. *J Card Surg* 2008; **23:** 394–97.

88 al-Eryani AY, al-Momen AK, Fayed DF, Allam AK. Successful heparin desensitization after heparin-induced anaphylactic shock. *Thromb Res* 1995; **79:** 523–26.

89 Parekh K, Burkhart HM, Hatab A, Ross A, Muller BA. Heparin allergy: successful desensitization for cardiopulmonary bypass. *J Thorac Cardiovasc Surg* 2005; **130:** 1455–56.

90 Verdonkschot AE, Vasmel WL, Middeldorp S, van der Schoot JT. Skin reactions due to low molecular weight heparin in pregnancy: a strategic dilemma. *Arch Gynecol Obstet* 2005; **271:** 163–65.

91 Sanders MN, Bernhisel-Broadbent J, Staker LV. Delayed hypersensitivity reaction to heparin in a pregnant woman. *Int J Dermatol* 1995; **34:** 443–44.

92 Aberer W, Bircher A, Romano A, et al, and the European Network for Drug Allergy (ENDA), and the EAACI interest group on drug hypersensitivity. Drug provocation testing in the diagnosis of drug hypersensitivity reactions: general considerations. *Allergy* 2003; **58:** 854–63.

93 Bates SM, Greer IA, Pabinger I, Sofaer S, Hirsh J. Venous thromboembolism, thrombophilia, antithrombotic therapy, and pregnancy: American College of Chest Physicians Evidence-Based Clinical Practice Guidelines (8th edition). *Chest* 2008; **133:** 844S–86S.

94 Gerhardt A, Zotz RB, Stockschlaeder M, Scharf RE. Fondaparinux is an effective alternative anticoagulant in pregnant women with high risk of venous thromboembolism and intolerance to low-molecular-weight heparins and heparinoids. *Thromb Haemost* 2007; **97:** 496–97.

95 Lagrange F, Vergnes C, Brun JL, et al. Absence of placental transfer of pentasaccharide (Fondaparinux, Arixtra) in the dually perfused human cotyledon in vitro. *Thromb Haemost* 2002; **87:** 831–35.

96 Dempfle CE. Minor transplacental passage of fondaparinux in vivo. *N Engl J Med* 2004; **350:** 1914–15.

97 Handschin AE, Trentz OA, Hoerstrup SP, Kock HJ, Wanner GA, Trentz O. Effect of low molecular weight heparin (dalteparin) and fondaparinux (Arixtra) on human osteoblasts in vitro. *Br J Surg* 2005; **92:** 177–83.

98 Akl EA, Gunukula S, Barba M, et al. Parenteral anticoagulation in patients with cancer who have no therapeutic or prophylactic indication for anticoagulation. *Cochrane Database Syst Rev* 2011; CD006652.

99 Ludwig RJ, Alban S, Bistrian R, et al. The ability of different forms of heparins to suppress P-selectin function in vitro correlates to their inhibitory capacity on bloodborne metastasis in vivo. *Thromb Haemost* 2006; **95:** 535–40.

100 Erpenbeck L, Schön MP. Deadly allies: the fatal interplay between platelets and metastasizing cancer cells. *Blood* 2010; **115:** 3427–36.

101 Ludwig RJ. Therapeutic use of heparin beyond anticoagulation. *Curr Drug Discov Technol* 2009; **6:** 281–89.

THE LANCET

Supplementary appendix

This appendix formed part of the original submission and has been peer reviewed. We post it as supplied by the authors.

Supplement to: Schindewolf M, Lindhoff-Last E, Ludwig RL, Boehncke W-H. Heparin-induced skin lesions. *Lancet* 2012; published online May 28. DOI:10.1016/S0140-6736(12)60409-7.

Introduction

1 Andersson LO, Barrowcliffe TW, Holmer E, Johnson EA, Sims GE. Anticoagulant properties of heparin fractionated by affinity chromatography on matrix-bound antithrombin iii and by gel filtration. *Thromb Res* 1976; **9:** 575-83.

2 Aquino RS, Pereira MS, Vairo BC, et al. Heparins from porcine and bovine intestinal mucosa: Are they similar drugs? *Thromb Haemost* 2010; **103:** 1005-15.

Pathogenesis of heparin-induced skin lesions

3 Patrizi A, Di Lernia V, Patrone P. Generalized reaction to subcutaneous heparin. *Contact Dermatitis* 1989; **20:** 309-10.

4 Estrada Rodriguez JL, Gozalo Reques F, Ortiz de Urbina J, Matilla B, Rodriguez Prieto MA, Gonzalez Moran NA. Generalized eczema induced by nadroparin. *J Investig Allergol Clin Immunol* 2003; **13:** 69-70.

5 Mora A, Belchi J, Contreras L, Rubio G. Delayed-type hypersensitivity skin reactions to low molecular weight heparins in a pregnant woman. *Contact Dermatitis* 2002; **47:** 177-8.

6 Jappe U, Juschka U, Kuner N, Hausen BM, Krohn K. Fondaparinux: a suitable alternative in cases of delayed-type allergy to heparins and semisynthetic heparinoids? A study of 7 cases. *Contact Dermatitis* 2004; **51:** 67-72.

7 Bircher AJ, Fluckiger R, Buchner SA. Eczematous infiltrated plaques to subcutaneous heparin: a type IV allergic reaction. *Br J Dermatol* 1990; **123:** 507-14.

8 Visentin GP, Ford SE, Scott JP, Aster RH. Antibodies from patients with heparin-induced thrombocytopenia/thrombosis are specific for platelet factor 4 complexed with heparin or bound to endothelial cells. *J Clin Invest* 1994; **93:** 81-8.

9 Newman PM, Chong BH. Heparin-induced thrombocytopenia: new evidence for the dynamic binding of purified anti-PF4-heparin antibodies to platelets and the resultant platelet activation. *Blood* 2000; **96:** 182-7.

10 Martel N, Lee J, Wells PS. Risk for heparin-induced thrombocytopenia with unfractionated and low-molecular-weight heparin thromboprophylaxis: a meta-analysis. *Blood* 2005; **106:** 2710-5.

11 Chong BH. Heparin-induced thrombocytopenia. *J Thromb Haemost* 2003; **1:** 1471-8.

12 Ainley EJ, Mackie IG, Macarthur D. Adverse reaction to chlorocresol-preserved heparin. *Lancet* 1977; **1:** 705.

13 Basic-Jukic N, Kes P. Severe anaphylactic reaction in a haemodialysis patient after administration of reviparin. *Nephrol Dial Transplant* 2004; **19:** 1021-2.

14 Blossom DB, Kallen AJ, Patel PR, et al. Outbreak of adverse reactions associated with contaminated heparin. *N Engl J Med* 2008; **359:** 2674-84.

Risk factors for the development of heparin-induced skin lesions

15 Scherer K, Tsakiris DA, Bircher AJ. Hypersensitivity reactions to anticoagulant drugs. *Curr Pharm Des* 2008; **14:** 2863-73.

Diagnosis of heparin-induced skin lesions

16 Keeling D, Davidson S, Watson H. The management of heparin-induced thrombocytopenia. *Br J Haematol* 2006; **133:** 259-69.

17 Samama CM, Albaladejo P, Benhamou D, et al. Venous thromboembolism prevention in surgery and obstetrics: clinical practice guidelines. *Eur J Anaesthesiol* 2006; **23:** 95-116.

18 Encke A, Haas S, Sauerland S, et al. S3-Leitlinie Prophylaxe der venösen Thromboembolie (VTE). *VASA* 2009; **38:** 1-131.

19 Trautmann A, Seitz CS. Heparin allergy: delayed-type non-IgE-mediated allergic hypersensitivity to subcutaneous heparin injection. *Immunol Allergy Clin North Am* 2009; **29:** 469-80.

Management of heparin-induced skin lesions

20 Hirsch K, Ludwig RJ, Lindhoff-Last E, Kaufmann R, Boehncke WH. Intolerance of fondaparinux in a patient allergic to heparins. *Contact Dermatitis* 2004; **50:** 383-4.

21 Irion R, Gall H, Peter RU. Delayed-type hypersensitivity to heparin with tolerance of its intravenous administration. *Contact Dermatitis* 2000; **43:** 249-50.

22 Jappe U, Reinhold D, Bonnekoh B. Arthus reaction to lepirudin, a new recombinant hirudin, and delayed-type hypersensitivity to several heparins and heparinoids, with tolerance to its intravenous administration. *Contact Dermatitis* 2002; **46:** 29-32.

23 Seitz CS, Brocker EB, Trautmann A. Management of allergy to heparins in postoperative care: subcutaneous allergy and intravenous tolerance. *Dermatol Online J* 2008; **14:** 4.

24 Wurpts G, Merk HF. Delayed intracutaneous test reaction in heparin intolerance. *Hautarzt* 2007; **58:** 394-6.

25 Zollner TM, Gall H, Volpel H, Kaufmann R. Type IV allergy to natural hirudin confirmed by in vitro stimulation with recombinant hirudin. *Contact Dermatitis* 1996; **35:** 59-60.

26 Borch JE, Bindslev-Jensen C. Delayed-type hypersensitivity to heparins. *Allergy* 2004; **59:** 118-9.

27 Barbaud A, Goncalo M, Bruynzeel D, Bircher A. Guidelines for performing skin tests with drugs in the investigation of cutaneous adverse drug reactions. *Contact Dermatitis* 2001; **45:** 321-8.

28 Harrison SJ, Rafferty I, McColl MD. Management of heparin allergy during pregnancy with danaparoid. *Blood Coagul Fibrinolysis* 2001; **12:** 157-9.

29 Magnani HN. An analysis of clinical outcomes of 91 pregnancies in 83 women treated with danaparoid (Orgaran). *Thromb Res* 2010; **125:** 297-302.

30 Parody R, Oliver A, Souto JC, Fontcuberta J. Fondaparinux (ARIXTRA) as an alternative anti-thrombotic prophylaxis when there is hypersensitivity to low molecular weight and unfractionated heparins. *Haematologica* 2003; **88:** ECR32.

31 Mazzolai L, Hohlfeld P, Spertini F, Hayoz D, Schapira M, Duchosal MA. Fondaparinux is a safe alternative in case of heparin intolerance during pregnancy. *Blood* 2006; **108:** 1569-70.

32 Harenberg J. Treatment of a woman with lupus and thromboembolism and cutaneous intolerance to heparins using fondaparinux during pregnancy. *Thromb Res* 2007; **119:** 385-8.

33 Wijesiriwardana A, Lees DA, Lush C. Fondaparinux as anticoagulant in a pregnant woman with heparin allergy. *Blood Coagul Fibrinolysis* 2006; **17:** 147-9.

Conclusions

34 Lindner T, Cockbain AJ, El Masry MA, et al. The effect of anticoagulant pharmacotherapy on fracture healing. *Expert Opin Pharmacother* 2008; **9:** 1169-87.

35 Lee AY, Rickles FR, Julian JA, et al. Randomized comparison of low molecular weight heparin and coumarin derivatives on the survival of patients with cancer and venous thromboembolism. *J Clin Oncol* 2005; **23:** 2123-9.

36 Borsig L. Antimetastatic activities of heparins and modified heparins. Experimental evidence. *Thromb Res* 2010; **125:** S66-71.

37 Venous Thromboembolic Event (VTE) Prophylaxis in Medically Ill Patients (MAGELLAN). Available at: http://www.clinicaltrials.gov/ct2/show/NCT00571649?term=rivaroxaban&rank=16.

38 Study of Apixaban for the Prevention of Thrombosis-related Events in Patients With Acute Medical Illness (ADOPT). Available at: http://www.clinicaltrials.gov/ct2/show/NCT00457002?term=apixaban&rank=5.