Journal of Dermatological Treatment

ISSN: 0954-6634 (Print) 1471-1753 (Online) Journal homepage: https://www.tandfonline.com/loi/ijdt20

Rapid, persistent, and simultaneous remission of urticaria and severe atopic dermatitis after treatment with omalizumab

Ester Del Duca, Maria Esposito, Stefania Lechiancole, Alessandro Giunta & Luca Bianchi

To cite this article: Ester Del Duca, Maria Esposito, Stefania Lechiancole, Alessandro Giunta & Luca Bianchi (2018) Rapid, persistent, and simultaneous remission of urticaria and severe atopic dermatitis after treatment with omalizumab, Journal of Dermatological Treatment, 29:sup4, 2-4, DOI: 10.1080/09546634.2018.1550246

To link to this article: https://doi.org/10.1080/09546634.2018.1550246

Accepted author version posted online: 04 Dec 2018.
Published online: 08 Jan 2019.

Submit your article to this journal

Article views: 149

View related articles

View Crossmark data

Citing articles: 1 View citing articles

Full Terms & Conditions of access and use can be found at
https://www.tandfonline.com/action/journalInformation?journalCode=ijdt20

JOURNAL OF DERMATOLOGICAL TREATMENT
2018, VOL. 29, NO. S4, 2–4
https://doi.org/10.1080/09546634.2018.1550246

Taylor & Francis
Taylor & Francis Group

Check for updates

Rapid, persistent, and simultaneous remission of urticaria and severe atopic dermatitis after treatment with omalizumab

Ester Del Duca, Maria Esposito, Stefania Lechiancole, Alessandro Giunta and Luca Bianchi

Department of Dermatology, University of Rome "Tor Vergata", Roma, Italy

ABSTRACT
This article reports the rapid and complete remission of concomitant chronic spontaneous urticaria and atopic dermatitis, obtained in a woman of 32 years, after treatment with omalizumab, without adverse events.

ARTICLE HISTORY
Received 13 April 2018
Accepted 13 November 2018

KEYWORDS
Urticaria; atopic dermatitis; IgE

Introduction

Atopic dermatitis (AD) is a common skin disease, with a growing prevalence calculated between 10 and 20% in children, and between 1 and 3% in adults (1). It is a multifactorial, chronic, relapsing, and remitting disorder that often shows improvement during adolescence. Patients affected present high level of Serum IgE directed against ubiquitous allergens (2,3). The localization of AD lesions changes according to age and adult disease mainly predilects folds. Chronic spontaneous urticaria is a common debilitating disease characterized by itching and hives with or without angioedema lasting for more than 6 weeks (4). It is associated with several comorbidities, mainly represented by autoimmune diseases. Hashimoto thyroiditis, pernicious anemia, and type 1 diabetes mellitus are very frequent associations, but celiac disease and AD may also be present (5).

Patient and methods

A 32-year-old woman arrived at our clinic for urticaria not controlled by high dose of antihistamines. She suffered from widespread hives that have been presented for 6 months resistant to cetirizine 20 mg BID for 2 months and oral betamethasone 4 mg daily in decalage for 6 weeks. After 6 weeks, the therapy was reinforced adding rupatadine 10 mg once a day for 1 month without improvement. She reported also AD since the age of 10 treated with topical triamcinolone acetonide cream and emollients without any benefits. At the dermatological evaluation, we assessed the presence of widespread xerosis, flexural eczema, skin fissures involving perioral area and hands, hyperlinear palms and erythematous, lichenification of the neck area. Moreover, we identified a widespread erythema of trunk and limbs characterized by edematous, well-defined bordered wheals.

She reported in anamnesis personal history of thyroid carcinoma resolved with complete surgical excision and ulcerative colitis, remitting at that time. No personal history of angioedema, asthma, seasonal allergy, or any other respiratory conditions was reported. Anamnesis was positive for family history of atopy. She also complained exacerbation of atopic eczema occurring in concomitance with urticarious flare. The diagnosis of AD was made following the standard criteria (6,7). Pruritus and eczema were presented. In addition, the patient showed various associated features such as keratosis pilaris, perioral changes, hyperlinear palms, and lichenifications. Blood examination, serological and cultural tests were performed to rule out parasitic infestations, lymphoproliferative diseases, tumors, and chronic infections. Serum level of IgE was 1485 IU, and antinuclear antigen was positive 1:160. Prick tests for aeroallergens had been performed 6 months before, and had demonstrated sensitivity (±) to dermatophagoides. Based on these clinical clues, we provided diagnosis of urticaria occurring in patient affected by AD. Eczema Area and Severity Index (EASI) and Scoring Atopic Dermatitis (SCORAD) assessed the severity of AD. Urticaria Activity Score (UAS) assessed the severity of urticaria, at the visit. At the first visit, SCORAD was 41, EASI was 30, and Body surface area (BSA) was 70% (Figure 1(A,B)). Itching was scored 80 on a visuo-analogic scale (itch VAS) from 0 to 100. UAS score was 5.

We decided to start a treatment with bilastine 20 mg three times/day and prednisone 25 mg/day reduced after 10 days to 10 mg and continued until the follow-up visit. After 20 days, the weekly Urticaria Activity Score (UAS7) was 35/42 as recorded referring to the last week. Confirming chronic urticaria in concomitance with AD diagnosis subcutaneous omalizumab 300 mg/every 4 weeks. Antihistamines were continued, while prednisone was discontinued after 15 days.

Results

After 4 weeks from the first administration of omalizumab, an almost complete response of urticaria was seen (UAS7 = 10). AD symptoms were improved, with itch VAS =30. After 8 weeks, complete remission of both urticaria (UAS7 = 0) and AD (EASI =0, itch VAS =0) was obtained (Figure 2(A,B)). After 24 weeks of treatment with omalizumab, remission of urticaria and AD symptoms persisted and IgE value was stable. After treatment interruption and 4 months of follow-up, complete remission was still present, with BSA 0%, SCORAD =0, EASI =0, and itch VAS =0. At the 5-month

CONTACT Ester Del Duca ester.delduca@gmail.com Department of Dermatology, University of Rome "Tor Vergata", Via Cracovia, Roma, 00133, Italy
© 2018 Informa UK Limited, trading as Taylor & Francis Group

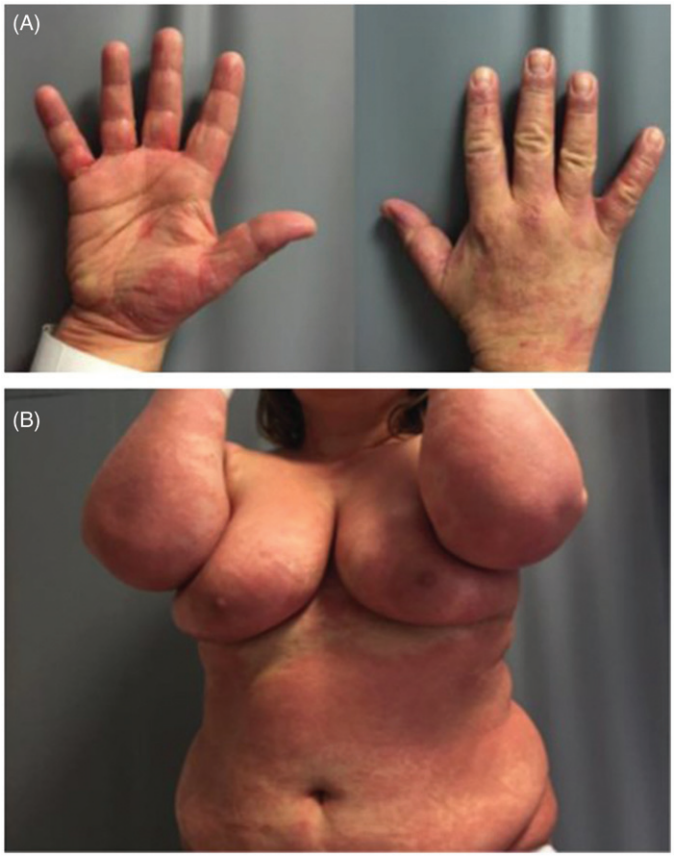

Figure 1. Skin lesions at presentation, hands (A) and trunk (B).

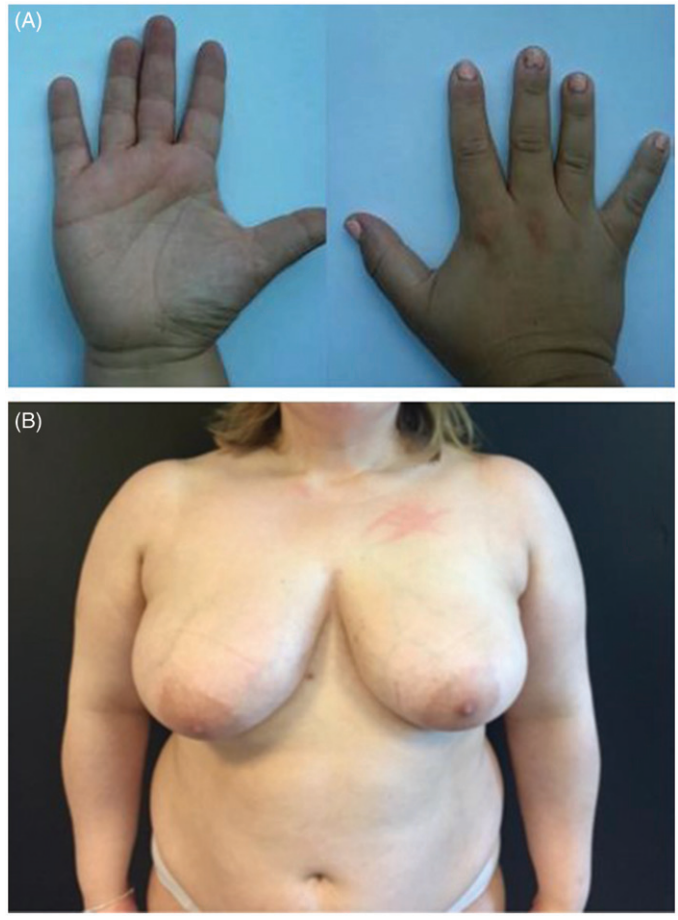

Figure 2. Symptoms resolution after treatment, hands (A) and trunk (B).

follow-up visit, erythematous patches were observed in the flexural area, with a mild exacerbation of palmar dryness BSA 5%, SCORAD =4, and EASI =3.

No adverse events were reported.

Discussion

Rapid and complete remission of concomitant chronic spontaneous urticaria and AD was obtained in a woman after treatment with omalizumab, without adverse events. These results persisted during the follow-up period.

Omalizumab is a monoclonal humanized anti-immunoglobulin E that binds to the Cε3 domain of the IgE heavy chain (8). Because of its mechanism of action, the treatment with Omalizumab results in a significant and rapid reduction in serum levels of free IgE, with succeeding downregulation of FcεRI (IgE high-affinity receptor) and FcεRII (IgE low-affinity receptor) (9). Omalizumab has been approved by the FDA for use in asthma in adults and adolescents, allergic rhinitis and occupational latex allergy (10–11). AD is the third element of the classic atopic march along with allergic rhinitis and asthma (12), for this reason, previous trials proposed omalizumab as a potential therapy for AD with high level of serum IgE.

This clinical experience shows a potential effectiveness of omalizumab in the treatment of chronic urticaria and, in agreement with previous observations (13,14), may suggests that, even though there is no indication, this drug may be a suitable option for patients with AD unresponsive to gold standard therapies. Along with our finding, a literature search (15) identified 26 studies and case series for 185 patients exploring omalizumab treatment in AD. One hundred and twenty-nine (74.1%) patients experienced a beneficial effect of treatment ranging from partial to complete response (15).

Conclusion

Our experience, although sporadic, showed good therapeutic results of omalizumab in severe AD in a patient with concomitant chronic spontaneous urticaria. Larger and controlled studies are needed on a representative sample of adult patients in order to confirm our clinical result.

Patient consent

The patient gave consent to the inclusion of material pertaining herself into this article, she acknowledged that she cannot be identified via the paper; the authors fully anonymized patient's material.

Acknowledgement

Medical writing assistance of this paper was provided by Laura Brogelli, on behalf of Content Ed Net; this assistance was funded by Novartis.

Funding

This supplement was funded by Novartis.

Disclosure statement

The authors report no conflicts of interest.

References

1. Flohr C, Mann J. New insights into the epidemiology of childhood atopic dermatitis. Allergy. 2014;69:3–16.
2. Leung D, Bieber T. Atopic dermatitis. Lancet. 2003;361: 151–160.
3. Tezza G, Mazzei F, Boner A. Epigenetics of allergy. Early Hum Dev. 2013;89:S20–S21.
4. Gallo C, Vighi G, Schroeder J, et al. Chronic urticaria atopic dermatitis and celiac disease. Am J Gastroenterol. 1992;87:1684
5. Kolkhir P, Borzova E, Grattan C, et al. Autoimmune comorbidity in chronic spontaneous urticaria: a systematic review. Autoimmun Rev. 2017;16:1196–1208.
6. Eichenfield L, Tom W, Chamlin S, et al. Guidelines of care for the management of atopic dermatitis: section 1. Diagnosis and assessment of atopic dermatitis. J Am Acad Dermatol. 2014; 70:338–351.
7. Schneider L, Tilles S, Lio P, et al. Atopic dermatitis: a practice parameter update. J Allergy Clin Immunol. 2013;131: 295–299.
8. MacGlashan D, Bochner B, Adelman D, et al. Down-regulation of FceRI expression on human basophils during in vivo treatment of atopic patients with anti-IgE antibody. J Immunol. 1997;158:1428–1445.
9. Labrador-Horrillo M, Ferrer M. Profile of omalizumab in the treatment of chronic spontaneous urticaria. Drug Des Devel Ther. 2015;9:4909–4915.
10. Vignola A, Humbert M, Bousquet J, et al. Efficacy and tolerability of anti-immunoglobulin E therapy with omalizumab in patients with concomitant allergic asthma and persistent allergic rhinitis: solar. Allergy. 2004;59:709–717.
11. Leynadier F, Doudou O, Gaouar H, et al. Effect of omalizumab in health care workers with occupational latex allery. J Allergy Clin Immunol. 2004;133:360–361.
12. Bantz SK, Zhu Z, Zheng T. The atopic march: progression from atopic dermatitis to allergic rhinitis and asthma. J Clin Cell Immunol. 2014;5:202.
13. Chen T, Chan S, Lack G, et al. The role of anti-IgE (omalizumab/Xolair) in the management of severe recalcitrant paediatric atopic eczema (ADAPT): statistical analysis plan. Trials. 2017;23:18–231.
14. Fernández-Antón Martínez M, Leis-Dosil V, Alfageme-Roldán F, et al. Omalizumab for the treatment of atopic dermatitis. Actas Dermosifiliogr. 2012;103:624–628.
15. Holm J, Agner T, Sand C, et al. Omalizumab for atopic dermatitis: case series and a systematic review of the literature. Int J Dermatol. 2017;56:18–26.