Recent Developments in Atopic Dermatitis

Eric J. Yang, BS,[a,b] Sahil Sekhon, MD,[a] Isabelle M. Sanchez, MPH,[a,c] Kristen M. Beck, MD,[a] Tina Bhutani, MD[a]

abstract

Atopic dermatitis (AD) is a bothersome and common skin disease affecting ~10.7% of children in the United States. This skin condition significantly decreases quality of life in not only patients, but in their families as well. Pediatricians are often the first physicians to diagnose and manage these patients and thus are relied on by families to answer questions about this disease. AD is complex, multifactorial, and has historically had limited therapeutic options, but the landscape of this disease is now rapidly changing. Pathways contributing to the pathogenesis of this disease are continually being discovered, and new therapies for AD are being developed at an unprecedented rate. With this article, we will review the current guidelines regarding the management of AD, outline updates in the current understanding of its pathophysiology, and highlight novel developments available for the treatment of this burdensome disease.

[a]Department of Dermatology, University of California, San Francisco, San Francisco, California; [b]Chicago Medical School, Rosalind Franklin University of Medicine and Science, North Chicago, Illinois; and [c]College of Medicine, University of Illinois at Chicago, Chicago, Illinois

Mr Yang, Dr Sekhon, Ms Sanchez, and Drs Beck and Bhutani participated in the drafting and revising of this manuscript; and all authors approved the final manuscript as submitted and agree to be accountable for all aspects of the work.

DOI: https://doi.org/10.1542/peds.2018-1102

Accepted for publication Jul 24, 2018

Address correspondence to Eric J. Yang, BS, Department of Dermatology, University of California, San Francisco, 515 Spruce St, San Francisco, CA 94118. E-mail: ericjyang@outlook.com

PEDIATRICS (ISSN Numbers: Print, 0031-4005; Online, 1098-4275).

Copyright © 2018 by the American Academy of Pediatrics

FINANCIAL DISCLOSURE: Dr Bhutani is an investigator for AbbVie, Janssen, Merck, Eli Lilly, and Strata Skin Sciences but has no direct financial conflicts to report; the other authors have indicated they have no financial relationships relevant to this article to disclose.

FUNDING: No external funding.

POTENTIAL CONFLICT OF INTEREST: Dr Bhutani is an investigator for AbbVie, Janssen, Merck, Eli Lilly, and Strata Skin Sciences; the other authors have indicated they have no potential conflicts of interest to disclose.

To cite: Yang EJ, Sekhon S, Sanchez IM, et al. Recent Developments in Atopic Dermatitis. *Pediatrics.* 2018;142(4):e20181102

Atopic dermatitis (AD) is a chronic inflammatory skin disease that affects ~10.7% of children in the United States[1] and is becoming increasingly prevalent.[2–4] Pediatricians are often the first physicians providing treatment to patients with new-onset AD and disease flares,[5] and ~50% of patients with AD are treated in a primary care setting.[6] Therefore, pediatricians play a key role in the overall management of patients with AD and should be well informed about recent developments in the clinical management of this disease.[7]

Despite its high prevalence, this complex disease has historically been poorly understood. With this article, we provide an update on recent advances in our understanding of the clinical presentation and pathophysiology of AD and highlight new therapeutic developments for this disease.

CLINICAL COURSE

AD is a bothersome skin condition often referred to as the "itch that rashes" because of the pruritus that patients experience. This hallmark symptom of AD is responsible for its significant negative impact on quality of life (QoL).[8] Patients with AD often present with severe pruritus and xerosis, with variable lesion distribution based on age. Young infants up to 2 years of age often present with scaly, crusted erythematous patches on the scalp, face, and extensor surfaces, whereas prepubertal children present with erythematous patches in a flexural distribution.[9] Adolescents and adults typically present with more lichenified skin changes.

The progression of AD is unpredictable, but the following 4 phenotypes have recently been identified: early-onset transient (9.2% of children), early-onset persistent (6.5%), late-onset (4.8%), and absent or infrequent AD (79.5%).[10] Patients with AD have alternating periods of exacerbated disease and symptom resolution. Thus, both the alleviation of symptoms and prevention of flares are important in the management of AD.

Diagnosis

Patients commonly present during acute flares with intense pruritus,

Downloaded from www.aappublications.org/news by guest on October 1, 2018

xerosis, erosions, excoriations, and ill-defined patches of erythema with a distribution that varies with age.[7,11] AD is clinically diagnosed on the basis of history, morphology, distribution of skin lesions, and associated clinical signs.[11] Other important factors suggesting a diagnosis of AD include early onset (<2 years of age), atopy, and family history of disease.[11,12] This diagnosis should be reevaluated frequently, particularly in patients not responding to appropriate treatment, to verify the accuracy of this diagnosis and exclude the possibility of other conditions, such as scabies, contact dermatitis, psoriasis, tinea infections, or viral exanthems.[7,13]

Comorbidities and Complications

AD is thought to "kick off" the atopic march, predisposing patients to other atopic disorders later in life.[14,15] Patients with AD with early sensitization to foods have an increased risk of developing asthma, allergic rhinitis, and food allergies.[16] Therefore, early diagnosis and management of AD and its associated risk factors may reduce the risk of developing other allergic diseases and improve overall QoL.[16]

AD has been associated with an increased risk of developing a peanut allergy specifically,[17] but previous clinical practice guidelines on food allergy prevention were constantly changing. Most recently, the Learning Early About Peanut Allergy trial revealed that an early introduction of peanut-containing foods reduces the risk of developing a peanut allergy in high-risk patients, including infants with severe AD.[18] Current consensus guidelines recommend an introduction of peanut-containing foods such as peanut butter or peanut puffs as early as 4 months of age to patients with AD to reduce this risk of future allergy.[19,20]

Children with AD have significant cutaneous immune dysregulation and an impaired skin barrier, which contribute to an increased susceptibility of developing skin infections.[21,22] Because of a decreased antimicrobial peptide expression,[23] >75% of affected children are colonized by *Staphylococcus aureus*, compared with <25% of healthy children in control groups.[24] *Staphylococcus* colonization worsens inflammation and pruritus,[24] increasing the risk of colonization and/or superinfection with *Streptococcus pyogenes*, viruses, or fungi.[21] AD can also predispose patients to disseminated eczema herpeticum and molluscum contagiosum outbreaks.[21]

Currently well-known comorbidities of AD are mostly atopic, but AD may have a broader impact on health. Authors of recent studies have shown that patients with AD are more likely be obese[25,26] and have elevated serum cardiovascular risk markers than healthy patients,[27] contributing to increased cardiovascular disease risk.[28–30] However, severe AD in children and adolescents has also been associated with impaired growth and short stature.[31–34] Patients with AD are also at an increased risk of developing depression, anxiety, attention-deficit/hyperactivity disorder, and conduct disorder,[35–37] with risk correlated with AD disease severity.[35] AD is not just skin deep, and management should be used to address the comorbidities, in addition to skin symptoms, associated with this systemic disease.

QoL Impairments

Although skin disease is often perceived to be relatively benign, children with generalized AD report QoL deficits similar to that of children with other serious chronic diseases, including renal disease and cystic fibrosis.[38,39] Because of the ever-present nature of the itch–scratch cycle, AD can be extremely burdensome and infringe on all areas of affected patients' lives, including sleep, social functioning, work productivity, and income.

AD has a well-characterized negative impact on sleep in children[40,41] and their families[42] because of debilitating pruritus and the constant care needed for this disease. Children with moderate-to-severe AD experience more restless sleep, increased waking, greater difficulty falling asleep, and increased daytime sleepiness compared with healthy patients; these are behaviors that worsen with the severity of AD and with flares.[21,43] Parents of affected children also experience significant sleep loss (~1–3 hours per night) while providing overnight care to soothe their children and help them return to sleep.[42,44] The severity of sleep disruption associated with AD is comparable to that of other chronic conditions requiring constant care, including autism spectrum disorder, mental retardation, and seizure disorders.[45] An effective treatment plan is necessary to minimize the QoL impairment because of poor sleep in both affected patients[46] and their families.[47]

AD affects children during critical stages of childhood development, causing significant QoL impairment at ages when patients are most vulnerable. Children with AD can be severely impacted by fear of embarrassment[46,48] and constant anxiety about future flares.[49] Patients with AD are often socially isolated and bullied because of the fear of contagion and stigma,[50] leading to poor self-esteem in these young and impressionable patients.[51] As a result, patients with AD often withdraw socially, avoid group activities, or may even skip school to prevent further embarrassment.[46,52] Affected patients will often also have impaired concentration because of sleep loss, antihistamine sedation, and irresistible itch, which, combined with stunted social development and missed school time, may decrease scholastic achievement and

Downloaded from www.aappublications.org/news by guest on October 1, 2018

ultimately diminish future career prospects.[46,49,52–54]

Additionally, AD is economically burdensome, costing the United States $5.3 billion in 2004,[55] a number that will likely rise with the rapidly increasing price of topical corticosteroids (TCSs).[56] In 1 study, families of affected patients spent 34.8% ($274) of their available monthly income on AD care, which can be a significant financial burden especially for low-income families.[57] Caregivers for patients with AD often miss work to care for their children's health issues,[42] which can contribute to impaired work performance and decreased income. It is important for pediatricians to be aware that the negative impact of AD on the QoL for patients and their families is multimodal. Skin symptoms represent a small portion of the negative impact of AD, which also profoundly affects sleep, childhood development, and finances.

PATHOPHYSIOLOGY AND PATHOGENESIS

The pathogenesis of AD involves a complex interplay of immunologic dysfunction, genetics, environmental exposures, and skin barrier disruption. Loss-of-function filaggrin gene mutations were implicated early on as a major predisposing risk factor for AD,[58] suggesting skin barrier defects to be key drivers of this disease. However, authors of more recent research have found that filaggrin is deficient in most affected adults regardless of genotype[59] but not in patients with new-onset AD.[60] Therefore, filaggrin deficiency is not necessary for disease onset but may be a downstream result of disease chronicity. Authors of recent findings have also found skin barrier disruption to occur early in life, with increased neonatal transepidermal water loss predicting future development of AD.[61] Nevertheless, most recent developments with respect to therapeutics and pathogenesis of this multifactorial condition have been in the understanding of the immunology of this disease.

However, much of the current understanding of AD immunology is based on studies in adults, who present different clinically and have a longer duration of disease than pediatric patients. Given that the immune system changes with age,[62] findings in adults may not represent the immunologic processes occurring in children. Authors of recent studies have characterized immunologic differences in AD observed with age,[63] ethnicity,[64] and disease subtype,[65] suggesting that several distinct inflammatory mechanisms likely contribute to this complex, heterogeneous skin disease. Significant recent advances have increased our understanding of the underlying mechanisms of both adult and pediatric AD, contributing to the development of novel therapies for this complex disease.

AD has historically been described as a biphasic T-cell–mediated disease, in which an initial T helper (Th) 2 (Th2) activation drives acute disease, whereas a later Th1 response maintains chronic AD.[66] Authors of recent studies corroborate the role of early Th1 axis suppression in this disease, finding low Th1 T-cell levels in acute AD lesions in adults[67] and children recently diagnosed with AD.[63] However, chronic AD lesions reveal intensification, rather than withdrawal, of Th2-related inflammation.[67] Strong activation of the Th2 and Th22 inflammatory responses are observed in the lesional skin of both children and adults with AD, but affected children demonstrate greater induction of the Th17 axis to levels comparable to that of patients with psoriasis.[60] Interestingly, the nonlesional skin of young children[60] and adults[68] also already harbors significant inflammation with increased Th2 and Th17 expression, suggesting that AD involves early systemic involvement. Thus, the progression of AD may not be as clear-cut as previously thought.

Despite major immunologic similarities to AD in adults, pediatric AD also reveals features that may be unique to new-onset disease. The skin of affected children reveals T-cell predominance as compared with healthy children and affected adults, implicating T-cell activation as a key driver of early AD.[69] Additionally, these children exhibit lymphocyte distributions similar to that of healthy adults, implying that accelerated lymphocyte development may play a role in disease initiation.[69] The lesional skin of affected children also uniquely reveals gene expression more similar to psoriatic lesions than that of adult AD or healthy pediatric skin, which may have implications for future treatment.[60] Significant inroads are being made to understand the pathogenesis of both adult and pediatric AD and the overlap and differences between the 2, which may help guide the development of future, more targeted therapies.

Although various additional pathways contribute to AD, the Th2 immune response remains the main focus of AD pathogenesis and therapeutic development. Th2 cells are the main producers of Th2 cytokines interleukin 4 (IL-4), interleukin 5 (IL-5), and interleukin 13 (IL-13) in AD, but type 2 innate lymphoid cells (ILC2s), found in increased numbers in lesional AD skin,[70] have recently been characterized as an additional source of Th2 cytokine release.[70–72] The recent discovery of these cells in AD may link several abnormalities known to occur within AD and may serve as a target for new therapies in the near future.

ILC2s express killer cell lectin-like receptor G1, which normally binds E-cadherin to inhibit ILC2 proliferation and IL-5 and/or IL-13 production.[70] E-cadherin is normally expressed by epidermal cells but is downregulated in AD[73] and

Downloaded from www.aappublications.org/news by guest on October 1, 2018

patients with filaggrin deficiency.[70] Because barrier dysfunction is a key pathogenic factor for AD, this model provides a novel barrier-sensing mechanism that contributes to the pathogenesis of AD.

Additionally, ILC2s proliferate in response to elevations in thymic stromal lymphopoietin (TSLP), a pro-inflammatory cytokine produced by epithelial cells in response to stress[74] found at increased levels in AD skin lesions.[75] TSLP selectively increases basophil hematopoiesis and promotes peripheral basophilia.[76] These basophils subsequently release IL-4, causing ILC2s to proliferate in an IL-4–dependent manner.[77,78] ILC2s release IL-5 and IL-13, further contributing to the upregulated Th2 response observed in AD. IL-13 also upregulates TSLP release by keratinocytes, creating a positive feedback loop for the worsening of AD.[79] However, the role of ILC2s specifically in AD pathogenesis is poorly understood and in the early stages of investigation. Further characterization of the mechanisms of AD-related immune dysfunction will aid the development of future therapeutics.

MANAGEMENT

AD is often managed successfully in the pediatric primary care setting with topical agents, but recalcitrant disease has been historically difficult to address because of a lack of approved second-line therapies for AD.[80] However, great strides have been made recently in the development of treatments for AD.

Basic Management

The basic management of AD has not changed significantly in recent years, still centering around gentle skin care and the prevention of disease exacerbation.[7,81] Skin hydration and liberal use of moisturizers is essential for all patients with AD both during flares and for maintenance, because skin barrier disruption in this disease results in xerosis and increased transepidermal water loss.[82] Adequate moisturization significantly decreases AD symptoms, including pruritus[83] and lichenification,[84] and decreases the amount of prescription medications needed for treatment.[85–87] In fact, applying moisturizer to neonates with a family history of AD reduces the risk of future development of the disease[88,89] and should be considered for patients at high risk of developing atopic disease.

Trigger avoidance is also important to prevent recurrent symptoms or disease worsening. A careful history should be taken to characterize relationships between suspected triggers and skin symptoms. Age can be used to guide the discussion of likely triggers (ie, younger children are more likely to have a food allergy than older children, who are more often triggered by aeroallergens).[90] Indiscriminate allergy testing without a history that suggests allergic triggers is not recommended, because these tests have low positive predictive values.[90] Skin-prick or specific immunoglobulin E testing should only be done when there is a high clinical suspicion of allergy-induced dermatitis.[90] If patients are found to have trigger-induced disease exacerbation, trigger avoidance can greatly decrease the frequency and severity of flares.[90]

Acute management of AD is largely focused on controlling pruritus, which is responsible for significant QoL impairment. Acute flares are often managed with topical therapies, but oral antihistamines may provide additional benefit in certain situations.[91] Nonsedating antihistamines are not recommended for routine treatment of AD, but short-term use of first-generation antihistamines such as diphenhydramine, in combination with topical therapies, may be helpful for patients with sleep loss secondary to itch because of their sedative effect.[91] Young patients should be monitored for paradoxic excitation, a sign of antihistamine toxicity that occurs at higher rates in children.[92,93] Sedating therapies should only be used short-term,[94] because long-term use can be detrimental to school performance.[95,96]

Although their clinical evidence is conflicting,[97] bleach baths are recommended for patients with moderate-to-severe AD with signs of secondary bacterial infection because of their presumed antistaphylococcal and antiseptic properties.[82] These may also be useful for maintenance treatment of patients suffering from recurrent infections to decrease bacterial colonization and the risk of secondary skin infection and to improve disease severity.[7,24,98] These patients should bathe twice weekly in 0.005% sodium hypochlorite (~0.5 cups of 6% bleach in a full bathtub of water [~40 gal])[24] but may use bleach baths daily if they have severe disease.[7] Intranasal mupirocin and sodium hypochlorite cleansers may provide additional benefit,[24,99] but consensus guidelines for these have not yet been developed.[100]

Vigilant skin care and trigger avoidance may often be sufficient for patients with mild disease, but patients with symptoms not adequately managed by these measures require further pharmacologic interventions, including topical and systemic agents.[82]

Topical Therapies

The recommended first-line pharmacologic therapy for AD continues to be TCSs,[81,82,101] which have proven to be effective for children over several decades. However, TCS phobia remains a significant concern for patients[102] and providers,[103] and is a significant source of treatment nonadherence.[102,104] AD persists on average for 6.1 years and can be active well into adulthood for some

Downloaded from www.aappublications.org/news by guest on October 1, 2018

patients,[105,106] so physicians often fear long-term TCS effects such as skin atrophy, striae development, or systemic effects. This has resulted in an increased use of second-line treatments, such as the topical calcineurin inhibitors (TCIs) tacrolimus and pimecrolimus, in the management of pediatric AD.[107] However, TCIs are associated with increased rates of burning sensations and pruritus and have higher costs, with no additional benefit over TCSs with respect to long-term safety or efficacy.[101] Thus, TCSs, when used appropriately, are a safe and effective first-line option for the treatment of pediatric AD.[82,108]

As the underlying mechanisms of AD have become better understood, new topical therapies have been developed for AD, most notably crisaborole. Crisaborole is a topical phosphodiesterase-4 (PDE-4) inhibitor approved in 2016 for the treatment of mild-to-moderate AD for patients ≥2 years of age.[109] PDE-4 inhibition inhibits intracellular cyclic adenosine monophosphate degradation, ultimately decreasing pro-inflammatory cytokine release via downregulation of the nuclear factor kappa-light-chain-enhancer of activated B cells pathway.[110] Two phase III trials revealed that nearly one-third of patients using twice-daily crisaborole therapy for 28 days demonstrated Investigator's Static Global Assessment of clear or almost clear with at least a 2-grade improvement from baseline, significantly more than patients applying vehicle ointment (AD-301: 32.8% vs 25.4%; $P = .038$; AD-302: 31.4% vs 18.0%; $P < .001$).[110] Notably, crisaborole is well tolerated by patients in the short-term[110] and the long-term (48 weeks).[111] Application-site burning and/or stinging was experienced by 4.4% of patients in the first 4 weeks,[110] with decreased incidence over time.[111] A far greater proportion of patients experience stinging in the authors' clinical experience, but crisaborole still provides a fairly well-tolerated, albeit expensive, nonsteroidal alternative to TCSs and TCIs for the management of mild-to-moderate adult and pediatric AD (Fig 1).

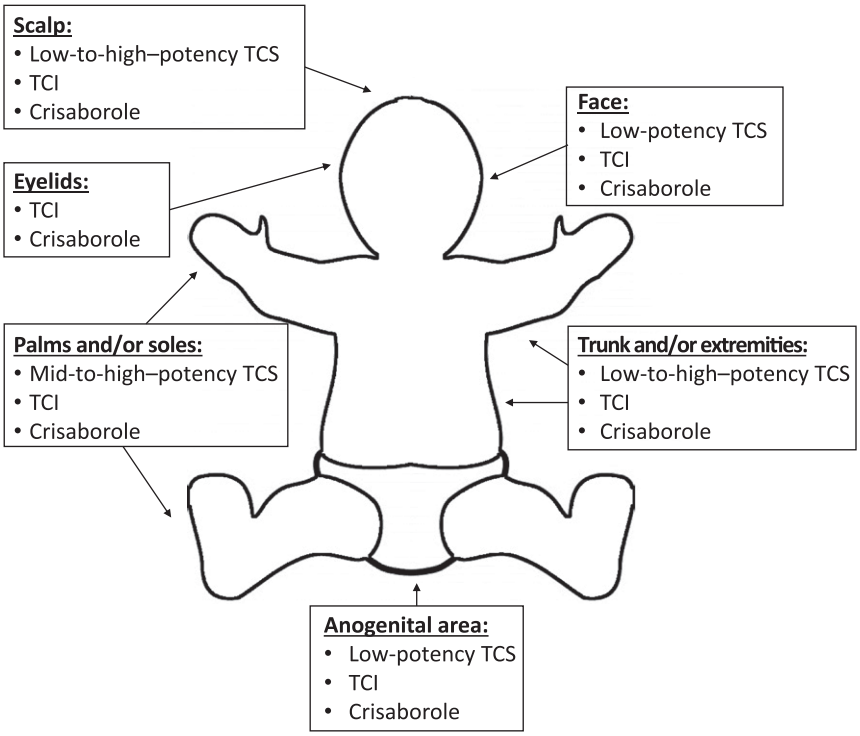

FIGURE 1
Guide to site-based topical therapies for AD. (Adapted with permission from Bhutani T, Kamangar F, Cordoro KM. Management of pediatric psoriasis. *Pediatr Ann.* 2012;41[1]:e13.)

Several other topical PDE-4 inhibitors have completed phase II studies and have revealed efficacy for AD.[112,113] An ointment preparation of tofacitinib, a Janus kinase inhibitor, also significantly improved AD severity and pruritus in a phase II trial.[114] Other topical agents being investigated for AD include toll-like receptor antagonists, serotonin inhibitors, aryl hydrocarbon receptor agonists, and leukotriene antagonists.[115–117] Clinical trials are currently ongoing to investigate the efficacy and safety of crisaborole for patients 3 months to 2 years in age (NCT03356977).

Topical Therapy Considerations

Safe usage of topical therapies requires a careful and deliberate approach. Patients generally should be treated with the least potent TCS that is effective, to minimize the risk of TCS-related side effects.[82] TCSs have greater penetration in sensitive and occluded areas such as the face, neck, and skin folds, so lower potency or nonsteroidal agents should be used in these areas to decrease the risk of systemic corticosteroid absorption (Fig 1).[118] Long-term use of high-potency TCSs should be avoided in pediatric patients, because of the increased risk of atrophy and striae as patients grow.[118] Because AD often persists for years, long-term maintenance management should alternate TCSs with nonsteroidal agents such as TCIs or crisaborole as appropriate to reduce the risk of treatment-related side effects.

Another important consideration in selecting topical therapies is vehicle choice. Children notoriously have poor adherence to topical medications,[119] so physicians must prescribe treatments their patients will actually tolerate and

Downloaded from www.aappublications.org/news by guest on October 1, 2018

TABLE 1 Off-label Systemic Therapies for the Treatment of AD in Children

Drug	Dose	Side Effects	Monitoring
Azathioprine	1–4 mg/kg per d	Myelosuppression, nausea, vomiting, hepatotoxicity	Baseline TPMT levels, CBC, CMP
Cyclosporine	2.5–6 mg/kg	Hypertension, renal insufficiency	CBC, CMP, Mg^{2+}, uric acid, lipids, blood pressure
Dupilumab	2–4 mg/kg[a]	Conjunctivitis, injection-site reactions	None
Methotrexate	0.2–0.7 mg/kg per wk	Nausea, ulcerative stomatitis, hepatotoxicity, myelosuppression	CBC, CMP
Mycophenolate mofetil	20–50 mg/kg daily	Nausea, vomiting, abdominal cramping	CBC, CMP

CBC, complete blood count; CMP, complete metabolic panel; Mg^{2+}, magnesium ion; TPMT, thiopurine methyltransferase.
[a] The dose used in the phase 2a trial is not currently approved for pediatric use.

use. Ointments are considered the most efficacious vehicle because of their occlusive nature and are well tolerated by infants and young children.[120] However, adolescents often dislike the greasy feel and thus avoid using ointments during the daytime.[118] Physicians must aim to optimize treatment adherence and may compromise by recommending nighttime ointment use while suggesting daytime application of thinner vehicles, such as creams or lotions.[118] However, choosing topical therapies requires a personalized approach, and vehicle selection should be evaluated on a case-by-case basis.

Systemic Therapies

Because of a historic lack of safe and efficacious options, the threshold for considering the initiation of systemic therapies has traditionally been high.[121] UV-B phototherapy is a safe and effective treatment, without increased skin cancer risk, for patients with AD uncontrolled by topical agents.[91,121–123] However, phototherapy can be inconvenient, requiring 2 to 3 treatments per week for several months. Patients deriving minimal benefit from phototherapy should consider systemic therapy. Traditionally, azathioprine, cyclosporine, methotrexate, and mycophenolate were the only systemic therapies that were efficacious for recalcitrant AD,[121] but these therapies are associated with potentially serious side effects and require close monitoring (Table 1). Because these medications are not frequently used by pediatricians in the outpatient setting, physicians may be hesitant in using them to treat patients with pediatric AD.

Despite these potential side effects, the "cost of not treating" should be a key consideration in selecting treatment for patients. AD is often thought of as "just a skin disease," but it is also associated with significant comorbidity and QoL deficits, as discussed previously. This disease typically affects patients during critical stages of development, and abnormal development may ultimately cause lifelong impairment. Pediatric providers must be mindful of these considerations when deciding the optimal course of therapy for their patients. Fortunately, more targeted biological therapies are in development for AD that will create more safe and effective systemic therapies for this disease.[121]

One such biological therapy is dupilumab, a human monoclonal immunoglobulin G4 antibody targeting *IL-4Rα* that was approved in 2017 for the treatment of moderate-to-severe AD for adults.[124] Dupilumab inhibits IL-4- and IL-13-mediated inflammatory responses, because the *IL-4Rα* subunit is shared by the receptor complexes for both of these cytokines. Two phase III trials revealed that more than one-third of patients on dupilumab monotherapy every 2 weeks for 16 weeks demonstrated Investigator's Global Assessment (IGA) of clear or almost clear with at least a 2-grade improvement from baseline, significantly more than patients receiving the placebo (Study of Dupilumab Monotherapy Administered to Adult Patients With Moderate-to-Severe Atopic Dermatitis 1 [SOLO1]: 37.9% vs 10.3%; SOLO2: 36.1% vs 8.5%).[125] Dupilumab use was associated with an increased risk of conjunctivitis (4%–5% of patients) and injection-site reactions (8%–14%) over the placebo.[125]

Topical therapies can be combined with dupilumab for additional benefit and to treat patients with recalcitrant disease. In the phase III trial LIBERTY AD CHRONOS, 38.7% of patients receiving combination therapy with both twice-weekly dupilumab and TCS achieved an IGA of 0 or 1 at week 16 with a ≥2-grade improvement from baseline, as compared with 12.4% of patients using only TCS.[126] This response with combination therapy persisted through week 52, with 36.0% of patients receiving combination therapy achieving this same end point, as compared with just 12.5% of patients in the control group.[126] Additionally, combination therapy with TCS and twice-weekly dupilumab therapy improved disease severity in patients not responding to cyclosporine, with 40.2% achieving an IGA of 0 or1 with a ≥2-grade improvement at week 16 as compared with 13.9% on TCS alone in the phase III LIBERTY AD CAFÉ trial.[127] Patients receiving combination therapy demonstrated no increased risk of serious adverse events over TCS monotherapy but still yielded an increased risk of conjunctivitis and injection-site

Downloaded from www.aappublications.org/news by guest on October 1, 2018

reactions, consistent with the results of SOLO1 and SOLO2.[126,127]

Dupilumab is currently only approved for adults, but investigations into its use for pediatric indications are currently ongoing (NCT02407756, NCT02612454, NCT03054428, NCT03345914). Various other biological therapies for AD have revealed promising results in phase II trials, including interleukin 12 and interleukin 23 inhibitor ustekinumab,[128] IL-13 inhibitors lebrikizumab[129] and tralokinumab,[130] interleukin 22 inhibitor fezakinumab,[131] and oral Janus kinase inhibitor baricitinib.[132] Several other promising therapies are still in the early stages of investigation and include PDE-4 inhibitor apremilast, interleukin 17A inhibitor secukinumab, TSLP inhibitor tezepelumab, and neurokinin-1 inhibitor serlopitant.[130] As AD is increasingly considered to be a systemic disease, a diverse range of safe, effective systemic therapies will be critical in the management of this disease.

CONCLUSIONS

Despite its high prevalence, AD has historically been poorly understood, resulting in a paucity of approved treatment options for this burdensome disease. However, several important recent advances have been made to increase our understanding of the mechanisms and physiology of this complex multifactorial disease. The approval of crisaborole and dupilumab for the treatment of AD marks the beginning of an exciting new era, with several other novel therapeutic options on the horizon.

The landscape of AD is rapidly evolving. Perceptions of the burden of this disease, as well as guidelines for the optimal treatment approach for patients, have changed drastically over the past decade. It is now apparent that AD extends beyond cutaneous manifestations to impair sleep,[40,41] social function,[46] school performance,[54] and overall development.[52] As such, the treatment paradigm for AD is shifting, and considering deficits beyond physical symptoms is recommended when developing treatment plans.[121] The management of affected patients will likely continue to progress in the coming years as the underlying mechanisms of this disease become better understood and new therapies become available. Primary pediatric care providers must stay aware of these updates, because they are the go-to provider for most patients with AD and will continue to be the first-line defense against this burdensome disease.

ABBREVIATIONS

AD: atopic dermatitis
IGA: Investigator's Global Assessment
IL-4: interleukin 4
IL-5: interleukin 5
IL-13: interleukin 13
ILC2: type 2 innate lymphoid cell
PDE-4: phosphodiesterase-4
QoL: quality of life
SOLO1: Study of Dupilumab Monotherapy Administered to Adult Patients With Moderate-to-Severe Atopic Dermatitis
SOLO2: Study of Dupilumab [REGN668/SAR231893] Monotherapy Administered to Adult Patients With Moderate-to-Severe Atopic Dermatitis
TCI: topical calcineurin inhibitor
TCS: topical corticosteroid
Th1: T helper 1
Th2: T helper 2
Th17: T helper 17
Th22: T helper 22
TSLP: thymic stromal lymphopoietin

REFERENCES

1. Shaw TE, Currie GP, Koudelka CW, Simpson EL. Eczema prevalence in the United States: data from the 2003 National Survey of Children's Health. *J Invest Dermatol*. 2011;131(1):67–73
2. Flohr C, Mann J. New insights into the epidemiology of childhood atopic dermatitis. *Allergy*. 2014;69(1):3–16
3. Jackson KD, Howie LD, Akinbami LJ. Trends in allergic conditions among children: United States, 1997-2011. *NCHS Data Brief*. 2013;(121):1–8
4. Asher MI, Montefort S, Björkstén B, et al; ISAAC Phase Three Study Group. Worldwide time trends in the prevalence of symptoms of asthma, allergic rhinoconjunctivitis, and eczema in childhood: ISAAC Phases One and Three repeat multicountry cross-sectional surveys. *Lancet*. 2006;368(9537):733–743
5. Saavedra JM, Boguniewicz M, Chamlin S, et al. Patterns of clinical management of atopic dermatitis in infants and toddlers: a survey of three physician specialties in the United States. *J Pediatr*. 2013;163(6):1747–1753
6. Totri CR, Diaz L, Eichenfield LF. 2014 update on atopic dermatitis in children. *Curr Opin Pediatr*. 2014;26(4):466–471
7. Eichenfield LF, Boguniewicz M, Simpson EL, et al. Translating atopic dermatitis management guidelines into practice for primary care providers. *Pediatrics*. 2015;136(3):554–565
8. Blome C, Radtke MA, Eissing L, Augustin M. Quality of life in patients with atopic dermatitis: disease burden, measurement, and treatment benefit. *Am J Clin Dermatol*. 2016;17(2):163–169
9. Rudikoff D, Lebwohl M. Atopic dermatitis. *Lancet*. 1998;351(9117):1715–1721
10. Roduit C, Frei R, Depner M, et al; the PASTURE Study Group. Phenotypes of atopic dermatitis depending on the timing of onset and progression in childhood. *JAMA Pediatr*. 2017;171(7):655–662
11. Eichenfield LF, Tom WL, Chamlin SL, et al. Guidelines of care for the management of atopic dermatitis:

Downloaded from www.aappublications.org/news by guest on October 1, 2018

section 1. Diagnosis and assessment of atopic dermatitis. *J Am Acad Dermatol*. 2014;70(2):338–351

12. Williams HC, Burney PG, Pembroke AC, Hay RJ. The U.K. Working Party's diagnostic criteria for atopic dermatitis. III. Independent hospital validation. *Br J Dermatol*. 1994;131(3):406–416
13. Krakowski AC, Eichenfield LF, Dohil MA. Management of atopic dermatitis in the pediatric population. *Pediatrics*. 2008;122(4):812–824
14. Bantz SK, Zhu Z, Zheng T. The atopic march: progression from atopic dermatitis to allergic rhinitis and asthma. *J Clin Cell Immunol*. 2014;5(2):202
15. Dharmage SC, Lowe AJ, Matheson MC, Burgess JA, Allen KJ, Abramson MJ. Atopic dermatitis and the atopic march revisited. *Allergy*. 2014;69(1):17–27
16. Dharma C, Lefebvre DL, Tran MM, et al; CHILD Study Investigators. Patterns of allergic sensitization and atopic dermatitis from 1 to 3 years: effects on allergic diseases. *Clin Exp Allergy*. 2018;48(1):48–59
17. Martin PE, Eckert JK, Koplin JJ, et al; HealthNuts Study Investigators. Which infants with eczema are at risk of food allergy? Results from a population-based cohort. *Clin Exp Allergy*. 2015;45(1):255–264
18. Du Toit G, Roberts G, Sayre PH, et al; LEAP Study Team. Randomized trial of peanut consumption in infants at risk for peanut allergy. *N Engl J Med*. 2015;372(9):803–813
19. Fleischer DM, Sicherer S, Greenhawt M, et al; LEAP Study Team. Consensus communication on early peanut introduction and the prevention of peanut allergy in high-risk infants. *Pediatrics*. 2015;136(3):600
20. Togias A, Cooper SF, Acebal ML, et al. Addendum guidelines for the prevention of peanut allergy in the United States: report of the National Institute of Allergy and Infectious Diseases-Sponsored Expert Panel. *Pediatr Dermatol*. 2017;34(1):e1–e21
21. Gupta D. Atopic dermatitis: a common pediatric condition and its evolution in adulthood. *Med Clin North Am*. 2015;99(6):1269–1285, xii
22. Sun D, Ong PY. Infectious complications in atopic dermatitis. *Immunol Allergy Clin North Am*. 2017;37(1):75–93
23. Ong PY, Ohtake T, Brandt C, et al. Endogenous antimicrobial peptides and skin infections in atopic dermatitis. *N Engl J Med*. 2002;347(15):1151–1160
24. Huang JT, Abrams M, Tlougan B, Rademaker A, Paller AS. Treatment of Staphylococcus aureus colonization in atopic dermatitis decreases disease severity. *Pediatrics*. 2009;123(5). Available at: www.pediatrics.org/cgi/content/full/123/5/e808
25. Silverberg JI, Becker L, Kwasny M, Menter A, Cordoro KM, Paller AS. Central obesity and high blood pressure in pediatric patients with atopic dermatitis. *JAMA Dermatol*. 2015;151(2):144–152
26. Zhang A, Silverberg JI. Association of atopic dermatitis with being overweight and obese: a systematic review and metaanalysis. *J Am Acad Dermatol*. 2015;72(4):606–616.e4
27. Brunner PM, Suárez-Fariñas M, He H, et al. The atopic dermatitis blood signature is characterized by increases in inflammatory and cardiovascular risk proteins [published correction appears in *Sci Rep*. 2018;8(1):8439]. *Sci Rep*. 2017;7(1):8707
28. Silverberg JI, Greenland P. Eczema and cardiovascular risk factors in 2 US adult population studies. *J Allergy Clin Immunol*. 2015;135(3):721–728.e6
29. Kwa MC, Silverberg JI. Association between inflammatory skin disease and cardiovascular and cerebrovascular co-morbidities in US adults: analysis of nationwide inpatient sample data. *Am J Clin Dermatol*. 2017;18(6):813–823
30. Silverberg JI. Association between adult atopic dermatitis, cardiovascular disease, and increased heart attacks in three population-based studies. *Allergy*. 2015;70(10):1300–1308
31. Silverberg JI, Paller AS. Association between eczema and stature in 9 US population-based studies. *JAMA Dermatol*. 2015;151(4):401–409
32. Silverberg JI. Association between childhood atopic dermatitis, malnutrition, and low bone mineral density: a US population-based study. *Pediatr Allergy Immunol*. 2015;26(1):54–61
33. Wu CY, Lu YY, Lu CC, Su YF, Tsai TH, Wu CH. Osteoporosis in adult patients with atopic dermatitis: a nationwide population-based study. *PLoS One*. 2017;12(2):e0171667
34. Drury KE, Schaeffer M, Silverberg JI. Association between atopic disease and anemia in US children. *JAMA Pediatr*. 2016;170(1):29–34
35. Yaghmaie P, Koudelka CW, Simpson EL. Mental health comorbidity in patients with atopic dermatitis. *J Allergy Clin Immunol*. 2013;131(2):428–433
36. Strom MA, Fishbein AB, Paller AS, Silverberg JI. Association between atopic dermatitis and attention deficit hyperactivity disorder in U.S. children and adults. *Br J Dermatol*. 2016;175(5):920–929
37. Yu SH, Silverberg JI. Association between atopic dermatitis and depression in US adults. *J Invest Dermatol*. 2015;135(12):3183–3186
38. Beattie PE, Lewis-Jones MS. A comparative study of impairment of quality of life in children with skin disease and children with other chronic childhood diseases. *Br J Dermatol*. 2006;155(1):145–151
39. Kiebert G, Sorensen SV, Revicki D, et al. Atopic dermatitis is associated with a decrement in health-related quality of life. *Int J Dermatol*. 2002;41(3):151–158
40. Dahl RE, Bernhisel-Broadbent J, Scanlon-Holdford S, Sampson HA, Lupo M. Sleep disturbances in children with atopic dermatitis. *Arch Pediatr Adolesc Med*. 1995;149(8):856–860
41. Eckert L, Gupta S, Amand C, Gadkari A, Mahajan P, Gelfand JM. Impact of atopic dermatitis on health-related quality of life and productivity in adults in the United States: an analysis using the National Health and Wellness Survey. *J Am Acad Dermatol*. 2017;77(2):274–279.e3
42. Su JC, Kemp AS, Varigos GA, Nolan TM. Atopic eczema: its impact on the family

Downloaded from www.aappublications.org/news by guest on October 1, 2018

and financial cost. *Arch Dis Child*. 1997;76(2):159–162

43. Fishbein AB, Mueller K, Kruse L, et al. Sleep disturbance in children with moderate/severe atopic dermatitis: a case-control study. *J Am Acad Dermatol*. 2018;78(2):336–341

44. Reid P, Lewis-Jones MS. Sleep difficulties and their management in preschoolers with atopic eczema. *Clin Exp Dermatol*. 1995;20(1):38–41

45. McCann D, Bull R, Winzenberg T. Sleep deprivation in parents caring for children with complex needs at home: a mixed methods systematic review. *J Fam Nurs*. 2015;21(1):86–118

46. Lewis-Jones S. Quality of life and childhood atopic dermatitis: the misery of living with childhood eczema. *Int J Clin Pract*. 2006;60(8):984–992

47. Beattie PE, Lewis-Jones MS. An audit of the impact of a consultation with a paediatric dermatology team on quality of life in infants with atopic eczema and their families: further validation of the Infants' Dermatitis Quality of Life Index and Dermatitis Family Impact score. *Br J Dermatol*. 2006;155(6):1249–1255

48. Roosta N, Black DS, Peng D, Riley LW. Skin disease and stigma in emerging adulthood: impact on healthy development. *J Cutan Med Surg*. 2010;14(6):285–290

49. Zuberbier T, Orlow SJ, Paller AS, et al. Patient perspectives on the management of atopic dermatitis. *J Allergy Clin Immunol*. 2006;118(1):226–232

50. Chamlin SL, Frieden IJ, Williams ML, Chren MM. Effects of atopic dermatitis on young American children and their families. *Pediatrics*. 2004;114(3):607–611

51. Magin P, Adams J, Heading G, Pond D, Smith W. Experiences of appearance-related teasing and bullying in skin diseases and their psychological sequelae: results of a qualitative study. *Scand J Caring Sci*. 2008;22(3):430–436

52. Brenninkmeijer EE, Legierse CM, Sillevis Smitt JH, Last BF, Grootenhuis MA, Bos JD. The course of life of patients with childhood atopic dermatitis. *Pediatr Dermatol*. 2009;26(1):14–22

53. Anderson RT, Rajagopalan R. Effects of allergic dermatosis on health-related quality of life. *Curr Allergy Asthma Rep*. 2001;1(4):309–315

54. Sibbald C, Drucker AM. Patient burden of atopic dermatitis. *Dermatol Clin*. 2017;35(3):303–316

55. Drucker AM, Wang AR, Li WQ, Sevetson E, Block JK, Qureshi AA. The burden of atopic dermatitis: summary of a report for the national eczema association. *J Invest Dermatol*. 2017;137(1):26–30

56. Song H, Adamson A, Mostaghimi A. Medicare part D payments for topical steroids: rising costs and potential savings. *JAMA Dermatol*. 2017;153(8):755–759

57. Filanovsky MG, Pootongkam S, Tamburro JE, Smith MC, Ganocy SJ, Nedorost ST. The financial and emotional impact of atopic dermatitis on children and their families. *J Pediatr*. 2016;169:284–290.e5

58. Liang Y, Chang C, Lu Q. The genetics and epigenetics of atopic dermatitis-filaggrin and other polymorphisms. *Clin Rev Allergy Immunol*. 2016;51(3):315–328

59. Pellerin L, Henry J, Hsu CY, et al. Defects of filaggrin-like proteins in both lesional and nonlesional atopic skin. *J Allergy Clin Immunol*. 2013;131(4):1094–1102

60. Esaki H, Brunner PM, Renert-Yuval Y, et al. Early-onset pediatric atopic dermatitis is T_H2 but also T_H17 polarized in skin. *J Allergy Clin Immunol*. 2016;138(6):1639–1651

61. Kelleher M, Dunn-Galvin A, Hourihane JO, et al. Skin barrier dysfunction measured by transepidermal water loss at 2 days and 2 months predates and predicts atopic dermatitis at 1 year. *J Allergy Clin Immunol*. 2015;135(4):930–935.e1

62. Gasparoni A, Ciardelli L, Avanzini A, et al. Age-related changes in intracellular TH1/TH2 cytokine production, immunoproliferative T lymphocyte response and natural killer cell activity in newborns, children and adults. *Biol Neonate*. 2003;84(4):297–303

63. Czarnowicki T, Esaki H, Gonzalez J, et al. Early pediatric atopic dermatitis shows only a cutaneous lymphocyte antigen (CLA)(+) TH2/TH1 cell imbalance, whereas adults acquire CLA(+) TH22/TC22 cell subsets. *J Allergy Clin Immunol*. 2015;136(4):941–951.e3

64. Noda S, Suárez-Fariñas M, Ungar B, et al. The Asian atopic dermatitis phenotype combines features of atopic dermatitis and psoriasis with increased TH17 polarization. *J Allergy Clin Immunol*. 2015;136(5):1254–1264

65. Suárez-Fariñas M, Dhingra N, Gittler J, et al. Intrinsic atopic dermatitis shows similar TH2 and higher TH17 immune activation compared with extrinsic atopic dermatitis. *J Allergy Clin Immunol*. 2013;132(2):361–370

66. Thepen T, Langeveld-Wildschut EG, Bihari IC, et al. Biphasic response against aeroallergen in atopic dermatitis showing a switch from an initial TH2 response to a TH1 response in situ: an immunocytochemical study. *J Allergy Clin Immunol*. 1996;97(3):828–837

67. Gittler JK, Shemer A, Suárez-Fariñas M, et al. Progressive activation of T(H)2/T(H)22 cytokines and selective epidermal proteins characterizes acute and chronic atopic dermatitis. *J Allergy Clin Immunol*. 2012;130(6):1344–1354

68. Suárez-Fariñas M, Tintle SJ, Shemer A, et al. Nonlesional atopic dermatitis skin is characterized by broad terminal differentiation defects and variable immune abnormalities. *J Allergy Clin Immunol*. 2011;127(4):954–964.e1–e4

69. Czarnowicki T, Esaki H, Gonzalez J, et al. Alterations in B-cell subsets in pediatric patients with early atopic dermatitis. *J Allergy Clin Immunol*. 2017;140(1):134–144.e9

70. Salimi M, Barlow JL, Saunders SP, et al. A role for IL-25 and IL-33-driven type-2 innate lymphoid cells in atopic dermatitis. *J Exp Med*. 2013;210(13):2939–2950

71. Kim BS, Siracusa MC, Saenz SA, et al. TSLP elicits IL-33-independent innate lymphoid cell responses to promote skin inflammation. *Sci Transl Med*. 2013;5(170):170ra16

72. Imai Y, Yasuda K, Sakaguchi Y, et al. Skin-specific expression of IL-33

Downloaded from www.aappublications.org/news by guest on October 1, 2018

activates group 2 innate lymphoid cells and elicits atopic dermatitis-like inflammation in mice. *Proc Natl Acad Sci USA*. 2013;110(34):13921–13926

73. Trautmann A, Altznauer F, Akdis M, et al. The differential fate of cadherins during T-cell-induced keratinocyte apoptosis leads to spongiosis in eczematous dermatitis. *J Invest Dermatol*. 2001;117(4):927–934

74. Liu YJ. Thymic stromal lymphopoietin: master switch for allergic inflammation. *J Exp Med*. 2006;203(2):269–273

75. Soumelis V, Reche PA, Kanzler H, et al. Human epithelial cells trigger dendritic cell mediated allergic inflammation by producing TSLP. *Nat Immunol*. 2002;3(7):673–680

76. Siracusa MC, Saenz SA, Hill DA, et al. TSLP promotes interleukin-3-independent basophil haematopoiesis and type 2 inflammation. *Nature*. 2011;477(7363):229–233

77. Kim BS, Wang K, Siracusa MC, et al. Basophils promote innate lymphoid cell responses in inflamed skin. *J Immunol*. 2014;193(7):3717–3725

78. Mashiko S, Mehta H, Bissonnette R, Sarfati M. Increased frequencies of basophils, type 2 innate lymphoid cells and Th2 cells in skin of patients with atopic dermatitis but not psoriasis. *J Dermatol Sci*. 2017;88(2):167–174

79. Zheng T, Oh MH, Oh SY, Schroeder JT, Glick AB, Zhu Z. Transgenic expression of interleukin-13 in the skin induces a pruritic dermatitis and skin remodeling. *J Invest Dermatol*. 2009;129(3):742–751

80. Paller AS, Kabashima K, Bieber T. Therapeutic pipeline for atopic dermatitis: end of the drought? *J Allergy Clin Immunol*. 2017;140(3):633–643

81. Schneider L, Tilles S, Lio P, et al. Atopic dermatitis: a practice parameter update 2012. *J Allergy Clin Immunol*. 2013;131(2):295–299.e1–e27

82. Eichenfield LF, Tom WL, Berger TG, et al. Guidelines of care for the management of atopic dermatitis: section 2. Management and treatment of atopic dermatitis with topical therapies. *J Am Acad Dermatol*. 2014;71(1):116–132

83. Angelova-Fischer I, Neufang G, Jung K, Fischer TW, Zillikens D. A randomized, investigator-blinded efficacy assessment study of stand-alone emollient use in mild to moderately severe atopic dermatitis flares. *J Eur Acad Dermatol Venereol*. 2014;28(suppl 3):9–15

84. Korting HC, Schöllmann C, Cholcha W, Wolff L; Collaborative Study Group. Efficacy and tolerability of pale sulfonated shale oil cream 4% in the treatment of mild to moderate atopic eczema in children: a multicentre, randomized vehicle-controlled trial. *J Eur Acad Dermatol Venereol*. 2010;24(10):1176–1182

85. Grimalt R, Mengeaud V, Cambazard F; Study Investigators' Group. The steroid-sparing effect of an emollient therapy in infants with atopic dermatitis: a randomized controlled study. *Dermatology*. 2007;214(1):61–67

86. Msika P, De Belilovsky C, Piccardi N, Chebassier N, Baudouin C, Chadoutaud B. New emollient with topical corticosteroid-sparing effect in treatment of childhood atopic dermatitis: SCORAD and quality of life improvement. *Pediatr Dermatol*. 2008;25(6):606–612

87. Tan WP, Suresh S, Tey HL, Chiam LY, Goon AT. A randomized double-blind controlled trial to compare a triclosan-containing emollient with vehicle for the treatment of atopic dermatitis. *Clin Exp Dermatol*. 2010;35(4):e109–e112

88. Horimukai K, Morita K, Narita M, et al. Application of moisturizer to neonates prevents development of atopic dermatitis. *J Allergy Clin Immunol*. 2014;134(4):824–830.e6

89. Simpson EL, Chalmers JR, Hanifin JM, et al. Emollient enhancement of the skin barrier from birth offers effective atopic dermatitis prevention. *J Allergy Clin Immunol*. 2014;134(4):818–823

90. Sidbury R, Tom WL, Bergman JN, et al. Guidelines of care for the management of atopic dermatitis: section 4. Prevention of disease flares and use of adjunctive therapies and approaches. *J Am Acad Dermatol*. 2014;71(6):1218–1233

91. Sidbury R, Davis DM, Cohen DE, et al; American Academy of Dermatology. Guidelines of care for the management of atopic dermatitis: section 3. Management and treatment with phototherapy and systemic agents. *J Am Acad Dermatol*. 2014;71(2):327–349

92. Cheng KL, Dwyer PN, Amsden GW. Paradoxic excitation with diphenhydramine in an adult. *Pharmacotherapy*. 1997;17(6):1311–1314

93. Schad CA, Skoner DP. Antihistamines in the pediatric population: achieving optimal outcomes when treating seasonal allergic rhinitis and chronic urticaria. *Allergy Asthma Proc*. 2008;29(1):7–13

94. Bender BG, McCormick DR, Milgrom H. Children's school performance is not impaired by short-term administration of diphenhydramine or loratadine. *J Pediatr*. 2001;138(5):656–660

95. Vuurman EF, van Veggel LM, Uiterwijk MM, Leutner D, O'Hanlon JF. Seasonal allergic rhinitis and antihistamine effects on children's learning. *Ann Allergy*. 1993;71(2):121–126

96. Vuurman EF, van Veggel LM, Sanders RL, Muntjewerff ND, O'Hanlon JF. Effects of semprex-D and diphenhydramine on learning in young adults with seasonal allergic rhinitis. *Ann Allergy Asthma Immunol*. 1996;76(3):247–252

97. Chopra R, Vakharia PP, Sacotte R, Silverberg JI. Efficacy of bleach baths in reducing severity of atopic dermatitis: a systematic review and meta-analysis. *Ann Allergy Asthma Immunol*. 2017;119(5):435–440

98. Wong SM, Ng TG, Baba R. Efficacy and safety of sodium hypochlorite (bleach) baths in patients with moderate to severe atopic dermatitis in Malaysia. *J Dermatol*. 2013;40(11):874–880

99. Ryan C, Shaw RE, Cockerell CJ, Hand S, Ghali FE. Novel sodium hypochlorite cleanser shows clinical response and excellent acceptability in the treatment of atopic dermatitis. *Pediatr Dermatol*. 2013;30(3):308–315

100. Eichenfield LF, Ahluwalia J, Waldman A, Borok J, Udkoff J, Boguniewicz M. Current guidelines for the evaluation and management of atopic

Downloaded from www.aappublications.org/news by guest on October 1, 2018

dermatitis: a comparison of the joint task force practice parameter and American Academy of Dermatology guidelines. *J Allergy Clin Immunol*. 2017;139(4S):S49–S57

101. Broeders JA, Ahmed Ali U, Fischer G. Systematic review and meta-analysis of randomized clinical trials (RCTs) comparing topical calcineurin inhibitors with topical corticosteroids for atopic dermatitis: a 15-year experience. *J Am Acad Dermatol*. 2016;75(2):410–419.e3

102. Li AW, Yin ES, Antaya RJ. Topical corticosteroid phobia in atopic dermatitis: a systematic review. *JAMA Dermatol*. 2017;153(10):1036–1042

103. Paller AS, McAlister RO, Doyle JJ, Jackson A. Perceptions of physicians and pediatric patients about atopic dermatitis, its impact, and its treatment. *Clin Pediatr (Phila)*. 2002;41(5):323–332

104. Charman CR, Morris AD, Williams HC. Topical corticosteroid phobia in patients with atopic eczema. *Br J Dermatol*. 2000;142(5):931–936

105. Kim JP, Chao LX, Simpson EL, Silverberg JI. Persistence of atopic dermatitis (AD): a systematic review and meta-analysis. *J Am Acad Dermatol*. 2016;75(4):681–687.e11

106. Margolis JS, Abuabara K, Bilker W, Hoffstad O, Margolis DJ. Persistence of mild to moderate atopic dermatitis. *JAMA Dermatol*. 2014;150(6):593–600

107. Horii KA, Simon SD, Liu DY, Sharma V. Atopic dermatitis in children in the United States, 1997-2004: visit trends, patient and provider characteristics, and prescribing patterns. *Pediatrics*. 2007;120(3). Available at: www.pediatrics.org/cgi/content/full/120/3/e527

108. Callen J, Chamlin S, Eichenfield LF, et al. A systematic review of the safety of topical therapies for atopic dermatitis. *Br J Dermatol*. 2007;156(2):203–221

109. EUCRISA. *(crisaborole) [package insert]*. New York City, NY: Pfizer Inc; 2016

110. Paller AS, Tom WL, Lebwohl MG, et al. Efficacy and safety of crisaborole ointment, a novel, nonsteroidal phosphodiesterase 4 (PDE4) inhibitor for the topical treatment of atopic dermatitis (AD) in children and adults [published correction appears in *J Am Acad Dermatol*. 2017;76(4):777]. *J Am Acad Dermatol*. 2016;75(3):494–503.e6

111. Eichenfield LF, Call RS, Forsha DW, et al. Long-term safety of crisaborole ointment 2% in children and adults with mild to moderate atopic dermatitis. *J Am Acad Dermatol*. 2017;77(4):641–649.e5

112. Ohba F, Matsuki S, Imayama S, et al. Efficacy of a novel phosphodiesterase inhibitor, E6005, in patients with atopic dermatitis: an investigator-blinded, vehicle-controlled study. *J Dermatolog Treat*. 2016;27(5):467–472

113. Hanifin JM, Ellis CN, Frieden IJ, et al. OPA-15406, a novel, topical, nonsteroidal, selective phosphodiesterase-4 (PDE4) inhibitor, in the treatment of adult and adolescent patients with mild to moderate atopic dermatitis (AD): a phase-II randomized, double-blind, placebo-controlled study. *J Am Acad Dermatol*. 2016;75(2):297–305

114. Bissonnette R, Papp KA, Poulin Y, et al. Topical tofacitinib for atopic dermatitis: a phase IIa randomized trial. *Br J Dermatol*. 2016;175(5):902–911

115. Edwards T, Patel NU, Blake A, et al. Insights into future therapeutics for atopic dermatitis [published correction appears in *Expert Opin Pharmacother*. 2018;19(9):1041]. *Expert Opin Pharmacother*. 2018;19(3):265–278

116. Udkoff J, Waldman A, Ahluwalia J, Borok J, Eichenfield LF. Current and emerging topical therapies for atopic dermatitis. *Clin Dermatol*. 2017;35(4):375–382

117. Nygaard U, Deleuran M, Vestergaard C. Emerging treatment options in atopic dermatitis: topical therapies. *Dermatology*. 2017;233(5):333–343

118. Bhutani T, Kamangar F, Cordoro KM. Management of pediatric psoriasis. *Pediatr Ann*. 2012;41(1):e1–e7

119. Krejci-Manwaring J, Tusa MG, Carroll C, et al. Stealth monitoring of adherence to topical medication: adherence is very poor in children with atopic dermatitis. *J Am Acad Dermatol*. 2007;56(2):211–216

120. Tollefson MM, Bruckner AL; Section on Dermatology. Atopic dermatitis: skin-directed management. *Pediatrics*. 2014;134(6). Available at: www.pediatrics.org/cgi/content/full/134/6/e1735

121. Simpson EL, Bruin-Weller M, Flohr C, et al. When does atopic dermatitis warrant systemic therapy? Recommendations from an expert panel of the International Eczema Council. *J Am Acad Dermatol*. 2017;77(4):623–633

122. Lee E, Koo J, Berger T. UVB phototherapy and skin cancer risk: a review of the literature. *Int J Dermatol*. 2005;44(5):355–360

123. Hearn RM, Kerr AC, Rahim KF, Ferguson J, Dawe RS. Incidence of skin cancers in 3867 patients treated with narrow-band ultraviolet B phototherapy. *Br J Dermatol*. 2008;159(4):931–935

124. DUPIXENT. *(dupilumab) [package insert]*. Tarrytown, NY: Regeneron Pharmaceuticals, Inc; Bridgewater, NJ: sanofi-aventis US LLC; 2017

125. Simpson EL, Bieber T, Guttman-Yassky E, et al; SOLO 1 and SOLO 2 Investigators. Two phase 3 trials of dupilumab versus placebo in atopic dermatitis. *N Engl J Med*. 2016;375(24):2335–2348

126. Blauvelt A, de Bruin-Weller M, Gooderham M, et al. Long-term management of moderate-to-severe atopic dermatitis with dupilumab and concomitant topical corticosteroids (LIBERTY AD CHRONOS): a 1-year, randomised, double-blinded, placebo-controlled, phase 3 trial. *Lancet*. 2017;389(10086):2287–2303

127. de Bruin-Weller M, Thaçi D, Smith CH, et al. Dupilumab with concomitant topical corticosteroid treatment in adults with atopic dermatitis with an inadequate response or intolerance to ciclosporin A or when this treatment is medically inadvisable: a placebo-controlled, randomized phase III clinical trial (LIBERTY AD CAFÉ). *Br J Dermatol*. 2018;178(5):1083–1101

128. Khattri S, Brunner PM, Garcet S, et al. Efficacy and safety of ustekinumab

Downloaded from www.aappublications.org/news by guest on October 1, 2018

treatment in adults with moderate-to-severe atopic dermatitis. *Exp Dermatol*. 2017;26(1):28–35

129. Simpson EL, Flohr C, Eichenfield LF, et al. Efficacy and safety of lebrikizumab (an anti-IL-13 monoclonal antibody) in adults with moderate-to-severe atopic dermatitis inadequately controlled by topical corticosteroids: a randomized, placebo-controlled phase II trial (TREBLE). *J Am Acad Dermatol*. 2018;78(5):863–871.e11

130. Nygaard U, Vestergaard C, Deleuran M. Emerging treatment options in atopic dermatitis: systemic therapies. *Dermatology*. 2017;233(5):344–357

131. Guttman-Yassky E, Brunner PM, Neumann AU, et al. Efficacy and safety of fezakinumab (an IL-22 monoclonal antibody) in adults with moderate-to-severe atopic dermatitis inadequately controlled by conventional treatments: a randomized, double-blind, phase 2a trial. *J Am Acad Dermatol*. 2018;78(5):872–881.e6

132. Guttman-Yassky E, Silverberg JI, Nemoto O, et al. Baricitinib in adult patients with moderate-to-severe atopic dermatitis: a phase 2 parallel, double-blinded, randomized placebo-controlled multiple-dose study [published online ahead of print February 1, 2018]. *J Am Acad Dermatol*. doi:10.1016/j.jaad.2018.01.018

Downloaded from www.aappublications.org/news by guest on October 1, 2018

Recent Developments in Atopic Dermatitis

Eric J. Yang, Sahil Sekhon, Isabelle M. Sanchez, Kristen M. Beck and Tina Bhutani

Pediatrics 2018;142;
DOI: 10.1542/peds.2018-1102 originally published online September 28, 2018;

Updated Information & Services	including high resolution figures, can be found at: http://pediatrics.aappublications.org/content/142/4/e20181102
References	This article cites 130 articles, 13 of which you can access for free at: http://pediatrics.aappublications.org/content/142/4/e20181102#BIBL
Subspecialty Collections	This article, along with others on similar topics, appears in the following collection(s): **Dermatology** http://www.aappublications.org/cgi/collection/dermatology_sub **Allergy/Immunology** http://www.aappublications.org/cgi/collection/allergy:immunology_sub **Immunologic Disorders** http://www.aappublications.org/cgi/collection/immunologic_disorders_sub
Permissions & Licensing	Information about reproducing this article in parts (figures, tables) or in its entirety can be found online at: http://www.aappublications.org/site/misc/Permissions.xhtml
Reprints	Information about ordering reprints can be found online: http://www.aappublications.org/site/misc/reprints.xhtml

American Academy of Pediatrics
DEDICATED TO THE HEALTH OF ALL CHILDREN™

Downloaded from www.aappublications.org/news by guest on October 1, 2018

PEDIATRICS®
OFFICIAL JOURNAL OF THE AMERICAN ACADEMY OF PEDIATRICS

Recent Developments in Atopic Dermatitis

Eric J. Yang, Sahil Sekhon, Isabelle M. Sanchez, Kristen M. Beck and Tina Bhutani

Pediatrics 2018;142;
DOI: 10.1542/peds.2018-1102 originally published online September 28, 2018;

The online version of this article, along with updated information and services, is located on the World Wide Web at:
http://pediatrics.aappublications.org/content/142/4/e20181102

Pediatrics is the official journal of the American Academy of Pediatrics. A monthly publication, it has been published continuously since 1948. Pediatrics is owned, published, and trademarked by the American Academy of Pediatrics, 141 Northwest Point Boulevard, Elk Grove Village, Illinois, 60007. Copyright © 2018 by the American Academy of Pediatrics. All rights reserved. Print ISSN: 1073-0397.

American Academy of Pediatrics
DEDICATED TO THE HEALTH OF ALL CHILDREN™

Downloaded from www.aappublications.org/news by guest on October 1, 2018