Annales de dermatologie et de vénéréologie 148 (2021) 256–258

Available online at
ScienceDirect
www.sciencedirect.com

Elsevier Masson France
EM|consulte
www.em-consulte.com/en

Letter to the editor

Is it safe to vaccinate within a tattoo?

ARTICLE INFO

Keywords:
Tattoos
Tattooing
Vaccination
COVID-19
SARS-CoV-2

Mass vaccination against SARS-CoV-2 has begun worldwide [1]. By February 16, 184 million individuals had already received their first vaccine shot [1]. COVID-19 vaccination requires two intramuscular injections, which are traditionally performed in adults in the upper arm, within the deltoid muscle [2,3]. Currently, 18% of the adult population in Western countries have ≥ 1 tattoo, up to one adult out of three in the United States [4]. Shoulders are a fairly popular location for tattoos, especially for men [5,6]. It is therefore not uncommon for the deltoid area to be covered by a tattoo. The lack of evidence or rationale for avoiding injection within a tattoo is mentioned in Canada and on US vaccination websites [7,8]. However, the question whether an individual can have a vaccination shot within a tattoo is recurrent on the Internet and social media. Some health-care professionals acknowledge avoiding tattoos because of the risk of tissue entrapment or dissemination in the blood stream (personal data). Although no specific studies have specifically evaluated the impact of vaccination within a tattoo, this letter aims to clarify some concerns.

Fear of entrapment of tattoo pigments and chemical arachnoiditis were first reported 18 years ago with regard to epidural analgesia within a lumbar tattoo in parturient women [9]. However, this phenomenon has never been observed in humans, and experimental rabbit models failed to show pigment deposition [10–12]. The number of such procedures in the presence of tattoo is not known and we lack any prospective follow-up studies, but there is still not a single convincing case of complications after epidural administration of analgesia within a tattoo [13]. Until very recently, neurologists had never published any similar concerns with lumbar punctures in tattoos [14]. However, a study by nephrologists was recently published concerning potential risks of tattoos on arteriovenous dialysis access in patients with chronic kidney diseases [15]. The authors suggested avoiding tattooed areas in clinical practice as site of vascular access "in order to prevent possible infections due to repeated punctures in each hemodialysis session. Moreover, reasonable doubts arise about the correct realization of vascular access within a preexisting tattooed area". There is no evidence that puncturing repeatedly tattooed skin exposes subjects to a higher risk of infection than use of plain skin. Lastly, the author is aware about concerns and sometimes refusal regarding venipuncture within a tattoo (personal data). In this context, it is highly likely that concerns will be raised by health-care providers, nurses especially, during this unprecedented massive COVID-19 vaccination campaign.

Tattoo pigments reside permanently in the dermis. Ink particles are found in fibroblasts, in macrophages, or are free within collagen bundles [16,17]. Infections within tattoos are mostly the consequence of direct inoculation during tattooing or during the healing phase [18]. Anecdotal cases of delayed warts (and molluscum contagiosum) within tattoos point to possible impairment of local immunity in previously HPV-infected skin area by various factors related to tattooing, that may lead to a reactivation within the tattooed skin [19]. However, no studies have evaluated whether a healed tattoo may impair the vaccination efficacy. Numerous experiments have evaluated the risk of needles carrying cells or fragments of epidermal tissues during epidural/spinal analgesia, named tissue coring, because of the risk of squamous cell-tumors [20,21]. Studies have also been conducted during other procedures because of the risk of local infection [22]. The risk of tissue coring in case of subcutaneous (25-26 gauge) or intramuscular (21–22 gauge) vaccination has never been assessed but does not seem to have any relevance, as coring would involve deposition of tissue in fat or in muscle. The risk of introducing tattoo pigments into the blood circulation is rhetorical: if blood-borne distribution of tattoo ink in the body is a possibility, it has already occurred when the tattoo was being done [23]. To the best of our knowledge, no complication has been reported to date after vaccination within a tattoo. A young military recruit who received a smallpox vaccine had a tattoo placed directly over his inoculation site 4 days after vaccination [24]. He developed signs of smallpox on the area. According to Carius et al., thirteen cases of tattoo and smallpox inoculation complications have been reported in the Vaccine Adverse Events Reporting System database in the last 15 years. Current US Army Public Health Command (USAPHC) guidance recommends no new tattoos for 30 days post-inoculation, although the Military Vaccine Agency notes that this period may be extended to a window of greater than 60 days on a case-by-case basis [24].

To conclude, fears by some health-care providers are related to their own misconceptions about tattoos and tattoo-associated complications and possibly to a negative opinion about tattoos [25]. We agree that it is more comfortable for everyone to avoid a tattoo when performing a vaccine shot, if possible. No vaccination should be performed on a recent fresh tattoo, which is still healing (less than a one month). No tattoos should be performed on the same area right after a vaccination, especially in the case of live attenuated vaccines. Based on the data in hand, we suggest the following recommendation in case of vaccination to help health-care providers and patients to choose the best solution (Figs. 1 and 2).

https://doi.org/10.1016/j.annder.2021.04.008
0151-9638/© 2021 Elsevier Masson SAS. All rights reserved.

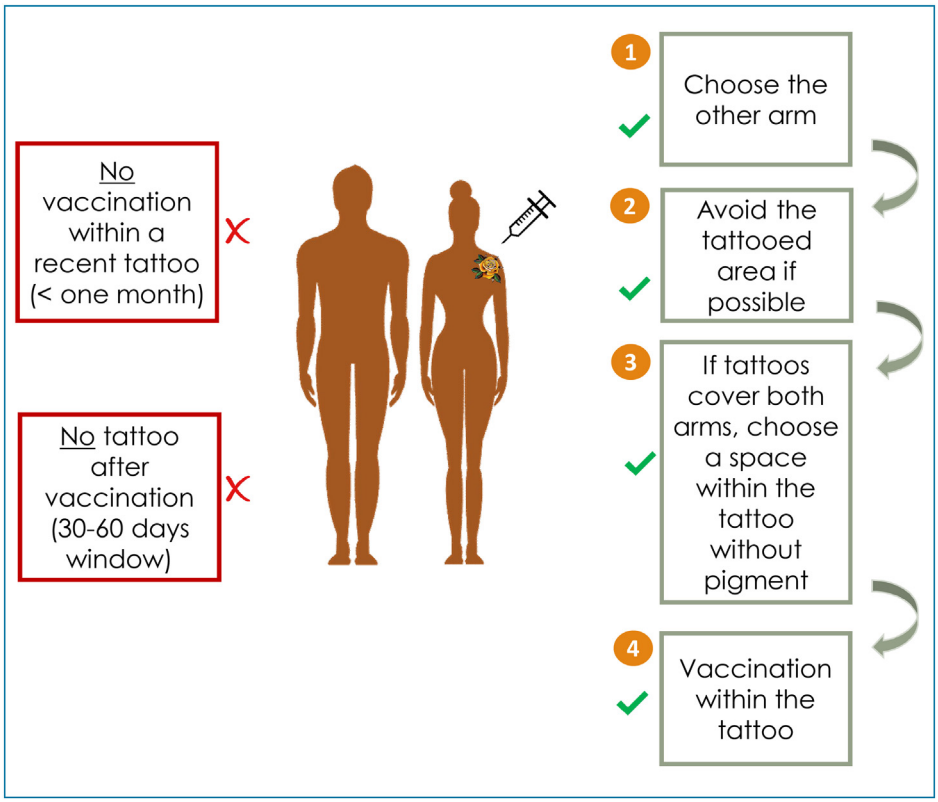

Fig. 1. Recommendations in case of a tattoo within a vaccination area. The choices 1–4 are based on a discussion between the patient and the health-care professional that performs the injection. In case of a tattoo on only one deltoid, would the patient accept the injection on the other arm? (1) If no, can the tattoo lines be avoided? (2,3). If no, the professional can vaccinate through the tattoo (4).

Fig. 2. The author gets his influenza vaccination every year in an area without visible pigment, but within his tattoo. On May the 10th, he got his first BNT1262b mRNA COVID-19 vaccine shot within the eye of the owl witout notable side effect.

Funding

None.

Disclosure of interest

The author declares that he has no competing interest.

References

[1] Our World in Data. COVID-19 vaccination doses administered. https://ourworldindata.org/grapher/cumulative-covid-vaccinations.[accessed 17 February 2021].
[2] Oliver SE, Gargano JW, Marin M, Wallace M, Curran KG, Chamberland M, et al. The advisory committee on immunization practices' interim recommendation for use of moderna COVID-19 vaccine – United States, December 2020. MMWR Morb Mortal Wkly Rep 2021;69:1653–6.
[3] Tanne JH. COVID-19: FDA panel votes to approve Pfizer BioNTech vaccine. BMJ 2020;371:m4799.
[4] Kluger N, Seité S, Taieb C. The prevalence of tattooing and motivations in five major countries over the world. J Eur Acad Dermatol Venereol 2019;33:e484–6.
[5] Laumann AE, Derick AJ. Tattoos and body piercings in the United States: a national data set. J Am Acad Dermatol 2006;55:413–21.
[6] Kluger N, Misery L, Seité S, Taieb C. Tattooing: a national survey in the general population of France. J Am Acad Dermatol 2019;81:607–10.
[7] Vaccine administration practices: Canadian immunization guide; 2017 [accessed 16 Feb 2021] https://www.canada.ca/en/public-health/services/publications/healthy-living/canadian-immunization-guide-part-1-key-immunization-information/page-8-vaccine-administration-practices.html.
[8] Immunization Action Coalition. Administering vaccines; 2020 [accessed 16 Feb 2021] https://www.immunize.org/askexperts/administering-vaccines.asp.
[9] Douglas MJ, Swenerton JE. Epidural anesthesia in three parturients with lumbar tattoos: a review of possible implications. Can J Anaesth 2002;49:1057–60.
[10] Ferraz IL, Barros GA, Ferreira Neto PG, Solanki D, Marques MA, Machado VM, et al. Does spinal block through tattooed skin cause histological changes in nervous tissue and meninges? An experimental model in rabbits. Reg Anesth Pain Med 2015;40:533–8.

[11] da Silva RA, Ferraz IL, Zuza RS, Camara C, Marques MA, Machado VMV, et al. Can an inflammatory reaction in the meninges, caused by spinal puncture through tattooed skin, evolve into adhesive arachnoiditis? An experimental model in rabbits. Reg Anesth Pain Med 2019;44:355–9.
[12] Kluger N, Sleth JC. Of tattooed rabbits, parturients, and neuraxial blocks. Reg Anesth Pain Med 2016;41:419–20.
[13] Kluger N, Sleth JC. Tattoo and epidural analgesia: rise and fall of a myth. Presse Med 2020;49:104050.
[14] Henson JW. Technique for lumbar puncture through a tattoo. Neurol Clin Pract 2019;9:535.
[15] Esteve Simó V, Martínez Carnovale L, Álvarez Rodríguez L, Paredes Mariñas E, Pou Potau M, De la Torre Morán A, et al. Vascular access for hemodialysis and tattoos: a consideration to bear in mind. J Vasc Access 2017;18:e73.
[16] Sperry K. Tattoos and tattooing. Part II: gross pathology, histopathology, medical complications, and applications. Am J Forensic Med Pathol 1992;13:7–17.
[17] Kluger N, Plantier F, Moguelet P, Fraitag S. Tattoos: natural history and histopathology of cutaneous reactions. Ann Dermatol Venereol 2011;138:146–54 [quiz 144-5, 155].
[18] Kluger N. Cutaneous and systemic complications associated with tattooing. Presse Med 2016;45:567–76.
[19] Kluger N. Viral warts and seborrhoeic keratoses on tattoos: a review of nine cases. J Eur Acad Dermatol Venereol 2017;31:e340–2.
[20] Campbell DC, Douglas MJ, Taylor G. Incidence of tissue coring with the 25-gauge Quincke and Whitacre spinal needles. Reg Anesth 1996;21:582–5.
[21] Guldogus F, Baris YS, Baris S, Karakaya D, Kelsaka E. Comparing tissue coring potentials of hollow needles without stylet and caudal needles with stylet: an experimental study. Eur J Anaesthesiol 2008;25:498–501.
[22] Xu C, Peng H, Chai W, Li X, Li R, Chen J. Inadvertent introduction of tissue coring into joints during arthrocentesis: an experimental study. Med Sci Monit 2017;23:3571–7.
[23] Sepehri M, Sejersen T, Qvortrup K, Lerche CM, Serup J. Tattoo pigments are observed in the kupffer cells of the liver indicating blood-borne distribution of tattoo ink. Dermatology 2017;233:86–93.
[24] Carius BM, Dodge PM, Randles JD. Smallpox autoinoculation via tattoo in a soldier. Mil Med 2019;184:e275–9.
[25] Grodner C, Beauchet A, Kluger N, Fougerousse AC, Cinotti E, Lacarrubba F, et al. Reluctance determinants of dermatologists about tattooing in patients with psoriasis. An international study. Ann Dermatol Venereol 2020;147:809–17.

N. Kluger [a,b]
[a] *Department of Dermatology, Allergology and Venereology, University of Helsinki and Helsinki University Hospital, Meilahdentie 2, 00029 Helsinki, Finland*
[b] *"Tattoo" consultation, Department of dermatology, Bichat-Claude-Bernard Hospital, 46, rue Henri-Huchard, 75018 Paris, France*
E-mail address: nicolas.kluger@hus.fi

Received 19 January 2021

Accepted 12 April 2021
Available online 1 July 2021