[Downloaded free from http://www.cmj.org on Monday, August 17, 2015, IP: 160.80.2.38]

Integrated Therapy for Invasive Pulmonary Aspergillosis in a Patient with Asthma and Chronic Obstructive Pulmonary Disease Overlap Syndrome

Ya-Qin Shi[1], Pei Li[1], Ting Wu[1], Yuan Ding[1], Yi Shi[1], Mark E Wylam[2], Xin Su[1]

[1]Department of Respiratory and Critical Care Medicine, Jinling Hospital, Medical School of Nanjing University, Nanjing, Jiangsu 210002, China
[2]Department of Pediatric and Adolescent Medicine, Department of Internal Medicine, Mayo Clinic College of Medicine, Rochester, MN 55905, USA

To the Editor: We here present a case of invasive pulmonary aspergillosis (IPA) with asthma and chronic obstructive pulmonary disease (COPD) overlap syndrome (ACOS). The patient recently took a high dose of systemic corticosteroids. Additionally, pneumothorax occurred, prompting right upper lobectomy, which contained the majority of the *Aspergillus* lesion. Full recovery occurred utilizing a combination of surgical resection and systemic antifungal therapy. This case supports a surgical approach to clear the infection when antifungal agents are inadequate.

A 61-year-old male nonsmoker with poorly controlled asthma for 50 years developed fever, wheezing, expectoration on August 30, 2009. The total leukocyte count was 7.9×10^9/L, with neutrophils accounting for 80%. Chest radiology showed hyperinflation and mild emphysema, but no infiltrates. He was commenced on cefpiramide, inhaled budesonide and terbutaline, along with methylprednisolone (40 mg, intravenous [IV], tid) in other hospital. Afterward, the dose of methylprednisolone was increased to 80 mg, tid. Blood and sputum cultures both grew Gram-negative bacilli. With no evidence of remission, the patient was admitted to our hospital on October 1, 2009.

Pulmonary function tests showed a forced expiratory volume in 1 s (FEV_1)/forced vital capacity of 48.41%, FEV_1 of 1.37 L (41.9% of predicted), maximum ventilatory volume of 50.1 L/min (49.4%), revealing persistent airflow limitation, even when he was in stable. The bronchial test revealed positive. Using GINA or GOLD guidelines, his diagnosis was consistent with ACOS. He had ACOS exacerbations triggered by upper respiratory tract infections once a year, and corticosteroids pulses were frequently administered. He has no other past history except ACOS.

On admission, the temperature was 38.8°C, pulse 80 beats/min; blood pressure 135/80 mmHg; respiratory rate, 20 breaths/min. There was dullness to percussion of the upper right lung, diminished breath sounds and rales in both lungs. He had a decreased $CD3^+$ T-cell (490/mm^3, % predicted 50%), a $CD4^+$ T-cell (118/mm^3, % predicted 12%). Acid-fast bacilli smear test was negative. Blood and sputum cultures both grew methicillin-resistant coagulase-negative *Staphylococcus*. Blood beta-D-glucan was significantly elevated (2580 pg/ml), as well as galactomannan (2.66 pg/ml). The specific and total serum immunoglobulin E for *Aspergillus* was normal. On October 2009, chest computed tomography scans [Figure 1a and b] showed new right greater than left upper lobe infiltrates with the cavitary lesion formation.

The patient was treated empirically for asthma with IV methylprednisolone (40 mg, qd), inhaled budesonide, salbutamol, ipratropium bromide. Linezolid and imipenem were used for an anti-infection therapy. Meanwhile, the patient was commenced on IV itraconazole (ITR) (250 mg/d). On day 5 of the treatment, he defervesced. Neither acid-fast bacilli nor bacteria were detected. However, sputum culture still grew *Aspergillus fumigatus*. After 1-month of IV ITR, he was discharged with oral ITR (200 mg, bid).

On November 15, 2009, the patient was readmitted with worse wheezing, as well as hemoptysis and lower extremities edema. Chest radiology showed shrinking cavitary lesions with bilateral lung [Figure 1c and d]. Sputum cultures persisted with *Aspergillus* 2+. Combination therapy with IV voriconazole (VRZ) (200 mg/d) and Caspofungin (CAS) (50 mg/d) was used. Two weeks after therapy, the patient suddenly developed increased shortness of breath. Chest X-ray revealed right pneumothorax. Persistent bronchopleural fistula with air leak persisted in the following 2 weeks [Figure 1e and f] despite chest tube suction. Though the patient was malnourished (albumin = 31.3 g/L), he underwent successful upper right lobectomy. Postoperative histology [Figure 2] demonstrated filamentous fungus growth in lung tissue. He improved markedly after surgery. The first postoperative sputum culture was negative. After the surgery, combination therapy was continued for another 2 months and then de-escalated to oral VRZ (400 mg/d).

After 6 months' antifungal treatment, the patient reported again with cough, expectoration, and hemoptysis. Chest radiology revealed enlarged lesions in left upper lobe [Figure 1g and h]. IV VRZ (200 mg/d) and CAS (50 mg/d) were started on for 2 weeks. Symptoms significantly improved. Oral VRZ was continued for 3 months. Follow-up chest radiology showed improvement in the left upper lung [Figure 1i and j]. On August 12, 2010, oral VRZ was discontinued. The patient has had no recurrence of IPA but has periodically been treated for bacterial exacerbations of ACOS in the next 5 years.

ACOS-related deficiencies in the airway epithelial barrier create a higher opportunity for *Aspergillus* colonization.[1] Meanwhile,

Access this article online

Quick Response Code:

Website: www.cmj.org

DOI: 10.4103/0366-6999.162511

Address for correspondence: Dr. Xin Su, Department of Respiratory and Critical Care Medicine, Jinling Hospital, Medical School of Nanjing University, 305 East Zhongshan Road, Nanjing, Jiangsu 210002, China
E-Mail: suxinjs@163.com

[Downloaded free from http://www.cmj.org on Monday, August 17, 2015, IP: 160.80.2.38]

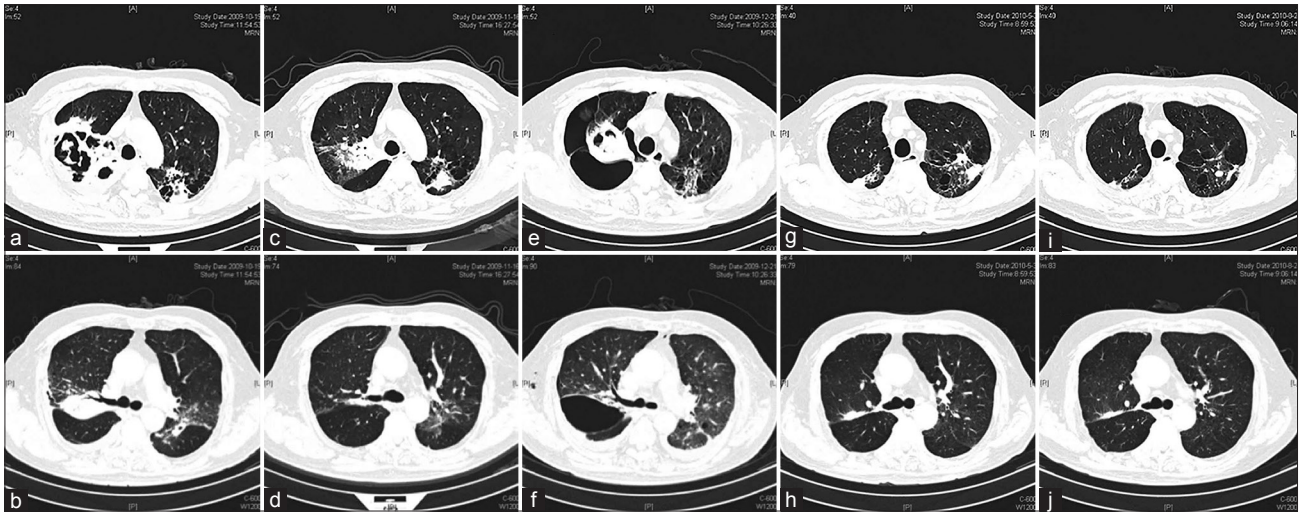

Figure 1: Axial images from chest computed tomography scan show the progression of the disease. (a and b): On October 19, 2009, shows bilateral lung infiltrations and cavitary lesions, prominently in right upper lung; (c and d): On November 16, 2009, shrinking cavitary lesions; (e and f): On December 21, 2009, unresolved pneumothorax; (g and h): On May 3, 2010, stable lesions in left upper lobe; (i and j): On August 2, lesions are mostly absorbed.

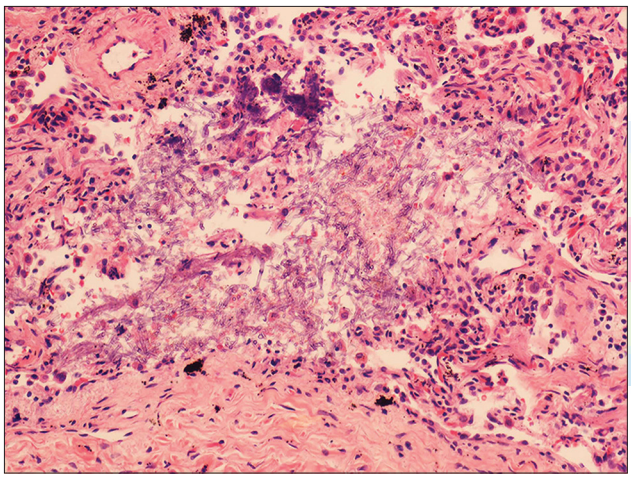

Figure 2: Histology of right upper lung shows filamentous fungus (H and E, original magnification ×200).

systemic corticosteroids pulse also disposes the patient to IPA.[2,3] Treatment for IPA remains difficult, and prompt administration of antifungal agents should be considered after a clinical suspicion of IPA. VRZ is now indicated as a standard antifungal therapy. CAS is approved as salvage therapy after intolerance or failure of conventional antifungal therapy. For the combination therapy, no enough evidence supported as primary therapy, but it can act as a salvage antifungal therapy that supported by many studies reported a decrease in mortality in IPA.[4] In this case, the patient started with ITR as primary therapy since VRZ was not covered by the medical insurance in China. Due to the unsatisfied effect of 1-month single-antifungal therapy with ITR, we changed to the combination therapy with both VRZ and CAS. Conclusively, in this case, the unique mechanisms of combination therapy provided clinical benefits for the refractory IPA. For ACOS control, the GOLD guideline recommends that it is prudent to start treatment as for asthma until further investigation has been performed to confirm the COPD diagnosis. If COPD was assessed, treatment with bronchodilators or combination therapy was suggested. The patient has severe asthma. Treatment during stable periods is inhaled corticosteroid/long-acting beta-agonist. However, due to combined COPD, the long-acting muscarinic antagonist was added to control the symptoms.

Surgery of an IPA focus is seldom used in ACOS patients due to the poor pulmonary function. However, in this case, the role of surgical lung resection cannot be ignored. While antifungal therapy is essential for IPA, often there is reduced lung tissue penetration, particularly notable with ITR, and residual lesions are often present.[5] Surgeries can potentially eradicate localized infection and simultaneously provide both a definitive diagnosis of IPA. In this case, negative fungus result was achieved in the first sputum culture after surgery, suggested that the surgery scavenged the majority of *Aspergillus* spp., thus reduced secondary dissemination. Besides, right upper lobectomy made intractable pneumothorax curable.

References

1. Holt PG, Strickland DH, Hales BJ, Sly PD. Defective respiratory tract immune surveillance in asthma: A primary causal factor in disease onset and progression. Chest 2014;145:370-8.
2. Kousha M, Tadi R, Soubani AO. Pulmonary aspergillosis: A clinical review. Eur Respir Rev 2011;20:156-74.
3. Wessolossky M, Welch VL, Sen A, Babu TM, Luke DR. Invasive *Aspergillus* infections in hospitalized patients with chronic lung disease. Infect Drug Resist 2013;6:33-9.
4. Koulenti D, Garnacho-Montero J, Blot S. Approach to invasive pulmonary aspergillosis in critically ill patients. Curr Opin Infect Dis 2014;27:174-83.
5. Felton T, Troke PF, Hope WW. Tissue penetration of antifungal agents. Clin Microbiol Rev 2014;27:68-88.

Received: 06-04-2015 **Edited by:** Li-Shao Guo
How to cite this article: Shi YQ, Li P, Wu T, Ding Y, Shi Y, Wylam ME, Su X. Integrated Therapy for Invasive Pulmonary Aspergillosis in a Patient with Asthma and Chronic Obstructive Pulmonary Disease Overlap Syndrome. Chin Med J 2015;128:2265-6.

Source of Support: This work was supported by grants from the National Natural Science Foundation of China (No. 81330035), Medical and Health Research Foundation of Nanjing Military Area Command (No. 12MA082). **Conflict of Interest:** None declared.