DOI: 10.1111/cea.13207

REVIEW

WILEY

Nasal cytology: Methodology with application to clinical practice and research

E. Heffler[1,2] | M. Landi[3,4] | C. Caruso[5] | S. Fichera[6] | F. Gani[7] | G. Guida[8] | M. T. Liuzzo[6] | M. P. Pistorio[6] | S. Pizzimenti[9] | A. M. Riccio[10] | V. Seccia[11] | M. Ferrando[1,10] | L. Malvezzi[12] | G. Passalacqua[10] | M. Gelardi[13]

[1]Department of Biomedical Sciences, Humanitas University, Milano, Italy

[2]Personalized Medicine, Asthma and Allergy Unit, Humanitas Clinical and Research Center, Humanitas University, Milano, Italy

[3]Institute of Biomedicine and Molecular Immunology, National Research Council of Italy, Palermo, Italy

[4]Paediatric National Healthcare System, Torino, Italy

[5]Allergy Unit, Fondazione Policlinico Gemelli, Presidio Columbus, Rome, Italy

[6]Respiratory Medicine and Allergy, University of Catania, Catania, Italy

[7]Respiratory Allergy, A.O.U. San Luigi, Orbassano, Torino, Italy

[8]Allergy and Lung Physiology, AO Santa Croce e Carle, Cuneo, Italy

[9]Respiratory Medicine Unit, National Health System, ASL Città di Torino, Torino, Italy

[10]Allergy and Respiratory Diseases, IRCCS Policlinico San Martino, University of Genoa, Genova, Italy

[11]1st Otorhinolaryngology Unit, Department of Medical and Surgical Pathology, Pisa University Hospital, Pisa, Italy

[12]Department of Otolaryngology, Humanitas Clinical and Research Center, Milano, Italy

[13]Section of Otolaryngology, Department of Basic Medical Science, Neuroscience and Sensory Organs, University of Bari, Bari, Italy

Correspondence
Enrico Heffler, Personalized Medicine, Asthma and Allergy Unit, Humanitas Clinical and Research Center, Humanitas University, Rozzano, Italy.
Email: heffler.enrico@gmail.com

Summary

Nasal cytology is an easy, cheap, non-invasive and point-of-care method to assess nasal inflammation and disease-specific cellular features. By means of nasal cytology, it is possible to distinguish between different inflammatory patterns that are typically associated with specific diseases (ie, allergic and non-allergic rhinitis). Its use is particularly relevant when other clinical information, such as signs, symptoms, time-course and allergic sensitizations, is not enough to recognize which of the different rhinitis phenotypes is involved; for example, it is only by means of nasal cytology that it is possible to distinguish, among the non-allergic rhinitis, those characterized by eosinophilic (NARES), mast cellular (NARMA), mixed eosinophilic-mast cellular (NARESMA) or neutrophilic (NARNE) inflammation. Despite its clinical usefulness, cheapness, non-invasiveness and easiness, nasal cytology is still underused and this is at least partially due to the fact that, as far as now, there is not a consensus or an official recommendation on its methodological issues. We here review the scientific literature about nasal cytology, giving recommendations on how to perform and interpret nasal cytology.

 © 2018 John Wiley & Sons Ltd

1 | INTRODUCTION

Over the past 20 years, advances in technology and scientific research dramatically changed the clinical approach to diagnosis and treatment of rhinitis. Specifically, in the field of rhinology, numerous diagnostic procedures (fiberoptic endoscopy, immunohistochemistry…) were introduced in clinical practice to refine the diagnostic accuracy.[1] Among these procedures, and due to the fact that nasal mucosa is can be easily accessed, nasal cytology[2,3] appears to be as an attractive and promising additional diagnostic tool, to be associated to the standard diagnostic methods. Nasal cytology represents an useful, cheap and easy-to-apply diagnostic method to better detail the phenotypic characteristics of rhinitis. In fact, it allows to detect and quantify the cell populations within the nasal mucosa at a given instant, to better discriminate the different pathological conditions and also to evaluate the effects of various stimuli (allergens, infectious, irritants, physico-chemicals) or the effect of treatments.

Despite its simplicity and proven utility in giving direction to the diagnostic study of many nasal diseases, nasal cytology paradoxically still remains underused. This may be due to the fact that current research is mainly devoted to high-tech instruments and biological treatments. For nasal cytology, the only instrument required is a standard light microscope, which costs far less than any instrument required for conducting more sophisticated studies.

Moreover, nasal cytology plays an important research role in the evaluation of effect of noxious stimuli, outcomes of treatments, effects of allergen immunotherapy and pathogenic aspects of comorbidities.[4,5] The major unmet need, so far, is its standardization to use a reproducible methodology.[6]

We here summarize the most updated evidence on methods and clinical interpretation of nasal cytology, making our recommendations for clinical routinely use.

2 | NASAL SAMPLING

There are numerous techniques to obtain an adequate specimen, each with their advantages and disadvantages.[1,7]

The most frequently used are here summarized.

2.1 | Nasal lavage

Nasal lavage implies the introduction of fluid into the nasal cavity and its recovery after a dwell time.[8,9] Nasal lavage allows the evaluation of proteins, cells, and mediators such as cytokines in the nasal cavity. Nasal lavage cannot be considered as the "gold standard" method for cytological sampling since, often, the sampled cells are in apoptotic degeneration. Therefore, we recommend the use of nasal lavage only to study nasal secretion mediators and not for cytological assessment.

2.2 | Pre-weighted sinus packs or filter papers

They are placed on the floor of the nasal cavity between the septum and the inferior turbinate for 5 minutes and then stored in a Falcon tube.[10] The sinus pack is then washed with 3 mL of 0.9% NaCl solution, placed into a syringe shaft and squeezed by moving the syringe piston. After the first pressure, the shaft containing the sinus pack is placed into a Falcon tube and centrifuged to recover all fluid. The samples are then weighted after collection to measure collected volumes and to correct measured markers for volume. This technique gives reliable results but it needs the collaboration with a fully equipped laboratory to process and read the samples, with concomitant increase in costs and time to obtain the results; therefore, we do not recommend it for clinical purpose, but for research settings.

2.3 | Direct aspiration using microsuction tubes

The samples are collected by repeated aspiration into a pre-weighted plastic sampling tube immediately followed by aspiration of a known volume (1.0 mL) of PBS containing 10% of Mesna. The direct aspiration system combines the advantage of minimal irritation of the nasal mucosa with the facility to determine concentrations per gram of secretion. We recommend the use of this method only for research purpose.

2.4 | Nasal brushing

A small nylon brush is introduced in the middle meatus of the nose and turned carefully. The brush is immediately placed in a 5 mL polystyrene plastic tube containing 5 mL of PBS and cut-off just above the bristles. The brush will be shaken vigorously in the solution and carefully brushed off against the wall of the tube.[11,12] The tubes are centrifuged at 400 *g* for 10 minutes. Nasal brushing gives information on living epithelial cells, which is an advantage over nasal lavage. It is often used to study ciliary ultrastructure, even if recent studies showed better results with less prevalence of blood-derived artefacts with nasal scraping.[13]

2.5 | Nasal scraping

It is performed with a pencil-shaped disposable nasal curette with a small distal cup (Rhinoprobe®, Nasal scraping®). The cupped tip is gently passed over the mucosal surface of the medial aspect of the inferior turbinate (Figure 1). Two or three short scrapes of the epithelial layer are made to obtain a sample. The specimen is spread onto a plain slide and air-dried. Nasal scraping give information on living epithelial cells sometimes in larger lumps[6,14,15] and it can be used to evaluate the ciliary activity if the slide is observed by a phase-contrast microscope.

2.6 | Nasal swab

It is an easy technique, mainly used in children, in whose the nasal scraping can be difficult to perform. It can be performed using a oropharyngeal swab or, in newborns, an urethral swab. Any used swab

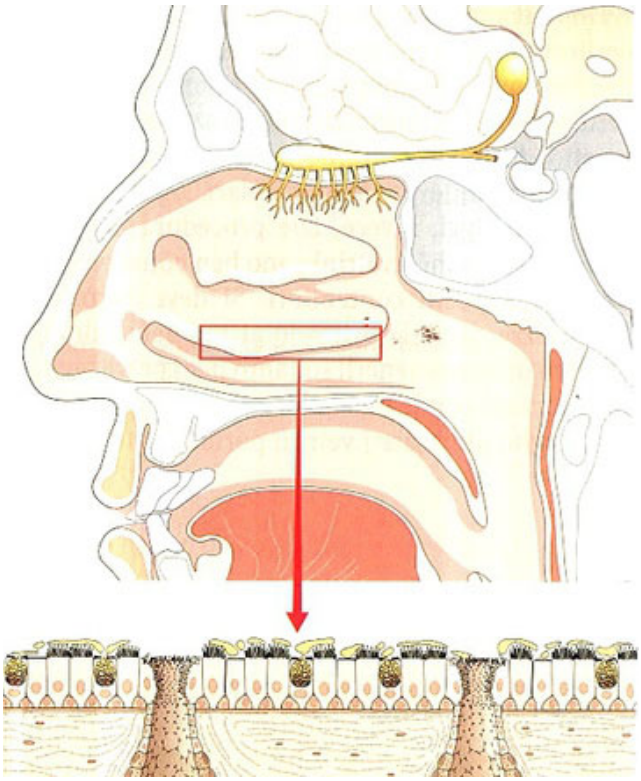

FIGURE 1 Anatomic site for nasal scraping: the mucosal surface of the medial aspect of the inferior turbinate [Colour figure can be viewed at wileyonlinelibrary.com]

should be wet in saline and then squeezed before the use; the sample should be performed at inferior turbinate level by "go-and-turn" rotation movements. Recent paediatric studies, however, showed that nasal scraping is still the preferable methods also in children.[16]

2.7 | Nasal biopsy

It is not recommendend for cytologycal purpose, while it is the gold standard for histological assessment of nasal mucosa.[17]

Considering the ease of execution, its cheapness and the quality of obtained sample, we suggest that the reference method for nasal cytology sampling for adults should be nasal scraping, while nasal swab should be reserved to newborns and children. The other methods should be reserved for specific aims (ie, assessing soluble biomarkers concentration) but are not advisable for the routine cytological assessment. Moreover, considering that the cellular infiltrate reappears about 4-6 days after stopping nasal corticosteroids, we suggest to perform nasal cytology after at least 7 days of nasal sprays (and oral corticosteroids) suspension to obtain a clearer view on the real cytological involvement.[18]

3 | SAMPLE STAINING

Data from the literature are quite homogenous and concordant about the use of May-Grünwald-Giemsa (MGG) staining[6,15,19] for its ability to correctly identify inflammatory nasal cells: in particular, MGG shows in blue the nuclei of white blood cells and the granules of basophils granulocytes, while red blood cells and eosinophils granules are red. The cytoplasm of white blood cells appears in light blue. The traditional MGG staining procedure requires about 30 minutes, but premixed compounds (eg, MGG QUICK STAIN®; Bio-Optica, Milan, Italy) are available and allow a satisfactory preparation in less than 1 minute.

4 | SAMPLE READING

The stained sample is read at optical microscopy, at 1000× magnification with oil immersion. We recommend to read at least 50 fields. The minimum number of cells counted into the 50 fields should be more than 200 to consider the sample as adequate. The count of each cell type can be expressed as a percentage of the total cells (including mucinous and ciliated cells), as an absolute value, or by a semiquantitative grading.[6] For clinical practice, we recommend a semiquantitative approach as reported in Table 1.[6]

5 | CYTOLOGICAL ASPECTS OF NORMAL NASAL MUCOSA

Microscopically, nasal mucosa consists of an epithelial layer, leaning on a thin basal membrane which separates it from "lamina propria"; this epithelium is pseudostratified and prismatic with different types of cells: columnar ciliated and not ciliated cells, muciparous goblet cells and basal epithelial cells (Figure 2, Panel A). Into the intercellular spaces, even in normal conditions, it is possible to find few lymphocytes and neutrophils.

Nasal mucosa may change according to the studied anatomical region: the most anterior part of nasal mucosa is called "nasal vestibule" and it is characterized by a squamous, stratified and keratinized epithelium; moving posteriorly, nasal mucosa consists of pseudostratified non-ciliated epithelium called "transitional epithelium," followed by a bathiprysmatic epithelium. Eventually, the remaining portion of nasal mucosa is made by ciliated columnar pseudostratified epithelium. The term "pseudostratified" means that all the cells have a direct contact with *lamina basale*, despite their nuclei are placed at different levels, giving the optical impression of a epithelium made by several layers.[20] The knowledge of the cytological features of normal nasal epithelium is useful to verify if the cytological sample has been correctly collected.[6]

Another peculiar feature of nasal epithelium is the presence of a mucous secretion entirely covering the epithelial surface, and structurally divided into 2 layers: *sol* and *gel*; the layer at contact with the epithelial surface is aqueous (*sol* phase) and it almost entirely covers the surface of respiratory cilia. Over the *sol*, there is a thick layer called "gel" mainly made by mucins, a group of glycoproteins. These 2 layers are part of the non-specific respiratory defence system deputy to decontaminate inspired air: many inspired particles remain

TABLE 1 Quantitative and semiquantitative grading of nasal cytology results[6]

	Description	Quantitative	Grading
Epithelial ciliated cells	Normal	–	N
	Abnormal	–	A (CCP/MN)
Mucinous cells	None	0	0
	Occasional	l%-24%	1+
	Moderate number	25%-49%	2+
	Large number	50%-74%	3+
	Covering the entire field	75%-100%	4+
Neutrophils and eosinophils	None	0	0
	Occasional	0.1%-1%	½+
	Few scattered cells, small clumps	1.1%-5%	1+
	Moderate number, large clumps	5%-15%	2+
	Large clumps not covering the field	15%-20%	3+
	Clumps covering entire field	>20%	4+
Basophilic (mast cells)	None	0	0
	Occasional	0.1-0.3	½+
	Few scattered cells, small clumps	0.4-1	1+
	Moderate number, large clumps	1.1-3	2+
	Large clumps not covering the field	3.1-6	3+
	Up to 25 per an ×100 field	>6	4+
Eosinophil/mast cell degranulation	None observed	Present/absent	0
	Occasional granules		1+
	Moderate number of granules		2+
	Many granules easily seen		3+
	Massive degranulation. entire field		4+
Bacteria and spores	None observed	None standardized	0
	Occasional clumps		1+
	Moderate number		2+
	Many cells easily seen		3+
	Bacteria/spores over the entire field		4+

CCP, cilioeytophthoria; MN, multinucleation.

trapped into the *gel* layer, while the *sol* layer allows the appropriate movement of cilia that contributes to move the *gel* layer towards the rhino-pharynx to be eliminated.

Main characteristics of normal nasal epithelial cells:

Ciliated cells: They represent the most differentiated and the most frequent cell type into the nasal epithelium. They generally have a polygonal shape with about 150-200 cilia at the of top a big central nucleus and a basal region which is in strict contact with basal membrane through desmosomes (Figure 2, Panel B). A perinuclear halo or *hypercromatic supernulcear stria* in ciliated cells is a hallmark of normal function,[21] and its reduction has been put in correlation with severity of vasomotor, inflammatory and infectious nasal diseases.[22,23]

Muciparous goblet cell: It is a unicellular gland interposed among the respiratory pseudostratified epithelial cells[20,24] secreting *mucin*, that in contact with water originates mucus. On its surface, there are many microvilli and a small hole, called "stoma," from which mucin granules are secreted by exocitosis. The nucleus is always put into the lower part of cellular body, while vacuoles containing mucin and mucinogenous are localized in the upper part of the cell giving it the characteristic shape of a "goblet" (Figure 2, Panel C). Goblet cells' secretions contribute to the cleansing of respiratory mucosa.

Striated cell: It is a columnar cell with the nucleus localized into its lower part; the upper portion is characterized by the presence of many microvilli containing microfilaments (Figure 2, Panel D). Its biological role is still not completely clear: it has been postulated that striated cells could be progenitors of both ciliated and goblet cells,[25] but specific studies are lacking on this topic.

Basal epithelial cell: It is smaller than the other nasal epithelial cells and it is characterized by being in contact with basal

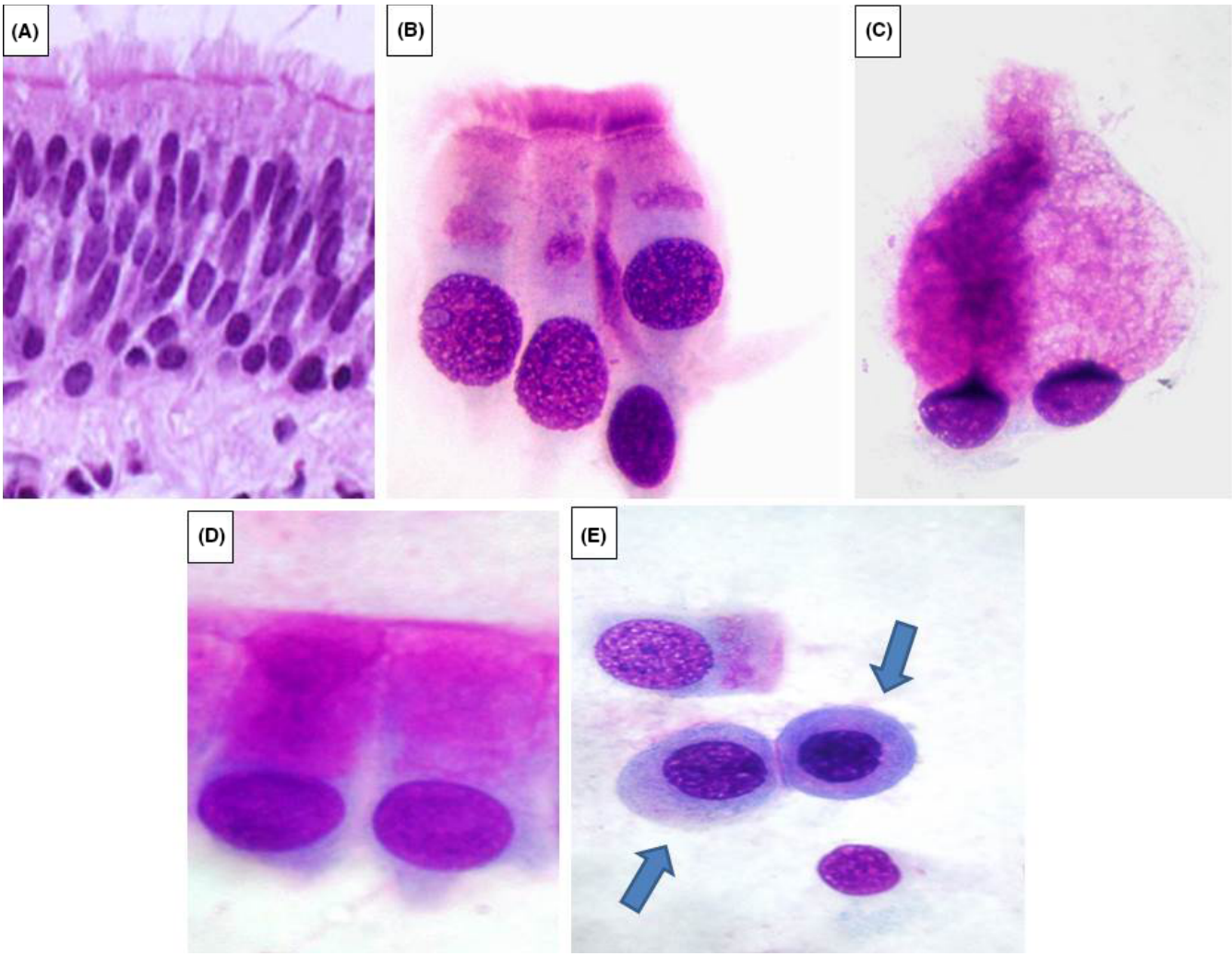

FIGURE 2 Panel A, Normal nasal mucosa (stained with May-Grunwald-Giemsa; 400×). Panel B, Ciliated cells (stained with May-Grunwald-Giemsa; 1000× with Camera Magnification Factor 2×). Panel C, Muciparous goblet cells (stained with May-Grunwald-Giemsa; 1000× with Camera Magnification Factor 2×). Panel D, Striated cells (stained with May-Grunwald-Giemsa; 1000× with Camera Magnification Factor 2×). Panel E, Basal epithelial cells (stained with May-Grunwald-Giemsa; 1000×)

membrane without reaching the surface of nasal mucosa. Its nucleus is hyperchromatic and quite big in relation to its cytoplasm (Figure 2, Panel E). As far as striated cells, also basal epithelial cells have been considered as progenitors for goblet and epithelial cells.[25]

6 | EVALUATION OF MUCOCILIARY CLEARANCE

Nasal epithelial cells can be observed in vitro, and their physiological motility, which is genetically determined, measured. Usually, the cilia propel the mucus layer by rhythmic movements, at a mean frequency of about 250 beats/min. Their rhythmic activity is constant and evaluable till 18-24 hours after death.[26]

Nasal epithelium can be obtained by means of a Rhinoprobe from the inferior or middle turbinate. The material is spread uniformly in the centre of a slide, added with 1-2 drops of physiological solution at 36°C, and covered with a cover glass. After that, an in vitro evaluation of ciliary movement is possible with a phase-contrast microscopy with ×100 objective lens in immersion. Ciliary beat frequency can be recorded and classified as: present (3-4 beats/s), hypovalid (1-2 beats/s) and absent.[26]

Epithelial cells can be evaluated for ciliary beat frequency (CBF) and the ciliary waveform analysed in detail by digital high-speed video imaging. The demonstration of normal CBF and beat pattern excludes the diagnosis of ciliary dyskinesia.

Nasal ciliary movements can be impaired in primary and secondary dyskinesia, rare autosomal syndromes and chronic rhinosinusitis (CRS).

7 | BIOFILM

Biofilm is an organized community of bacteria or fungi adherent to an inert or living surface, embedded in a self-produced extracellular

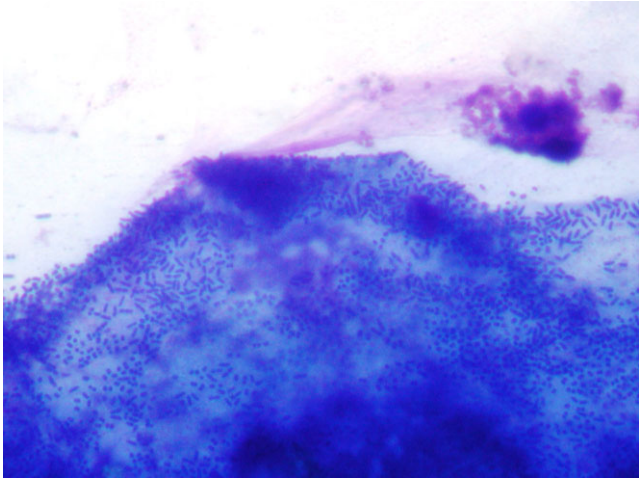

FIGURE 3 Bacterial biofilm (stained with May-Grunwald-Giemsa; 1000× with Camera Magnification Factor 2×) [Colour figure can be viewed at wileyonlinelibrary.com]

polymeric matrix (85% in volume) composed of a mixture of biopolymers, primarily polysaccharides, protein and nucleic acids. Organisms living in a biofilm are relatively protected against host defences and antimicrobial agents. In the biofilm, bacteria interact by quorum sensing, using different classes of signalling molecules; only when bacteria leave the biofilm in the planktonic form, they cause symptoms and become susceptible to host defences and antibiotics.[27] Bacterial biofilms are likely present in most difficult-to-treat CRS patients and its presence is related to a worse prognosis patients; moreover, it is believed to play a significant role in the pathophysiology of the disease and in its consequences in adjacent organs (ie, middle ear).[28] Nasal cytology, performed by optical microscopy, is able to identify biofilms on nasal mucosal surfaces. Biofilms appear cyan-stained "infectious spot," (Figure 3) whose polysaccharide nature can be confirmed by periodic acid-Schiff staining.[29]

8 | EPITHELIAL CELL MODIFICATIONS

The mucosal epithelium lining the upper and lower conducting airways provides a barrier against injury from inhaled toxins, bacteria and other biogenic agents (organic dust, pollen, mould spores, etc.). The normal respiratory epithelium is coated with mucus that lubricates, insulates and humidifies the epithelium and protects it by entrapping bacteria and other particulates for removal by mucociliary clearance.

The pathomechanisms of inflammatory airway diseases are connected to the large biological networks between the environment and the host. During development, host genetics and environmental factors can significantly modulate the barrier homeostasis, thus influencing the predilection towards chronic inflammation of the airways.[30] Moreover, the respiratory epithelium has important innate immunity functions. It also mediates parts of the innate and adaptive immunity by its antigen presentation, phagocytosis and pattern recognition abilities. These functions seem to be essentially involved in the development of human chronic upper airway disorders.[31]

Nasal epithelial repair and remodelling is a highly organized process leading to necessary self-renewal after injury.[31] Upon injury, non-differentiated basal cells migrate and proliferate into ciliated and goblet cells in injured regions. Moreover, epithelial cells may dedifferentiate through squamous metaplasia or epithelial to mesenchymal transition (EMT), which describes a rapid and normally reversible modulation of the epithelial phenotype towards mesenchymal cells.[32]

Nasal pathologies affect first ciliated cells, which are the most differentiated, with a rearrangement of the respiratory mucosal epithelium, which favours goblet cells (metaplasia mucipara). This has important pathophysiologic and clinical consequences, in fact, the decrease in the ciliated component and the proportional increase in goblet cells increases the production of mucus production and its consequent endonasal stagnation.[33] The reduced mucociliary transport is a risk factor for inflammation, because of the facilitation of bacterial infections and of vicious circles leading to repeated inflammatory events. Considering that the usual turnover of ciliated cells is about 3 weeks, recurrent inflammations prevent the recovery of the normal relationship among the different cell types in the respiratory epithelium.

Hypertrophy, hyperplasia and metaplasia of secretory cells in surface epithelium and submucosal glands associated with hypersecretion of mucus are major factors in the pathogenesis of airway inflammations such as rhinitis, sinusitis and tracheobronchitis.[34]

The increase in goblet cell numbers in the respiratory epithelium during airway inflammation has been described both as *mucous metaplasia* and as *goblet cell hyperplasia* (Figure 4) Metaplasia implies a change in cell phenotype, while hyperplasia suggests cell proliferation as the mechanism for the increase in goblet cell numbers. In human airways, a detailed analysis of the epithelial transition to a mucus-secreting phenotype has not been undertaken.[35]

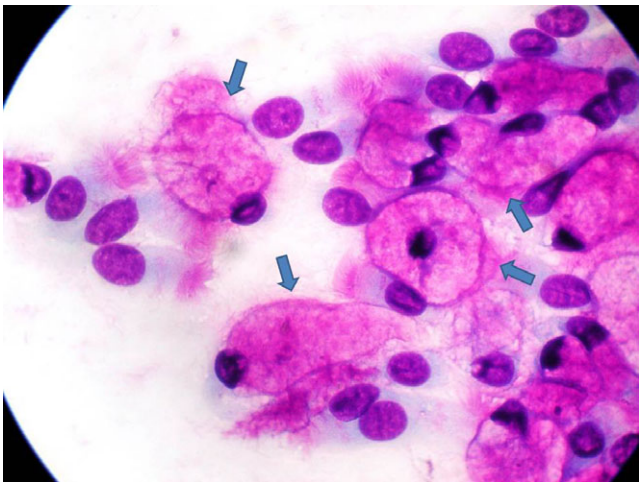

FIGURE 4 Mucous metaplasia (stained with May-Grunwald-Giemsa; 1000×) [Colour figure can be viewed at wileyonlinelibrary.com]

Besides environmental pollution, other risk factor associated with chronic rhinosinusitis is active smoking and second-hand smoke.[36] Many studies demonstrated a strong association between smoking and increased incidence of upper airway inflammatory disease in both adults and children.

Trombitas et al[37] demonstrated in a recent work that cigarette smoke induces sinonasal mucosa wound changes and delays in healing. Within the surface of epithelium, there are a progressive injuries represented initially by loss of cilia and globlet cell hyperplasia, followed by hyperplasic/dysplastic epithelium.

During ageing, nasal mucosa shows signs of atrophy with decrease in goblet cells and thickening of the basal membrane. In parallel, elasticity of nasal mucosa decreases, by part due to a decreasing level of estrogens in postmenopausal women.[38]

The effects of age on mucociliary clearance are controversial. Some studies showed no effect on mucociliary clearance,[39,40] but others were able to demonstrate a decrease in ciliary beat frequency, with an increase in saccharin transit time, as equivalent of deterioration of mucociliary clearance in old age.[41] Viscosity of nasal secretion increases and causes post-nasal drip with consecutive repeated clearing of the throat.[42]

9 | INFECTIOUS RHINITIS

Nasal cytology helps to recognize involved microorganism species (at least for bacteria and fungi) (Figure 5) and infection-related inflammatory patterns.

9.1 | Viral rhinitis

Viral rhinitis is the most frequent upper airways infectious disease and can be easily diagnosed on a clinical base. Due to their small size, viruses cannot be visualized at optical microscopic observation but cytopathic effects on nasal mucosa may be pathognomonic.

After a viral infection, the cellular infiltrate from nasal mucosa in characterized by an increased number of neutrophils and lymphocytes, within 24 hours from the infection. A morphological change in the ciliated epithelium can be seen, known as "ciliocytophthoria"; it includes a typical nuclear chromatin condensation with nuclear margination and multiple cytoplasmic vacuoles with "decapitation" of the apical portion of the ciliated cell due to the lateral confluence of cytoplasmic vacuoles (Figure 6, Panel A).

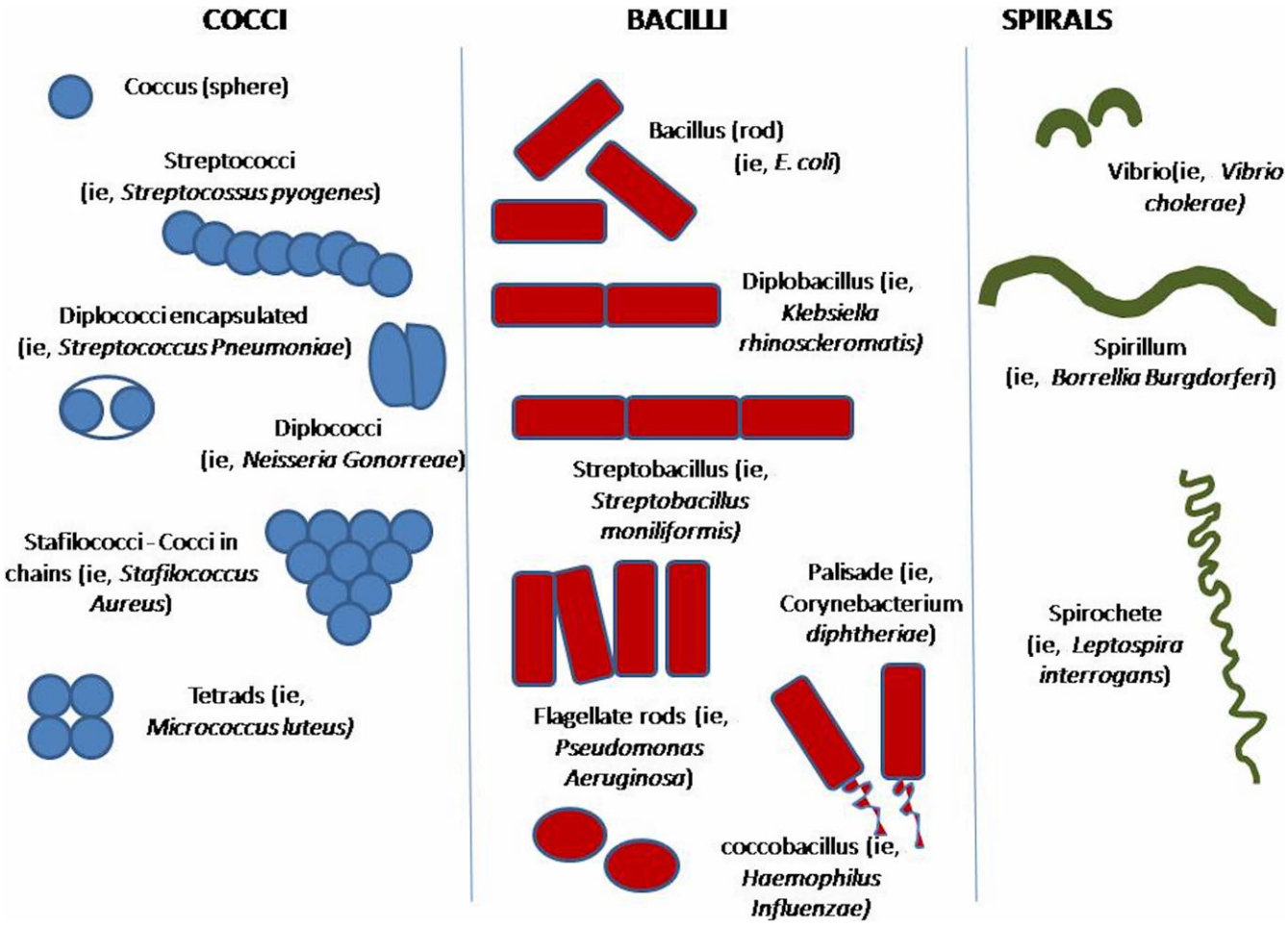

FIGURE 5 Recognizable bacterial species by means of nasal cytology [Colour figure can be viewed at wileyonlinelibrary.com]

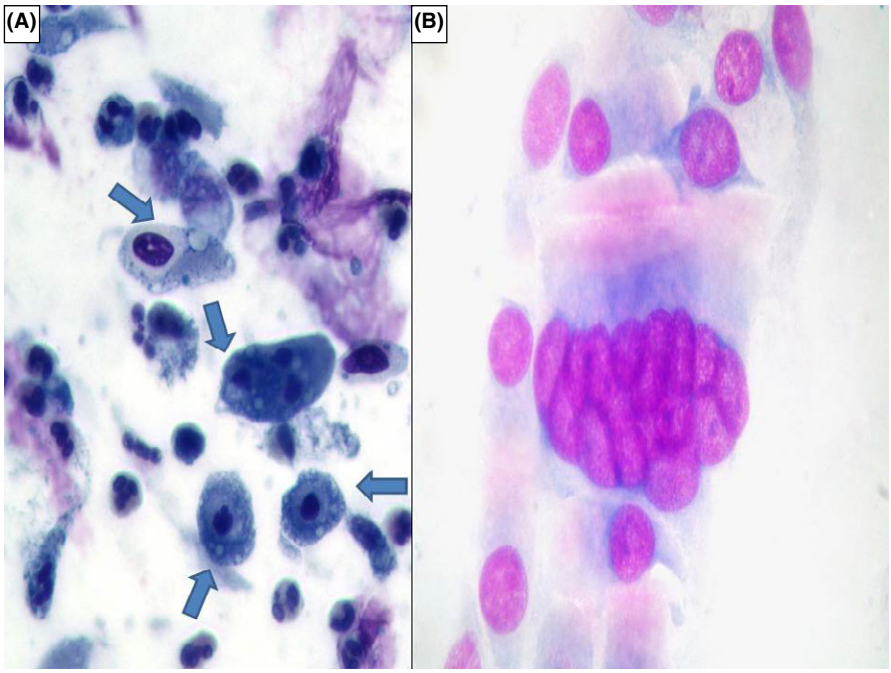

FIGURE 6 Panel A, Ciliocytophthoria. Panel B, Polynuclear cells (stained with May-Grunwald-Giemsa; 1000× with Camera Magnification Factor 1.5×) [Colour figure can be viewed at wileyonlinelibrary.com]

Other cytopathic effects are nuclear alterations such as ground glass image, syncytium of cells or polynuclear cells and inclusion bodies (Figure 6, Panel B).[6,14]

9.2 | Bacterial acute rhinosinusitis

In nasal cytology, bacterial infectious rhinosinusitis (bacterial infection always spreads to sinuses) are usually characterized by the presence of a large number of neutrophils, with intra- and extracellular bacteria that can easily identified at optical microscopy (Figure 5). Ciliated cells are significantly reduced in favour of mucinous cells and both metaplastic and platicellular cells are observed. Lymphocytes and macrophage can accompany the neutrophilic infiltrate (Figure 7).[6]

As previously reported, the observation of bacteria in the nasal passages do not provide any specific diagnostic value for the causative pathogen but can help in suggesting a superimpose bacterial role in forms of allergic/cellular non-allergic rhinitis or CRS.

9.3 | Fungal infection

A diagnosis of fungal pathology is established by combining findings on history, clinical examination, laboratory testing, imaging and histopathology. Cytologic observation in nasal scrapings may contribute to confirm the clinical suspicious. In nasal cytology, fungal rhinitis/sinusitis may be suspected through (i) identification of hyphae or yeasts with the proper stain (although not the first choice of stains for fungi, yeast cells, pseudohyphae, and fungal hyphae—they are better visualized in potassium hydroxide staining—may be easily visualized in MGG); (ii) characteristic of the inflammatory infiltrate and/or mucous/mucin secretion, that is eosinophils, mucin, neutrophils; (iii) cytopathic effects on epithelial cells that are mainly nuclear rarefaction reaching sometimes "karyorrhexis" appearance or intracellular invasion by spores or hyphae (Figure 8).

10 | ALLERGIC RHINITIS

The patient suffering from seasonal or perennial allergic rhinitis (AR), stimulated naturally or by specific nasal provocation tests, develops an immediate nasal response, so-called early phase (primarily histamine-mediated), and a late phase due to the influx of inflammatory cells.[43,44] From a microscopic point of view, the response is always characterized by a presence of inflammatory cells (eosinophils, mast cells, neutrophils and lymphocytes) in the nose, that following the release of several chemical mediators provoke the main symptoms (itching, nasal congestion, runny nose, sneezing, watery eyes, etc.).

When the allergen exposure is of low intensity, but persistent in time, as is typical of perennial rhinitis (for example by mites), it leads to a cell condition, defined as "Minimal Persistent Inflammation",[45,46] characterized by a persistent infiltration of neutrophils overall and only minimally by eosinophils, even in the absence of symptoms (Figure 9, Panel A). Mast cells and important signs of eosinophilic-mast cell degranulation are rarely found. This cellular condition is clinically translated in an absent or subchronic symptomatology, which distinguishes patients suffering from these perennial forms compared with those acutely exposed to allergens (ie, seasonal allergic rhinitis, acute occupational rhinitis, acute exposure to perennial allergens…), where the principal symptoms are nasal obstruction and rhinorrhea. Some differences are due to dust mites, however, by monitoring over time allergic patients: the eosinophilic component increases in April and October, the periods in which the dust mites have their peaks.[47]

As far as seasonal AR, the rhinocytogram will change depending on whether the patient will be examined during or off the

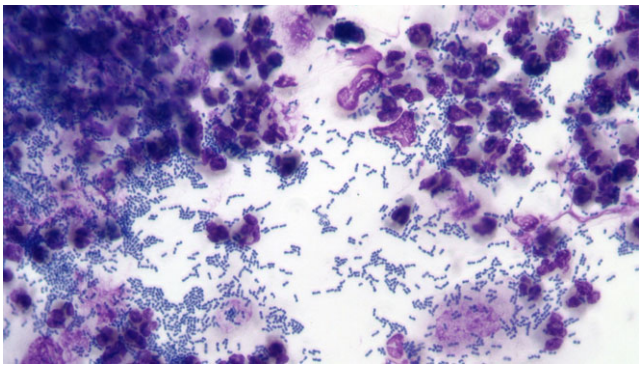

FIGURE 7 Bacterial rhinosinusitis (stained with May-Grunwald-Giemsa; 1000×) [Colour figure can be viewed at wileyonlinelibrary.com]

pollen season. In the first condition, the patient will present all the clinical signs of the disease: nasal cytology is characterized by neutrophils, lymphocytes, eosinophils and mast cells, largely degranulated (Figure 9, Panel B); conversely, if assessed out of season, the patient will clearly present a clinical and cytological "silence," especially if more than thirty days passed after the end of exposure.

An interesting fact has emerged in the course of a study[48] in which it was found that subjects with perennial rhinitis and allergic monosensitized patients present different aspects, regarding both the relative abundance of immunoflogistic cells and the values of nasal resistance to rhinomanometry. In particular, those patients allergic to pollens displayed higher levels of cellular infiltration (eosinophils, neutrophils and mast cells) and a greater increase in nasal resistance. In addition, changes in the degree of eosinophilic-mast cell degranulation, which varied depending on the pollen (grasses, pellitory, cypress and olive tree), with a greater degree of degranulation for pollen belonging to the grass pollen, was found.

Moreover, nasal cytology may be used as one of the assessable outcomes for evaluating the effect of a nasal provocation test with a given allergen,[1] or as an additional diagnostic tool in occupational setting, where cytological pattern may put in evidence a classical allergic picture or a non-allergic nasal inflammation, depending on the involved occupational allergen.[49]

11 | CELLULAR NON-ALLERGIC RHINITIS (NARNE, NARES, NARMA, NARESMA)

When a chronic persistent rhinitis is not associated with the evidence of relevant allergic sensitization(s) and/or to a chronic rhinosinusitis, performing a nasal cytological evaluation may really be helpful in better understanding the underlying cellular inflammatory involvement, and therefore giving the most appropriate treatment for each single subtype of non-allergic rhinitis. Indeed, the identification of eosinophilic and/or mast cellular inflammation will implicate a preference for a certain drug, more specifically intranasal steroids intranasal corticosteroids and/or intranasal antihistamines, which are known to be effective in reducing the activity of these cells, while when neutrophils are predominant the expected efficacy of corticosteroids and antihistamines is poor.

The common characteristic of all these type of rhinitis is the absence of both allergenic sensitization and infection. The best known and first described is the Non-Allergic Rhinitis Eosinophilic Syndrome (NARES).[50] In this cellular form of rhinitis, the presence of eosinophils is not only predominant (inconsistently defined as >5% to >20%), but massively present with even higher expression than in seasonal rhinitis (Figure 10, Panel A).

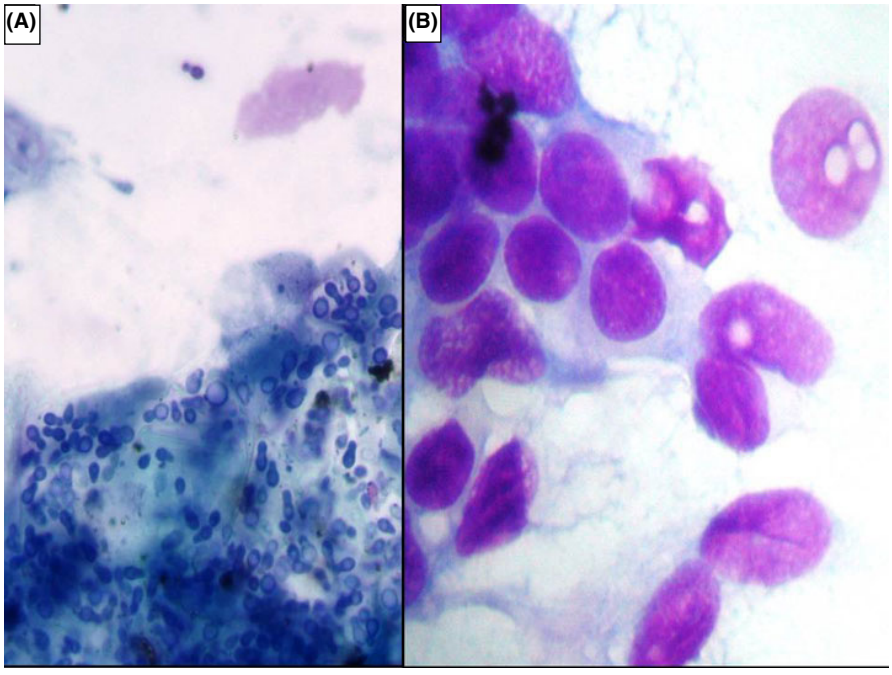

FIGURE 8 Panel A, Fungal sporae in biofilm. Panel B: karyorrhexis (stained with May-Grunwald-Giemsa; 1000× with Camera Magnification Factor 2×) [Colour figure can be viewed at wileyonlinelibrary.com]

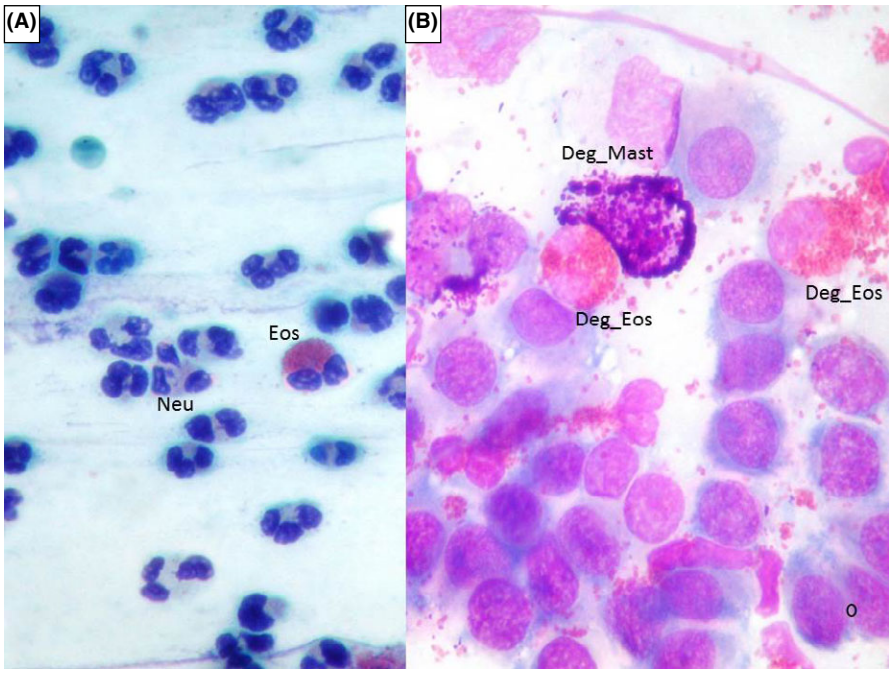

FIGURE 9 Panel A, Minimal persistent inflammation (Eos: eosinophils; Neu: neutrophils) (stained with May-Grunwald-Giemsa; 1000× with Camera Magnification Factor 1.5×). Panel B, Allergic rhinitis (Deg_Eos, degranulated eosinophils; Deg_Mast, degranulated mast cells) (stained with May-Grunwald-Giemsa; 1000× with Camera Magnification Factor 2×) [Colour figure can be viewed at wile yonlinelibrary.com]

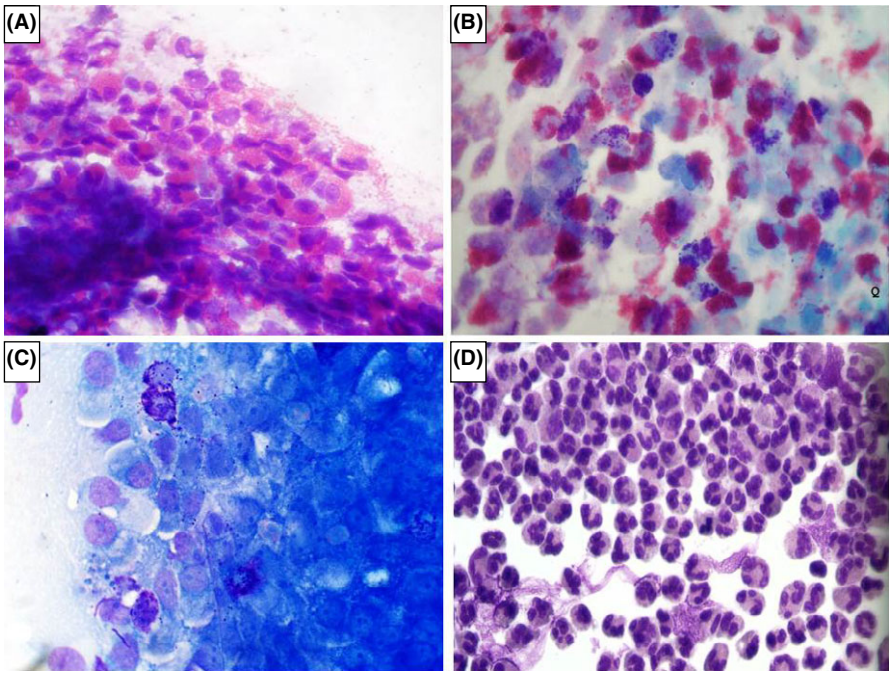

FIGURE 10 Non-allergic cellular rhinitis. Panel A, Non-allergic rhinitis with eosinophils (NARES). Panel B, Non-allergic rhinitis with eosinophils and mast cells (NARESMA). Panel C, Non-allergic rhinitis with mast cells (NARMA). Panel D, Non-allergic rhinitis with neutrophils (NARNE) (stained with May-Grunwald-Giemsa; 1000×) [Colour figure can be viewed at wileyonlinelibrary.com]

Another important inflammatory non-allergic rhinitis is the so-called NARESMA (Non-Allergic Rhinitis Eosinophilic Mastcell Syndrome)[51] in which, in addition to the important eosinophilic infiltrate, mast cell component (>10% of total nasal cells) is detectable. (Figure 10, Panel B).

The NARMA (Non-Allergic Rhinitis with Mast cells) is characterized by the isolated mast cell infiltration (>10% of total nasal cells) (Figure 10, Panel C) while NARNE by a massive presence of neutrophils (>50 of total nasal cells) without concomitant bacterial colonization[14,51] (Figure 10, Panel D).

These forms of rhinitis are characterized by a chronic course, with intense symptoms, and can cause local (otitis, sinusitis) or respiratory (asthma, bronchial or/and rhino inflammation) symptoms, and over time, they may evolve into nasal polyposis[52-55] (apart from NARNE, which generally is the cytologycal expression of a damaged mucosa by external chemical-physical noxae such as laryngeal-pharyngeal reflux or chlorine inhalation in swimmers)[56]; these findings need to be confirmed by further studies.

Few data are known about the epidemiology of cellular non-allergic rhinitis forms, but in an unselected group of patients with non-

allergic rhinitis, the frequencies of the different forms were as follow: NARES 30%, NARESMA 28%, NARMA 22% and NARNE 20%.[51]

Taken together, little is known about the pathogenesis of cellular non-allergic rhinitis forms; few studies have focused on the presence of local specific IgE, grouping these forms under the so-called Local Allergic Rhinitis nosological entity.[57] However, at present, there are still many points to be clarified in this regard. Beyond the pathogenetic classification, nasal cytology represents a marker of cellular presence.

12 | MIXED RHINITIS

This term refers to the overlapping of at least 2 of the previously described forms of rhinitis: for example, allergic rhinitis concomitant with cellular or infectious rhinitis. A deep and complete clinical history collection is essential for the correct diagnosis of these forms. Persistent obstructive symptoms outside the pollen season for which the patient is sensitized should suggest a mixed rhinitis. It is important to remember that the cytological sampling must be performed outside the pollen season (ie, in Italy, November appears to be the best month from this point of view for the scarcity of pollen allergens in the air): the presence of eosinophilia outside of the pollen period confirms the overlap with a cellular rhinitis.[57-62]

Similarly, in the case of patients allergic to dust mites, the most common feature is the presence of a minimal persistent inflammation: an increase in eosinophilic-mast cells should suggest an overlap with a cellular rhinitis.[6]

13 | CHRONIC RHINUSINUSITIS WITH AND WITHOUT NASAL POLYPS

Knowledge and definition about Rhinosinusitis and Nasal Polyps is significantly changed in the last decade, since 2005 when the first European Position Paper (EP3OS) was published. Nowadays, the Chronic Rhinosinusitis (CRS) classification in CRS with (CRSwNP) and without nasal polyps (CRSsNP) is world-wide recognized pointing to differences in the respective inflammatory profiles and treatment outcome.[63]

The majority of the available studies are based on the histological analysis of nasal polyps, while experiences on CRSwNP and nasal cytology are limited, but in line with the previous literature. In fact, Gelardi et al[52,64-69] studied the presence of the inflammatory cell population in the nasal mucosa of patients with CRSwNP and without allergy, demonstrating that the most represented cell types were eosinophils (61.8%), associated with mast cells in a further 31.9% of patients. Furthermore, they showed the mast cells/eosinophils association was more frequently associated to a clinical phenotype, namely patients with polyposis, asthma and ASA-sensitivity.[46]

Considering that nasal polyps recur in approximately one-third of patients after surgical treatment,[66] CRSwNP phenotypes would be helpful in depicting patients in whom we might expect recurrence and in predicting clinical outcome after surgery. Significant efforts have been made to individuate some specific clinical (comorbid asthma),[67,70] serological (high peripheral eosinophil count[66,71] and histological predictors of recurrence, such as high eosinophilic infiltrates in polyps[72] and adhesion molecules (mucin 1 and CD86 stromal expression)[73]: Wormald and colleagues[74] recommended that the extent of mucosal inflammatory load, especially tissue eosinophils, should be considered as the most important indicator for functional or radical surgical approach.[75] Similarly, Uhliarova et al[76] demonstrated that in patients with CRSwNP and elevated levels of eosinophils in the nasal lavage fluid and in nasal tissue are significantly more prone to recurrence and therefore require higher rate of revision FESS (Functional Endoscopic Sinus Surgery). Similarly, Gelardi et al[69] demonstrated that the presence of eosinophils and mast cells in the nasal smears of patients with CRSwNP is significantly related to a higher risk of polyps' recurrence after surgery in the long-term period, especially, when mast cells are associated to eosinophils in the same sample. The association between inflammatory cell types, comorbidities (asthma and ASA-sensitivity) and allergy helped Gelardi et al[69] in clustering patients in 3 classes of risk of recurrence of nasal polyps after surgery.

Furthermore, the inflammatory phenotype has a relevant role in determining steroid responsiveness and surgical outcome.[66] However, the number of eosinophils, neutrophils and other inflammatory cells vary greatly in nasal polyps, and accurate algorithms of CRSwNP classification are not clear-cut. Once identified the inflammatory phenotype, it is now possible to choose a tailored/personalized treatment.[77]

The nasal cytology pattern typically found in patients with CRSsNP resembles that of chronic nasal infection, with evidence of bacterial (or by other microorganisms) chronic infection, biofilm formation and increased number of neutrophils.[27]

14 | EFFECT OF THERAPY ON NASAL CYTOLOGY

14.1 | Pharmacological therapy

The pharmacological therapy of allergic rhinitis must take into account the severity and duration of the symptoms, the efficacy, availability, and cost of the drugs and the patient's choices.

In this regard, one must keep in mind that antihistamines act mainly on the symptom of rhinorrhea and nasal itching (the mast cellular component), while steroids act on the congestion symptom (the eosinophilic component).[78,79]

14.1.1 | Antihistamines

Several studies investigating the effect of antihistamines on nasal cytology: data are available mainly for levocetirizine,[80-82] desloratadine[83] and rupatadine[82] as far as oral antihistamines are concerned, and for azelastine hydrochloride[84-86] and levocabastine hydrochloride[87] ad far as nasal sprays are concerned.

Treatment with levocetirizine or rupatadine was associated with significant reduction in eosinophils[81,83,88] and neutrophils[80,83] in few

studies, while a randomized, open-label study with levocetirizine did not show significant reduction in nasal eosinophils both for continuously and for on-demand-treated patients.[81] Similar negative results were obtained with oral desloratadine.[80,83]

Only 3 studies investigated the effect of topical azelastine hydrochloride on nasal cytology: in 2 of them, a significant reduction of nasal eosinophils was found in allergic patients,[84,85] while the third one was not able to show any significant change in total cell numbers and/or differential count in nasal lavage fluid.[86] As far as levocabastine hydrochloride, only 1 study evaluated its effect on nasal cells showing reduced ciliary beat frequency at nasal epithelial level.[87]

14.1.2 | Topical nasal corticosteroids

Both intranasal mometasone furoate and fluticasone furoate demonstrated to induce a marked reduction in eosinophils and neutrophils count in nasal smears,[88–91] which is probably at the base of their efficacy in eosinophilic nasal diseases such as allergic rhinitis, NARES or CRSwNP. Moreover, intranasal mometasone furoate seems to be able to modify the biofilm of patients with CRSwNP.[92,93]

There is now the possibility of using the topical steroid-antihistamine combination, which is more efficacious than the steroid by itself in controlling nasal symptoms in patients >12 years old,[78] letting suppose a parallel enhancement of cytological response of the 2 drugs.

14.1.3 | Antileukotrienes

Antileukotrienes use is associated, independently of other possible concomitant drugs, with a significant reduction in eosinophilic nasal inflammation in patients with allergic rhinitis (reduction in eosinophils, neutrophils and lymphocytes)[94] and in CRSwNP[95,96] (significant reduction in mucosal eosinophils).

14.1.4 | Decongestants

Decongestants chronic use is not recommended as they can lead to an irreversible worsening of rhinitis called "rhinitis medicamentosa," characterized by structural modification of nasal mucosa and cytological abnormalities such as: squamous cell metaplasia, goblet cell hyperplasia with increased production of mucus, change from ciliated columnar epithelial cells to non-ciliated, stratified squamous cells, and increased number of lymphocytes and plasma cells.[97]

14.1.5 | Specific immunotherapy (AIT)

AIT is the only treatment that can modify the natural course of allergic disease[98,99] and it can be administered either subcutaneously (SCIT) or sublingually (SLIT).

The decision to undertake a specific immunotherapy must take into consideration the importance of the allergen, the intensity of the disease, the availability of a standardized extract and above all, the correlation between exposure to the allergen and the appearance of the symptoms.

It is precisely in this context that nasal cytology plays an important role, because it can reveal the cells of the immune inflammation and link them to the symptomatology.

Thus, this process of precision medicine may be applied, prescribing, if necessary, the appropriate immunotherapy or not, after a careful assessment, because it would not be efficacious or only partially efficacious in a given patient suffering from a mixed or overlapping form.

In effect, numerous studies have shown a correlation between cellular infiltrate and the symptomatology, thus allowing the therapeutic effects of both the pharmacology and the immunotherapy to be monitored.[100-104]

Few studies on small amount of patients showed a decrease in nasal eosinophilia and eosinophilic activity markers (together with decrease in symptoms) in patients treated with allergy immunotherapy both in mice[104] and in humans.[103,105,106]

14.1.6 | Systemic steroids

Their effect on nasal cytology is mainly on a significant reduction eosinophils. In such patients, therefore, it is important to periodically monitor the nasal cytology inflammation to reduce steroids consumption to the minimum.[6]

15 | DISCUSSION

Nowadays, according to the knowledge about anatomo-physiological and immunopathological mechanisms, it is possible to affirm that nasal symptoms are the clinical expression of the presence of cells that are normally supposed not to be present into the nasal mucosa. Therefore, nasal cytology, being cheap, non-invasive and repeatable, can easily be considered as part of the rhino-allergologic diagnostics. However, for having clinically relevant results, nasal cytology should be performed, read and interpreted by trained personnel. Many efforts have been put, in the last 20 years, for the implementation and the dissemination of nasal cytology as non-invasive assessment of nasal inflammation. However, many allergy centres still do not use routinely it, despite the evidence of its easiness, cheapness, non-invasiveness and usefulness in clinical practice. This limits its use to specialized centres in which trained personnel can give an additional value to the commonly used diagnostics in rhinology.

For some diseases (ie, cellular rhinitis: NARES, NARMA, NARNA, NARESMA…), nasal cytology represents the diagnostic gold standard as they are not diagnosable without it. Other conditions that may be diagnosed only by means of nasal cytology are overlapped rhinitis, the presence of biofilm and ciliocytophthoria; moreover, nasal cytology can give information on the activity and the efficacy of drugs used for rhinitis and it can help the physician to phenotype CRSwNP or CRSsNP in a "precision medicine" perspective.

CONFLICT OF INTERESTS

The authors declare no conflict of interest.

ORCID

E. Heffler http://orcid.org/0000-0002-0492-5663

REFERENCES

1. Hellings PW, Scadding G, Alobid I, et al. Executive summary of European Task Force document on diagnostic tools in rhinology. *Rhinology*. 2012;50:339-352.
2. Bogaerts P, Clement P. The diagnostic value of a cytogram in rhinopathology. *Rhinology*. 1981;19:203-208.
3. Malmberg H, Holopainen E. Nasal smear as a screening test for immediate-type nasal allergy. *Allergy*. 1979;34:331-337.
4. Gelardi M, Leo ME, Quaranta VN, et al. Clinical characteristics associated with conjunctival inflammation in allergic rhinoconjunctivitis. *J Allergy Clin Immunol Pract*. 2015;3:387-391.
5. Gelardi M, Spadavecchia L, Fanelli P, et al. Nasal inflammation in vernal keratoconjunctivitis. *J Allergy Clin Immunol*. 2010;125:496-498.
6. Gelardi M, Iannuzzi L, Quaranta N, Landi M, Passalacqua G. Nasal cytology: practical aspects and clinical relevance. *Clin Exp Allergy*. 2016;46:785-792.
7. Scadding G, Hellings P, Alobid I, et al. Diagnostic tools in rhinology EAACI position paper. *Clin Transl Allergy*. 2011;1:2.
8. Riccio AM, Tosca MA, Cosentino C, et al. Cytokine pattern in allergic and non-allergic chronic rhinosinusitis in asthmatic children. *Clin Exp Allergy*. 2002;32:422-426.
9. Irander K, Palm JP, Borres MP, Ghafouri B. Clara cell protein in nasal lavage fluid and nasal nitric oxide – biomarkers with anti-inflammatory properties in allergic rhinitis. *Clin Mol Allergy*. 2012;10:4.
10. Biewenga J, Stoop AE, Baker HE, et al. Nasal secretions from patients with polyps and healthy individuals, collected with a new aspiration system: evaluation of total protein and immunoglobulin concentrations. *Ann Clin Biochem*. 1991;28(Pt 3):260-266.
11. Park DY, Kim S, Kim CH, Yoon JH, Kim HJ. Alternative method for primary nasal epithelial cell culture using intranasal brushing and feasibility for the study of epithelial functions in allergic rhinitis. *Allergy Asthma Immunol Res*. 2016;8:69-78.
12. van Benten IJ, van Drunen CM, Koopman LP, et al. Age- and infection-related maturation of the nasal immune response in 0-2-year-old children. *Allergy*. 2005;60:226-232.
13. Caruso G, Gelardi M, Passali GC, De Santi MM. Nasal scraping in diagnosing ciliary diskinesia. *Am J Rhinol*. 2007;21:702-705.
14. Gelardi M. *Atlas of Nasal Cytology*. Turin: Centro Scientifico Editore; 2006.
15. Meltzer EO, Orgel HA, Rogenes PR, Field EA. Nasal cytology in patients with allergic rhinitis: effects of intranasal fluticasone propionate. *J Allergy Clin Immunol*. 1994;94:708-715.
16. Pipolo C, Bianchini S, Barberi S, et al. Nasal cytology in children: scraping or swabbing? *Rhinology*. 2017;55:242-250.
17. Fokkens WJ, Vroom TM, Gerritsma V, Rijntjes E. A biopsy method to obtain high quality specimens of nasal mucosa. *Rhinology*. 1988;26:293-295.
18. Ciprandi G, Ricca V, Paola F, et al. Duration of anti-inflammatory and symptomatic effects after suspension of intranasal corticosteroid in persistent allergic rhinitis. *Eur Ann Allergy Clin Immunol*. 2004;36:63-66.
19. Prat J, Xaubet A, Mullol J, et al. Immunocytologic analysis of nasal cells obtained by nasal lavage: a comparative study with a standard method of cell identification. *Allergy*. 1993;48:587-591.
20. Harkema JR, Carey SA, Wagner JG. The nose revisited: a brief review of the comparative structure, function, and toxicologic pathology of the nasal epithelium. *Toxicol Pathol*. 2006;34:252-269.
21. Gelardi M, Cassano P, Cassano M, Fiorella ML. Nasal cytology: description of a hyperchromatic supranuclear stria as a possible marker for the anatomical and functional integrity of the ciliated cell. *Am J Rhinol*. 2003;17:263-268.
22. Aslani FS, Khademi B, Yeganeh F, Kumar PV, Bedayat GR. Nasal cytobrush cytology: evaluation of the hyperchromatic supranuclear stria. *Acta Cytol*. 2006;50:430-434.
23. Cassano M, Russo L, Del Giudice AM, Gelardi M. Cytologic alterations in nasal mucosa after sphenopalatine artery ligation in patients with vasomotor rhinitis. *Am J Rhinol Allergy*. 2012;26:49-54.
24. Petruson B. Secretion from gland and goblet cells in infected sinuses. *Acta Otolaryngol Suppl*. 1994;515:33-36.
25. Yu F, Zhao X, Li C, et al. Airway stem cells: review of potential impact on understanding of upper airway diseases. *Laryngoscope*. 2012;122:1463-1469.
26. Romanelli MC, Gelardi M, Fiorella ML, Tattoli L, Di Vella G, Solarino B. Nasal ciliary motility: a new tool in estimating the time of death. *Int J Legal Med*. 2012;126:427-433.
27. Al-Mutairi D, Kilty SJ. Bacterial biofilms and the pathophysiology of chronic rhinosinusitis. *Curr Opin Allergy Clin Immunol*. 2011;11:18-23.
28. Gelardi M, Passalacqua G, Fiorella ML, Quaranta N. Assessment of biofilm by nasal cytology in different forms of rhinitis and its functional correlations. *Eur Ann Allergy Clin Immunol*. 2013;45:25-29.
29. Gelardi M, Passalacqua G, Fiorella ML, Mosca A, Quaranta N. Nasal cytology: the "infectious spot", an expression of a morphological-chromatic biofilm. *Eur J Clin Microbiol Infect Dis*. 2011;30:1105-1109.
30. Holgate ST, Roberts G, Arshad HS, Howarth PH, Davies DE. The role of the airway epithelium and its interaction with environmental factors in asthma pathogenesis. *Proc Am Thorac Soc*. 2009;6:655-659.
31. Toppila-Salmi S, van Drunen CM, Fokkens WJ, et al. Molecular mechanisms of nasal epithelium in rhinitis and rhinosinusitis. *Curr Allergy Asthma Rep*. 2015;15:495.
32. Hupin C, Gohy S, Bouzin C, Lecocq M, Polette M, Pilette C. Features of mesenchymal transition in the airway epithelium from chronic rhinosinusitis. *Allergy*. 2014;69:1540-1549.
33. Sala O, Marchiori C, Soranzo G. Nasal cytology in the diagnosis of chronic rhinitis in children. *Acta Otorhinolaryngol Ital*. 1988;19:25-33.
34. Shimizu T, Takahashi Y, Kawaguchi S, Sakakura Y. Hypertrophic and metaplastic changes of goblet cells in rat nasal epithelium induced by endotoxin. *Am J Respir Crit Care Med*. 1996;153(4 Pt 1):1412-1418.
35. Curran DR, Cohn L. Advances in mucous cell metaplasia a plug for mucus as a therapeutic focus in chronic airway disease. *Am J Respir Cell Mol Biol*. 2010;42:268-275.
36. Reh DD, Higgins TS, Smith TL. Impact of tobacco smoke on chronic rhinosinusitis: a review of the literature. *Int Forum Allergy Rhinol*. 2012;2:362-369.
37. Trombitas V, Nagy A, Berce C, Tabaran F, Albu S. Effect of cigarette smoke on wound healing of the septal mucosa of the rat. *Biomed Res Int*. 2016;2016:6958597.
38. Toppozada H. The human nasal mucosa in the menopause (a histochemical and electron microscopic study). *J Laryngol Otol*. 1988;102:314-318.
39. Edelstein DR. Aging of the normal nose in adults. *Laryngoscope*. 1996;106:1-25.
40. Agius AM, Smallman LA, Pahor AL. Age, smoking and nasal ciliary beat frequency. *Clin Otolaryngol Allied Sci*. 1998;23:227-230.
41. Ho JC, Chan KN, Hu WH, et al. The effect of aging on nasal mucociliaryclearance, beat frequency, and ultrastructure of respiratory cilia. *Am J Respir Crit Care Med*. 2001;163:983-988.
42. Beule AG. Physiology and pathophysiology of respiratory mucosa of the nose and the paranasal sinuses. *GMS Curr Top Otorhinolaryngol Head Neck Surg*. 2010;9:Doc07.
43. Pelikan Z, Pelikan-Filipek M. Cytologic changes in the nasal secretions during the immediate nasal response. *J Allergy Clin Immunol*. 1988;82:1103-1112.

44. Pelikan Z, Pelikan-Filipek M. Cytologic changes in the nasal secretions during the late nasal response. *J Allergy Clin Immunol*. 1989;83:1068-1079.
45. Ciprandi G, Buscaglia S, Pesce G, et al. Minimal persistent inflammation is present at mucosal level in asymptomatic rhinitis patients with allergy due to mites. *J Allergy Clin Immunol*. 1995;96:971-979.
46. Ricca V, Landi M, Ferrero P, et al. Minimal persistent inflammation is also present in patients with seasonal allergic rhinitis. *J Allergy Clin Immunol*. 2000;105(1 Pt 1):54-57.
47. Gelardi M, Peroni DG, Incorvaia C, et al. Seasonal changes in nasal cytology in mite-allergic patients. *J Inflamm Res*. 2014;7:39-44.
48. Gelardi M, Maselli Del Giudice A, Candreva T, et al. Nasal resistance and allergic inflammation depend on allergen type. *Int Arch Allergy Immunol*. 2006;141:384-389.
49. Quirce S, Lemière C, de Blay F, et al. Noninvasive methods for assessment of airway inflammation in occupational settings. *Allergy*. 2010;65:445-458.
50. Jacobs RL, Freedman PM, Boswell RN. Non—allergic rhinitis with eosinophilia (NARES syndrome): clinical and immunologic presentation. *J Allergy Clin Immunol*. 1981;67:253-257.
51. Gelardi M, Maselli Del Giudice A, Fiorella ML, et al. Non-allergic rhinitis with eosinophils and mast cells constitutes a new severe nasal disorder. *Int J Immunopathol Pharmacol*. 2008;23:325-331.
52. Gelardi M, Russo C, Fiorella ML, Fiorella R, Ciprandi G. Inflammatory cell types in nasal polyps. *Cytopathology*. 2009;21:201-203.
53. Gelardi M, Iannuzzi L, Tafuri S, Passalacqua G, Quaranta N. Allergic and non-allergic rhinitis: relationship with nasal polyposis, asthma and family history. *Acta Otorhinolaryngol Ital*. 2014;34:36-41.
54. Moneret-Vautrin DA, Jankowski R, Bene MC, et al. NARES: a model of inflammation caused by activated eosinophils? *Rhinology*. 1992;30:161-168.
55. Moneret-Vautrin DA, Hsieh V, Wayoff M, Guyot JL, Mouton C, Maria Y. Nonallergic rhinitis with eosinophilia syndrome a precursor of the triad: nasal polyposis, intrinsic asthma, and intolerance to aspirin. *Ann Allergy*. 1990;64:513-518.
56. Gelardi M, Ventura MT, Fiorella R, et al. Allergic and non-allergic rhinitis in swimmers: clinical and cytological aspects. *Br J Sports Med*. 2012;46:54-58.
57. Campo P, Rondón C, Gould HJ, Barrionuevo E, Gevaert P, Blanca M. Local IgE in non-allergic rhinitis. *Clin Exp Allergy*. 2015;45:872-881.
58. Gelardi M, Fiorella ML, Fiorella R, Russo C, Passalacqua G. When allergic rhinitis is not only allergic. *Am J Rhinol*. 2009;23:312-315.
59. Gelardi M. "Overlapped" rhinitis: a real trap for rhinoallergologists. *Eur Ann Allergy Clin Immunol*. 2014;46:234-236.
60. Gelardi M, Marseglia GL, Landi M, et al. Nasal cytology in children: recent avances. *Ital J Pediatr*. 2012;38:51.
61. Rondón C, Bogas G, Barrionuevo E, Blanca M, Torres MJ, Campo P. Non-allergic rhinitis and lower airway disease. *Allergy*. 2017;72:24-34.
62. Rondón C, Campo P, Zambonino MA, et al. Follow-up study in local allergic rhinitis shows a consistent entity not evolving to systemic allergic rhinitis. *J Allergy Clin Immunol*. 2014;133:1026-1031.
63. Fokkens WJ, Lund VJ, Mullol J, et al. EPOS 2012: European position paper on rhinosinusitis and nasal polyps 2012. A summary for otorhinolaryngologists. *Rhinology*. 2012;50:1-12.
64. Wei Y, Han M, Wen W, Li H. Differential short palate, lung, and nasal epithelial clone 1 suppression in eosinophilic and noneosinophilic chronic rhinosinusitis with nasal polyps: implications for pathogenesis and treatment. *Curr Opin Allergy Clin Immunol*. 2016;16:31-38.
65. Bernstein JM, Kansal R. Superantigen hypothesis for the early development of chronic hyperplastic sinusitis with massive nasal polyposis. *Curr Opin Otolaryngol Head Neck Surg*. 2005;13:39-44.
66. Lou H, Meng Y, Piao Y, Wang C, Zhang L, Bachert C. Predictive significance of tissue eosinophilia for nasal polyp recurrence in the Chinese population. *Am J Rhinol Allergy*. 2015;29:350-356.
67. Nakayama T, Asaka D, Yoshikawa M, et al. Identification of chronic rhinosinusitis phenotypes using cluster analysis. *Am J Rhinol Allergy*. 2012;26:172-176.
68. Soler ZM, Hyer JM, Rudmik L, Ramakrishnan V, Smith TL, Schlosser RJ. Cluster analysis and prediction of treatment outcomes for chronic rhinosinusitis. *J Allergy Clin Immunol*. 2016;137:1054-1062.
69. Gelardi M, Fiorella R, Fiorella ML, Russo C, Soleti P, Ciprandi G. Nasal-sinus polyposis: clinical-cytological grading and prognostic index of relapse. *J Biol Regul Homeost Agents*. 2009;23:181-188.
70. ten Brinke A, Sterk PJ, Masclee AA, et al. Risk factors of frequent exacerbations in difficult-to-treat asthma. *Eur Respir J*. 2005;26:812-818.
71. Drake VE, Rafaels N, Kim J. Peripheral blood eosinophilia correlates with hyperplastic nasal polyp growth. *Int Forum Allergy Rhinol*. 2016;6:926-934.
72. Grgić MV, Ćupić H, Kalogjera L, Baudoin T. Surgical treatment for nasal polyposis: predictors of outcome. *Eur Arch Otorhinolaryngol*. 2015;272:3735-3743.
73. Batzakakis D, Stathas T, Mastronikolis N, Kourousis C, Aletras A, Naxakis S. Adhesion molecules as predictors of nasal polyposis recurrence. *Am J Rhinol Allergy*. 2014;28:20-22.
74. Bassiouni A, Naidoo Y, Wormald PJ. When FESS fails: the inflammatory load hypothesis in refractory chronic rhinosinusitis. *Laryngoscope*. 2012;122:460-466.
75. Vlaminck S, Vauterin T, Hellings PW, et al. The importance of local eosinophilia in the surgical outcome of chronic rhinosinusitis: a 3-year prospective observational study. *Am J Rhinol Allergy*. 2014;28:260-264.
76. Uhliarova B, Kopincova J, Kolomaznik M, Adamkov M, Svec M, Calkovska A. Comorbidity has no impact on eosinophil inflammation in the upper airways or on severity of the sinonasal disease in patients with nasal polyps. *Clin Otolaryngol*. 2015;40:429-436.
77. Gelardi M, Iannuzzi L, De Giosa M, et al. Non-surgical management of chronic rhinosinusitis with nasal polyps based on clinical-cytological grading: a precision medicine-based approach. *Acta Otorhinolaryngol Ital*. 2017;37:38-45.
78. Brozek JL, Bousquet J, Baena-Cagnani CE, et al. Allergic rhinitis and its impact on asthma (ARIA) guidelines: 2010 revision. *J Allergy Clin Immunol*. 2010;126:466-476.
79. Kirtsreesakul V, Hararuk K, Leelapong J, Ruttanaphol S. Clinical efficacy of nasal steroids on nonallergic rhinitis and the associated inflammatory cell phenotypes. *Am J Rhinol Allergy*. 2015;29:343-349.
80. Ciprandi G, Cirillo I, Vizzaccaro A, Tosca MA. Levocetirizine improves nasal obstruction and modulates cytokine pattern in patients with seasonal allergic rhinitis: a pilot study. *Clin Exp Allergy*. 2004;34:958-964.
81. Canonica GW, Fumagalli F, Guerra L, et al. Levocetirizine in persistent allergic rhinitis: continuous or on-demand use? A pilot study. *Curr Med Res Opin*. 2008;24:2829-2839.
82. Maiti R, Rahman J, Jaida J, Allala U, Palani A. Rupatadine and levocetirizine for seasonal allergic rhinitis: a comparative study of efficacy and safety. *Arch Otolaryngol Head Neck Surg*. 2010;136:796-800.
83. Ciprandi G, Cirillo I, Vizzaccaro A, et al. Desloratadine and levocetirizine improve nasal symptoms, airflow, and allergic inflammation in patients with perennial allergic rhinitis: a pilot study. *Int Immunopharmacol*. 2005;5:1800-1808.
84. Ciprandi G, Pronzato C, Passalacqua G, et al. Topical azelastine reduces eosinophil activation and intercellular adhesion molecule-1 expression on nasal epithelial cells: an antiallergic activity. *J Allergy Clin Immunol*. 1996;98(6 Pt 1):1088-1096.
85. Ciprandi G, Ricca V, Passalacqua G, et al. Seasonal rhinitis and azelastine: long- or short-term treatment? *J Allergy Clin Immunol*. 1997;99:301-307.
86. Kalpaklioglu AF, Kavut AB. Comparison of azelastine versus triamcinolone nasal spray in allergic and nonallergic rhinitis. *Am J Rhinol Allergy*. 2010;24:29-33.

87. Jiao J, Meng N, Zhang L. The effect of topical corticosteroids, topical antihistamines, and preservatives on human ciliary beat frequency. *ORL J Otorhinolaryngol Relat Spec*. 2014;76:127-136.
88. Frieri M, Therattil J, Chavarria V, et al. Effect of mometasone furoate on early and late phase inflammation in patients with seasonal allergic rhinitis. *Ann Allergy Asthma Immunol*. 1998;81:431-437.
89. Meltzer EO, Jalowayski AA, Orgel HA, Harris AG. Subjective and objective assessments in patients with seasonal allergic rhinitis: effects of therapy with mometasone furoate nasal spray. *J Allergy Clin Immunol*. 1998;102:39-49.
90. Ciprandi G, Tosca MA, Passalacqua G, Canonica GW. Intranasal mometasone furoate reduces late-phase inflammation after allergen challenge. *Ann Allergy Asthma Immunol*. 2001;86:433-438.
91. Tantilipikorn P, Thanaviratananich S, Chusakul S, et al. Efficacy and safety of once daily fluticasone furoate nasal spray for treatment of irritant (non-allergic) rhinitis. *Open Respir Med J*. 2010;4:92-99.
92. Korkmaz H, Ocal B, Tatar EC, et al. Biofilms in chronic rhinosinusitis with polyps: is eradication possible? *Eur Arch Otorhinolaryngol*. 2014;271:2695-2702.
93. Csomor P, Sziklai I, Karosi T. Effects of intranasal steroid treatment on the presence of biofilms in non-allergic patients with chronic rhinosinusitis with nasal polyposis. *Eur Arch Otorhinolaryngol*. 2014;271:1057-1065.
94. Braido F, Riccio AM, Rogkakou A, et al. Montelukast effects on inflammation in allergic rhinitis: a double blind placebo controlled pilot study. *Eur Ann Allergy Clin Immunol*. 2012;44:48-53.
95. Schäper C, Noga O, Koch B, et al. Anti-inflammatory properties of montelukast, a leukotriene receptor antagonist in patients with asthma and nasal polyposis. *J Investig Allergol Clin Immunol*. 2011;21:51-58.
96. Kieff DA, Busaba NY. Efficacy of montelukast in the treatment of nasal polyposis. *Ann Otol Rhinol Laryngol*. 2005;114:941-945.
97. Ramey JT, Bailen E, Lockey RF. Rhinitis medicamentosa. *J Investig Allergol Clin Immunol*. 2006;16:148-155.
98. Bachert C, Larché M, Bonini S, et al. Allergen immunotherapy on the way to product-based evaluation-a WAO statement. *World Allergy Organ J*. 2015;8:29.
99. Canonica GW, Bachert C, Hellings P, et al. Allergen immunotherapy (AIT): a prototype of precision medicine. *World Allergy Organ J*. 2015;8:31.
100. Gelardi M, Bosoni M, Morelli M, et al. In children allergic to ragweed pollen, nasal inflammation is not influenced by monosensitization or polysensitization. *J Inflamm Res*. 2016;9:21-25.
101. Gelardi M, Ciprandi G, Buttafava S, et al. Nasal inflammation in Parietaria allergic patients is associated with pollen exposure. *J Investig Allergol Clin Immunol*. 2014;24:352-353.
102. Gelardi M, Incorvaia C, Passalacqua G, Quaranta N, Frati F. The classification of allergic rhinitis and its cytological correlate. *Allergy*. 2011;66:1624-1625.
103. Ventura MT, Murgia N, Montuschi P, et al. Exhaled breath condensate, nasal eosinophil cationic protein level and nasal cytology during immunotherapy for cypress allergy. *J Biol Regul Homeost Agents*. 2013;27:1083-1089.
104. Kaminuma O, Suzuki K, Mori A. Effect of sublingual immunotherapy on antigen-induced bronchial and nasal inflammation in mice. *Int Arch Allergy Immunol*. 2010;152(Suppl 1):75-78.
105. Can D, Tanaç R, Demir E, Gülen F, Veral A. Efficacy of pollen immunotherapy in seasonal allergic rhinitis. *Pediatr Int*. 2007;49:64-69.
106. Ciprandi G, Tosca MA. Sublingual immunotherapy affects transforming growth factor-beta and nasal eosinophils. *Clin Exp Allergy*. 2010;40:1431-1432; author reply 1432.

How to cite this article: Heffler E, Landi M, Caruso C, et al. Nasal cytology: Methodology with application to clinical practice and research. *Clin Exp Allergy*. 2018;48:1092–1106. https://doi.org/10.1111/cea.13207