Internal Medicine
The Japanese Society of Internal Medicine

doi: 10.2169/internalmedicine.8323-21
Intern Med Advance Publication
http://internmed.jp

【 CASE REPORT 】

Sustained Eosinophilic Cholangitis Due to a Mite Allergy Mimicking Sclerosing Cholangitis

Masayo Motoya[1], Shun Takai[2], Hiroshi Moriya[2], Takehiro Hirano[1], Kohei Wagatsuma[1], Yasunao Numata[1], Yujiro Kawakami[1], Yoshiharu Masaki[1], Keisuke Ishigami[1], Ayako Murota[1] and Hiroshi Nakase[1]

Abstract:
Eosinophilic cholangiopathy (EC) presents with thickening and stenosis of the bile duct wall that is histologically characterized by eosinophil infiltration. The diagnosis is often difficult. We herein report a patient who had been followed up with a diagnosis of primary sclerosing cholangitis but had a final diagnosis of EC based on eosinophilia, histological findings of bile duct and liver biopsy specimens, and a review of a previous surgical specimen of the gallbladder. Antigen tests, isolation from her house, and accidental re-exposure to the antigen revealed that the causative antigen was the mite *Dermatophagoides pteronyssinus*.

Key words: Eosinophilic cholangiopathy, Eosinophilia, Sclerosing cholangitis, Eosinophilic cholecystitis

(Intern Med Advance Publication)
(DOI: 10.2169/internalmedicine.8323-21)

Introduction

Eosinophilic cholangiopathy (EC) is a rare disease with an uncommon etiology. The histological characteristics are the infiltration of eosinophils into the bile duct wall with resulting thickening of the bile duct wall and stenosis of the biliary tract. Inflammation due to stones, allergic reactions to drugs, and parasitic infection have been reported as causes of EC (1-3). In clinical practice, it is difficult to distinguish EC from primary sclerosing cholangitis (PSC) and biliary tract cancer.

Matsumoto et al. (2) advocated the following diagnostic criteria of EC: 1) wall thickening or stenosis of the biliary system, 2) histopathological findings of eosinophilic infiltration, and 3) reversibility of biliary abnormalities without treatment or following steroid treatment. However, the long-term clinical course of EC remains unclear.

We encountered a patient with a final diagnosis of EC who had been followed up for PSC for a long time based on elevated eosinophils in the peripheral blood due to a mite allergy. Furthermore, we confirmed that the patient had already had eosinophilic cholangitis 15 years earlier by reviewing the histology of a previous surgical specimen of her gallbladder. Given the above, we considered that prolonged eosinophilic cholangitis contributed to the PSC-like changes.

Case Report

A 75-year-old woman with a diagnosis of PSC, bronchial asthma, and indeterminate colitis who had been followed for 2 years was admitted to our hospital because of a sustained low-grade fever and right upper quadrant abdominal pain. Two years ago, PSC had been suspected at a previous hospital because of sustained elevation of hepatobiliary enzymes and bile duct stricture on magnetic resonance cholangiopancreatography (MRCP). Her serum IgG4 level was normal, and a liver biopsy did not show any specific findings of PSC or IgG4-related sclerosing cholangitis (IgG4-SC).

At her initial admission to our hospital, MRCP showed multiple short stenoses of the hilar and intrahepatic bile duct (Fig. 1a). Endoscopic retrograde cholangiopancreatography (ERCP) showed peripheral obliteration and reduced arborization of the intrahepatic bile ducts, a so-called “pruned tree

[1]Department of Gastroenterology and Hepatology, Sapporo Medical University School of Medicine, Japan and [2]Department of Gastroenterology, Hakodate Goryoukaku Hospital, Japan
Received: July 12, 2021; Accepted: December 13, 2021; Advance Publication by J-STAGE: February 1, 2022
Correspondence to Dr. Masayo Motoya, hmasayo@sapmed.ac.jp

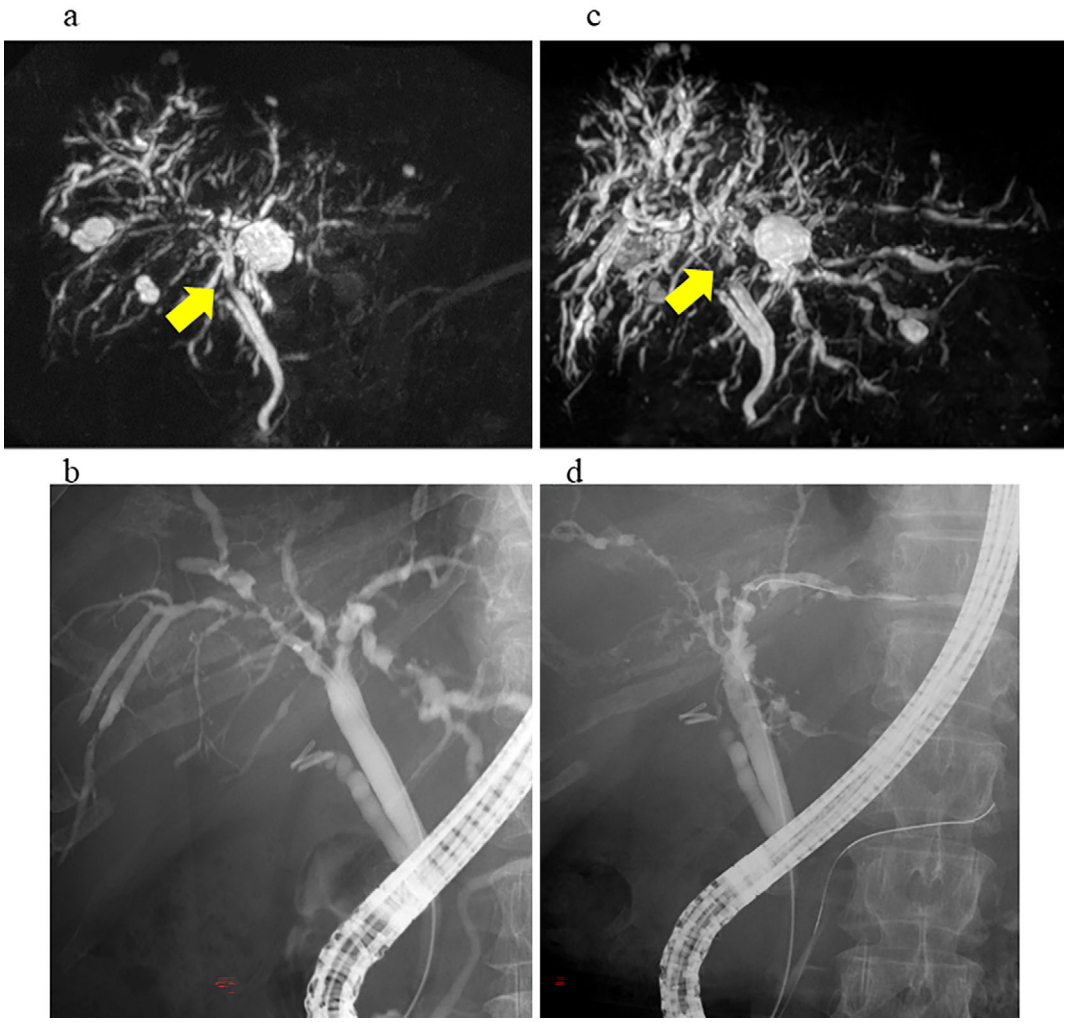

Figure 1. Magnetic resonance cholangiopancreatography (MRCP) and endoscopic retrograde cholangiopancreatography (ERCP) findings from two years ago (a, b) and before treatment with oral corticosteroid (c, d). The stenosis of the hilar bile duct was worsened (arrow).

appearance", and multiple short strictures (Fig. 1b).

At this time, she did not complain of dyspnea, wheezing, or diarrhea. A physical examination revealed tenderness in the upper right abdomen. Laboratory data showed a white blood cell count of 18,200/mm^3 with 57% eosinophils, a total bilirubin level of 0.9 mg/dL, aspartate transaminase of 86 U/L, alanine aminotransferase of 80 U/L, alkaline phosphatase of 1,658 U/L, a γ- glutamyltransferase of 246 U/L, C-reactive protein of 1.96 mg/dL, IgG4 of 106 mg/dL, IgE of 1,545 IU/mL, carcinoembryonic antigen of 1.9 ng/mL, and carbohydrate antigen 19-9 of 14.9 U/mL. A bone marrow biopsy revealed no abnormality. MRCP and ERCP on admission showed exacerbation of the stenosis in the hilar bile duct (Fig. 1a, c). Intraductal ultrasonography (IDUS) showed diffuse uniform wall thickening and stenosis from the left hepatic bile duct to the hilar bile duct, while the extrahepatic bile duct did not show these findings.

A histological examination of a bile duct biopsy showed fibrosis with a large amount of eosinophil infiltration (Fig. 2a). In addition, the histological result of the liver biopsy showed extensive eosinophil infiltration in the portal tract area with bile ductular proliferation (Fig. 2b). No specific findings of IgG4-SC were observed by IgG4 staining. Based on these findings, we diagnosed her with eosinophilic cholangitis. Since this case was diagnosed as one of indeterminate colitis, we suspected complications of eosinophilic gastroenteropathy and performed upper and lower gastrointestinal endoscopy. We performed a tissue biopsy from the esophagus, stomach, small intestine, and colon. Particularly in the colon, we took biopsy specimens from inflamed mucosa. These specimens did not meet the diagnostic criteria of eosinophilic gastroenteropathy.

The symptoms, such as her fever and upper abdominal pain, were relieved after hospitalization without any specific treatments. She was discharged because of the improvement in her hepatobiliary enzymes with a decreasing number of eosinophils. However, two weeks after her discharge, her eosinophil count and hepatobiliary enzyme increased again. Various allergy tests showed a strong allergic reaction to *Dermatophagoides pteronyssinus* and a slight positive reac-

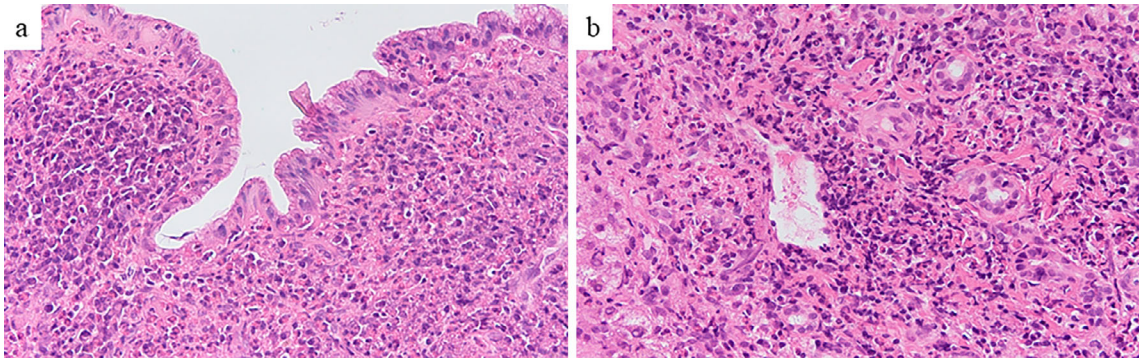

Figure 2. **Histological findings of a (a) bile duct biopsy [objective, 40× with Hematoxylin and Eosin (H&E) staining] and (b) liver biopsy (objective, 40× with H&E staining).**

Table 1. **Results of Allergy Test.**

Allergen	Specific IgE (UA/mL)
Birch	<0.35
Japanese cedar	<0.35
Moth	<0.35
Poaceae	<0.35
Weed pollen	<0.35
Wheat grain	<0.35
Animal dander	<0.35
Dermatophagoides pteronyssinus	25.00
Food	0.54
Fungi	0.76

tion to food and fungi. All other results were negative (Table 1).

Given her allergy to the dust mite and the worsening of her symptoms and blood data after returning home, we attributed her problem to house dust mites. After having the bed and carpets in her house cleaned, laboratory data revealed a markedly decreased number of eosinophils. The patient was followed up, and no exacerbations were reported. Four months after her discharge, she organized the closet in her house. Subsequently, laboratory data showed increased eosinophils in her peripheral blood and elevated serum levels of hepatobiliary enzymes. No improvement in the eosinophil count was observed despite her rehospitalization. Therefore, we started corticosteroid (CS) treatment at a dose of 25 mg/day (Fig. 3). After treatment with the CS, the stenosis of the hilar bile duct partially improved, and her eosinophil count decreased (Fig. 4). She received 50 mg/day of azathioprine and 5 mg/day of the CS. Currently, she remains asymptomatic.

The patient had a history of undergoing laparoscopic cholecystectomy due to cholecystitis at 60 years old. We reexamined the histology of the gallbladder and found eosinophilic cholecystitis (Fig. 5a, b). Based on this clinical course and histological results, she was deemed to have already had eosinophilic cholangiopathy at 60 years old. Therefore, we considered that prolonged eosinophilic cholangitis resulted in PSC-like changes.

Discussion

The present case is a rare case in which EC was associated with a mite allergy, as exposure to mites repeatedly exacerbated cholangitis. There were no cases in which exacerbation of cholangitis via direct exposure to allergens was observed, as in this case. A histological review of past cholecystectomy revealed EC, indicating that she had had EC for at least 15 years. We considered that long-term EC had contributed to a PSC-like bile duct image.

In 1997, Tenner (4) advocated broader-term EC to describe changes in either the gallbladder or bile ducts. EC is diagnosed by histopathologically revealing eosinophil infiltration with thickening and fibrosis of the bile duct wall. A search using PubMed for the terms “eosinophilic cholangiopathy,” “eosinophilic cholangitis,” and “eosinophilic cholecystitis” from January 2000 to March 2021 resulted in 44 reports. The median age was 46 (13-84) years old, 61% were men, and 21 of 35 cases (60%) had elevated peripheral blood eosinophil counts (>1,500/μL). Bile duct stricture or wall thickening was found diffusely (41%) and in the hilar bile duct (34%) and extrahepatic duct (22%). Four patients had allergic diseases (bronchial asthma, sinusitis, urticaria), and one patient had inflammatory bowel disease (ulcerative colitis) (Table 2).

The cause of EC has not been determined for any of the 44 EC cases reported so far. Generally, an allergic response to any antigen is assumed to be the cause. Nevertheless, the causative agent in each case has not always been identified (5-11).

In our patient, exposure to mites exacerbated her cholangitis. In her first hospitalization, her symptoms naturally improved without any special treatment just by being away from the allergen. However, re-exposure to the allergen after returning home caused her relapse, and cleaning the bed and carpet in her house helped improve her clinical symptoms and laboratory data again. Interestingly, we believe that the second hospitalization was due to re-exposure to mites by organizing the closet. Unlike the previous admission, there

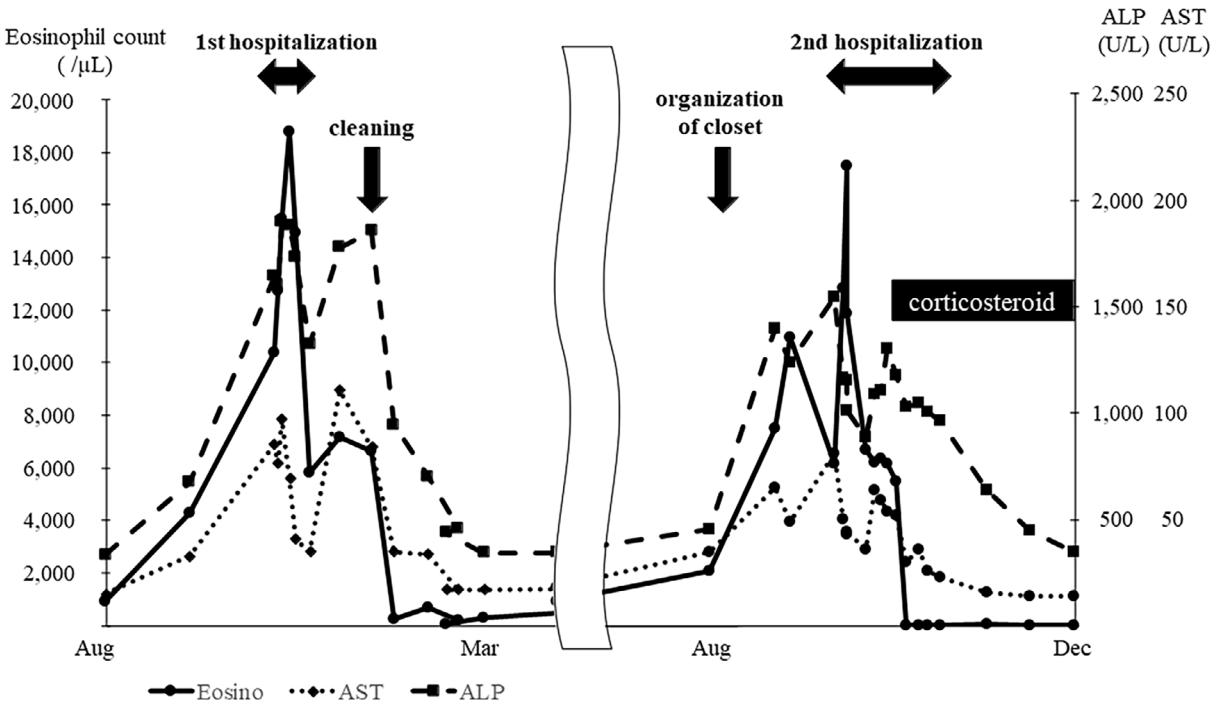

Figure 3. Clinical course and the change in the eosinophil count, AST, and ALT in the peripheral blood. AST: aspartate aminotransferase, ALP: alkaline phosphatase, CS: corticosteroid, Eosino: Eosinophil count

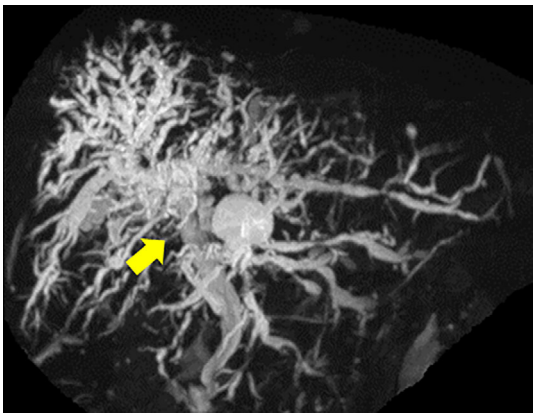

Figure 4. Magnetic resonance cholangiopancreatography (MRCP) after treatment with an oral corticosteroid. The stenosis of the hilar bile duct was improved (arrow).

was no improvement in the blood test despite isolation from the antigen. It is unclear why her blood data did not improve after the second hospitalization, but she may have been exposed to more allergens or been allergic to other substances. Therefore, we treated her with CS (Fig. 3).

Distinguishing between EC and PSC is usually difficult because both diseases show similar imaging findings, such as the dilation and stenosis of the bile duct. Only 5% of PSCs have extrahepatic bile duct lesions, which may help determine whether or not the stenosis is of the extrahepatic bile duct alone (12). Matsumoto et al. advocated that the EC bile duct image is reversible by treatment with CS (2), but bile duct stenosis often remains after treatment, as in the present case. Among individuals with EC, 30%-40% do not show eosinophilia (13-15). Our patient also showed no eosinophilia (eosinophil count >1,500/mm^3) for approximately 3 years of follow-up at our hospital and the previous hospital. Gunji et al. suggested that the differential diagnosis of PSC, especially without eosinophilia, is difficult without performing a bile duct biopsy (16). In this patient, the histological examination of the bile duct and liver biopsy revealed no characteristic findings of PSC and a high degree of eosinophil infiltration in the bile duct, which led to the diagnosis.

Importantly, a detailed examination of the pathology of her previous cholecystectomy specimen revealed that she had already suffered from EC 15 years prior. Jimenez-Saenz et al. reported that eosinophilic cholangitis was diagnosed by reexamining the gallbladder tissue from cholecystectomy performed five years earlier (17). If a patient who has had cholecystitis with an unknown cause in the past later develops bile duct stenosis, we should consider reviewing the histopathological findings of the gallbladder, as in the present case.

In conclusion, we encountered a patient with EC, the cause of which was a mite allergy. The diagnosis of EC is often difficult, but a detailed medical history and tests for various antigens aid not only in the identification of allergens but also in the diagnosis of EC.

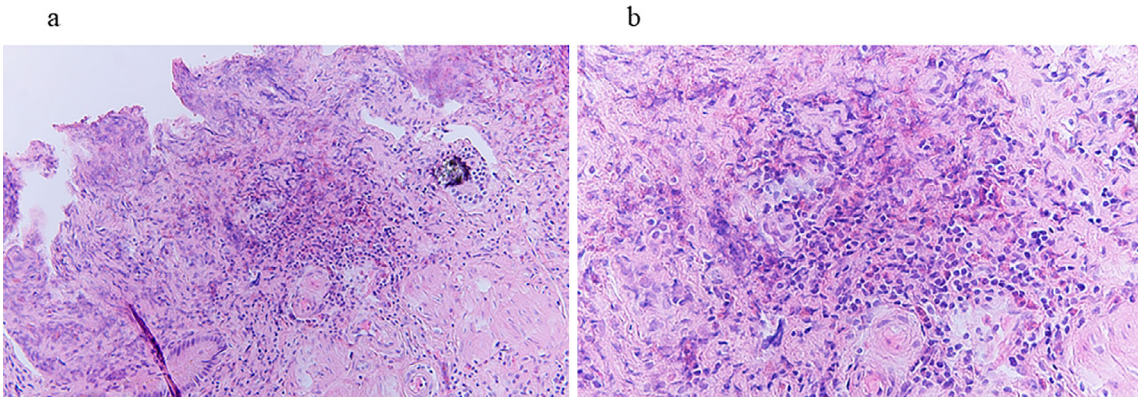

Figure 5. The cholecystectomy specimen revealed the infiltration of eosinophils into the wall of the gallbladder: (a) objective, 20× with Hematoxylin and Eosin (H&E) staining and (b) objective, 40× with H&E staining.

Table 2. Characteristics of Eosinophilic Cholangitis, Cholecystitis, and Cholangiopathy in 44 Cases.

Age	Median (IOR)	46 (13-84)
Gender, n (%)	Male	27 (61%)
	Female	17 (39%)
Peripheral eosinophils count, n	>1,500 /μL	21
	≤1,500 /μL	14
	ND	9
Bile duct stricture / wall thickness, n	Diffuse	17
	Hilar	14
	Extrahepatic	9
	Other	1
	ND	3
Comorbidity, n	allergic disease	4
	malignancy	3
	IBD	1
	Eosinophilic gastroenteropathy	1

ND, no data. IOR, Interquartile range. IBD, Inflammatory bowel disease.

The authors state that they have no Conflict of Interest (COI).

References

1. Platt ML, Kiesling VJ, Vaccaro JA. Eosinophilic Ureteritis Associated with Eosinophilic Cholangitis: A Case Report. J Urol **144**: 127-129, 1990.
2. Matsumoto N, Yokoyama K, Nakai K, et al. A case of eosinophilic cholangitis: imaging findings of contrast-enhanced ultrasonography, cholangioscopy, and intraductal ultrasonography. World J Gastroenterol **13**: 1995-1997, 2007.
3. Lai CH, Chin C, Chung HC, Liu H, Hwang JC, Lin HH. Clonorchiasis-associated perforated eosinophilic cholecystitis. Am J Trop Med Hyg **76**: 396-398, 2007.
4. Tenner S, Roston A, Lichtenstein D, Brooks D, Herlihy E, Carr-Locke D. Eosinophilic cholangiopathy. Gastrointest Endosc **45**: 307-309, 1997.
5. Fox H, Path MRC, Mainwamng AR, Path MRC. Eosinophilic Infiltration of the Gallbladder. Gastroenterology **63**: 1049-1052, 1972.
6. Felman RH, Sutherland DB, Conklin JL, Mitros FA. Eosinophilic cholecystitis, appendiceal inflammation, pericarditis, and cephalosporin-associated eosinophilia. Dig Dis Sci **39**: 418-422, 1994.
7. Duseja A, Nada R, Dhiman RK, et al. Eosinophilic cholangiopathy--a case report. Dig Dis Sci **50**: 1422-1425, 2005.
8. Shakov R, Simoni G, Villacin A, Baddoura W. Eosinophilic cholecystitis, with a review of the literature. Ann Clin Lab Sci **37**: 182-185, 2007.

9. Miura F, Asano T, Amano H, et al. Resected case of eosinophilic cholangiopathy presenting with secondary sclerosing cholangitis. World J Gastroenterol **15**: 1394-1397, 2009.

10. Keyal NK, Adhikari P, Baskota BD, Rai U, Thakur A. Eosinophilic Cholecystitis presenting with Common Bile Duct Sludge and Cholangitis: A Case Report. Journal of Nepal Medical Association **58**: 188-191, 2020.

11. Yoshihara R, Komai T, Nagafuchi Y, et al. Eosinophilic cholangitis with eosinophilic granulomatosis with polyangiitis: A case report and review of the literature. Allergol Int **69**: 154-156, 2020.

12. Hirschfield GM, Karlsen TH, Lindor KD, Adams DH. Primary sclerosing cholangitis. The Lancet **382**: 1587-1599, 2013.

13. Fukatsu S, Kitamura K, Asai Y, et al. A case of juvenile eosinophilic cholangitis: Rapid peripheral blood hypereosinophilia after admission leading to diagnosis. JGH Open **5**: 314-316, 2021.

14. Hokuto D, Yamato I, Nomi T, et al. Eosinophilic cholangitis coexisted with idiopathic thrombocytopenic purpura: Report of a case. Hepatol Res **45**: 595-600, 2015.

15. Nashed C, Sakpal SV, Shusharina V, Chamberlain RS. Eosinophilic cholangitis and cholangiopathy: a sheep in wolves clothing. HPB Surg **2010**: 906496, 2010.

16. Gunji N, Katakura K, Takahashi A, et al. Concurrent primary sclerosing cholangitis and eosinophilic colitis. Intern Med **53**: 2319-2324, 2014.

17. Jimenez-Saenz M, Villar-Rodriguez JL, Torres Y, et al. Biliary tract disease: a rare manifestation of eosinophilic gastroenteritis. Dig Dis Sci **48**: 624-627, 2003.

The Internal Medicine is an Open Access journal distributed under the Creative Commons Attribution-NonCommercial-NoDerivatives 4.0 International License. To view the details of this license, please visit (https://creativecommons.org/licenses/by-nc-nd/4.0/).

© The Japanese Society of Internal Medicine
Intern Med Advance Publication