Respiratory Medicine Case Reports 20 (2017) 156–159

Contents lists available at ScienceDirect

Respiratory Medicine Case Reports

journal homepage: www.elsevier.com/locate/rmcr

Case report

Invasive pulmonary aspergillosis in a steroid-dependent asthmatic

Bibi Aneesah Jaumally [a,*], Ahmed M. Salem [a], Ala Eddin Sagar [b], George Pyrgos [c]

[a] Department of Medicine, Medstar Harbor Hospital, 3001 South Hanover Street, Baltimore, MD 21225, United States
[b] Division of Critical Care Medicine, University of Texas Health Center at Houston, 7000 Fannin St #12, Houston, TX 77030, United States
[c] Department of Medicine, Medstar Franklin Hospital, 9000 Franklin Square Dr., Baltimore, MD 21237, United States

ARTICLE INFO

Article history:
Received 6 December 2016
Received in revised form
12 February 2017
Accepted 13 February 2017

1. Introduction

Aspergillus species primarily affects the lungs, causing one of four syndromes: Allergic bronchopulmonary aspergillosis (ABPA), chronic necrotizing pulmonary aspergillosis (CNPA), aspergilloma or invasive pulmonary aspergillosis (IPA) [1]. We present a case of IPA in a steroid-dependent asthmatic.

2. Case presentation

A 51-year old Caucasian female with a history of severe persistent asthma that is steroid-dependent with multiple prior intubations presented with 2 weeks of progressive shortness of breath associated with a cough productive of yellow sputum. She denied any fever, runny nose, recent travel or sick contacts but admits to unintentional weight loss. She tried increasing her prednisone dose at home (up to 100 mg/day) without significant relief. On physical examination, she was noted to be tachycardic and in mild respiratory distress with an inability to lie flat. She had diffuse inspiratory and expiratory wheezing on auscultation. Her WBC count on admission was noted to be elevated at 24.6×10^9/L and she was found to be in respiratory alkalosis on ABG with a pH of 7.57, pCO2 of 26 and oxygen saturation of 90% on room air. She had a positive pneumococcal urinary antigen and her PCR nasal swab demonstrated rhinovirus was present. Her initial CT scan displayed subtle ground glass opacities in bilateral upper lobes. Despite treatment for community-acquired pneumonia with levofloxacin, she did not have any improvement and had a recurrence of her symptoms three days following her discharge. She was readmitted, her steroid dose was increased, and she required intermittent BiPAP as well as Heliox to improve her oxygenation. A repeat CT scan showed new multilobar pulmonary infiltrates (Fig. 1). She was started empirically on amphotericin B and bronchoscopy was performed which demonstrated the presence of black vascular lesions (Fig. 2) in the trachea spreading bilaterally. Two days following the initiation of antifungal treatment the patient showed some clinical improvement with repeat ABG showing a pH of 7.47 and pCO2 of 44 with adequate oxygenation. Repeat bronchoscopy demonstrated resolution of the black vascular lesions (Fig. 3). Both serum and bronchoalveolar lavage *Aspergillus* galactomannan antigen were negative but the (1 → 3)-β-D-Glucan assay was positive. BAL cultures from the initial bronchoscopy grew *Aspergillus niger*. Her antifungal regimen was switched to voriconazole and she was discharged on 200mg twice a day for 6 months with outpatient follow up with Infectious Diseases. Her steroid dosage was also tapered slowly to her regular home dose of 10mg daily. Attempting to wean her off completely from prednisone resulted in continued wheezing and dyspnea. She has not had any recurrence of IPA.

3. Discussion

IPA is a rapidly progressive infection, typically occurring in patients who are severely immunosuppressed, including those with prolonged neutropenia, those who have received bone marrow or solid organ (especially lung) transplants, those receiving cytotoxic or prolonged corticosteroid therapy and patients with advanced AIDS or chronic granulomatous disease. IPA is characterized by invasion of blood vessels, resulting in multifocal infiltrates, which are often wedge-shaped, pleural-based, and cavitary. It is often fatal with mortality rate estimates between 30 and 95%. Patients with chronic obstructive pulmonary disease (COPD) have increasing susceptibility towards IPA as well. There are several reasons for this occurrence, which include structural changes in lungs related to the pulmonary disease, the use of long-term or increased cumulative use of short-term steroid treatments, frequent hospitalizations and antibiotic treatment, and co-morbid factors such as alcoholism, diabetes mellitus or malnutrition [2,4]. Treatment is with voriconazole or amphotericin B. We suspect that our patient had such

* Corresponding author.
E-mail address: aneesah.jaumally@gmail.com (B.A. Jaumally).

http://dx.doi.org/10.1016/j.rmcr.2017.02.007
2213-0071/© 2017 The Authors. Published by Elsevier Ltd. This is an open access article under the CC BY-NC-ND license (http://creativecommons.org/licenses/by-nc-nd/4.0/).

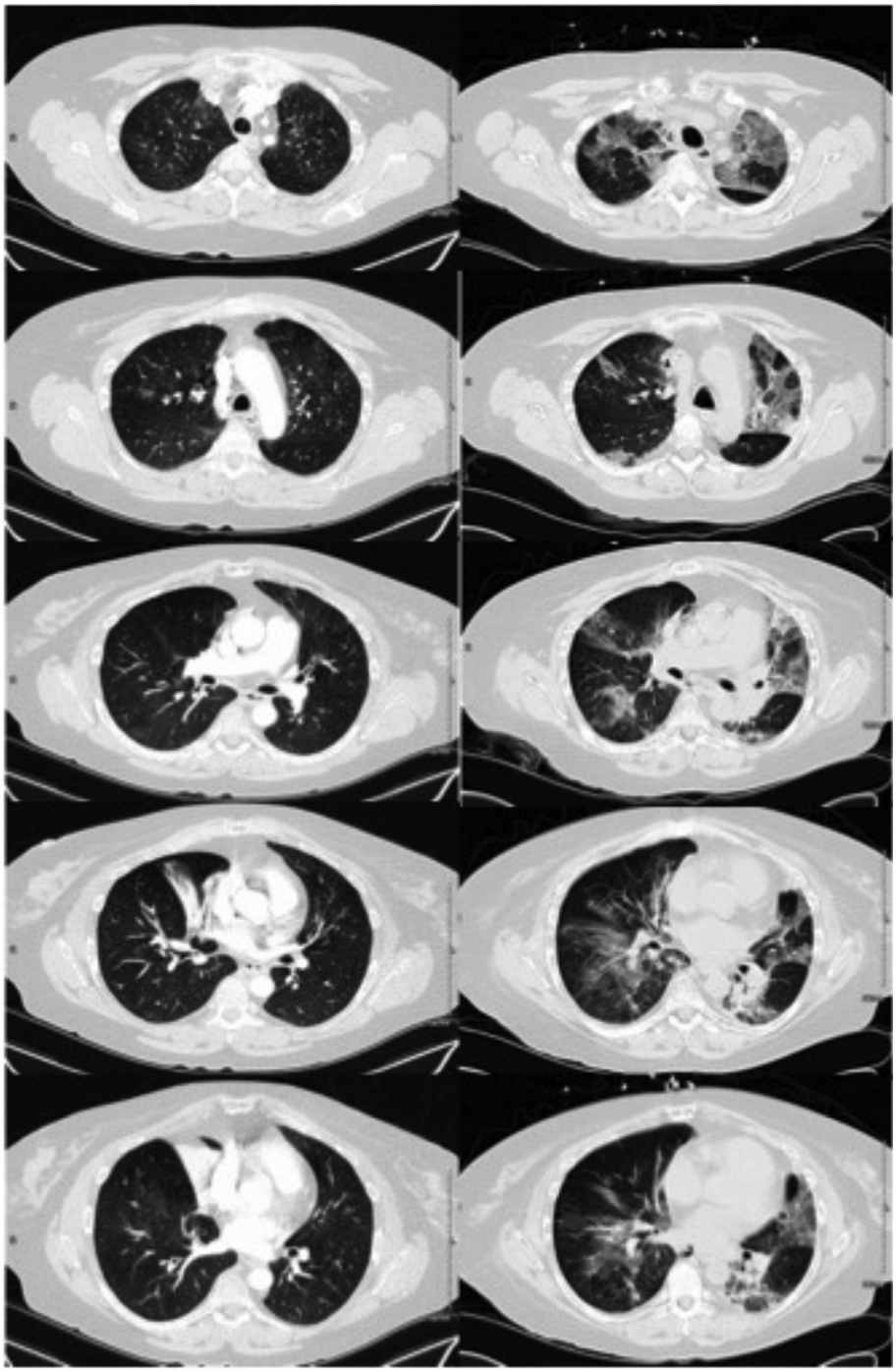

Fig. 1. CT scan on initial presentation (on left) showed subtle ground glass opacity bilaterally. In spite of broad-spectrum antibiotic coverage, the patient continued to have increasing oxygen requirements. Repeat CT scan performed a few days later (on right) demonstrated new multilobar pulmonary infiltrates.

dramatic improvement due to early initiation of antifungal therapy based on a high index of suspicion prior to availability of culture results.

Steroids diminish the host response against *Aspergillus* in a variety of ways including inhibiting neutrophils, suppressing type 1 T helper cells, enhancing cytokine release from type 2 T helper cells and inhibiting ROI production [4]. Mortality in patients with COPD and IPA has been shown to be higher despite administration of effective antifungal therapy. In COPD patients found to have IPA, 60.3% and 39.7% had stage III and IV disease respectively (assessed through the GOLD criteria) [3] whereas there have been no reported IPA cases in patients with stage I or II disease, suggesting an increased risk of infection with increasing severity of the pulmonary condition. Galactomannan is a heteropolysaccharide present in the cell wall of *Aspergillus*. The immunoassay that detects galactomannan in serum samples could be beneficial in determining IPA in its early stages [3]. However, this assay may only be beneficial in neutropenic patients, since higher neutrophil count translates to a delayed angioinvasive phase resulting in low serum galactomannan levels. Hence, in non-neutropenic patients, it is

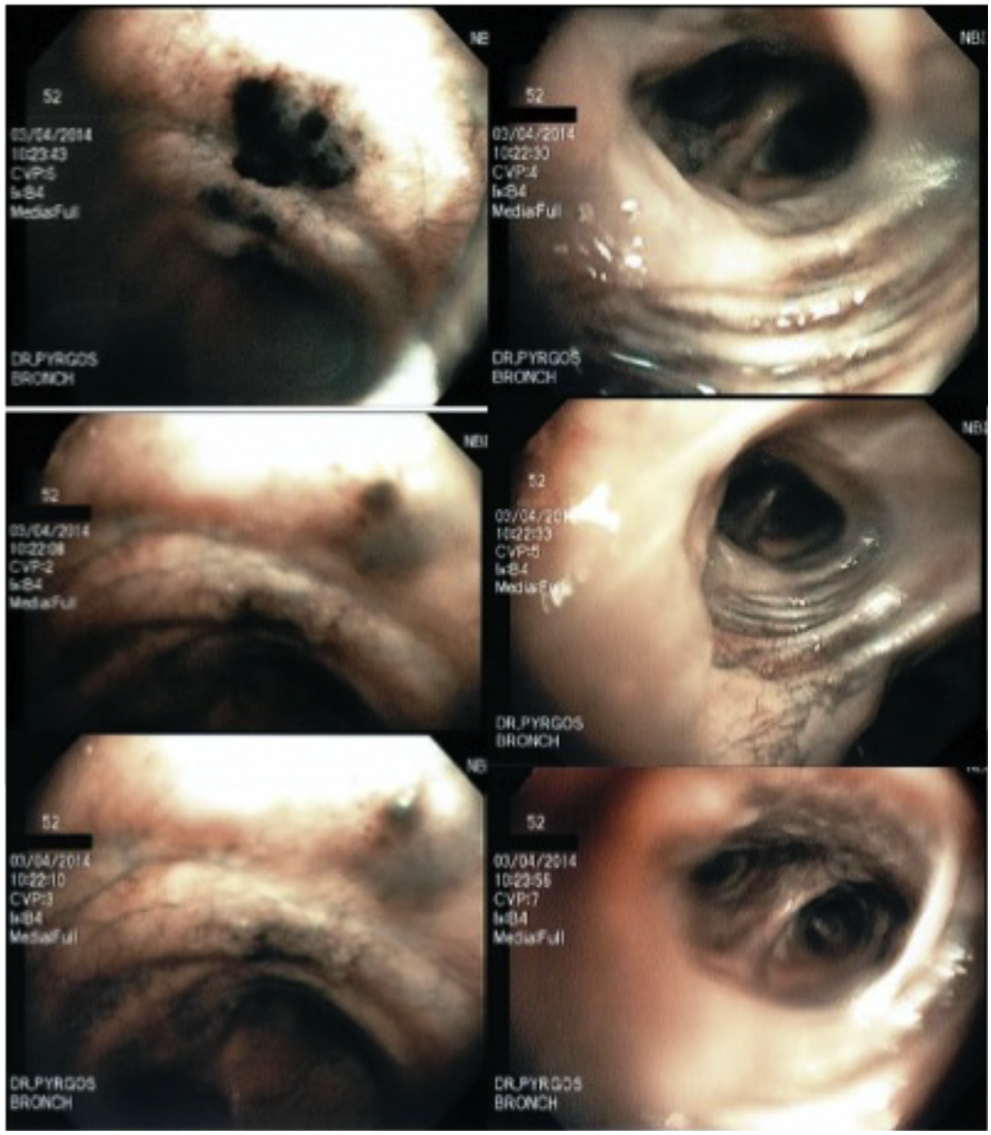

Fig. 2. Initial bonchoscopy illustrating black submucosal vascular lesions.

essential to obtain a BAL [3]. The sensitivity of serum and BAL galactomannan assay has been reported at 38% and 92% respectively [5]. It is also crucial to have IPA as a differential diagnosis for high-risk patients, such as those with long term steroid use and obstructive lung disease such as asthma or COPD so that adequate workup and therapy can be initiated.

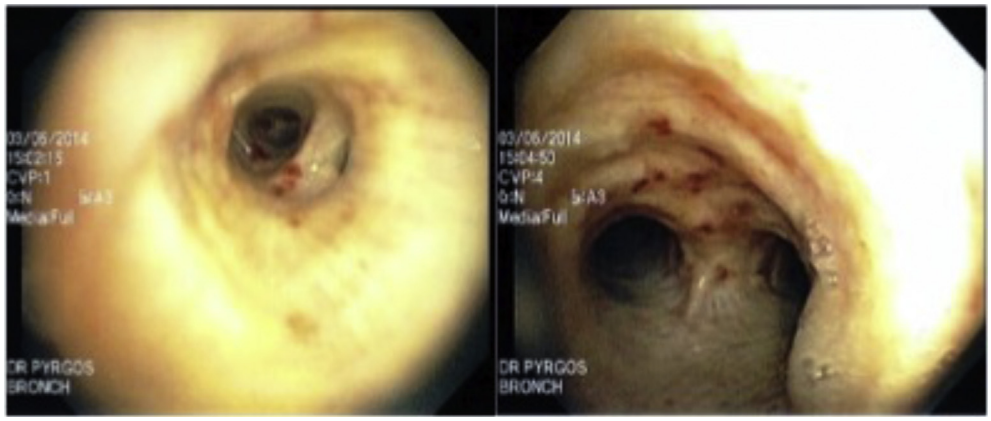

Fig. 3. Repeat bonchoscopy performed 2 days later following administration of amphotericin B shows resolution of black submucosal vascular lesions.

4. Conclusion

Dyspnea and sepsis among patients with prolonged and high dose corticosteroid use presents a diagnostic and therapeutic challenge. Among such hosts presenting with respiratory failure, invasive pulmonary aspergillosis should be in the differential diagnosis.

References

[1] J. Guinea, M. Torres-Narbona, P. Gijón, et al., Pulmonary aspergillosis in patients with chronic obstructive pulmonary disease: incidence, risk factors, and outcome, Clin. Microbiol. Infect. 16 (2010) 870–877.
[2] F. Ader, S. Neir, R. Le Berre, et al., Invasive pulmonary aspergillosis in chronic obstructive pulmonary disease: an emerging fungal pathogen, Clin. Microbiol. Infect. 11 (2005) 427–429.
[3] M. Nucci, S.A. Nouér, D. Cappone, E. Anaissie, Early diagnosis of invasive pulmonary aspergillosis in hematologic patients: an opportunity to improve the outcome, Haematologica 98 (2013) 1657–1660.
[4] P. Bulpa, A. Dive, Y. Sibille, Invasive pulmonary aspergillosis in patients with chronic obstructive pulmonary disease, Eur. Respir. J. 30 (4) (2007) 782–800.
[5] S.Y. Park, S.O. Lee, S.H. Choi, J.Y. Jeong, H. Sung, M.N. Kim, et al., Serum and bronchoalveolar lavage fluid galactomannan assays in patients with pulmonary aspergilloma, Clin. Infect. Dis. 52 (7) (2011) e149–e152.