[Downloaded free from http://www.ijo.in on Sunday, April 13, 2014, IP: 160.80.2.8] || Click here to download free Android application for this journal



# Excellent outcome of *Aspergillous endophthalmitis* in a case of allergic bronchopulmonary aspergillosis

*Balbir Khan, Ravi Vohra, Rajwinder Kaur, Sukhwinder Singh, Ashapritpal, Vartika*

While invasive aspergillosis occurs typically in severely immunocompromised patients, cases of surgical site infections have been reported in immunocompetent individuals. The purpose is to report an eye with post-operative *Aspergillus endophthalmitis*, which achieved a good visual outcome following early and aggressive treatment. A young patient, known case of allergic bronchopulmonary aspergillosis presented to us with post-cataract surgery endophthalmitis. He was treated with pars plana vitrectomy and intravitreal voriconazole and systemic itraconazole. The patient regained a vision of 20/30 with follow up of 2 years.

**Key words:** Aspergillosis, endophthalmitis, vitrectomy, voriconazole

While invasive aspergillosis occurs typically in severely immunocompromised patients, cases of surgical site infections have been reported in immunocompetent individuals. It was unique case of *aspergillous endophthalmitis* associated with allergic broncho-pulmonary aspergillosis. No such case has been reported till date. Our case indicates that early pars plana vitrectomy and aggressive treatment with intravitreals and systemic anti-fungal drugs can lead to better visual outcome.

| Access this article online | |
|---|---|
| Quick Response Code: | Website: www.ijo.in |
| | DOI: 10.4103/0301-4738.125552 |

Department of Ophthalmology, Gian Sagar Medical College and Hospital, Banur, Patiala, Punjab, India

Correspondence to: Dr. Balbir Khan, H no-78- S.S.T Nagar, Patiala, Punjab - 147 001, India. E-mail: balbirkhan@yahoo.com

Manuscript received: 21.05.11; Revision accepted: 08.08.12

## Case Report

A 25-year-old male was referred to us with a 10-day history of decreased vision in the left eye after cataract surgery elsewhere. There was no history of diabetes or ocular trauma.

Initial examination revealed a visual acuity of counting finger close to face in left eye and 20/30 in right eye. The anterior segment in right eye revealed aphakia after being operated for steroid-induced cataract elsewhere and in left eye showed 3 mm hypopyon and intraocular lens. Cornea was clear. Vitreous cavity was hazy with no view of the retina in left eye. Ultrasonography showed multiple moderate to high reflective echoes with attached retina.

He was a known case of bronchial asthma and was on irregular treatment of steroids. He was diagnosed to be a case of allergic bronchopulmonary aspergillosis at our institute on the basis of diagnostic criteria for diagnosing ABPA.[1] His total white blood cell count was 19000/cmm. Differential leukocyte count revealed raised eosinophil count. Serum Ig E levels were 145 IU/ml.[3] ESR was 58 mm/hr, and C-reactive protein was 1 mg/L. Wheal-and-flare skin reaction to *Aspergillus* antigen was positive. Sputum for acid-fast bacilli was negative. Serology for HIV and VDRL was negative. Chest X-ray revealed wedge-shaped pleural-based densities.

Diagnostic and therapeutic pars plana vitrectomy was done on the second day of presentation. Vitreous aspirate showed moderate number of neutrophils, branching septate hyphae and no bacteria on Gram stain [Fig. 1]. KOH mount revealed brancing septate hyphae. Intravitreal voriconazole 50 microgram/0.1 ml was given. The culture for bacteria was negative, but Sabouraud's agar grew *A. flavus*.

He was put on topical voriconazole (10 mg/ml) drops one-hourly, and oral Itraconazole 200 mg twice-a-day was given for 6 wks. Oral prednisolone 1 mg/kg/bodyweight and topical prednisolone 1% were started in tapering doses. Two weeks post-vitrectomy BCVA in left eye was 20/50, anterior segment showed no activity [Fig. 2]. Retina was attached. One-month postoperative visual acuity improved to 20/30 in left eye. Fundus examination showed posterior vitreous detachment and a horseshoe tear in superonasal quadrant. Barrage laser was done for the same. After 1 month, his vision dropped to 20/70 and fundus showed a partial rhegmatogenous retinal detachment. He underwent revitrectomy with Belt Buckle with 360 degree Endolaser with silicone oil insertion. One-week post-operative showed attached retina [Fig. 3]. Two months post-surgery vision improved to 20/30. He was followed every month for 1 year, during which no complications developed. After Silicone oil removal, his BCVA is 20/30.

[Downloaded free from http://www.ijo.in on Sunday, April 13, 2014, IP: 160.80.2.8] || Click here to download free Android application for this journal



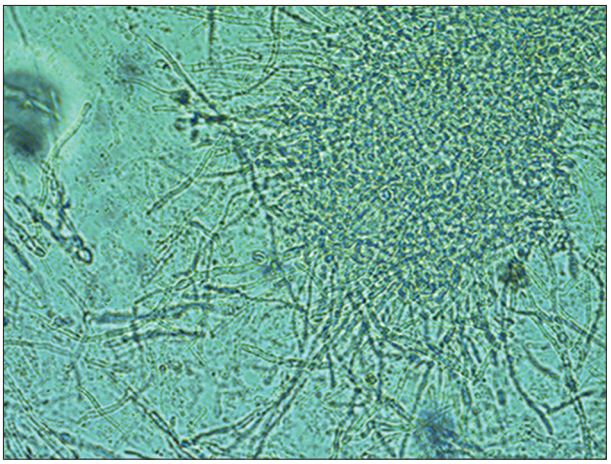

**Figure 1:** Septate hyphae in KOH stain

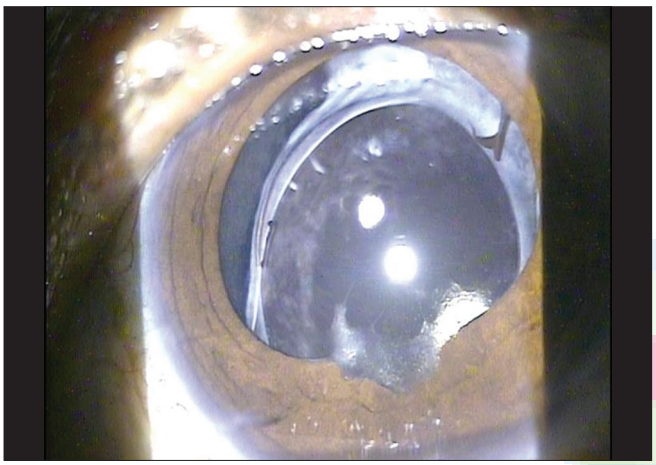

**Figure 2:** Anterior segment photo of the patient 2 years postoperatively

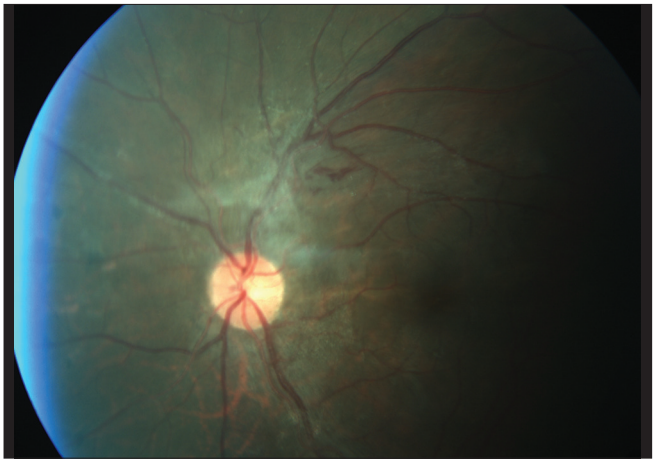

**Figure 3:** Posterior segment photo of the patient 2 year postoperatively

## Discussion

Allergic bronchopulmonary aspergillosis is a hypersensitivity reaction to *A. fumigatus* that occurs almost exclusively in patients with asthma or, less commonly, cystic fibrosis. Symptoms and signs are those of asthma with the addition of productive cough and, occasionally, fever and anorexia. Diagnosis is suspected based on history and imaging tests and confirmed by *Aspergillus* skin testing and measurement of IgE levels, circulating precipitins, and *A. fumigatus*–specific antibodies. Treatment is with corticosteroids and, in patients with refractory disease, itraconazole.

Endogenous *Aspergillus endophthalmitis* is reported in immunocompromised individuals.[2-4] Exogenous *Aspergillus endophthalmitis* is reported following cataract surgery, keratoplasty, and eye trauma.

A review of literature revealed only 5 other cases of endogenous *Aspergillosis endophthalmitis* in immunocompetent patients.[2-4] Recognized risk factors include a history of immunocompromise, malignancy, organ transplantation, long-term corticosteroid use, drug abuse, ocular surgery, trauma, endocarditis, and chronic obstructive airways disease.[4-6] As in our patient, 3 of the reported immunocompetent cases had been treated with corticosteroids for their symptoms prior to the diagnosis being made.[2,3] The portal of entry in our case was probably the lungs. It would be reasonable to assume that the administration of steroids in the absence of anti-fungal agent may have worsened the condition in our case.

There are only 2 patients reported in the literature with endogenous *A. flavus* who recovered useful vision, from a total of 6 patients, with endogenous *Aspergillous spp*. who received a final visual acuity of 20/200 or better. Both patients underwent an early pars plana vitrectomy with intravitreal and systemic amphotericin B and recovered vision to 20/70. During the vitrectomy, it is preferred to avoid a very posterior vitrectomy as well as peeling of exudates and membranes over the retina to avoid iatrogenic retinal tears. These can occur in endophthalmitis as the retina tends to be edematous, necrotic, and friable.[7] Poor visual outcomes were correlated with macular lesions of *Aspergillous*.[5,8]

Voriconazole is a second generation synthetic derivative of fluconazole.[9] Voriconazole is an effective agent for treatment of fungal endophthalmitis; it has a broad spectrum of activity. Intravitreal dose of Voriconazole up to 100 microgram/ml is considered safe for the retina.[10] Voriconazole is superior or at least similar to amphotericin B against common and rare yeast and mould infections. It is suggested that voriconazole should be considered as a first-line intravitreal agent for treatment of fungal endophthalmitis.[10]

Itraconazole exhibits a favorably low MIC for many species of *Aspergillous*, and in selected reports, it has shown a favorable response for the treatment of invasive aspergillosis. The vitreous penetration of itraconazole is better than amphotericin but remains only a fraction of the serum level.[11,12] It is suggested that oral fluconazole or itraconazole should be included in the regime.

## Conclusion

Endogenous fungal endophthalmitis should be considered in the differential diagnosis of progressive intraocular inflammation of unknown cause in persons predisposed to systemic fungal infection. When the infection is isolated to the choroid and retina, systemic treatment alone may be curative. When there is vitreous involvement, a vitrectomy and intravitreal injection of voriconazole should be considered.

[Downloaded free from http://www.ijo.in on Sunday, April 13, 2014, IP: 160.80.2.8] || Click here to download free Android application for this journal



Fungal endophthalmitis following early and aggressive treatment results in good visual outcome.

## References


1. Stevens DA, Moss RB, Kurup VP, Knutsen AP, Greenberger P, Judson MA, *et al*. Allergic bronchopulmonary aspergillosis in cystic fibrosis-state of the art: Cystic Fibrosis Foundation Consensus Conference. Clin Infect Dis 2003;37:S225-64.
2. Agarwal M, Biswas J, Mathur U, Sijwali MS, Singh AK. Aspergillus iris granuloma in a young male: A case report with review of literature. Indian J Ophthalmol 2007;55:73-4.
3. Myles WM, Brownstein S, Dechenes J. Clinically unsuspected bilateral Aspergillus endophthalmitis. Can J Ophthalmol 1996;32:182-4.
4. Valluri S, Moorthy RS, Liggett PE, Rao NA. Endogenous Aspergilllus endophthalmitis in an immunocompetent individual. Int Ophthalmol 1993;17:131-5.
5. Leibovitch I, Lai T, Raymond G, Zadeh R, Nathan F, Selva D. Endogenous endophthalmitis. A 13-year review at a tertiary hospital in South Australia. Scand J Infect Dis 2005;37:184-9.
6. Anaissie EJ, Stratton SL, Dignani MC. Pathogenic Aspergillus species recovered from a hospital water system: A 3-year prospective study. Clin Infect Dis 2002;34:780-9.
7. Charles S. Witreous Microsurgery. 2nd ed. Baltimore: Williams and Wilkins; 1987. p. 195-8.
8. Weishaar PD, Flynn HW, Murray TG, Davis JL, Barr CC, Gross JG, *et al*. Endogenous Aspergillus endophthalmitis. Clinical features and treatment outcomes. Ophthalmology 1998;105:57-64.
9. Walsh TJ, Dixon DM. Nosocomial aspergillosis: Environmental microbiology, hospital epidemiology, diagnosis and treatment. Eur J Epidemiol 1989;5:131-42.
10. Gao H, Pennesi M, Shah K, Qiao X, Hariprasad SM, Mieler WF, *et al*. Safety of intravitreal voriconazole: Electroretinographic and histopathologic studies. Trans Am Ophthalmol Soc 2003; 101:183-90.
11. Denning DW, Lee JY, Hostetler JS, Pappas P, Kauffman CA, Dewsnup DH, *et al*. NIAID mycoses study group multicenter trial of oral itraconazole therapy for invasive aspergillosis. Am J Med 1994;97:135-44.
12. Breit SM, Hariprasad SM, Mieler WF, Shah GK, Mills MD, Grand MG. Management of Endogenous Endophthalmitis with Voriconazole and Caspofungin. Am J Ophthalmol 2005;139:135-40.


**Cite this article as:** Khan B, Vohra R, Kaur R, Singh S, A, V. Excellent outcome of *Aspergillous endophthalmitis* in a case of allergic bronchopulmonary aspergillosis. Indian J Ophthalmol 2014;62:352-4.

**Source of Support:** Nil. **Conflict of Interest:** None declared.