Medical Mycology Case Reports 10 (2015) 7–10

Contents lists available at ScienceDirect

Medical Mycology Case Reports

journal homepage: www.elsevier.com/locate/mmcr

Fever and multilobular mass of the right lung in a young adult with asthma

Adamantia Sotiriou, Nikolaos Koulouris, Petros Bakakos *

1st University Department of Respiratory Medicine, Athens, Greece

ARTICLE INFO

Article history:
Received 26 October 2015
Received in revised form
30 November 2015
Accepted 4 December 2015
Available online 5 December 2015

Keywords:
Asthma
Aspergillus fumigatus
Allergic bronchopulmonary aspergillosis

ABSTRACT

We report a case of a 37-year-old mild asthmatic male presenting with fever, productive cough and chest pain. The chest x-ray showed a multilobular perihilar shadow of the right lung with a mass-like appearance, confirmed by the CT-scan. He was diagnosed with allergic bronchopulmonary aspergillosis (ABPA). ABPA usually manifests as chronic asthma, recurrent pulmonary infiltrates and bronchiectasis. However, it can rarely be seen in patients with mild asthma and with an unusual radiological presentation of a solid mass.

© 2015 International Society for Human and Animal Mycology. International Society for Human and Animal Mycology Published by Elsevier B.V. All rights reserved.

1. Introduction

Allergic bronchopulmonary aspergillosis (ABPA) is an allergic pulmonary disorder that represents a hypersensitivity reaction to *Aspergillus fumigatus*. It is clinically manifested as chronic asthma, recurrent pulmonary infiltrates and bronchiectasis [1-3]. The incidence of the disease is 1–2% among asthma patients with increasing numbers in patients with corticosteroid-dependent and/or difficult to treat asthma (up to 15%) [1,3,4]. ABPA also occurs in patients with cystic fibrosis. The condition remains underdiagnosed with reports of mean diagnostic latency of even 10 years between the occurrence of symptoms and the diagnosis.

2. Case

A 37-year-old patient with a history of mild asthma presented with high grade fever, productive cough and pleuritic chest pain. The symptoms occurred 48 h prior to medical consulting.

He was diagnosed with asthma 3 years before the appearance of these symptoms. He did not smoke or drink alcohol or use any illicit drugs. He had normal physical activities and had been working in a metal pipe industry for the past 2 years. He was living in a clean apartment. His asthma treatment 6 months prior to the ER visit was inhaled salbutamol per needed (step 1-GINA). He had never experienced any severe asthma exacerbations or been admitted to the hospital due to asthma. His latest lung function tests were normal.

On admission (Day 0), he was febrile (*T*: 38.5 °C) , normotensive (BP: 120/70 mmHg) and with sinus tachycardia (HR: 98/min). Chest auscultation revealed neither wheezing nor crackles and the rest of the physical examination was normal. His laboratory tests showed a mild leucocytosis (WBC: 12.200 cells/μL) with a predomination of neutrophils (70%), and low C-reactive protein (1.1 mg/dl) and erythrocyte sedimentation rate (25 mm/1 h). His renal and hepatic functions were normal. His arterial blood gases were PO_2:78 mmHg, PCO_2:35 mmHg, pH:7.43. A test for human immunodeficiency virus was negative. His chest x-ray showed a multilobular perihilar shadow in the right lung with a mass-like appearance and another infiltrate in the lower right lung field (Fig. 1A).

A computed tomography of the lungs was performed the following day (Day 1) which confirmed the pulmonary infiltrates on the right lung with additional high-enhancement after intravenous administration of contrast and a smaller nodule in the upper lobe of the left lung (Fig. 2A).

His pulmonary function tests (Day 1) were normal (FEV1: 87% predicted (3.37 lt) with no response to bronchodilation (post brochodilation FEV1: 89% predicted (3.45 lt)) and FEV1/FVC ratio: 80%. The Mantoux dermoreaction was negative (0 mm). Sputum cultures were negative for bacteria and the Ziehl–Nielsen stain was negative for the presence of *Mycobacterium tuberculosis* and *Mycobacterium avium* complex. Electrophoresis of proteins and immunoglobulins was normal. A urine specimen showed no sign of proteinuria or erythrocyte cylinders. Antinuclear antibodies were negative. On re-examination (Day 5) during his hospitalisation, peripheral blood eosinophilia was noted (19%) with a total

* Corresponding author.

http://dx.doi.org/10.1016/j.mmcr.2015.12.001
2211-7539/© 2015 International Society for Human and Animal Mycology. International Society for Human and Animal Mycology Published by Elsevier B.V. All rights reserved.

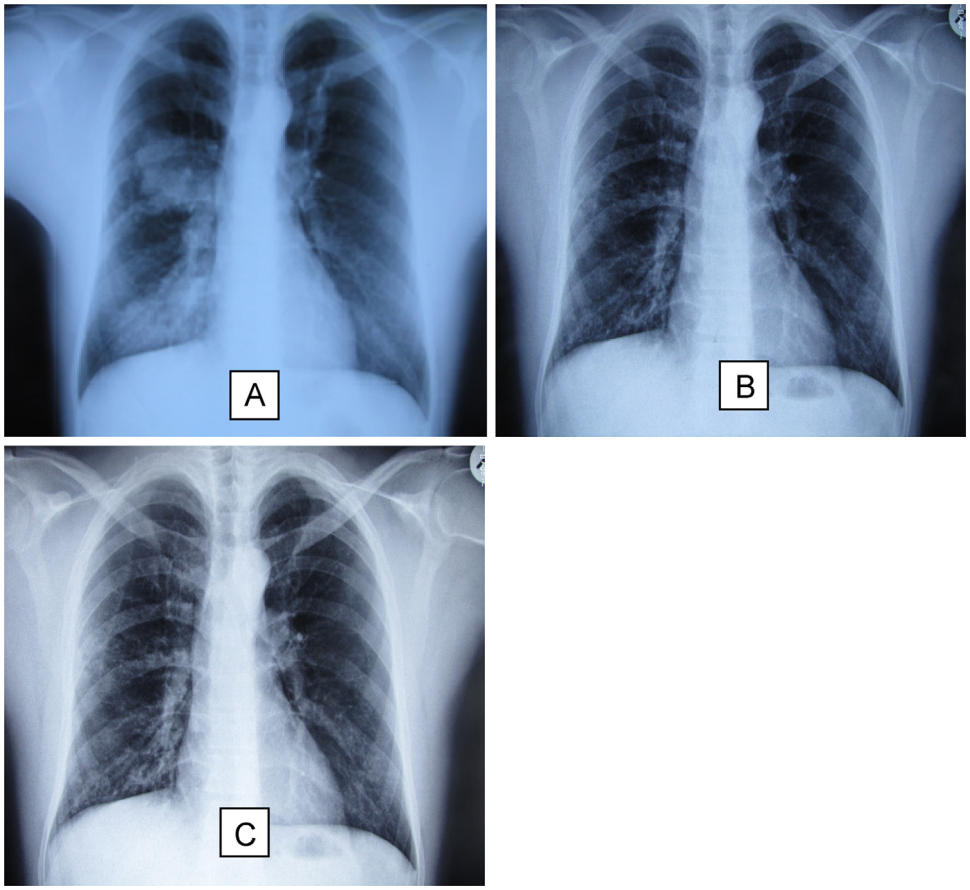

Fig. 1. A. Chest x-ray on admission B. Chest x-ray 4 weeks after the commencement of treatment with oral corticosteroids C. Chest x-ray after 7 months of treatment with oral corticosteroids showing disappearance of the multilobular perihilar infiltrates of the right lung.

eosinophil count of 1810/μl. Stool paracitologic examination was negative.

A bronchoscopy was performed on Day 6 which showed mucosal oedema of the right upper bronchus and to a lesser extent of the middle segmental bronchus without signs of endoluminal mass. The bronchoalveolar lavage revealed no elevated total number of cells with a proportion of eosinophils 9%. The cytologic examination of the BAL was negative and the bronchial washing cultures were negative for bacteria (including nocardia and actinomyces), fungi, *Mycobacterium tuberculosis* and *Mycobacterium avium* complex. The endobronchial biopsy of the oedematous bronchial wall revealed absence of granuloma but noted metaplasia of the bronchial epithelium suggesting a high probability of neoplasia adjacent to the tissue sample obtained.

Due to the patient's history of asthma, a test for total IgE levels was performed which was found significantly elevated (2927.32 IU/ml). Aspergillus skin test, IgE and IgG antibodies for Aspergillus were also positive. A diagnosis of allergic bronchopulmonary aspergillosis was established. The patient was treated with oral corticosteroids (prednisolone 0.5 mg/kgBW) for 4 weeks with regression of the symptoms and amelioration of the chest x-ray findings (Fig. 1B).

Following tapering of the dose, IgE levels were measured 8 weeks after initiation of treatment, revealing a $>50\%$ diminution of the initial IgE value (937 IU/ml). Oral corticosteroids were further tapered by 5-10mg every 2 weeks and the patient was monitored with symptoms, clinical examination and chest x-ray. At 4 months of treatment a high resolution computed tomography of the chest (HRCT) was performed, which showed disappearance of the pulmonary infiltrates and presence of ipsilateral centrilobular cystic bronchiectasis (Fig. 2B). Moreover, the small nodule of the left upper lobe was not visible anymore.

The patient was last seen 7 months after the initiation of treatment. He was on perfect clinical state, with no symptoms, while receiving 5 mg of prednisolone on alternative days. His chest x-ray showed further amelioration (Fig. 1C).

3. Discussion

This patient was diagnosed with ABPA and was treated successfully with oral corticosteroids. He had no further symptoms and his chest x-ray improved. During the follow-up, total serum IgE levels also diminished more than 35% of the initial value, which is also regarded as response to therapy and allows tapering of the corticosteroid dose. Although ABPA mostly occurs in a context of severe asthma, this patient had mild asthma and his lung function tests never showed any deterioration. The initial absence of central bronchiectasis confirms that ABPA can be diagnosed even without the characteristic radiological presence of central bronchiectasis, especially in the acute phase of the disease [1,4,5]. Nevertheless, central bronchiectasis appeared in the patient's CT scanning of the chest four months after the initiation of treatment. Peripheral blood eosinophilia in a symptomatic asthma patient should always raise the suspicion of ABPA. However, our patient presented with fever and mild cough without any obvious deterioration of his asthma and without peripheral eosinophila on admission. However, it should be noted that blood eosinophilia is not regarded an essential criterion for the diagnosis of ABPA [1,5].

In 1986, Rosenberg and Patterson proposed eight major criteria for the diagnosis of ABPA [1,4]. These criteria included (1) a history of asthma, (2) elevated levels of total IgE in the serum (>1000 IU/ml), (3) elevated levels of specific IgE to *A. fumigatus*,

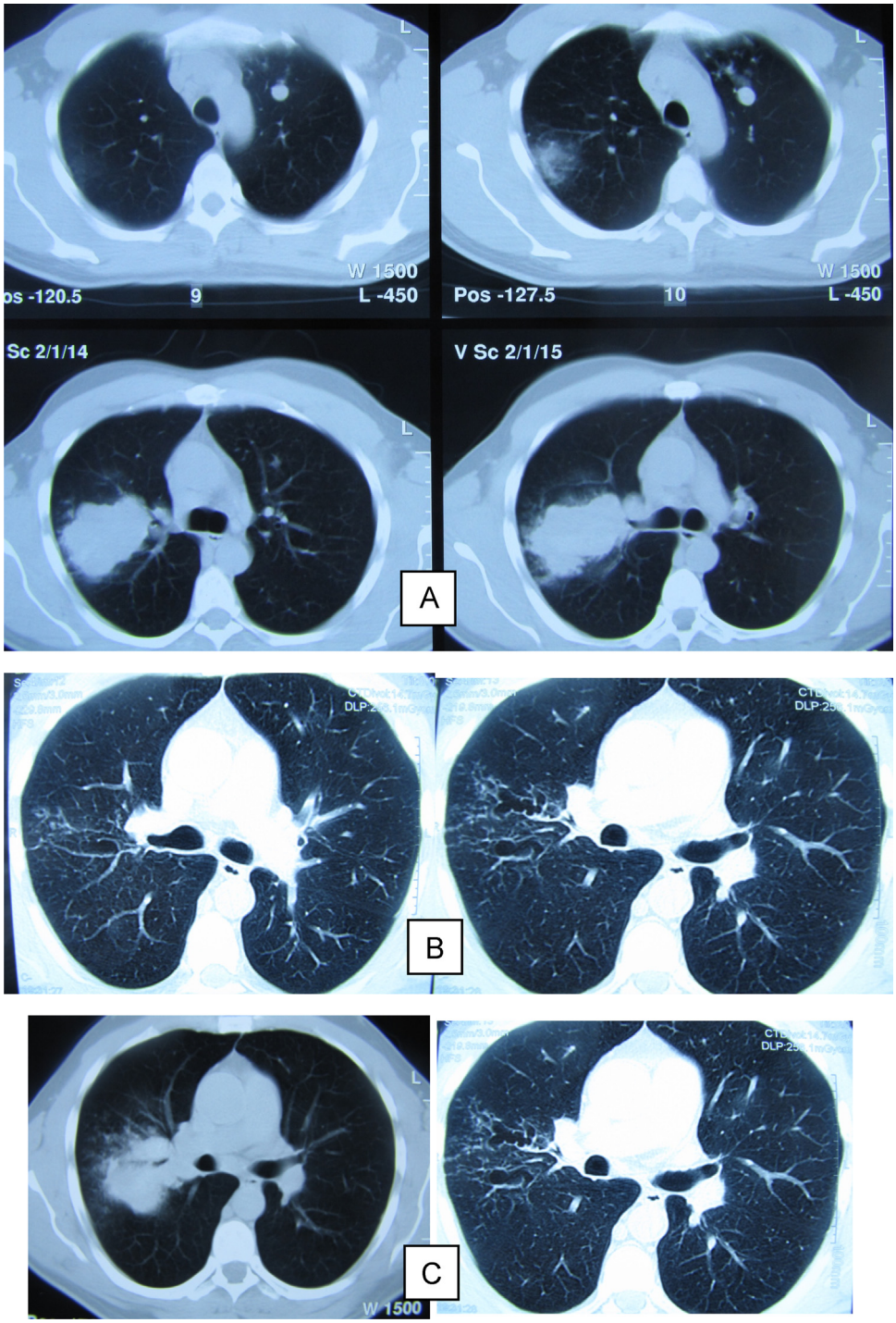

Fig. 2. A. CT scanning on admission, showing multilobular perihilar infiltrates in the right lung with enhancement after intravenous administration of contrast medium and a smaller nodule on the left lung. B. CT scanning performed 4 months after the beginning of treatment with oral corticosteroids, revealing multiple central bronchiectasis in the right lung. C. Comparison of CT scanning before (A) and 4 months after (B) the commencement of treatment with oral corticosteroids.

(4) precipitating antibodies to *A.Fumigatus*, (5) immediate cutaneous reaction to *A. fumigatus*, (6) peripheral blood eosinophilia, (7) chest roentgenographic infiltrates and (8) central bronchiectasis. ABPA progresses in five stages and treatment differs depending on the stage [1,2]. A patient does not necessarily progress from one stage to the other sequentially. Therefore, the natural history of ABPA is not well characterized [1]. An early diagnosis and initiation of treatment are essential to prevent irreversible damage. The cornerstone of ABPA treatment is systemic corticosteroids [1,2,4,5]. Antifungal agents have also been used, especially at the end-stage disease and/or after the first episode of exacerbation, but their role in the treatment of ABPA has not been clearly established [1,2,4,5].

Conflict of interest

There are none.

Acknowledgement

None.

References

[1] R. Agarwal, Allergic bronchopulmonary aspergillosis, Chest 135 (2008) 805–826.
[2] I. Tillie-Leblond, A.B. Tonnel, Allergic bronchopulmonary aspergillosis, Allergy 60 (2005) 1004–1013.
[3] G.P. Latge, *Aspegillus fumigatus* and aspergillosis, Clin. Microb. Rev. 12 (2) (1999) 310–350.
[4] A.O. Soubani, P.H. Chandrasekar, The clinical spectrum of pulmonary aspergillosis, Chest 121 (2002) 1988–1999.
[5] B.H. Segal, Aspergillosis, N. Engl. J. Med. 360 (2009) 1870–1884.