Available online at www.sciencedirect.com

ScienceDirect

journal homepage: www.elsevier.com/locate/ihj

Case Report

Coronary involvement in Churg-Strauss syndrome

Gregory Dendramis *, *Claudia Paleologo, Davide Piraino, Salvatore Arrotti, Pasquale Assennato*

Division of Cardiology II, Section of Intensive Coronary Care Unit, Department of Internal Medicine and Cardiovascular Diseases, University Hospital "Paolo Giaccone", Palermo, Italy

ARTICLE INFO

Article history:
Received 2 May 2014
Accepted 30 July 2015
Available online 18 October 2015

Keywords:
Churg-Strauss syndrome
Acute coronary syndrome
Coronary ectasia
Matrix metalloproteinases
Diagnostic approach

ABSTRACT

Systemic autoimmune diseases are themselves a relevant and independent risk factor for atherosclerosis and coronary ectasia. We describe a case of a 58-year-old Caucasian man who was admitted to our department for unstable angina. History of asthma, paranasal sinus abnormality, and peripheral eosinophilia given a high suspicion of Churg-Strauss syndrome (CSS). Diagnosis was performed with 5 of the 6 American College of Rheumatology criteria.

The knowledge that CSS is often associated with significant coronary artery involvement and the persistence of chest pain led us to performing immediately a coronary angiography.

Coronary angiography showed diffuse ectasic lesions, chronic occlusion of left anterior descending artery with homocoronary collateral circulation from left circumflex artery and subocclusive stenosis in the proximal tract of posterior descending artery.

The early recognition of CSS, an aggressive invasive diagnostic approach, and an early appropriate therapy are important to prevent the progressive and permanent cardiac damage in these patients.

In the setting of a multidisciplinary approach, careful cardiac assessment is an essential step in CSS, even in mildly symptomatic patients.

© 2015 Cardiological Society of India. Published by Elsevier B.V. All rights reserved.

1. Introduction

Churg-Strauss syndrome (CSS) is a rare form of systemic vasculitis affecting small and medium-sized blood vessels associated with the presence of perinuclear antineutrophil cytoplasmatic antibodies (p-ANCA). CSS has an incidence of 0.11–2.66 cases per million per year and predominantly affects males between the third and sixth decade.

The most typical manifestations are allergic rhinitis, asthma, and peripheral blood eosinophilia. According to the American College of Rheumatology (ACR), there are 6 criteria for the diagnosis of CSS: asthma, eosinophilia, pulmonary infiltrates, acute or chronic sinusitis, histological evidence of vasculitis with extravascular eosinophils, and mononeuropathy or polyneuropathy. The presence of 4 or more criteria yields a sensitivity of 85% and a specificity of 99.7%.[1]

The disease can be divided into 3 phases. The initial phase starts with allergic rhinitis, asthma, and nasal polyposis; the second is marked by peripheral and tissue eosinophilia with pulmonary infiltrates; the third is characterized by systemic vasculitis.

* *Corresponding author.*
E-mail address: gregorydendramis@libero.it (G. Dendramis).
http://dx.doi.org/10.1016/j.ihj.2015.07.049
0019-4832/© 2015 Cardiological Society of India. Published by Elsevier B.V. All rights reserved.

Involvement of the heart has been described in the third phase of CSS as vasculitic lesions in epicardial coronary vessels and in myocardium. It is a major cause of morbidity and mortality in these patients. CSS patients with cardiac involvement can present ECG abnormalities (nonspecific ST-segment and T-wave changes, conduction disturbances, and typical pattern of pericarditis or acute coronary syndromes), but in the absence of major abnormalities, cardiac involvement could be detected in nearly 40% of patients.[2]

In CSS, coronary angiography can show various degrees of stenosis, vasospasm, and coronary ectasia. Especially, coronary ectasia is often reported in literature in systemic inflammatory vasculitis, and it is associated with ectasia of numerous other arterial districts such as cerebral and renal. A wide variety of factors may influence the genesis of coronary ectasia, particularly the overexpression of matrix metalloproteinases has been associated with an excessive expansive arterial remodeling.

In these patients, coronary ectasia may have a variable clinical presentation, often represents a coronary angiography finding detected occasionally or following the occurrence of an atypical chest pain, stable angina, or even of an acute coronary syndrome.[3]

The involvement of cardiovascular system is responsible for approximately 50% of all mortality in these patients and early recognition of CSS is important to prevent permanent organ damage, particularly coronary artery diseases.[4]

2. Case report

We present a case of a 58-year-old Caucasian man with hypertension and previous ischemic stroke, admitted to our department for typical acute chest pain started while he was walking, with spontaneous regression and associated with paresthesia in both upper limbs.

As regards past medical history, from a young age, he was suffering from bronchial asthma, and he was subjected to nasal polypectomy at age twenty-five.

After the ischemic stroke had at the age of forty-eight and labeled as cryptogenic, never have been found evidences of vasculitis anywhere else and after he had never been subjected to further investigation.

On examination, blood pressure was 140/80 mmHg and heart rate was 76 bpm. The ECG showed a sinus rhythm with first degree atrioventricular block, left anterior fascicular block, Q waves in DIII and aVF; T negative waves in V5, V6 (Fig. 1). Troponin I was normal (<0.012 ng/ml) and blood sample showed leukocytosis with 15% of eosinophil (2.010/μL).

Transthoracic echocardiogram showed normal left ventricular systolic function with ejection fraction of 55%, thickened ventricular wall, low mitral regurgitation, and altered relaxation mitral inflow pattern.

History of asthma with paranasal sinus abnormality associated with paresthesia in both upper limbs (probably due to polyneuropathy) and peripheral eosinophilia gave a high suspicion of CSS.

For this reason, we performed a thoracic high-resolution computed tomography (HRCT), which revealed a bilateral ground-glass pattern compatible with inflammatory lesions.

Perinuclear antineutrophil cytoplasmic antibodies (p-ANCA) were also positive (279 AU/mL).

Diagnosis of CSS was performed with 5 of the 6 ACR criteria: asthma, paranasal sinusitis, eosinophilia, paresthesia, and pulmonary infiltrates.

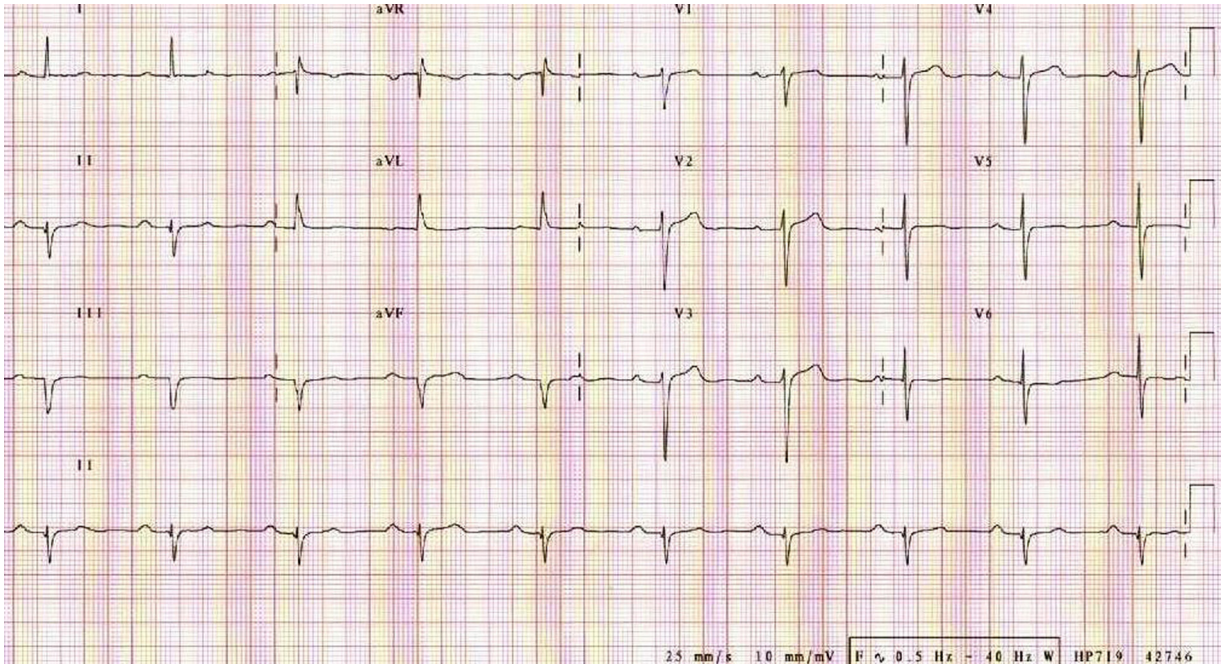

Fig. 1 – ECG at the admission.

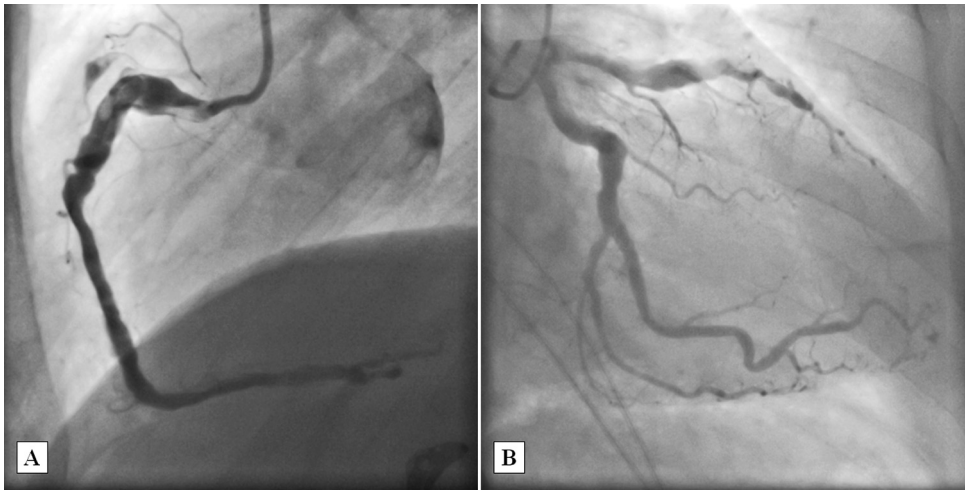

Fig. 2 – Coronary angiography: ectasic lesions of right coronary artery with subocclusive stenosis in the proximal tract of posterior descending artery (panel A) and chronic occlusion of middle-tract of left anterior descending artery with homocoronary collateral circulation from left circumflex artery (panel B).

Coronary angiography with right femoral artery access was performed and showed diffuse ectasic lesions; chronic occlusion of middle-tract of left anterior descending artery with homocoronary collateral circulation from left circumflex artery, ectasic lesions of right coronary artery with subocclusive stenosis (90%) in the proximal tract of posterior descending artery which required a PCI (percutaneous coronary intervention) with bare metal stent (Fig. 2, panels A and B).

On the basis of the presence of coronary ectasia, matrix metalloproteinases plasma concentrations (MMP-2 and MMP-9) and their tissue inhibitors (TIMP-1 and TIMP-2) were also assessed.

An increasing of matrix metalloproteinases values and a reduction of their tissue inhibitors were shown as reported in literature in systemic inflammatory vasculitis.

The patient was also treated with steroid therapy, and his eosinophil count dropped down to normal level with improvement of pulmonary involvement at three months HRCT control.

3. Conclusions

Systemic autoimmune diseases are themselves a relevant and independent risk factor for atherosclerosis and coronary ectasia.[2,3] As reported in our case report, CSS may present from the beginning with clinical findings of an acute coronary syndrome (in this patient as unstable angina).

Diagnosis of CSS, the knowledge that this disease is often associated with significant coronary involvement (high pretest probability of coronary artery disease) and the persistence of chest pain led us to performing immediately a coronary angiography.

This case underlines that the early recognition of CSS, an aggressive invasive diagnostic approach and an early appropriate therapy are important to prevent the progressive and permanent cardiac damage in these patients.

In our opinion, in the setting of a multidisciplinary approach, careful cardiac assessment is an essential step in CSS, even in mildly symptomatic patients.

Conflicts of interest

The authors have none to declare.

REFERENCES

1. Masi AT, Hunder GG, Lie JT, et al. The American College of Rheumatology 1990 criteria for the classification of Churg-Strauss syndrome (allergic granulomatosis and angiitis). *Arthritis Rheum*. 1990;33:1094–1100.
2. Dennert RM, van Paassen P, Schalla S, et al. Cardiac involvement in Churg-Strauss syndrome. *Arthritis Rheum*. 2010;62:627–634.
3. Dendramis G, Paleologo C, Lo Presti A, et al. Coronary artery ectasia: etiopathogenesis, diagnosis and treatment. *G Ital Cardiol (Rome)*. 2014;15:161–169.
4. Lanham JG, Elkon KB, Pusey CD, et al. Systemic vasculitis with asthma and eosinophilia: a clinical approach to the Churg-Strauss syndrome. *Medicine*. 1984;63:65.