International Immunopharmacology 80 (2020) 106191

Contents lists available at ScienceDirect

International Immunopharmacology

journal homepage: www.elsevier.com/locate/intimp

Topical ozone therapy restores microbiome diversity in atopic dermatitis

Jinrong Zeng[a,1], Jianhua Dou[a,1], Lihua Gao[a], Yaping Xiang[a], Jinhua Huang[a], Shu Ding[a], Jing Chen[a], Qinghai Zeng[a], Zhen Luo[b], Wenbin Tan[c], Jianyun Lu[a,*]

[a] Department of Dermatology, the Third Xiangya Hospital, Central South University, Changsha, Hunan 410013, China
[b] Department of Laboratory, the Third Xiangya Hospital, Central South University, Changsha, Hunan 410013, China
[c] Department of Cell Biology and Anatomy, University of South Carolina School of Medicine, Columbia, SC 29209, USA

ARTICLE INFO

Keywords:
Atopic dermatitis
Ozone
Microbiome
Therapeutic intervention

ABSTRACT

Background: *Staphylococcus aureus (S. aureus)* accounts for 90% of the microbiome in atopic dermatitis (AD) lesions and plays a role in disease flare-ups and worsens disease outcome. Ozone treatment can improve AD conditions by its bactericidal effect on *S. aureus*.
Objective: To study the effects of topical ozone therapy on microbiome diversity in AD lesions and explore potential probiotic pathogens correlated with AD progression.
Methods: Patients with moderate to severe bilateral skin lesions in AD were recruited. Randomized split sides were performed. One side was treated with ozone hydrotherapy followed by ozonated oil; while the contralateral side with tap water and basal oil. Patients' SCORAD scores and modified EASI were recorded before and after treatments. The microbiological compositions in targeting sites were determined using 16S rDNA sequencing.
Results: After three-day ozone therapy, patients showed a significant decrease in SCORAD scores and inflammatory cell infiltration in AD lesions. The micro-ecological diversity was higher in the non-lesional as compared with lesional areas ($p < 0.05$), which was also negatively correlated with the severity of AD ($r = -0.499$, $p < 0.05$). The proportion of *S. aureus* in AD lesions was positively correlated with the severity of AD ($r = 0.564$, $p = 0.010$), which was decreased after ozone treatment ($p = 0.07$). Ozone therapy showed an increase in microbiological diversity with a significant increase in the proportion of *Acinetobacter* ($p < 0.05$).
Conclusion: Topical ozone therapy is highly effective for treatment for AD. It can change the proportional ratio of *Staphylococcus* and *Acinetobacter*, thereby restoring the microbiological diversity in AD lesions.

1. Introduction

Atopic dermatitis (AD) is a chronic and relapsing inflammatory skin disease involving intense skin pruritus, pachylosis and skin barrier damage. Consequently, it affects up to 20% of children and 10% of adults worldwide with various conditions such as sleeping disorders, anxiety, social withdrawal and depression [1,2]. *Staphylococcus aureus (S. aureus)* occupies up to 90% of the lesional skin microbiome in AD patients and contributes to the frequent flare-ups and disease worsening of AD [3,4]. Moreover, colonization of *S. aureus* may activate T helper type 2 (Th2) cells, the dominant immune phenotype in AD [5]. Accumulating evidence has shown that the abundance of *S. aureus* increases significantly in the acute phase of AD and is closely correlated with the severity of the disease; while other major skin bacteria groups are decreased including *Propionibacterium*, *Corynebacterium*, and *Malassezia* [6,7]. It has been shown that the diversity of skin microbiome correlates with disease severity for lesional and nonlesional skins in AD [8]. However, how dysbiosis impacts on the onset or development of AD remains incompletely understood. The recent emerging 16S rDNA sequencing technology allows us to investigate the composition and the skin microbiome in a high-throughput manner [9]. Ozone, a classic oxidant and sterilizer, has been widely applied in clinic, which involves in mechanisms of antimicrobial effect, antioxidant defenses, immunoregulation, epigenetic modification, biosynthesis, analgesics and vasodilation [10]. Ozonated water and oil have been widely used in treatment of inflammatory and infectious skin conditions because it can quickly relieve symptoms such as pruritus and edema thus mitigating disease severity [11,12]. In this study, we investigated the effect of microbiome diversity in AD lesions by a short-term topical ozone treatment and explored the potential probiotics and pathogens.

* Corresponding author at: the Third Xiangya Hospital, Central South University, No. 138 Tongzipo Rd, Changsha, Hunan 410013, China.
E-mail address: xiaoyun3@csu.edu.cn (J. Lu).
[1] These authors contributed equally to this work.

https://doi.org/10.1016/j.intimp.2020.106191
Received 12 November 2019; Received in revised form 10 December 2019; Accepted 3 January 2020
1567-5769/ © 2020 The Authors. Published by Elsevier B.V. This is an open access article under the CC BY-NC-ND license (http://creativecommons.org/licenses/BY-NC-ND/4.0/).

2. Methods

2.1. Subjects

This study was approved by the IRB committee at the Third Xiangya Hospital, Central South University, China. There was no compensation for study participation. AD patients visited the outpatient clinic of the Department of Dermatology, the Third Xiangya Hospital, from June 2016 to June 2018 were enrolled into in the study after being consented and signing a written consent form. Inclusion criteria include: age of 6–28 years old with a diagnosis of AD according to William criteria [13]; moderate to severe AD determined by the Severity Scoring of Atopic Dermatitis (SCORAD) evaluation; and bilateral skin lesions with a size larger than 4*4 cm^2 on both sides of their elbow or axillary fossa with normal skin area adjacent. Exclusion criteria include: allergic to ozonated water or oil; serious infections in skin or other disruptive skin diseases; pregnancy, breastfeeding or with severe systemic diseases; and corticosteroid, immune inhibitor or antibiotic therapy within the past 2 weeks.

2.2. Topical ozone therapy

The lesions, adjacent non-lesion, and external nares on bilateral antecubital creases, popliteal creases, or nasal cavity were paired as targeting sites during the treatment. One side of paired targeting sites was randomly chosen as the treatment group; while the other side was assigned as the control group. Lesions and non-lesions in the treatment groups were treated with ozonated water (3.0 ± 1.5 mg/L) shower (HZ-2601B, Hunan Health Care Technology, Changsha, China) for 15 min once per day, and followed by topical ozonated camellia oil (20160522, with an approximate peroxide value of 2,000 to 2,200 mmol-equiv/Kg, Hunan Health Care Technology, Changsha, China) twice per day. Cotton swabs dipped with ozonated water were rotated in nasal cavities for 10 times for each treatment per day. Lesions, non-lesions and nasal cavity of control groups received tap water shower and basal oil at the same frequency. The intervention lasted for 3 days. Clinical photographs, SCORAD, objective SCORAD, modified Eczema Area and Severity Index (EASI), Reflectance Confocal Microscopy (RCM) image and microbiome samplings were collected at the day before and after treatment.

2.3. Scoring methods

Disease severity was assessed by SCORAD [14]. Objective SCORAD was used to assess the whole body lesion severity. Target sites were assessed by modified EASI. Four characteristics of the targeting sites were assessed: erythema, edema, lichenification and excoriation. Each characteristic was scored as 0–3 points, according to its severity: none, mild, moderate and severe. The total was the sum of the four categories [15].

2.4. Microbiome sampling

Sterile cotton swabs soaked with sterilizing saline were taken from different sites of each AD patient. Skin samples were collected by rubbing the skin for 10 times perpendicularly; and nasal samples were taken by rotating the swab 10 times in the anterior nares. All lesional samples were taken from visible eczema in the antecubital and popliteal creases. All non-lesional samples were taken from the adjacent normal skins.

2.5. DNA extraction and sequencing

DNA from swabs was isolated by BGI genomics kit (Beijing Genomics Institute, Shenzhen, China) and stored at −80 °C for future use. The V4 region of the 16S rDNA gene was amplified by the following primers to generate an amplicon library for each sample, 515F (5′-GTGCCAGCMGCCGCGGTAA-3′) and 806R (5′- GGACTACHVGGGTWTCTAAT-3′) [16]. PCR-amplification, cloning and sequencing were performed as previously described [17]. DNA library fragments in proper sizes were selected using Agencourt AMPure XP (Beckman coulter, CA, USA) and subjected to a qualification using a Bioanalyzer-2100 (Agilent Technologies, CA, USA) and pair-end sequencing using a Hiseq-2500 (Illumine Inc., CA, USA) [18].

Table 1
Clinical characteristics of the enrolled subjects.

Characteristics	AD patients
Total subjects analyzed	12
Age, mean (range)	17.08 ± 6.72 yr (6–28)
Male: female	4:8
Allergic rhinitis or asthma	8
Family history of allergic disease	9
S. aureus positive in lesions	7
Popliteal creases: Antecubital creases	6:6
Eosinophils count[a]	0.50 ± 0.22
Eosinophils (%)[b]	6.40 ± 2.25
IgE[c]	1338.4 ± 1723.2

Reference interval: a, 0.02–0.52*10^9/L; b, 0.4–8.0%; c, 0–165 UI/ml.

2.6. Bacterial cultivation

All collected samples were put into sterile tubes and quickly transported into the clinical laboratory for bacterial culture. The collected specimens were removed from swabs in a sterile ultra-clean workbench and dipped into a sterilized NaCl solution (0.9%) 3 times. The samples were centrifuged with 12, 000 rpm/min for 10 min to retain precipitation, followed by inoculating in Blood agar plate (Sigma-Aldrich, MO, USA). The plates were incubated at 37 °C for 48 h.

2.7. Mass spectrometric analysis

A single colony was picked from the plate to perform a mass spectrometric analysis (Bruker, NASDAQ, USA) to determine the bacterial species according to manufacturer's instructions.

2.8. Operational taxonomic unit (OTU) picking

High quality paired-end reads were categorized into groups by tags [19], which were clustered into OTU with a 97% similarity by using USEARCH (v7.0.1090). OTU sequences were annotated using Ribosomal Database Project (RDP) Classifier (v2.2) with a cutoff of confidence value as 0.60 [20,21]. Finally, alpha diversity, beta diversity and the different species screening were used to distinguish the classification based on OTU and taxonomic ranks.

The top 25 abundance of OTUs or tags above 10,000 were analyzed at the family and genus levels to avoid contaminated species that were far less abundant. Compositional variations in abundance were used to describe patterns and trends. The indices of alpha diversity were evaluated by Mothur (v 1.31.2). Shannon diversity analysis was used to evaluate the richness (number of different species) and evenness (how evenly they are distributed) of microbiome as the main metrics in this study [22].

2.9. Statistical analysis

Statistical analysis was performed by PAWS Statistics 18.0 (IBM, NY, USA) and graphs were produced using Graphpad Prism7 (GraphPad Software, CA, USA). Differences in SCORAD, OTU amount, and Shannon diversity between groups were tested with a paired *t* test. Library generation rates of different target sites were tested with χ^2 test. Correlation and partial correlation analyses were used to analyze

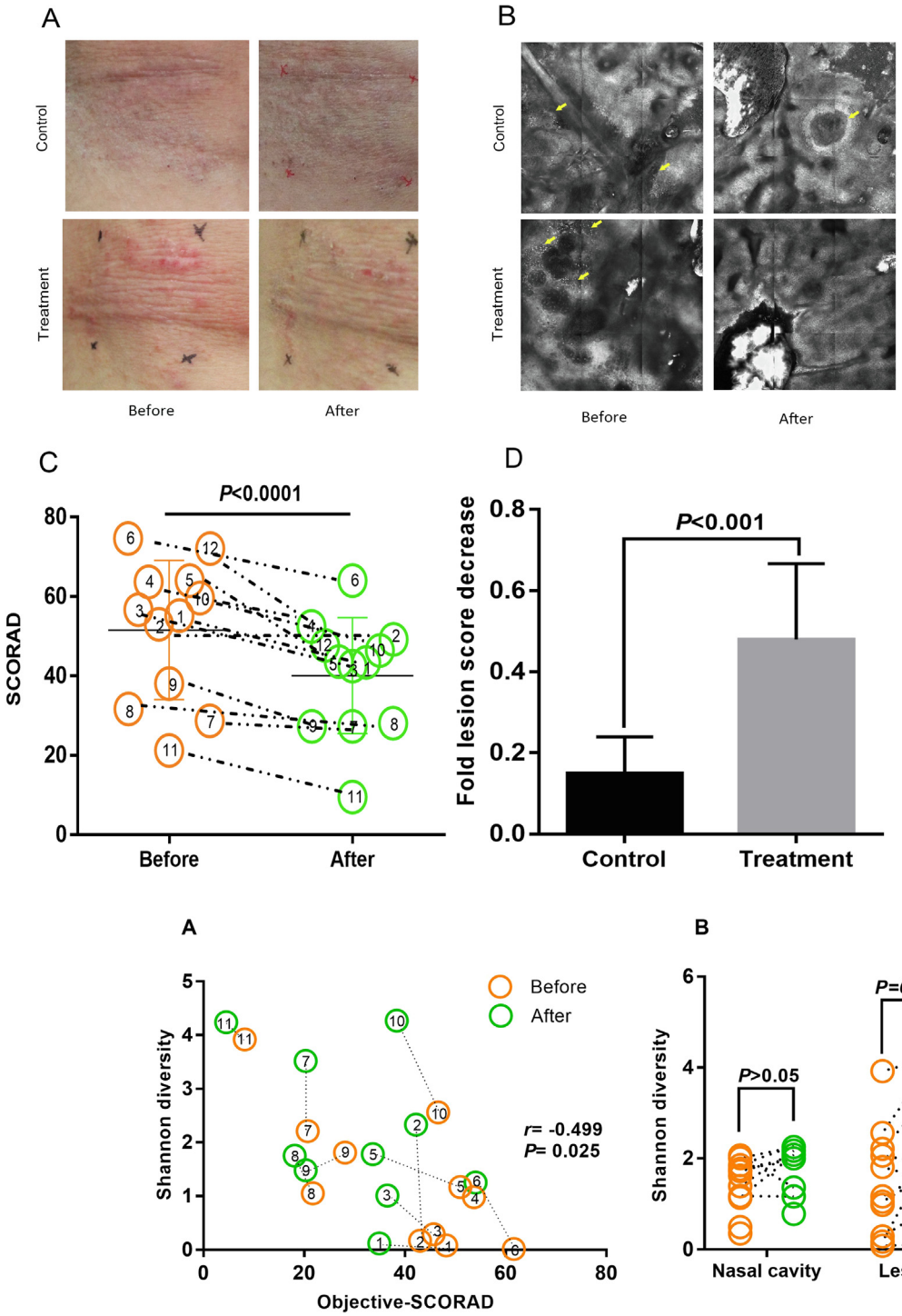

Fig. 1. Ozone topical therapy on patients with AD. (A) Clinical efficacies on skin lesions in AD after ozone intervention in the control and treatment groups. The clinical images were taken from bilateral popliteal creases from the same subject. (B) RCM images of the lesions in (A). A large quantity of inflammatory cells (yellow arrows) were observed to be infiltrating into epidermis before treatment. After intervention, less inflammatory cells were observed in treatment groups as compared with controls. (C) SCORAD statistical graph of all AD patients in pre- and post-treatments. The digits in the symbol represented the patient's assigned number. The data set from the same subject before and after treatment was connected by a dashed line. (D) Decreased rate of lesional index in different groups after intervention. *P* values were calculated by two-tailed paired *t*-test. (For interpretation of the references to colour in this figure legend, the reader is referred to the web version of this article.)

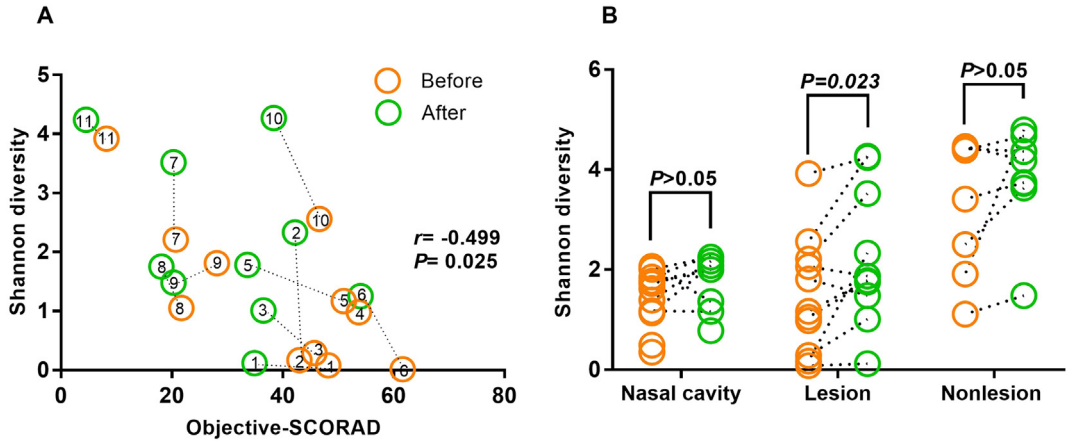

Fig. 2. Microbiome diversity in AD. (A) Relationship between objective SCORAD and Shannon diversity in lesions of AD patients. (B) Shannon diversity in different groups. The data set from the same subject before and after treatment was connected by a dashed line. *P* values were calculated by two-tailed paired *t*-test between two indicated groups.

the correlation factors. All data are represented as mean ± SEM unless otherwise indicated. Two-tailed *P* value less than 0.05 was considered to be statistically significant.

3. Results

A total of 12 patients with AD (4 male and 8 female from 6 to 28 years old) were enrolled in the study (Table 1). Half of AD lesional and non-lesional skin samples were collected from antecubital creases; half were from popliteal creases. Skin bacterial cultivation showed that *S. aureus* was found in 7 out of 12 lesions from patients (SF.1A). *Staphylococcus epidermis (S. epidermis)* and *Staphylococcus capitis (S. capitis)* were also found (SF.1B&C). Allergic rhinitis or asthma history were found in 8 AD patients.

3.1. Efficacy of ozone therapy on patients with AD

Before intervention, the lesions with manifestations of

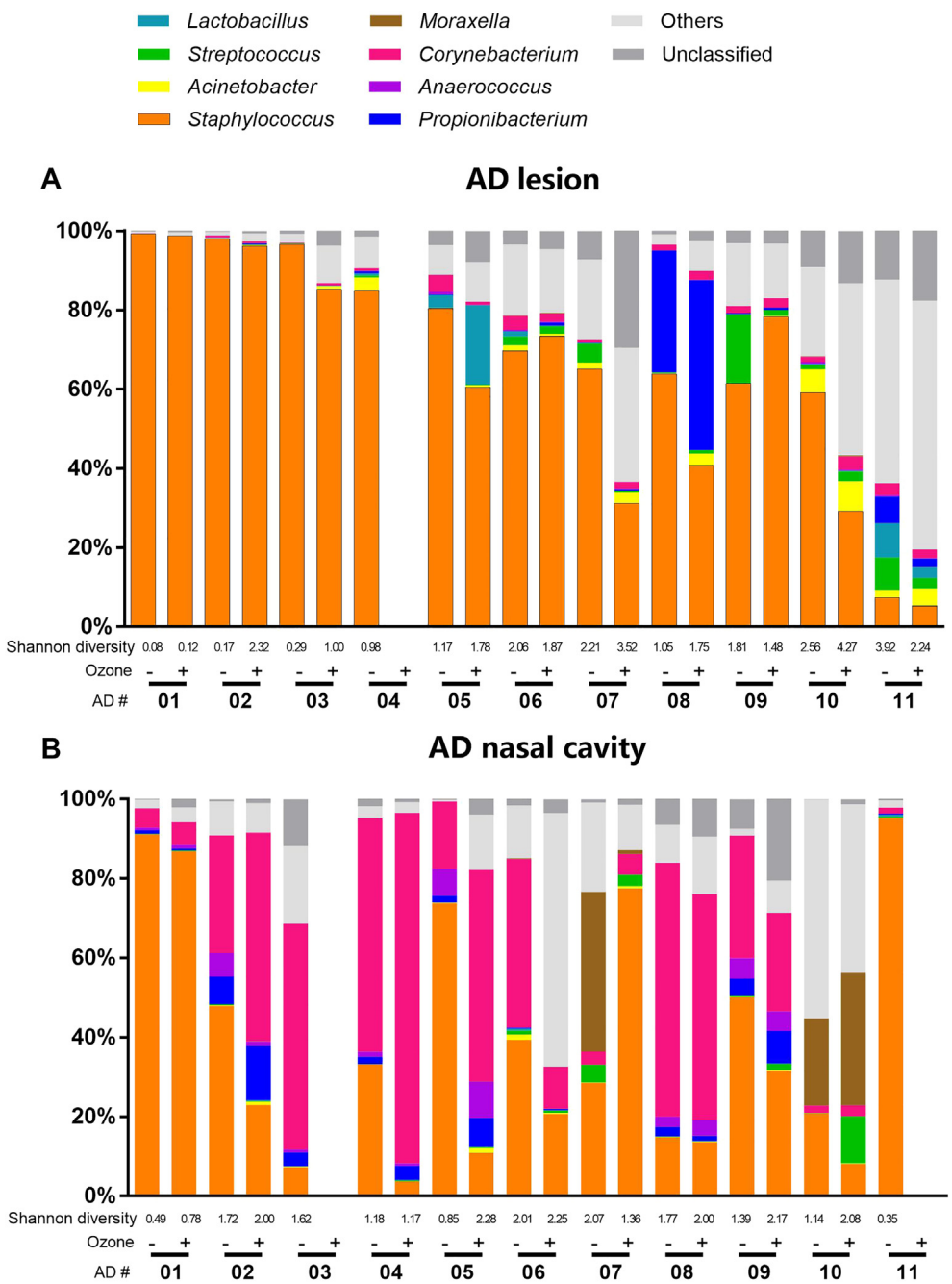

Fig. 3. Proportional distribution of bacterial species in skin and nasal cavity from skin lesions in AD before and after treatment. (A) Rebalance of microbiome diversity among main abundant bacterial species from skin lesions in AD before and after treatment. (B) Relative abundance of different microbiome clusters in the nasal cavity before and after treatment. The data of No. AD 12, No.04 in lesion and No. 03 in nasal cavity were not obtained successfully.

maculopapule, erosion, and exudation were mainly distributed in the flexion of limbs. Dry skin is a common phenomenon observed in these patients. After treatment, an attenuation of inflammatory papule and edema was observed (Fig. 1A). Under RCM, less infiltrated inflammatory cells were observed in epidermis after treatment as compared with before treatment (Fig. 1B). In order to assess the effect of ozone therapy on AD severity, we estimated SCORAD and modified EASI. The SCORAD dropped by 22.15% (95% CI, $P = 0.0001$) after three-day treatment (Fig. 1C). The modified baseline EASI in lesions in treatment and control groups were 5.17 ± 2.23 and 5.13 ± 2.14, respectively (95% CI, $P > 0.05$). After intervention, the index was decreased by $48.0 \pm 18.6\%$ and $15.0 \pm 8.9\%$, respectively. Therefore, ozone therapy could significantly mitigate the AD lesions (95% CI, $P < 0.001$) (Fig. 1D).

3.2. Lesional microbiome diversity and disease severity

The association between Shannon diversity and objective SCORAD was used to investigate a possible relationship between microbial diversity and disease severity. Considering both antecubital and popliteal creases are susceptible sites of AD and have similar results, we averaged these sites per subject for the analyses to avoid repetitive calculations. We found a negative correlation between SCORAD and Shannon diversity of lesions, adjusting for disease state ($r = -0.499$, $P = 0.025$) (Fig. 2A). This data demonstrated that the susceptible sites of severe AD had lower skin bacterial diversity.

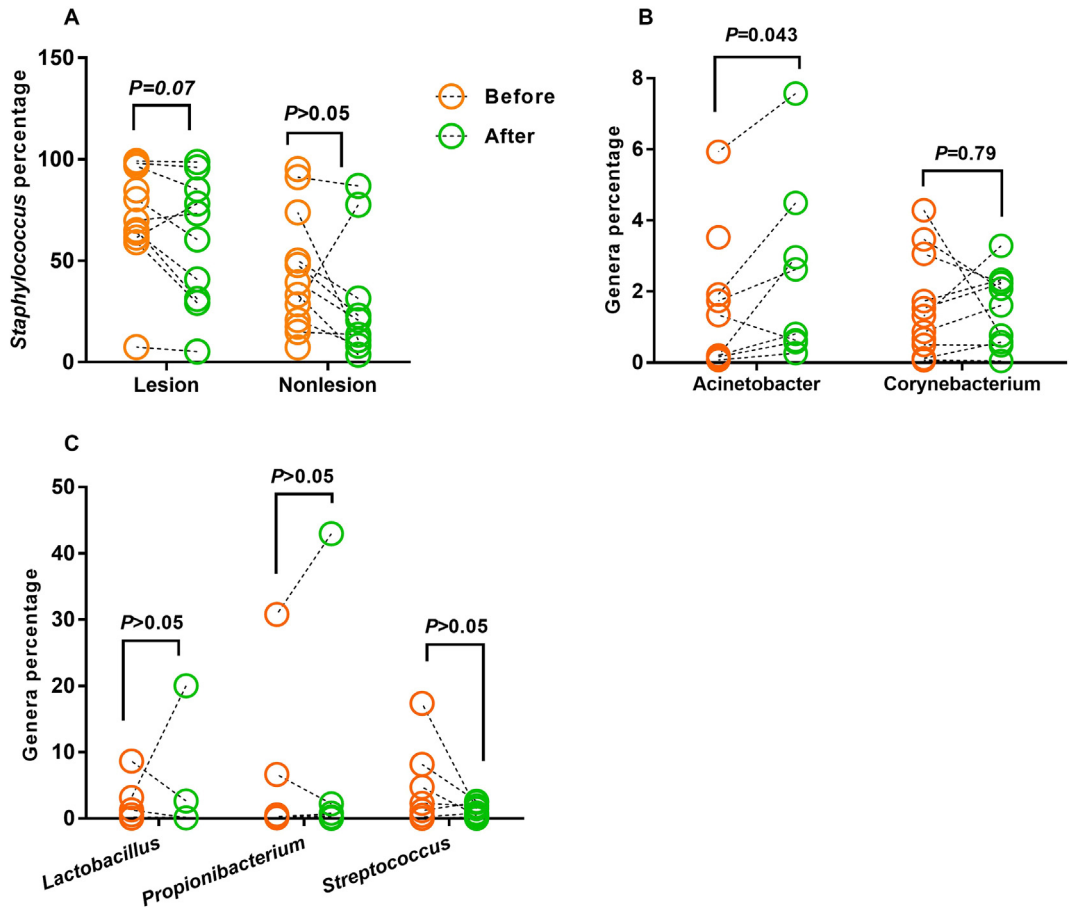

Fig. 4. Changes of major microbial species before and after treatment in AD lesions or non-lesional skins. The compositional percentage of *Staphylococcus* showed an insignificant decrease after treatment in lesions; while there was no significant change in non-lesional skins before and after treatment. (B) *Acinetobacter* and *Corynebacterium* showed a significant or insignificant increase in their proportional percentages in AD lesions after treatment, respectively. (C) *Lactobacillus* and *Propionibacterium* showed insignificant increases in their proportional percentages after treatment in AD lesions. The data set from the same subject before and after treatment was connected by a dashed line.

3.3. The effect of ozone therapy on AD skin microecology

We found that the non-lesion groups had the greatest bacterial diversity (95% CI, $P < 0.05$) as compared with lesional and nasal sites (Fig. 2B). We then performed a further investigation on the skin microbiological effect by ozone therapy on lesions, non-lesions and the nasal cavity of AD. We found that ozone treatment significantly increased the Shannon index in lesional targeting sites but not nasal cavity and non-lesional control sites (Fig. 2B). Therefore, ozone therapy could restore the decreased microbiome diversity in AD lesions.

3.4. Ozone topical therapy on changes of compositions of skin microbiome

We screened the most abundant 25 OTUs in each lesional sample. A total of 18 genera in four major phyla, e.g. *Actinobacteria*, *Bacteroidetes*, *Firmicutes,* and *Proteobacteria,* were found in AD lesions. The compositional changes in genus level were shown in Fig. 3A. At baseline in AD lesions, *Staphylococcus* dominated in the lesional microbiology, ranging from 59 to 99 percent in accordance with cultivated microbes from skins. *Staphylococcus* percentage decreased after treatment ($P = 0.07$, Fig. 4A). The proportion of *Staphylococcus* in AD lesions were partially correlated with the disease severity ($r = 0.564$, $P = 0.010$, Fig. 5A). Further, the abundance of *Acinetobacter* in AD lesions dropped as well after treatment ($P = 0.039$, Fig. 4B), but its correlation with disease severity was not significant ($r = -0.096$, $P = 0.695$) (Fig. 5B). Interestingly, *Corynebacterium* did not show a correlation with lesional severity ($r = 0.071$, $P = 0.766$) (Fig. 5C) and its proportion was not decreased significantly in lesions after treatment (Fig. 4B). We also observed a slight decrease in *Lactobacillus*, *Streptococcus* and *Propionibacterium* (Fig. 4C). *Staphylococcus* was found colonized with a large quantity in nasal cavity of AD patients, along with *Corynebacterium, Moraxella* and *Propionibacterium* as the main genera (Fig. 3B). The proportion of *Staphylococcus* showed a slight decrease but its correlation with severity was not significant ($P = 0.529$, Fig. 5D). To be noted, its abundance in subject AD07 even increased during disease remission. We also observed bacterial diversity in non-lesions of those subjects, which was significantly higher than lesion sites ($P < 0.05$, Fig. 2B). The above-mentioned 18 genera composed only 55.3 ± 30.76% in non-lesions, but 85.6 ± 15.8% in lesions. *Staphylococcus* was still the main composition in non-lesions by 31.55 ± 30.76%. Its abundance decreased, but insignificantly, after ozone therapy (Fig. 4A). It is to be noted that *Staphylococcus* in subject AD06 and AD09 increased in both lesions and non-lesions after treatment.

4. Discussion

An imbalance of the skin microbiome has been shown to impact inflammatory and immune responses in AD, thus contributing to its severity [23,24]. Colonization of *S. aureus* in skin is associated with exacerbation and relapse of AD [25]. *S. aureus* may expropriate *P. acnes*, a critical skin microbiome member, to spread its invasion by producing secretory virulence factors and cause endogenous epidermal proteolysis and skin barrier damage [26]. In this study, we observed a significant increase in proportion of *Staphylococcus* in the microbiome composition

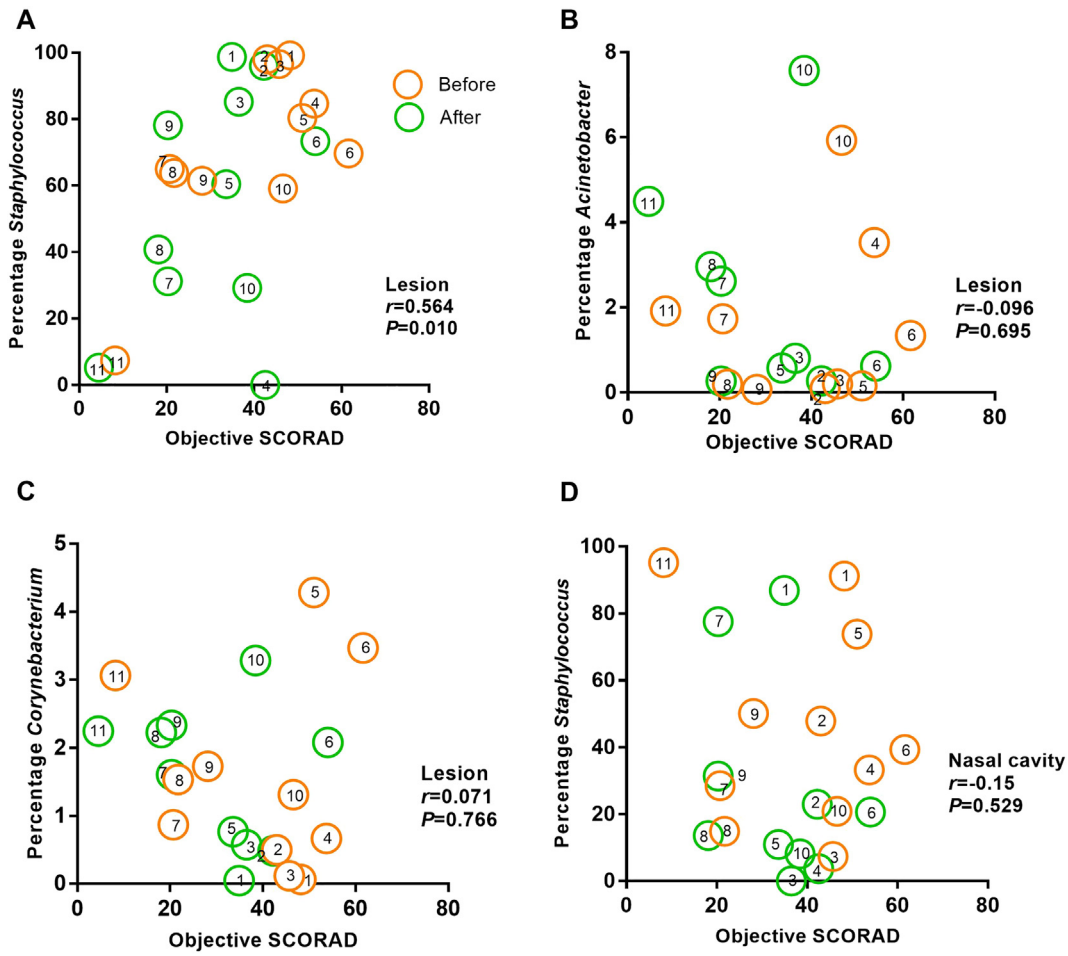

Fig. 5. Correlations between percentages of major bacterial genera and objective SCORAD. (A) The proportional percentage of *Staphylococcus* shows a positive correlation with disease severity of AD. (B) Both *Acinetobacter* and (C) *Corynebacterium* do not show a significant correlation between their abundances and AD severity. (D) Correlation between *Staphylococcus* abundance and disease severity is not significant in nasal cavity. The digits in the symbol represented the patient's assigned number.

in moderate to severe AD lesions, which can be reversed by a short-term topical ozone therapy. Our results suggest that ozone-therapy not only exhibits bactericidal effects but also involves in restoration of skin microbiological diversity in AD lesions. Our previous study found that the load of *S. aureus* decreased by 75.55 ± 21.81% after 3 days of topical ozone treatment for AD [27]. This study further analyzed the changes of micro-ecological diversity in nasal, lesion and non-lesion areas in pre- and post-ozone intervention. As a whole, we observed that the micro-ecological diversity in treatment groups was increased as compared to the baselines. Consistently, the bacterial diversity in non-lesion areas was also higher than lesion areas and the nasal cavity.

Acinetobacter is a group of conditional pathogenic bacteria. In a previous report, *A. ropheus* was confirmed to be able to induce immune tolerance in dendritic cells and inhibit T helper type 1 (Th1) cells' polarization, thus reducing allergic reaction in mice [28]. Another recent study showed that *A. ropheus* could stimulate the production of interleukin 10 from monocytes and keratinocytes to modulate the balance of Th1/Th2 cell differentiation and exert an anti-inflammatory effect [29]. In this study, we demonstrated that the proportion of *Acinetobacter* species was elevated after ozone treatment, suggesting its negative correlation with the disease severity. These data are consistent with those above-mentioned reports. The upregulation of *Acinetobacter* possibly is likely the secondary consequence of the removal of *Staphylococcus* by ozone.

Ozone was originally applied in medicine acting as a strong oxidant to kill microorganisms. Until now, this active molecule has been widely used to treat more than 50 pathological conditions including skin diseases [30,31]. The mechanisms of ozone's action may refer to direct antimicrobial effect, immunoregulation, antioxidant defenses, epigenetic modification, analgesics, biosynthesis, and vasodilation [10]. In our research, we showed the efficacy of a short-term ozone topical therapy for moderate to severe AD, which may partially due to restoration of skin microbiota diversity. Particularly, ozone can act as an antibacterial agent to reduce *Staphylococcus,* subsequently rebalance skin micro-ecology by increasing *Acinetobacter* to improve skin conditions in lesions. There restoration of skin micro-ecological diversity induced by ozone treatment may help repair skin barrier function and improve the immune system to relieve inflammatory reaction. Furthermore, ozone can serve as a sterilizing agent, thus reducing the risk of flora disturbance and bacteria drug-resistance in AD lesions. In this study, we found that nasal micro-ecology diversity of AD patients was poorer than that of skin surface and most patients had *Staphylococcus* colonization. There is no significant correlation between *Staphylococcus* and AD condition in the process of ozone intervention in nasal cavity. A series of follow-up experiments will be required to answer this question.

5. Limitation

The limitations of this study include: (1) insufficient sample size that is unable to reduce variances due to individual variables in skin microorganisms susceptible to environmental factors; and (2) limitations of 16SrDNA V4-tag sequencing that can result in an

underrepresentation of *Staphylococcus epidermidis* and *Propionibacterium* and an overrepresentation of *Staphylococcus aureus* [32]. Therefore, our results may not be able to accurately reflect the changes of *Staphylococcus epidermidis* and *Propionibacterium* in the skin before and after treatment. However, considering the fact that *Staphylococcus aureus* accounts for 90% of microbiome in AD lesions which is the main focus in this study and can be enriched by V4-tag sequence, the conclusions drawing from this study shall not be undermined. Nevertheless, using 16SrDNA V1-V3 tag sequencing will be necessary to further investigate the microbiome profiling in skin lesions in response to ozone treatment in our future studies.

6. Conclusion

In conclusion, we reported here that topical ozone treatment of AD can rapidly improve symptoms, including relief of itching and reduction of inflammation. A proportion of *Staphylococcus* is positively correlated to the AD severity. Ozone intervention can lower the abundance of *Staphylococcus* and augment the micro-ecological diversity of AD lesions by increasing *Acinetobacter* proportion, thus alleviating the disease.

Prior publication

None of the material in this manuscript has been published or is under consideration for publication elsewhere, including the Internet.

Funding statement

This work was supported by the New Xiangya Talent Projects, the Third Xiangya Hospital of Central South University (20170309 to JL) and the Science and Health Projects of Hunan Natural Science Foundation (2018JJ6094 to JL).

Declaration of Competing Interest

The authors declare that they have no known competing financial interests or personal relationships that could have appeared to influence the work reported in this paper.

Appendix A. Supplementary material

Supplementary data to this article can be found online at https://doi.org/10.1016/j.intimp.2020.106190.

References

[1] D. Garmhausen, T. Hagemann, T. Bieber, I. Dimitriou, R. Fimmers, T. Diepgen, N. Novak, Characterization of different courses of atopic dermatitis in adolescent and adult patients, Allergy 68 (4) (2013) 498–506.
[2] M. Boguniewicz, D.Y. Leung, Atopic dermatitis: a disease of altered skin barrier and immune dysregulation, Immunol. Rev. 242 (1) (2011) 233–246.
[3] J.E. Totté, V.D.F. Wt, M. Hennekam, B.A. Van, E.J. van Zuuren, S.G. Pasmans, Prevalence and odds of Staphylococcus aureus carriage in atopic dermatitis: a systematic review and meta-analysis, Br. J. Dermatol. 175 (4) (2016) 687–695.
[4] L. Hepburn, D.J. Hijnen, B.R. Sellman, T. Mustelin, M.A. Sleeman, R.D. May, I. Strickland, The complex biology and contribution of Staphylococcus aureus in atopic dermatitis, current and future therapies, Br. J. Dermatol. 177 (1) (2016).
[5] H. Liu, N.K. Archer, C.A. Dillen, Y. Wang, A.G. Ashbaugh, R.V. Ortines, T. Kao, S.K. Lee, S.S. Cai, R.J. Miller, Staphylococcus aureus epicutaneous exposure drives skin inflammation via IL-36-mediated T cell responses, Cell Host Microbe 22 (5) (2017) 653–666.
[6] H.H. Kong, J. Oh, C. Deming, S. Conlan, E.A. Grice, M.A. Beatson, E. Nomicos, E.C. Polley, H.D. Komarow, N.C.S. Program, Temporal shifts in the skin microbiome associated with disease flares and treatment in children with atopic dermatitis, Genome Res. 22 (5) (2012) 850–859.
[7] H.M.P. Consortium, Structure, function and diversity of the healthy human microbiome, Nature 486 (7402) (2012) 207–214.
[8] M.L. Clausen, T. Agner, B. Lilje, S.M. Edslev, T.B. Johannesen, P.S. Andersen, Association of disease severity with skin microbiome and filaggrin gene mutations in adult atopic dermatitis, JAMA Dermatol. 154 (3) (2018) 293–300.
[9] U. Edwards, T. Rogall, H. Blöcker, M. Emde, E.C. Böttger, Isolation and direct complete nucleotide determination of entire genes. Characterization of a gene coding for 16S ribosomal RNA, Nucleic Acids Res. 17 (19) (1989) 7843–7853.
[10] J. Zeng, J. Lu, Mechanisms of action involved in ozone-therapy in skin diseases, Int. Immunopharmacol. 56 (6) (2018) 235–241.
[11] N. Braidy, M. Izadi, A. Sureda, N. Jonaidi-Jafari, A. Banki, S.F. Nabavi, S.M. Nabavi, Therapeutic relevance of ozone therapy in degenerative diseases: focus on diabetes and spinal pain, J. Cell. Physiol. 233 (4) (2018) 2705.
[12] G.á. Borges, S.T. Elias, S.M.M. da Silva, P.O. Magalh?es, S.B. Macedo, A.P.D. Ribeiro, E.N.S. Guerra, In?vitro evaluation of wound healing and antimicrobial potential of ozone therapy, J. Craniomaxillofac. Surg. 45 (3) (2017) 364–370.
[13] F. Bath-Hextall, H. Williams, Eczema (atopic), Clin. Evidence 2006 (2005) 657–672.
[14] A.P. Oranje, E.J. Glazenburg, A. Wolkerstorfer, W.V.D.S. Fb, Practical issues on interpretation of scoring atopic dermatitis: the SCORAD index, objective SCORAD and the three-item severity score, Br. J. Dermatol. 157 (4) (2010) 645–648.
[15] J.M. Hanifin, M. Thurston, M. Omoto, R. Cherill, S.J. Tofte, M. Graeber, The eczema area and severity index (EASI): assessment of reliability in atopic dermatitis, EASI Evaluator Group, Ex. Dermatol. 10 (1) (2010) 11–18.
[16] H.C. Ring, J. Thorsen, D.M. Saunte, B. Lilje, L. Bay, P.T. Riis, N. Larsen, L.O. Andersen, H.V. Nielsen, I.M. Miller, The follicular skin microbiome in patients with hidradenitis suppurativa and healthy controls, Jama Dermatol. 153 (9) (2017) 897.
[17] E.A. Grice, H.H. Kong, C. Sean, C.B. Deming, D. Joie, A.C. Young, G.G. Bouffard, R.W. Blakesley, P.R. Murray, E.D. Green, Topographical and temporal diversity of the human skin microbiome, Science 324 (5931) (2009) 1190–1192.
[18] D.W. Fadrosh, B. Ma, P. Gajer, N. Sengamalay, S. Ott, R.M. Brotman, J. Ravel, An improved dual-indexing approach for multiplexed 16S rRNA gene sequencing on the Illumina MiSeq platform, Microbiome 2 (1) (2014) 6.
[19] T. Magoč, S.L. Salzberg, FLASH: fast length adjustment of short reads to improve genome assemblies, Bioinformatics 27 (21) (2011) 2957–2963.
[20] T.Z. Desantis, P. Hugenholtz, N. Larsen, M. Rojas, K. Keller, T. Huber, D. Dalevi, P. Hu, G.L. Andersen, Greengenes: Chimera-checked 16S rRNA gene database and workbenchcompatible in ARB, Appl. Environ. Microbiol. 72 (72) (2006) 5069–5072.
[21] W. Qiong, G.M. Garrity, J.M. Tiedje, J.R. Cole, Naive Bayesian classifier for rapid assignment of rRNA sequences into the new bacterial taxonomy, Appl. Environ. Microbiol. (2007).
[22] P.D. Schloss, S.L. Westcott, T. Ryabin, J.R. Hall, M. Hartmann, E.B. Hollister, R.A. Lesniewski, B.B. Oakley, D.H. Parks, C.J. Robinson, Introducing mothur: open-source, platform-independent, community-supported software for describing and comparing microbial communities, Appl. Environ. Microbiol. (2009).
[23] P.Y. Ong, D.Y. Leung, Bacterial and viral infections in atopic dermatitis: a comprehensive review, Clin. Rev. Allergy Immunol. 51 (3) (2016) 329–337.
[24] Y. Yamazaki, Y. Nakamura, G. Núñez, Role of the microbiota in skin immunity and atopic dermatitis, Allergology Int. Official J. Jpn. Soc. Allergology 66 (4) (2017) S1323893017301156.
[25] S.H. Jun, J.H. Lee, S.I. Kim, C.W. Choi, T.I. Park, H.R. Jung, J.W. Cho, S.H. Kim, J.C. Lee, Staphylococcus aureus-derived membrane vesicles exacerbate skin inflammation in atopic dermatitis, Clin. Exp. Allergy J. Br. Soc. Allergy Clin. Immunol. 47 (1) (2016).
[26] C.W. Lo, Y.K. Lai, Y.T. Liu, R.L. Gallo, C.M. Huang, Staphylococcus aureus hijacks a skin commensal to intensify its virulence: immunization targeting β-hemolysin and CAMP factor, J, Invest. Dermatol. 131 (2) (2011) 401–409.
[27] J. Lu, M. Li, J. Huang, L. Gao, Y. Pan, Z. Fu, J. Dou, J. Huang, Y. Xiang, [Effect of ozone on Staphylococcus aureus colonization in patients with atopic dermatitis], Zhong nan da xue xue bao, Yi xue ban = J. Central South Univ. Med. Sci. 43 (2) (2018) 157–162.
[28] S. Brand, R. Teich, T. Dicke, H. Harb, A.Ö. Yildirim, J. Tost, R. Schneider-Stock, R.A. Waterland, U.M. Bauer, M.E. Von, Epigenetic regulation in murine offspring as a novel mechanism for transmaternal asthma protection induced by microbes, J. Allergy Clin. Immunol. 128 (3) (2011) 618–625.e7.
[29] N. Fyhrquist, L. Ruokolainen, A. Suomalainen, S. Lehtimäki, V. Veckman, J. Vendelin, P. Karisola, M. Lehto, T. Savinko, H. Jarva, Acinetobacter species in the skin microbiota protect against allergic sensitization and inflammation, J. Allergy Clin. Immunol. 134 (6) (2014) 1301–1309.e11.
[30] I. Zanardi, E. Borrelli, G. Valacchi, V. Travagli, V. Bocci, Ozone: a multifaceted molecule with unexpected therapeutic activity, Curr. Med. Chem. 23 (4) (2016).
[31] V. Travagli, I. Zanardi, G. Valacchi, V. Bocci, Ozone and ozonated oils in skin diseases: a review, Mediators Inflamm. 2010 (1) (2010) 610418.
[32] J.S. Meisel, G.D. Hannigan, A.S. Tyldsley, A.J. SanMiguel, B.P. Hodkinson, Q. Zheng, E.A. Grice, Skin microbiome surveys are strongly influenced by experimental design, J. Invest. Dermatol. 136 (5) (2016) 947–956.