STUDY

Noninvasive Evaluation of Allergic and Irritant Contact Dermatitis by In Vivo Reflectance Confocal Microscopy

Susanne Astner, Salvador González, and Ernesto Gonzalez

Background: **The clinical differentiation of allergic contact dermatitis (ACD) and irritant contact dermatitis (ICD) is often difficult to accomplish. Reflectance-mode confocal microscopy (RCM) is an imaging technique that has previously been used to examine ACD and ICD noninvasively in vivo.**

Objective: **To determine characteristic features of ACD and ICD and their kinetic evolution over time. Ethnic susceptibility to contact irritants such as sodium lauryl sulfate and Ivory dishwashing liquid was evaluated noninvasively, and the sensitivity and specificity of RCM parameters were analyzed in a clinical context and in reference to patch testing.**

Methods: **Subjects were patch-tested with allergens, irritants, and controls. Clinical scoring and RCM evaluation were performed at various time points, assessing stratum corneum (SC) disruption, spongiosis, exocytosis, vesicle formation, and epidermal thickness.**

Results: **RCM features of both ACD and ICD include spongiosis, exocytosis, vesicle formation, and blood vessel dilatation. SC disruption, epidermal necrosis, and hyperproliferation are hallmarks of ICD whereas ACD more typically presents with vesicle formation. Patients with ICD showed a more rapid recovery than those with ACD. When tested with Ivory soap at selected concentrations, Caucasians, when compared to African Americans, showed significantly lower clinical thresholds for ICD and features that were more severe.**

Conclusions: **RCM may be a promising new technology for longitudinal noninvasive studies of contact dermatitis (CD). Using a diagnostic algorithm and those parameters with high sensitivity for CD, RCM may facilitate the differentiation of acute ACD and ICD. RCM can reliably visualize cutaneous changes at subclinical degrees of CD, which suggests a possible role for RCM as an adjunctive tool in CD diagnosis. The results of this pilot study also indicate ethnic differences in the response to contact irritants. However, further studies are needed to substantiate the relevance and clinical applicability of our findings.**

CONTACT DERMATITIS (CD) affects approximately 20% of the population in the United States and accounts for 90 to 95% of occupational skin disease.[1] Allergic CD (ACD) and irritant CD (ICD) have many shared characteristics, such that their clinical presentation, immunologic profile, and histopathologic features can be remarkably similar.[2–8] Because of their morphologic similarities, conventional histology has frequently failed to distinguish between the two types of acute CD reactions despite their different pathogeneses.[9–11]

The ''gold standard'' for diagnosing CD is patch testing, yet the validity, reproducibility, and accuracy of this technique has increasingly been questioned in recent years.[12–16] Although the interpretation of most positive test sites does not pose a problem to clinicians,[3,11–16] the assessment of questionable positive test results can be difficult, and their relevance remains to be determined.[3] Furthermore, the data regarding ethnic differences in susceptibility to ACD and ICD and in the manifestation of ACD and ICD have been contradictory.[17–24] Owing to increased endogenous pigmentation, the assessment of erythema in African American skin is difficult and can interfere with the identification of subclinical degrees of irritancy.

Efforts are therefore being made to establish noninvasive technologies that would allow for real-time in vivo evaluation of test sites. Recent studies have used real-time reflectance confocal microscopy (RCM) to image normal[25–27] and diseased human skin [28–30] noninvasively and in vivo. By correlating RCM histopathology with conven-

From the Wellman Center for Photomedicine, Department of Dermatology, Massachusetts General Hospital, Harvard Medical School, Boston, MA; the Contact Dermatitis Unit, Department of Dermatology, Massachusetts General Hospital, Boston, MA; and the Dermatology Service, Memorial Sloan-Kettering Cancer Center, New York, NY.

Funded by an R01 grant to SG (RO1 OH0429) from the National Institute of Occupational Safety and Health.

Address reprint requests to Ernesto Gonzalez, MD, Department of Dermatology, Contact Dermatitis Unit, Massachusetts General Hospital, Boston, MA 02114. E-mail: Gonzalez.ernesto@mgh.harvard.edu

DOI 10.2310/6620.2006.05052

tional histopathology, our group recently identified distinctive characteristics for ICD and ACD.[31–34]

Herein we report the results of serial in vivo human research studies using real-time RCM to investigate the dynamic pathophysiologic changes associated with ACD and ICD. Preliminary data on the sensitivity and specificity of this technique in the diagnosis of ACD as compared with patch testing will be reviewed in a clinical context, and ethnic differences in susceptibility to ICD will be discussed.

Materials and Methods

Participants

A total of 44 persons aged between 29 and 69 years (mean, 49 years) were recruited for this study. These subjects were assigned to the individual study goals as follows: 18 individuals with a history of contact allergy were enrolled, to evaluate the kinetics of ACD and ICD over time (group A); 16 individuals with a history of contact allergy were studied to analyze the sensitivity and specificity of RCM in the diagnosis of patch testing (group B); and 10 individuals (5 African Americans and 5 Caucasians) with no past history of contact allergy or significant skin disease were enrolled, to evaluate ethnic variability in skin response to Ivory dishwashing liquid (Procter Gamble, Inc., Cincinnati, OH), a common household irritant (group C).

Written consent was obtained prior to enrollment. The research protocol was approved by the Institutional Review Board Subcommittee on Human Studies at Massachusetts General Hospital. All evaluations were conducted in collaboration with the Contact Dermatitis Unit at the Massachusetts General Hospital. The clinical investigation was conducted according to the Declaration of Helsinki principles. All 44 subjects completed the study. The data of all subjects were included in the analysis.

Protocol Design

All sites for testing were selected on the ventral forearm or anterior thigh, and a total of six 10 mm Finn Chambers (Allerderm Laboratories, Inc., Petaluma, CA) and filter paper disks for the aqueous solutions (Epitest Ltd Oy, Tuusula, Finland; distributed by Allerderm) were used. The subjects for the kinetics study (group A) were exposed to 3.5 mL of 4% sodium lauryl sulfate and the specific test allergen (Trolab, Hermal Kurt Hermann, Reinbek, Germany) in two duplicate chambers. Phosphate-buffered saline (PBS) and a substance with no chemical served as controls. Allergens used included nickel sulfate ($n = 4$), fragrance mix ($n = 3$), balsam of Peru ($n = 3$), quaternium-15 ($n = 1$), wool alcohols ($n = 1$), thimerosal ($n = 1$), para-phenylenediamine-2 (PPD-2) ($n = 1$), mercapto mix ($n = 1$), 4-para-tert-butylphenol formaldehyde resin ($n = 1$), and imidazolidinylurea ($n = 1$).

Subjects for the sensitivity and specificity protocol (group B) were exposed to nickel sulfate (6 $2H_2O$) 5% ($n = 6$), thimerosal ($n = 2$), fragrance mix 8% with sorbitan sesquioleate 5% ($n = 2$), wool alcohols ($n = 1$), mercapto mix ($n = 2$), quaternium-15 1% ($n = 1$), balsam of Peru 25% ($n = 2$), and PBS, in duplicate or triplicate chambers.

The patch-test substances were applied for 48 hours, and individual participants returned for follow-up evaluations at one or more time points following patch removal. At every evaluation visit, each site was studied with clinical judgment and an RCM evaluation.

To evaluate the ethnic variability in skin response to contact irritants, participants in group C were patch-tested with graded concentrations of a common household irritant (Ivory dishwashing liquid) and were evaluated by clinical scoring and RCM at 24 and 48 hours.

Clinical Evaluation

Table 1 shows the criteria for the clinical scoring of CD reactions. Clinical evaluations were performed by the investigator and were based on the standard clinical evaluation scheme recommended by the North American Contact Dermatitis Group for ACD and ICD.[3,18] Clinical photographs of the skin reactions were taken with a digital camera (Nikon Coolpix 950, Nikon Corporation, Tokyo, Japan) under standard conditions. All patients in the kinetics study (group A) returned for clinical scoring and RCM evaluation at 48 and 72 hours and for two or more follow-up evaluations at different time points thereafter within up to 21 days.

In patients enrolled for the sensitivity and specificity study (group B), all sites were subjected to clinical evaluation for the presence or absence of CD. The final interpretation of patch-test results was made by an expert in the field of CD (one of the present authors [E.G.]) who was blinded to the participants' names and exposure protocol, and a score of 1 (for ACD) or 0 (for no ACD) was assigned to each test site. Subsequently, all test sites were evaluated with RCM; the investigators conducted a systematic assessment of the presence or absence of the individual RCM features of ACD and assigned a score of 1 or 0 to each parameter. The RCM images of control and

Table 1. Clinical Scoring Scale*

Score	*ACD*	*ICD*
0	Negative	Negative
0.5	Macular erythema	Barely perceptible macular erythema
1	Weak (nonvesicular) reaction, induration, papules possible	Mild erythema
2	Strong (edematous or vesicular) reaction, erythema, induration, papules, vesicles	Moderate to intense uniform erythema
3	Extreme (spreading, bullous, or ulcerative) reaction	Intense erythema and edema, vesiculation, or erosion

ACD = allergic contact dermatitis; ICD = irritant contact dermatitis.
*Based on the guidelines of the International Contact Dermatitis Research Group and the North American Contact Dermatitis Group and modified to a simple present/absent scheme for the sensitivity and specificity protocol (not shown).

ACD sites were then evaluated by three independent observers who were blinded to participants' names and to the sites of exposure. Sensitivity and specificity were determined for each individual RCM parameter in reference to patch testing. Observers saw images taken at 48 and 72 hours sequentially, to somewhat imitate the clinical setting of patch testing.

Observations of patients enrolled for the ethnic susceptibility study (group C) were performed at 24 and 48 hours after exposure to the irritant. Clinical scores were assigned to each test site, and the threshold irritant concentration was determined individually for each participant. The threshold irritation concentration was defined (by visual inspection) as the lowest concentration of the selected irritant upon exposure to which a clinical reaction occurred; the subthreshold concentration was defined as the highest analyzed concentration of the selected irritant upon exposure to which a skin reaction was still not clinically perceptible.

In Vivo RCM Evaluation

A commercially available reflectance confocal microscope (Vivascope 1000, Lucid-Tech Inc., Henrietta, NY) was used to image the ACD and control skin sites. (A detailed description of this technique and the device used here has been published elsewhere.)[25,26] Briefly, images obtained by confocal microscopy in real time are en face horizontal images parallel to the skin surface, as compared to vertical sections perpendicular to the skin surface that are obtained by routine histology. The generation of images in RCM is based on the principle of reflection, absorption, and scattering [25,26,35–37] and corresponds to the presence of endogenous contrast, which is provided by chromophores such as melanin, hemoglobin, and cellular microstructures.[25] Visualization of cellular details depends on optical properties such as the refraction index and the reflectivity of the tissue under investigation.[36,37] The interpretation of confocal images is defined by "virtual sectioning" of the skin[25] by focusing the laser light on individual levels within the skin. To allow a systematic skin analysis, horizontal mapping was performed, producing an overview of an area of 800 × 1,000 microns, and four to six individual images (200 × 250 microns) were captured. For the orientation of the investigator, imaging routinely started with the stratum corneum (SC) as the topmost layer and continued in axial imaging mode through the entire epidermis and into the upper reticular dermis.[29,32,33] New commercially available systems can obtain mosaics from areas up to 4 × 4 mm.

Characteristic RCM parameters of ACD have been described previously.[31–33] Evaluation parameters are shown in Figure 1, and the corresponding features are listed in Table 2. Additionally, in vivo RCM was used to quantify the thickness of the suprapapillary epidermal plates.[27,32] The investigator (S.G.), an expert in the field of confocal microcopy, evaluated all test sites. The sites were systematically evaluated for the presence or absence of individual RCM features.

Statistical Analysis

The sensitivity and specificity for each RCM parameter were determined in reference to patch testing, and p values were determined with the chi-square test. All significant RCM parameters were analyzed by logistic regression analysis to determine which parameter had the best predictive value for the presence or absence of disease (ie, ACD). To establish the relevant features for the characterization of ACD, discriminative analysis was applied to all parameters. Further analysis was performed on all parameters by using cross-tables to determine the correlation between a selected RCM feature and the confocal parameters themselves.

For the analysis of data on ethnic susceptibility to ICD, nonparametric variables such as quantitative RCM parameters and the clinical scores Mann-Whitney test was used. Fluorescence excitation spectro (FES) and transepidermal water loss (TEWL) values were analyzed with a

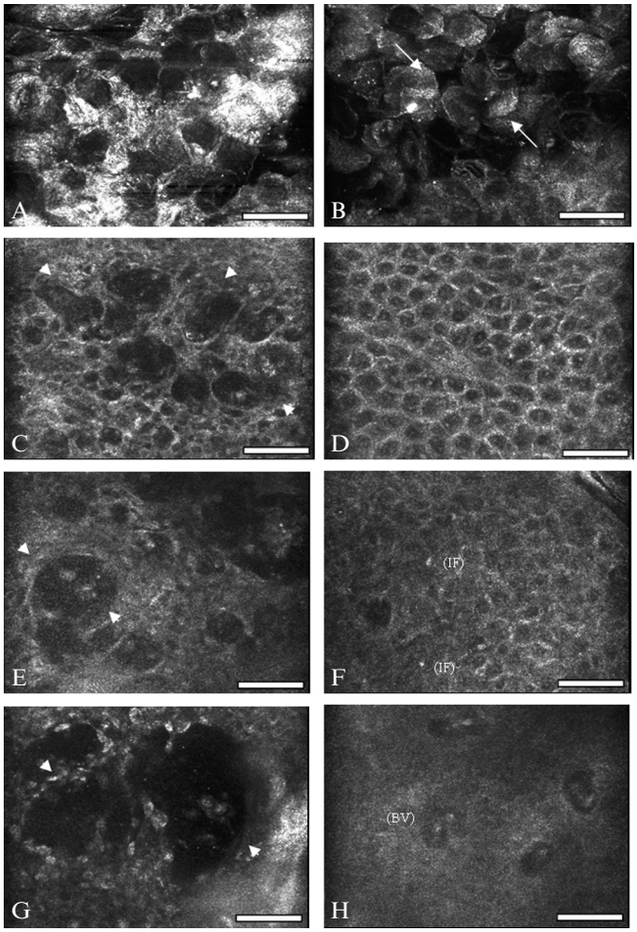

Figure 1. Reflectance confocal microscopy (RCM) evaluation parameters of contact dermatitis. *A* and *B*, parakeratosis and individual corneocytes (*arrows*), respectively, at the level of the stratum corneum. *C*, Features of a multichambered microvesicle (*arrowheads*) at the level of the granular layer. *D*, Severe spongiosis at the level of the granular layer, indicated by the marked increase in intercellular brightness. *E*, Intraepidermal vesicle formation in the spinous layer showing the delineation/dimension of the vesicle (*arrowheads*). *F*, Spongiosis and interspersed inflammatory cells (*IF*) in the spinous layer. *G*, Vesicle formation in the upper papillary dermis showing the dimension of the vesicle (*arrowheads*) *H*, blood vessel dilatation (*BV*) in the upper papillary dermis. Scale bars = 50 μm. Adapted from Swindells K, Burnett N, Rius-Diaz F, et al. Reflectance confocal microscopy may differentiate acute allergic and irritant contact dermatitis. J Am Acad Dermatol 2004;50:220–8. González et al.[31]

linear general model, using repeated-measurements multivariate analysis of variance with a within factor (time/days) and a between factor (race); results were expressed as the mean plus or minus the standard deviation. All data analyses were conducted with the *SPSS* software package (SPSS Inc., Chicago, IL). A value of $p < .05$ was considered statistically significant.

Results

Characteristics of ACD and ICD

The characteristic RCM features of CD are shown in Figure 1.[33,34] Spongiosis and exocytosis were present in both ACD and ICD whereas SC disruption, parakeratosis, and detached corneocytes were characteristically seen in ICD. Superficial perivascular infiltrate was present in both ACD and ICD, and whereas ACD more commonly presented with vesicle formation, increased epidermal thickness was more characteristic of ICD.[34]

RCM was able to identify disruptive changes in the SC by the presence of parakeratosis and individual detached corneocytes (see Fig 1, *A* and *B*).[26,33,34,38]

Within the level of the stratum granulosum, large polygonal cells ranging from 25 to 30 microns in diameter were identified; epidermal spongiosis was defined by increased intercellular brightness with exaggerated cell-cell demarcation. Inflammatory cells were identified as bright round-to-oval structures, 8 to 10 microns in diameter, interspersed between the epidermal keratinocytes (see Fig 1, *C* and *D*).

Similarly, the presence of spongiosis of the spinous layer on RCM evaluation was identified by increased brightness of the intercellular spaces and cells measuring about 15 microns in diameter. Intraepidermal vesicle formation and necrosis corresponded to the presence of larger and somewhat circular dark areas; necrotic keratinocytes and inflammatory cells may be present in the vesicular lumen. Necrosis was defined by the complete disruption of the epidermal architecture in the absence of vesicle formation but with the presence of necrotic keratinocytes and inflammatory cells (see Fig 1, E and F).

Furthermore, RCM was able to show the presence of dilated capillaries in dermal papillae and leukocytes trafficking (see Fig 1, *G* and *H*).[26,38]

Confocal Features of CD and Their Kinetic Changes As Evaluated by Real-Time RCM (Group A)

Figure 2 illustrates the mean RCM scoring values of SC changes in ACD, ICD, and control over time. Selected RCM features demonstrated significant differences between ACD and ICD. Disruptive changes in the SC were significantly more pronounced in ICD than in either ACD or control sites. In ICD, RCM imaging at the level of the SC confirmed the presence of parakeratosis

Table 2. Reflectance Confocal Microscopy Evaluation Parameters for Contact Dermatitis

Imaging Level	*Evaluation Parameters**				
SC	Disruption	Individual corneocytes	Parakeratosis	SC inflammatory infiltrate	—
SG	Exocytosis	Vesicle formation	Necrosis	Spongiosis	Prominent nucleoli
SS	Exocytosis	Vesicle formation	Necrosis	Spongiosis	Prominent nucleoli
DEJ	Exocytosis	Vesicle formation	Necrosis	—	BV dilatation

Adapted from González S et al[31]; Hicks S et al[32]; Swindells K et al.[33]
BV = blood vessel; DEJ = dermo-epidermal junction; SC = stratum corneum; SG = stratum granulosum; SS= stratum spongiosum.
*Based on reflectance confocal microscopy features relevant for the diagnosis of allergic contact dermatitis and irritant contact dermatitis, respectively, as previously published and correlated to routine histology.

(see Fig 2*A*), detached corneocytes (see Fig 2*B*), and SC disruption (see Fig 2*C*) whereas similar changes were generally absent in ACD. Corresponding mean clinical scoring values were higher for ICD than for ACD up until day 9.

At the level of the granular and spinous layers, exocytosis, spongiosis, vesicle formation and epidermal necrosis were present in both ACD and ICD. Figure 3 shows the evolution of selected features over time. On days 2 and 3, epidermal hyperproliferation (see Fig 3*A*), exocytosis (see Fig 3*B*), spongiosis (see Fig 3*C*), vesicle formation, and epidermal necrosis were significantly more severe in ICD than in ACD; this might have been related to the higher clinical scores of the test sites exposed to irritants reported in this series. The selective presence of intraepidermal necrosis was more characteristic of ICD reactions whereas microvesicles were more typically seen in ACD. On the other hand, ACD demonstrated the prolonged presence of exocytosis in both the spinous and granular layers. Increased suprapapillary epidermal thickness corresponded to epidermal hyperproliferation and demonstrated significant differences between ACD and ICD at all time points. Overall, the data indicated a prolonged activity of ACD when compared to ICD.

Diagnostic Accuracy of RCM in CD (Group B)

Thirteen of 16 patients had negative clinical scores at the control sites, which correlated with the absence of ACD features on RCM (Fig 4, *A*, *C*, *E*, and *G*). Three subjects presented with a borderline positive clinical score at their control site, but RCM examination of these sites revealed no features of ACD suggestive of false-positive clinical responses.

For 11 of 16 patients who were clinically positive for ACD, the clinical findings correlated to the presence of RCM features of ACD (see Fig 4, *b*, *d*, *f*, and *G*). For those patients who were clinically negative for ACD, the clinical findings corresponded to the absence of RCM features of ACD. However, one subject with negative clinical scores

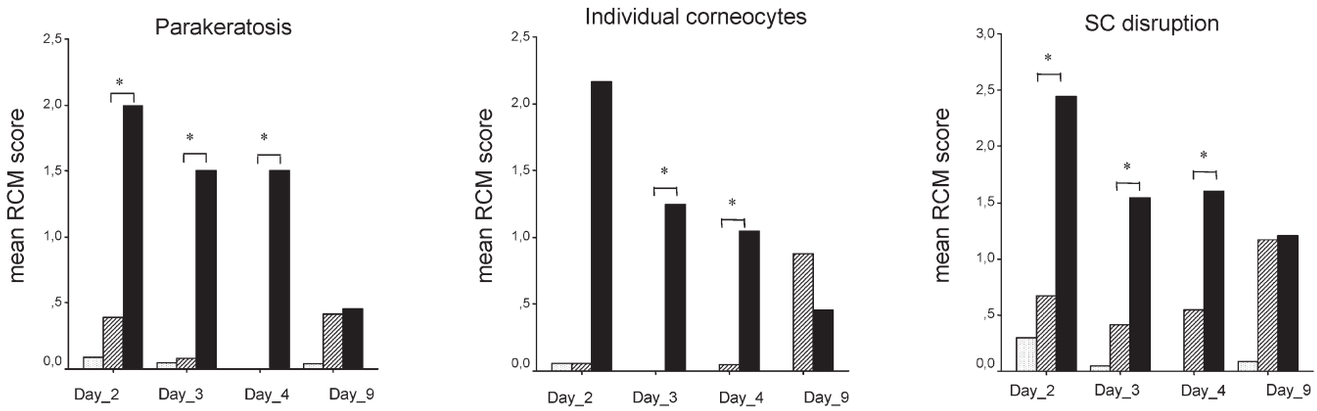

Figure 2. Graphs illustrating the severity and evolution of selected reflectance confocal microscopy (RCM) parameters of the stratum corneum (SC). *A*, *B*, and *C*, Mean RCM scores of parakeratosis, detached corneocytes, and SC disruption, respectively, over time; In each graph, the x-axis corresponds to days 2, 3, 4, and 9 after removal of the Finn Chambers; the y-axis corresponds to the respective mean RCM scoring values for each individual day. Black, striped, and dotted bars (respectively keyed as IRR, ALL, and CO in *A*) represent irritant contact dermatitis, allergic contact dermatitis, and control sites, respectively. (*Level of statistical significance [$p < .05$]).

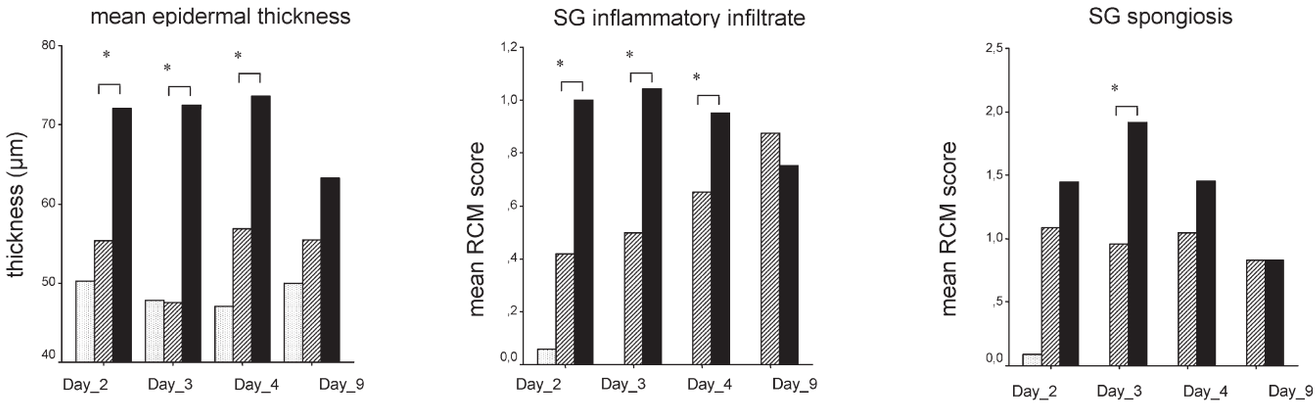

Figure 3. Graphs illustrating the severity and evolution of selected reflectance confocal microscopy (RCM) parameters at the level of the stratum granulosum (SG). Mean scoring values of allergic contact dermatitis (ACD), irritant contact dermatitis (ICD), and control sites are shown at days 2, 3, 4, and 9 after removal of the Finn Chambers. *A*, Evolution of the epidermal thickness in microns over time as evaluated by RCM. The x-axis indicates days 2, 3, 4, and 9 after removal of the Finn Chambers; the y-axis indicates the respective mean epidermal thickness in microns for each individual day. *B* and *C*, Evolution of SG exocytosis and SG spongiosis, respectively. The x-axis indicates days 2, 3, 4, and 9 after removal of the Finn Chambers; the y-axis indicates the mean RCM scoring values for each individual day. Black, striped, and dotted bars (respectively keyed as IRR, ALL, and CO in *A*) represent ICD, ACD, and control sites, respectively. (*Level of statistical significance [$p < .05$]).

actually demonstrated evidence of ACD on RCM evaluation at all test sites.

Table 3 shows sensitivity and specificity data for selected features in the granular and spinous layers. While the specificity was high for all features, ranging from 95.8 to 100%, the sensitivity ranged widely from 51.9 to 96.3%. Parameters with high sensitivity and specificity included stratum spongiosum (SS) spongiosis (100% sensitivity, 92.6% specificity, $p < .05$), stratum granulosum (SG) spongiosis (95.8% sensitivity, 96.3% specificity, $p < .05$), and exocytosis (100% sensitivity, 74.1% specificity, $p < .05$). Logistic regression analysis indicated that SS spongiosis was the best predictor for diagnosing ACD. Further analysis was applied to determine the correlation between SS spongiosis, SG spongiosis, and SS vesicle formation; SG spongiosis and features of SS and SG inflammatory infiltrate also correlated well with the presence of ACD.

Ethnic Variability in Skin Response (Group C)

Our findings showed a lower threshold for cutaneous irritation in Caucasians. RCM revealed SC disruption, parakeratosis, and detached corneocytes in both study groups, yet selected features were more severe in Caucasians. Intraepidermal changes such as spongiosis and vesicle formation at the level of the granular and spinous layers were observed in both African Americans and Caucasians at sites with comparable clinical scores at the 24-hour time point. Caucasian participants showed a significant increase of epidermal thickness at the threshold and subthreshold irritant concentration. At test sites where the clinical response was absent or subtle, characteristic pathologic changes of ICD were consistently visualized with RCM, and features were significantly more severe in the Caucasian group than in the African American group.[32]

Discussion

The inability to differentiate ACD and ICD on clinical or even histologic grounds represents a significant challenge to dermatologists.[2–8] While dermatologists have investigated the significant occupational impact and psychosocial aspects of this problem, the field has also become the focus of an expanding cosmetic industry.

Patch testing has become an essential tool in the investigation of ACD in clinical practice because of its diagnostic and therapeutic value. It has become the gold standard in the confirmation of ACD as a manifestation of delayed hypersensitivity to an antigen. The reliability of this bioassay as a window or "snapshot" of an immunologic event, however, has been questioned, and several clinical studies have investigated the reproducibility of its findings.[39–41] Repeated histologic evaluations, on the other hand, are limited by the removal of tissue from the subject and the irreversible alteration of the test area.[42] RCM allows the evaluation of skin architecture in real time and in vivo to a maximum depth of 300 to 350 microns. Because of the noninvasiveness of this methodology, skin sites can be imaged repeatedly, thus permitting a longitudinal evaluation over time. The investigation of a single

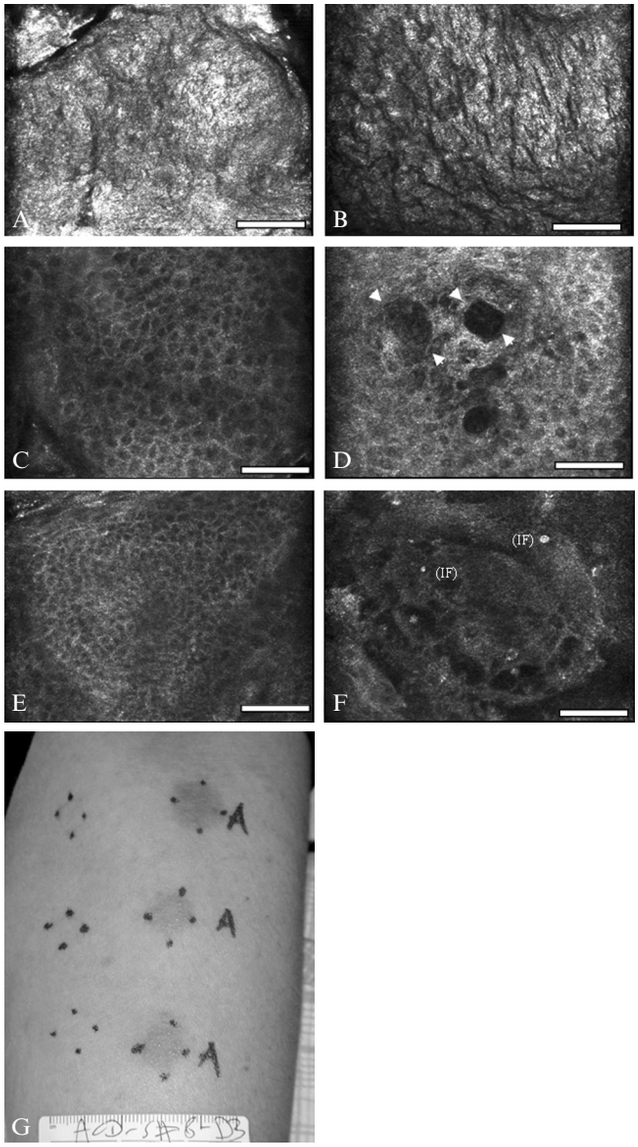

Figure 4. *A* to *F*, Reflectance confocal microscopy (RCM) images of control sites and test sites exposed to allergen. *Left panel* contains RCM images of control sites; *right panel* contains RCM images of allergic contact dermatitis (ACD) test sites. *A* and *B* correspond to the level of the stratum corneum; no abnormality was detected in either ACD or control sites. *C* and *D* correspond to the level of the stratum spinosum; the control site (*C*) showed no abnormality whereas the ACD test sites demonstrated spongiosis and the presence of intraepidermal vesicles (*arrowheads* in *D*). *E* and *F* correspond to the level of the stratum spinosum; *E* shows the normal appearance of the control site, and *F* displays the presence of spongiosis and inflammatory cells (*IF*) in the ACD test site. *G*, Clinical photograph taken at day 3 after removal of the Finn Chambers, showing the positive test results in the skin sites exposed to allergen and the absence of a clinical reaction in the control sites.

test site by an experienced investigator takes 10 to 15 minutes. Recent studies indicate that the interpretation of RCM images is easily learned and does not necessarily require previous experience in the field.[43] The system used in this study was the prototype of a smaller ''handheld'' confocal microscope that may aid in serial evaluations of study sites. Substantial costs are associated with acquisition, but recent technologic advancements incorporate a digital optical system that allows investigators to capture observed clinical images comparable to those of dermatoscopy and that may decrease the time needed for the acquisition, storage, and interpretation of imaging results.

Table 3. Specificity and Sensitivity of Selected Reflectance Confocal Microscopy Features of Contact Dermatitis

RCM Feature	*Sensitivity (%)*	*Specificity (%)*	p *Value**
Granular Layer			
Exocytosis	100	74.1	< .001
Spongiosis	95.8	96.3	< .001
Vesicles	100	77.8	< .001
Spinous Layer			
Exocytosis	95.8	66.7	< .001
Spongiosis	100	92.6	< .001
Vesicles	100	70.4	< .001

RCM = reflectance confocal microscopy.
*Respective levels of significance.

We used RCM to describe the pathophysiologic aspects of acute ACD and ICD. Whereas ACD predominantly demonstrated vesicle formation, inflammatory infiltrate, and spongiosis,[33,34] ICD was typically associated with pronounced superficial changes involving the SC, intraepidermal necrosis, and a prominent epidermal hyperproliferative response.[32–34] In the majority of reported studies, both ACD and ICD demonstrated similar degrees of spongiosis, and this feature may not facilitate the differentiation of these two reactions.

When kinetic evolution over time was examined, characteristic patterns of ACD and ICD could be visualized with RCM. First, the onset of disruptive changes was faster for ICD than for ACD. The characteristic superficial changes of the SC were evident within hours after the application of the contact irritants; similar changes were generally absent in acute ACD but did develop in subacute ACD reactions. The degrees of spongiosis and exocytosis were comparable for both reactions in the early phases of CD; yet during later phases, ACD more commonly presented with spongiotic features, owing to a longer recovery of allergic reactions. Whereas vesicles occurred in both ACD and ICD, intraepidermal necrosis was more commonly found in ICD.[33,34]

The marked increase of epidermal thickness in irritant reactions can only partially be explained by the presence of

spongiosis because it is not evident in ACD reactions with similar degrees of spongiosis. ICD and other skin diseases[44,45] have previously been associated with changes in epidermal proliferation, cellular differentiation,[46] and regenerative hyperplasia.[42]

Increased epidermal thickness in ICD is a function of the disruptive changes in the SC and corresponds to the presence of individual corneocytes, parakeratosis, and hyperkeratosis.[42,47,48] In subacute ACD focal parakeratosis, hyperkeratosis and increased epidermal thickness are features of a delayed hyperproliferative response, which is in concordance with previous studies.[42,49]

Non-Caucasian skin response to irritants presents difficulties in the assessment of erythema, particularly in individuals with skin phototype (SPT) V and VI; therefore, new methodologies for evaluation are needed. In our preliminary studies, we exposed participants to experimental irritants such as sodium lauryl sulfate and a common household detergent.[31] Participants with Fitzpatrick SPT I-III (Caucasians) and SPT V-VI (African-Americans), which defines individual response to sun exposure, exhibited different degrees of SC disruption, spongiosis and exocytosis,[32] and our findings indicated an increased susceptibility in Caucasians when compared to African Americans. In addition, RCM was able to visualize subclinical degrees of cutaneous irritation, demonstrating the ability of this technique to detect irritation at subthreshold irritant concentrations or when constitutive pigmentation precludes the clinical evaluation of erythema as a parameter of inflammation. Future studies are needed to confirm these findings, however, to determine their applicability to other contact irritants and detergents.

The reproducibility and accuracy of patch testing has been questioned in the interpretation of mild clinical reactions, for which inconclusive results are common. It has become customary to interpret mild (+) cases of ICD and ACD as questionable since there is no diagnostic tool to assess a true allergic reaction from an irritant reaction at that intensity level.[3] Preliminary data on the sensitivity and specificity of RCM in the diagnosis of ACD in reference to patch testing indicate that the adjunctive use of noninvasive diagnostics may increase the accuracy of patch-test interpretations.

Summary

Overall, reflectance confocal microscopy (RCM) may be a promising tool for noninvasive diagnosis of contact dermatitis (CD). The resolution of RCM is comparable to that of routine histology, the results are reproducible, and the procedure is painless. RCM may offer significant advantages and additional benefits over clinical assessment and conventional histology. We have demonstrated that RCM may differentiate acute irritant and allergic reactions accurately and can verify clinical readings. In instances associated with subthreshold allergen and irritant concentrations, subclinical changes may be observed with RCM. Furthermore, RCM may assist with the interpretation of allergic or irritant reactions after patch testing in persons of color, with whom the assessment of erythema is more difficult.

Our findings are consistent with previous results and generally confirm studies done with serial electron microscopy and histologic studies by other investigators.[4,42] The noninvasive nature of this method allows the evaluation of skin sites repeatedly and over time, thus permitting a longitudinal evaluation and a more comprehensive understanding of skin pathophysiology. RCM may be useful in diagnosing allergic contact dermatitis (ACD) and may help to further differentiate true positive ACD reactions from negative test results. By the integration of established features of cutaneous histopathology with images obtained with confocal microscopy, new insights into human skin can be obtained, and a distinction between ACD and irritant contact dermatitis may be achieved in questionable cases of CD.

These results substantiate the potential clinical application of noninvasive optical techniques as adjunct diagnostic tools for the evaluation of CD. Future work should be aimed at the evaluation of individual allergens, the testing of irritancy and allergenicity thresholds, and additional contact irritants and cosmetic products.

Acknowledgment

The authors would like to acknowledge Francisca Rius-Diaz, PhD, for her assistance with the data analysis.

References

1. Mathias C. The cost of occupational disease. Arch Dermatol 1985; 89:332–4.
2. Brasch J, Burgard J, Sterry W. Common pathogenetic pathways in allergic and irritant contact dermatitis. J Invest Dermatol 1992;98: 166–70.
3. Rietschel RL, Fowler JF, Fisher AA, editors. Fisher's contact dermatitis. 5th ed. Philadelphia: Lippincott Williams & Wilkins; 2001.
4. Willis CM, Young E, Brandon DR, Wilkinson JD. Immunopathological findings in human allergic and irritant contact dermatitis. Br J Dermatol 1986;115:305–16.

5. Scheynius A, Fischer T, Forsum U, Klareskog L. Phenotypic characterization in situ of inflammatory cells in allergic and irritant contact dermatitis in man. Clin Exp Immunol 1984;55:81–90.
6. Scheynius A, Fischer T. Phenotypic difference between allergic and irritant patch test reactions in man. Contact Dermatitis 1986;14: 297–302.
7. Flier J, Boorsma DM, Bruynzeel DP, et al. The CXCR activating chemokines IP-10, Mig, and IP-9 are expressed in allergic but not in irritant patch test reactions. J Invest Dermatol 1999;13: 574–8.
8. Ulfgren AK, Klareskog L, Lindberg M. An immunohistochemical analysis of cytokine expression in allergic and irritant contact dermatitis. Acta Derm Venereol 2000;80:167–70.
9. Dvorak HF, Mihm MC, Dvorak AM, et al. Morphology of delayed type hypersensitivity reactions in man. I: Quantitative description of the inflammatory response. Lab Invest 1974;31: 111–30.
10. Dvorak AM, Mihm MC, Dvorak HF. Morphology of delayed type hypersensitivity reactions in man. II: Ultrastructural alterations affecting the microvasculature and tissue mast cells. Lab Invest 1976;34:179–91.
11. Dvorak HF, Mihm MC. Basophilic leukocytes in allergic contact dermatitis. J Exp Med 1972;135:235–54.
12. Belsito DV, Frances SJ, Taylor JS, et al. Reproducibility of patch tests: a United States multicenter study. Am J Contact Dermat 1992; 3:193–200.
13. Schuster S. patch-test sensitivity and reproducibility in individual and populations. Am J Contact Dermat 1992;3:74–8.
14. Brasch J, Henseler T, Aberer W, et al. Reproducibility of patch tests. A multicenter study of synchronous left versus right-sided patch tests by the German Contact Dermatitis Research Group. J Am Acad Dermatol 1994;31:584–91.
15. Nethercott JR. Practical problems in the use of patch testing in the evaluation of patients with contact dermatitis. In: Weston WL, Mackie RM, Provost TT, editors. Current problems in dermatology. St. Louis: Mosby Yearbook; 1990. p. 101–23.
16. Nethercott JR. Sensitivity and specificity of patch tests. Am J Contact Dermat 1994;5:136–42.
17. Lushniak B. Occupational and environmental medicine; occupational skin diseases. Prim Care 2000;27:1–16.
18. Marks JG, Elsner P, DeLeo VA. Contact and occupational dermatology. 3rd ed. St. Louis: Mosby; 2002.
19. Berardesca E, Distante F. The modulation of irritation. Contact Dermatitis 1994;31:281–7.
20. Effendy I, Maibach HI. Surfactants and experimental contact dermatitis. Contact Dermatitis 1995;33:217–25.
21. Moeshell A. Workshop on irritant contact dermatitis. Am J Contact Dermat 1997;8:79–105.
22. Taylor SC. Skin of color: biology, structure, function, and implications for dermatologic disease. J Am Acad Dermatol 2002; 46:S41–62.
23. Weigand DA, Gaylor JR. Irritant reaction in Negro and Caucasian skin. South Med J 1974;67:548–51.
24. La Ruche G, Cesarini JP. Histology and physiology of black skin. Ann Dermatol Venereol 1992;119:567–74.
25. Rajadhyaksha M, Grossman M, Esterowitz D, et al. In vivo confocal scanning laser microscopy of human skin: melanin provides strong contrast. J Invest Dermatol 1995;104:946–52.
26. Rajadhyaksha M, Anderson RR, Webb RH. Video-rate confocal scanning laser microscope for imaging human tissues in vivo. Appl Optics 1999;38:1–12.
27. Huzaira M, Rius F, Rajadhyaksha M, et al. Topographic variations in normal skin, as viewed by in vivo reflectance confocal microscopy. J Invest Dermatol 2001;116:846–52.
28. Busam KJ, Hester K, Charles C, et al. Detection of clinically amelanotic malignant melanoma and assessment of its margins by in vivo confocal scanning laser microscopy. Arch Dermatol 2001; 137:923–9.
29. González S, Rajadhyaksha M, Rubinstein G, Anderson RR. Characterization of psoriasis in vivo by reflectance confocal microscopy. J Med 1999;30(5-6):337–56.
30. Aghassi D, Anderson RR, Gonzalez S. Confocal laser microscopic imaging of actinic keratoses in vivo: a preliminary report. J Am Acad Dermatol 2000;43(1 Pt 1):42–8.
31. González S, Gonzalez E, White MW, et al. Allergic contact dermatitis: correlation of in vivo confocal imaging to routine histology. J Am Acad Dermatol 1999;40:708–13.
32. Hicks S, Swindells KJ, Middelkamp-Hup MA, et al. Confocal histopathology of irritant contact dermatitis in vivo and the impact of skin color (black versus white). J Am Acad Dermatol 2003;48: 727–34.
33. Swindells K, Burnett N, Rius-Diaz F, et al. Reflectance confocal microscopy may differentiate acute allergic and irritant contact dermatitis in vivo. J Am Acad Dermatol 2004;50:220–8.
34. Astner S, González E, Cheung AC, et al. Non-invasive evaluation of the kinetics of allergic and irritant contact dermatitis. J Invest Dermatol 2005;124:351–9.
35. Vand de Hulst HC. Light scattering by small particles. New York: Dover Publications; 1981.
36. Carlsson K. The influence of specimen refractive index, detector signal integration, and non-uniform scan speed on the imaging properties in confocal microscopy. J Microsc 1991;163: 167–78.
37. Hell S, Reiner G, Cremer C, Stelzer EHK. Aberrations in confocal fluorescence microscopy induced by mismatches in refractive index. J Microsc 1993;169:391–405.
38. Rajadhyaksha M, González S, Zavislan JM, et al. In vivo confocal scanning laser microscopy of human skin II: advances in instrumentation and comparison with histology. J Invest Dermatol 1999;13:293–303.
39. Gollhausen R, Przybilla B, Ring J. Reproducibility of patch tests. J Am Acad Dermatol 1989;21:1196–202.
40. Bourke JF, Batta K, Prais L, et al. The reproducibility of patch tests. Br J Dermatol 1999;140:102–5.
41. Lachapelle J-M, Antoine JL. Problems raised by the simultaneous reproducibility of positive allergic patch test reactions in humans. J Am Acad Dermatol 1989;21:850–4.
42. Medenica M, Rostenberg A, Jr. A comparative light and electron microscopic study of primary irritant contact dermatitis and allergic contact dermatitis. J Invest Dermatol 1971;56:259–71.
43. Gerger A, Koller S, Kern T, et al. Diagnostic applicability of in vivo confocal laser scanning microscopy in melanocytic skin tumors. J Invest Dermatol 2005;124:493–8.
44. Ghadially R, Reed JT, Elias PM. Stratum corneum structure and function correlates with phenotype in psoriasis. J Invest Dermatol 1996;107:558–64.

45. Lavrijsen AP, Bouwstra JA, Gooris GS, et al. Reduced skin barrier function parallels abnormal stratum corneum lipid organization in patients with lamellar ichthyosis. J Invest Dermatol 1995;05: 619–24.
46. Le TKM, Van der Valk PGM, Schwalkwijk J, Van De Kerkhof PCM. Changes in epidermal proliferation and differentiation in allergic and irritant contact dermatitis reactions. Br J Dermatol 1995;133: 236–40.
47. Le TKM, Schalkwijk J, Siegenthaler G, et al. Changes in keratinocyte differentiation following mild irritation by sodium dodecyl sulphate. Arch Dermatol Res 1996;288:684–90.
48. Le TKM, Schalkwijk J, van de Kerkhof PC, et al. A histological and immunohistochemical study on chronic irritant contact dermatitis. Am J Contact Dermat 1998;9:23–8.
49. Lee JY, Effendy I, Maibach HI. Acute irritant contact dermatitis: recovery time in man. Contact Dermatitis 1997;36:285–90.