European Archives of Oto-Rhino-Laryngology
https://doi.org/10.1007/s00405-019-05465-x

RHINOLOGY

Multiple airborne allergen-induced eosinophilic chronic rhinosinusitis murine model

Sang Chul Park[1] · Soo In Kim[2,3] · Chi Sang Hwang[4] · Hyung-Ju Cho[1,3,5] · Joo-Heon Yoon[1,3,5,6] · Chang-Hoon Kim[1,3,5,7]

Received: 3 March 2019 / Accepted: 8 May 2019
© Springer-Verlag GmbH Germany, part of Springer Nature 2019

Abstract

Purpose Several murine models have been established to mimic human eosinophilic chronic rhinosinusitis (ECRS). However, in most of these models, ECRS was induced using ovalbumin, which does not cause sinusitis in humans. Thus, we aimed to develop a more clinically relevant murine model of ECRS using multiple airborne allergens. We also investigated the effects of exposure duration of the allergens on ECRS development.

Methods C57BL/6 mice were intranasally administered multiple airborne allergens (house dust mite, *Aspergillus fumigatus*, *Alternaria alternata*, and protease from *Staphylococcus aureus*) three times weekly for 4, 8, 12, and 16 consecutive weeks. Histopathological changes, the levels of cytokines and chemokines in the nasal lavage fluid, and immune cells of the blood and spleen were analyzed.

Results The mice administered multiple allergens showed significantly increased eosinophil infiltration, epithelial thickening and disruption, and subepithelial collagen deposition from 8 weeks compared to the control group. Goblet cell hyperplasia, polyp-like lesions, and blood eosinophils, as well as the levels of interleukin-5 and eotaxin in the nasal lavage fluid were considerably increased in the ECRS group from 12 weeks compared to those of controls. Instillation of allergens for 16 weeks exacerbated the eosinophil infiltration and eotaxin increase in the nasal lavage fluid.

Conclusions We successfully established a new murine model of ECRS using more clinically relevant multiple airborne allergens. Prolonged exposure to airborne allergens for 12 weeks or more, corresponding to the definition of human ECRS, strongly induced eosinophil infiltration as well as epithelial remodeling.

Keywords Rhinosinusitis · Eosinophil · Airborne allergen · Murine model · Epithelial remodeling

Introduction

Chronic rhinosinusitis (CRS) occurs due to chronic inflammation of the sinonasal mucosa, characterized by nasal obstruction, discharge, facial pain, and reduction of smell that can persist for at least 12 weeks [1]. CRS imposes a large social burden worldwide, affecting roughly 16% of the adult United States population [2]. Eosinophilic chronic

Sang Chul Park and Soo In Kim contributed equally to this work.

Electronic supplementary material The online version of this article (https://doi.org/10.1007/s00405-019-05465-x) contains supplementary material, which is available to authorized users.

✉ Chang-Hoon Kim
entman@yuhs.ac

1 Department of Otorhinolaryngology, Yonsei University College of Medicine, 50 Yonsei-ro, Seodaemun-gu, Seoul 03722, South Korea

2 Brain Korea 21 PLUS Project for Medical Science, Yonsei University College of Medicine, Seoul, South Korea

3 Korea Mouse Phenotyping Center, Seoul, South Korea

4 Department of Otorhinolaryngology, Yonsei University Wonju College of Medicine, Wonju, South Korea

5 The Airway Mucus Institute, Yonsei University College of Medicine, Seoul, South Korea

6 Global Research Laboratory for Allergic Airway Diseases, Seoul, South Korea

7 Medical Research Center, Yonsei University College of Medicine, Seoul, South Korea

Published online: 16 May 2019

rhinosinusitis (ECRS) is specifically characterized by eosinophilic inflammatory infiltration and production of type 2 cytokines [3, 4]. ECRS is clinically significant because of its high probability of recurrence despite medical and surgical treatments, as well as its strong association with asthma [5, 6]. ECRS is a common manifestation of CRS in Europe and the United States, whereas non-ECRS forms are more prevalent in Asian countries [7–9]; however, recent studies indicate that the prevalence of ECRS is increasing in Asia [10, 11]. Thus, new treatment strategies for ECRS are needed, which require gaining a better understanding of the mechanism and obtaining a clinically relevant model for testing.

Current animal models of ECRS have provided an opportunity to understand the pathophysiology of the disease and to test the safety and efficacy of new therapeutic agents. However, most of the murine models reported to date were induced to develop ECRS using ovalbumin (OVA) [12–14], which does not accurately mimic the physiological condition, as it does not cause sinusitis in humans. In addition, sensitizing mice with OVA alone via an inhalation route can induce immune tolerance rather than overt immunity [15]. Thus, systemic sensitization by an intraperitoneal route is required to boost immune responses in some models [13, 16, 17], whereas sensitization in humans is highly unlikely to occur through the peritoneum.

Accordingly, a novel murine model of ECRS that more accurately represents the pathophysiology of human ECRS has emerged as a major issue. In human ECRS, several factors activate nasal epithelial cells, including allergens, fungi, *Staphylococcus aureus*, and viruses, leading to the release of epithelial-derived cytokines such as thymic stromal lymphopoietin, interleukin (IL)-33, and IL-25. Subsequently, these cytokines stimulate myeloid dendritic cells, group 2 innate lymphoid cells, and mast cells to induce a type 2 inflammatory response [8, 9]. Thus, we used multiple airborne allergens that are clinically relevant to humans. House dust mite (HDM) is the most common allergen causing airway inflammation, which is frequently detected in home environments [18], and is the major cause of T-helper type 2 (Th2) inflammatory airway diseases. Fungi have also been strongly linked to human allergic diseases as well as to rhinosinusitis [19, 20]. *Aspergillus* has been considered to be the most common cause of fungal rhinosinusitis [21], and *Alternaria* was shown to induce innate Th2 inflammation in both CRS patients [22, 23] and allergic mice [23]. *S. aureus* is one of the most frequently detected bacteria in CRS, and is strongly associated with eosinophilic inflammation and nasal polyps [24].

Therefore, we aimed to develop a more clinically relevant murine model of ECRS using multiple airborne allergens. We combined these four allergens (HDM, *Aspergillus*, *Alternaria*, and *S. aureus*) for the establishment of the present model that better reflects the natural course of human ECRS. In addition, we investigated the effects of the duration of allergen exposure based on time-course analysis to confirm the minimum time required for inducing ECRS in mice and thus optimize the method for model establishment.

Materials and methods

Animals

C57BL/6N female mice at 6 weeks of age were purchased from Orient Bio (Seongnam, Korea) and maintained under specific pathogen-free conditions. The use of animals in this study was approved by the Ethics Committee and Institutional Animal Care and Use Committee of Yonsei University Health System (2017-0094), and the study was conducted according to international guidelines (ARRIVE) on animal experiments.

Establishment of the ECRS model

The mice were intranasally administered multiple airborne allergens three times weekly for 4, 8, 12, and 16 consecutive weeks in the ECRS group; phosphate-buffered saline (PBS)-treated mice were used as the control group. The multiple allergens included a mixture of 20 µg HDM extract (*Dermatophagoides pteronyssinus*; Greer Laboratories, Lenoir, NC, USA), 20 µg *Aspergillus fumigatus* (Greer Laboratories), 20 µg *Alternaria alternata* (Greer Laboratories), and 1 µg protease from *S. aureus* (Abnova, Taipei) dissolved in sterile PBS to a total volume of 30 µl, 15 µl of which was instilled in each nostril. The mice were analyzed at 4, 8, 12, and 16 weeks ($n = 6$ per time point for the control and ECRS group, respectively; based on the previous studies of sinusitis murine model using 3–8 mice per experimental group [12–14, 25]). All mice were killed 24 h after the last intranasal administration (Fig. 1).

Histopathology

The mouse heads were fixed in 4% PFA overnight, decalcified in 10% ethylenediaminetetraacetic acid for 2 weeks, and embedded in paraffin. The embedded tissues were cut into coronal, 4-µm-thick sections. An atlas of the normal murine sinonasal anatomy was used to standardize the anatomic locations examined [26]. The histological changes in the nasal mucosa were analyzed by hematoxylin and eosin stain for overall inflammation, Sirius red stain for eosinophil infiltration and polyp-like lesions, periodic acid–Schiff (PAS) stain for goblet cell hyperplasia, and Masson's trichrome stain for collagen deposition as well as the thickness of the epithelial and subepithelial layers. Quantitative histological analysis was performed independently by two examiners

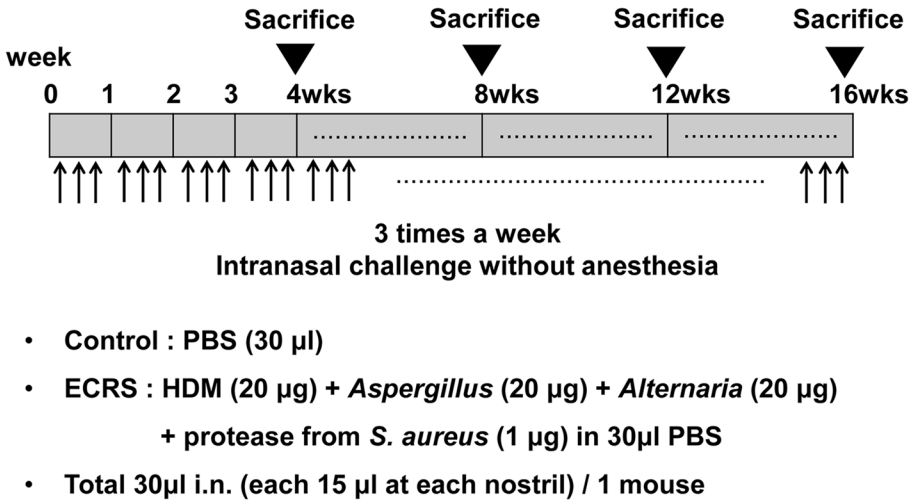

Fig. 1 Experimental protocol for the development of eosinophilic chronic rhinosinusitis (ECRS) in mice. Mice were subjected to intranasal challenge by multiple airborne allergens [house dust mite (HDM), *Aspergillus fumigatus*, *Alternaria alternata*, and protease from *Staphylococcus aureus*] three times weekly to induce ECRS. Phosphate-buffered saline (PBS) was used for the control group. Assessments were performed at 4, 8, 12, and 16 weeks (wks) after the first intranasal challenge

blinded to the experimental group and study interval. The measurement sites were unified for each mouse. Tissue eosinophil aggregates were defined as one or more clusters of eosinophils (> 20/high-power field) within the sinonasal mucosa [27]. The numbers of eosinophils (Supplementary Fig. 1) and goblet cells (Supplementary Fig. 2) were counted under nine high-power fields (400 ×) and summed for between-group comparisons. The maximal mucosal thickness at the transition zone between the olfactory and respiratory epithelium was measured, and the average value from four different areas was used for comparisons. The amount of total collagen deposition was calculated for each section and expressed as the percentage of the collagen-stained section among total cell area using ImageJ software (version 1.51j8; National Institutes of Health, Bethesda, MD, USA) [28]. Polyp-like lesions were defined as elevated mucosal lesions with eosinophilic infiltration and/or microcavity formation [13].

Cytokines and total cell counts in nasal lavage fluid

Nasal lavage was performed according to a previously described method with slight modifications [29]. In brief, the upper airway, including the palatopharyngeal region, was isolated by dissection, and the mouse head was separated at the level of the larynx. After inserting a 24-G catheter through the pharyngeal opening into the choana, 1000 µl of PBS was instilled. Collected fluids from the nostrils were centrifuged, and supernatants were stored for cytokine analysis. The levels of IL-4, IL-5, IL-6, IL-17A, eotaxin (CCL11), interferon (IFN)-γ, and tumor necrosis factor (TNF)-α were measured using enzyme-linked immunosorbent assay (ELISA) kits (R&D Systems, Minneapolis, MN, USA). Cell pellets were resuspended and total cells were counted using a hemocytometer.

Immune cells in the blood and spleen

The cell pellet of the blood was treated with red blood cells (RBC) lysis buffer (Sigma-Aldrich, St. Louis, MO, USA), and then single-cell suspensions were obtained by filtering through a 40-µm nylon mesh cell strainer. The harvested spleen was incubated in RPMI 1640 digestion medium [10% fetal bovine serum, 0.1% collagenase type II, 1 mM $MgCl_2$, and 1 mM $CaCl_2$] at 37 °C for 30 min. After lysis of RBC, suspended single cells were blocked with Fc block (anti-CD16/32; eBioscience, San Diego, CA, USA) at 4 °C for 15 min. Prepared cells of blood and the spleen were stained with fluorochrome-conjugated antibodies against CD3e, CD11b, CD11c, CD19, CD45, CD64, F4/80, MHC II, Siglec-F, and Ly6G (eBioscience) at 4 °C for 30 min. The stained cells were analyzed using a BD LSR II Fortessa flow cytometer (Becton–Dickinson, San Jose, CA, USA) and FlowJo software (Tree Star, Inc., Ashland, OR, USA).

Statistical analysis

All statistical analyses were performed using IBM SPSS software (version 23.0; IBM Corp., Armonk, NY, USA). Comparisons between groups were made by the Kruskal–Wallis test. Bonferroni's correction was applied to the post hoc analysis of the between-group comparisons to allow for the number of comparisons performed. If the variance analysis showed significant differences between groups, the Mann–Whitney *U* test was used for pairwise comparisons.

Results

Nasal histology

To confirm successful establishment of the model, we first checked the eosinophil infiltration in the nasal mucosa, the

indispensable finding in ECRS, using Sirius red stain. Mice in the control group showed no eosinophil infiltration at all study time points. However, considerably greater numbers of infiltrating eosinophils were observed as of 8 weeks in the ECRS group, which then increased, reaching the maximum level at 16 weeks (Fig. 2a, b). In addition, the eosinophil aggregates were detected in the ECRS group from 12 weeks (Fig. 2c). The eosinophils were distributed throughout the entire area of the nose, and were particularly more abundant along the nasal septum, followed by the superior and inferior maxillary turbinate (Supplementary Fig. 1).

We next used PAS stain to examine the extent of goblet cell hyperplasia. In the ECRS group, the goblet cell population increased gradually, with a significant difference detected from that of the control group at 12 and 16 weeks (Fig. 3a, b). The goblet cells were more frequently detected in the nasal septum than in the inferior maxillary turbinate at all study time points. Goblet cells were also noted in the superior maxillary turbinate of the ECRS group at 12 and 16 weeks (Supplementary Fig. 2).

Moreover, Masson's trichrome stain showed that the maximal epithelial and subepithelial thickness increased in the ECRS group as of 8 weeks, and then remained stable until 16 weeks. Mice in the ECRS group also showed higher collagen accumulation in the subepithelial layer as of 8 weeks compared to that of the controls (Fig. 4a, b).

As expected, epithelial disruption and polyp-like lesions, other typical findings of ECRS, were observed only in the ECRS group as of 8 weeks and 12 weeks, respectively. Epithelial disruption was detected in the nasal septum and inferior maxillary turbinate (Supplementary Fig. 3a), and polyp-like lesions were found in the inferior maxillary turbinate and the lateral wall of the nasal cavity (Supplementary Fig. 3b).

Immunological parameters of the nasal lavage fluid

The levels of major cytokines and chemokines of the nasal lavage fluid were evaluated to inspect the immunopathologic features of the ECRS model. IL-4 levels were elevated in the mice

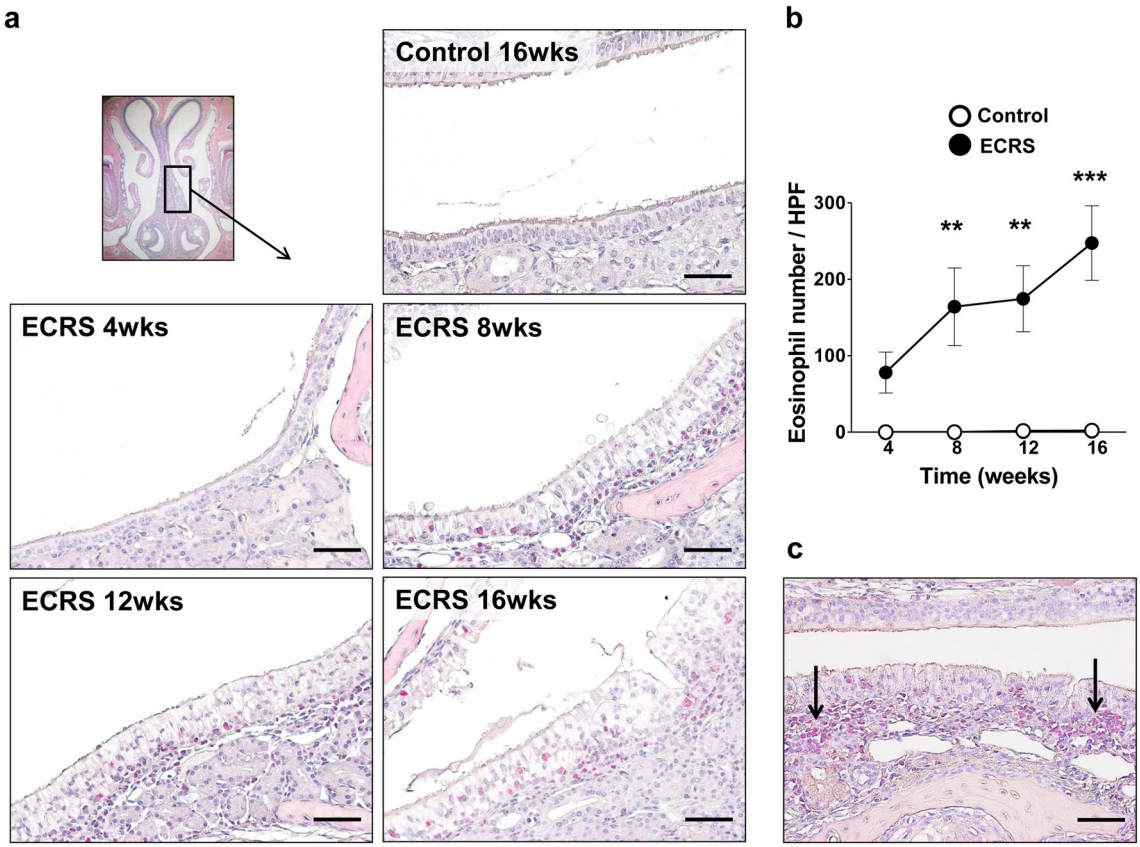

Fig. 2 Time-course analysis of eosinophil infiltration between groups. **a** Representative photomicrographs of Sirius red stain (original magnification: ×400, magnified image of the ×40 figure in the left upper quadrant) showing eosinophil infiltration in the ECRS groups at 8, 12, and 16 weeks (scale bar: 50 μm). **b** Numbers of infiltrated eosinophils were counted in nine different high-power fields. **c** Representative photomicrographs of eosinophil aggregates (arrow) observed in the ECRS group from 12 weeks (original magnification: ×400, scale bar: 50 μm). Data are expressed as mean ± SD. $^{**}p<0.01$, $^{***}p<0.001$ between control and ECRS groups. *ECRS* eosinophilic chronic rhinosinusitis, *wks* weeks, *HPF* high-power field

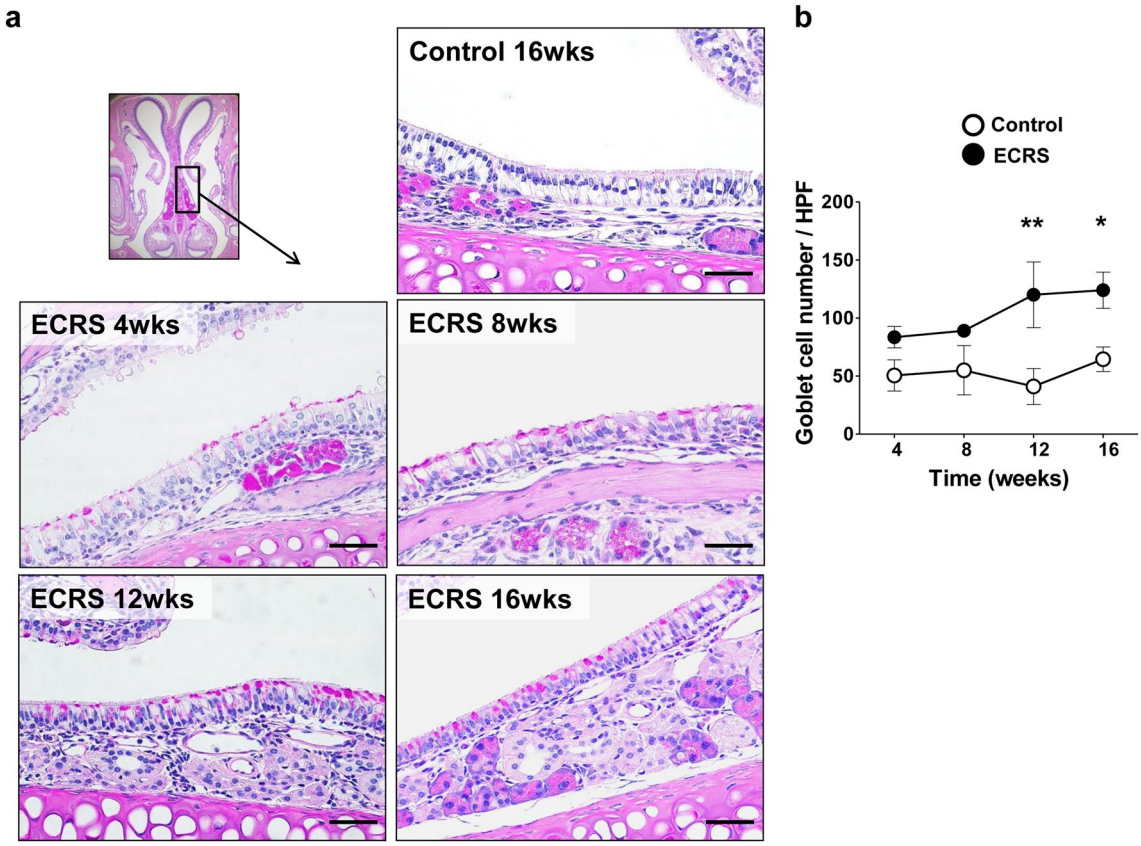

Fig. 3 Time-course analysis of goblet cell hyperplasia between groups. **a** Representative photomicrographs of periodic acid–Schiff stain (original magnification: ×400, magnified image of the ×40 figure in the left upper quadrant) showing goblet cell hyperplasia in the ECRS group (scale bar: 50 μm). **b** The numbers of goblet cells were counted in nine different high-power fields. Data are expressed as mean ± SD. $*p<0.05$, $**p<0.01$ between the control and ECRS groups. *ECRS* eosinophilic chronic rhinosinusitis, *wks* weeks, *HPF* high-power field

of the ECRS group from 8 weeks compared to those of controls, although the difference was not statistically significant. The levels of IL-6 and TNF-α in the ECRS group were similar to or higher than those in the controls, with significantly higher TNF-α levels detected at 8 weeks. Most strikingly, the levels of IL-5, which is involved in the activation and survival of eosinophils, and eotaxin (CCL11), a key chemokine in eosinophil maturation and recruitment, were significantly elevated in the ECRS group at 12 and 16 weeks compared to those of controls. However, IFN-r and IL-17 were not detected (Fig. 5a). In addition, the total number of immune cells in the nasal lavage fluid was increased in the ECRS group at all time points compared to that of controls, with significant elevation detected at 12 and 16 weeks (Fig. 5b).

Immune cell infiltration of the blood and spleen

To characterize the systemic immune response induced by multiple airborne allergens, we analyzed the differential cell counts in the blood and spleen as well as the immune cell population in the spleen. Eosinophils and neutrophils were identified by flow cytometry (Supplementary Fig. 4). Blood eosinophils were significantly increased in the ECRS group from 12 weeks compared to those of controls. The level of blood neutrophils was also elevated in the ECRS group at all time points, although the differences were not statistically significant (Fig. 5c).

Finally, flow cytometric analysis of the spleen at 16 weeks (Supplementary Fig. 5a) showed an approximately fourfold increase in eosinophils in the ECRS group compared to controls. The populations of T cells, B cells, dendritic cells, neutrophils, and macrophages were also slightly increased in the ECRS group but the difference from the control group was not statistically significant (Supplementary Fig. 5b).

Discussion

In the present study, we successfully developed an ECRS murine model for prolonged exposure to pathophysiologically relevant multiple airborne allergens for at least

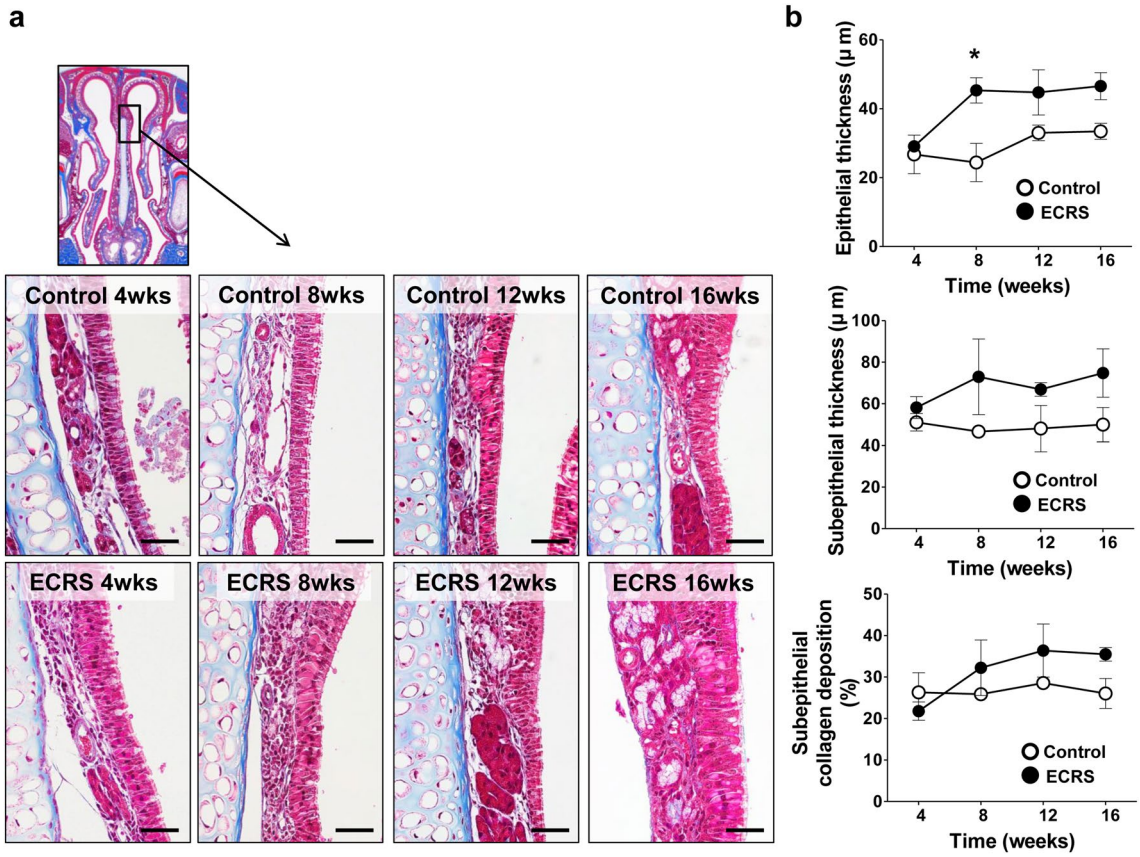

Fig. 4 Time-course analysis of maximal epithelial thickness, maximal subepithelial thickness, and subepithelial collagen deposition between groups. **a** Representative photomicrographs of Masson's trichrome stain (original magnification: ×400, magnified image of the ×40 figure in the left upper quadrant) obtained at the transition zone between the olfactory and respiratory epithelium (scale bar: 50 μm). **b** Changes in maximal epithelial and subepithelial thickness, and percentage of collagen deposition. Data are expressed as mean ± SD. *$p < 0.05$ between the control and ECRS groups. *ECRS* eosinophilic chronic rhinosinusitis, *wks* weeks

12 weeks, which corresponds to the definition of human ECRS. Indeed, this model showed typical histological changes of human ECRS such as eosinophil infiltration, goblet cell hyperplasia, epithelial thickening, and polypoid lesions.

To achieve natural environmental exposure, four different airborne allergens (HDM, *Aspergillus*, *Alternaria*, and *S. aureus*) that are associated with human ECRS were combined and administered to the mice through the nasal cavity. They synergistically generated robust eosinophilic inflammation within 12 weeks. HDM is strongly involved in the pathogenesis of airway inflammation, and a large proportion of patients with respiratory allergic diseases are sensitized to HDM [18]. A previously established ECRS murine model using intradermal immunization of HDM followed by intranasal administration for 12 consecutive weeks showed infiltration of eosinophils and mast cells [25]. CRS is associated with recurrent infections and colonization of certain organisms such as fungal species and *S. aureus* [9]. *Aspergillus* has been used for the development of an ECRS murine model by intraperitoneal and intranasal administration [17], or intranasal sensitization combined with OVA [14, 16]. Recently, intranasal sensitization of *Alternaria* combined with HDM and S. *aureus* for 16 weeks was used to generate a murine model of ECRS [30]. In addition, staphylococcal enterotoxin B, one of the *S. aureus* exotoxins, was used to develop an ECRS murine model combined with OVA [13, 31].

All four airborne allergens used for establishment of the new ECRS model in the present study have serine or cysteine protease activities that can cause disruption of the epithelial barrier, consequently allowing for the passage of allergens, and stimulating various immune cells through IgE-independent mechanisms. These processes induce pro-inflammatory and pro-allergy responses, eventually leading to a Th2 immune response [32–37]. Thus, the protease activity of airborne allergens is likely the main mechanism of the development of airway remodeling observed in the present study.

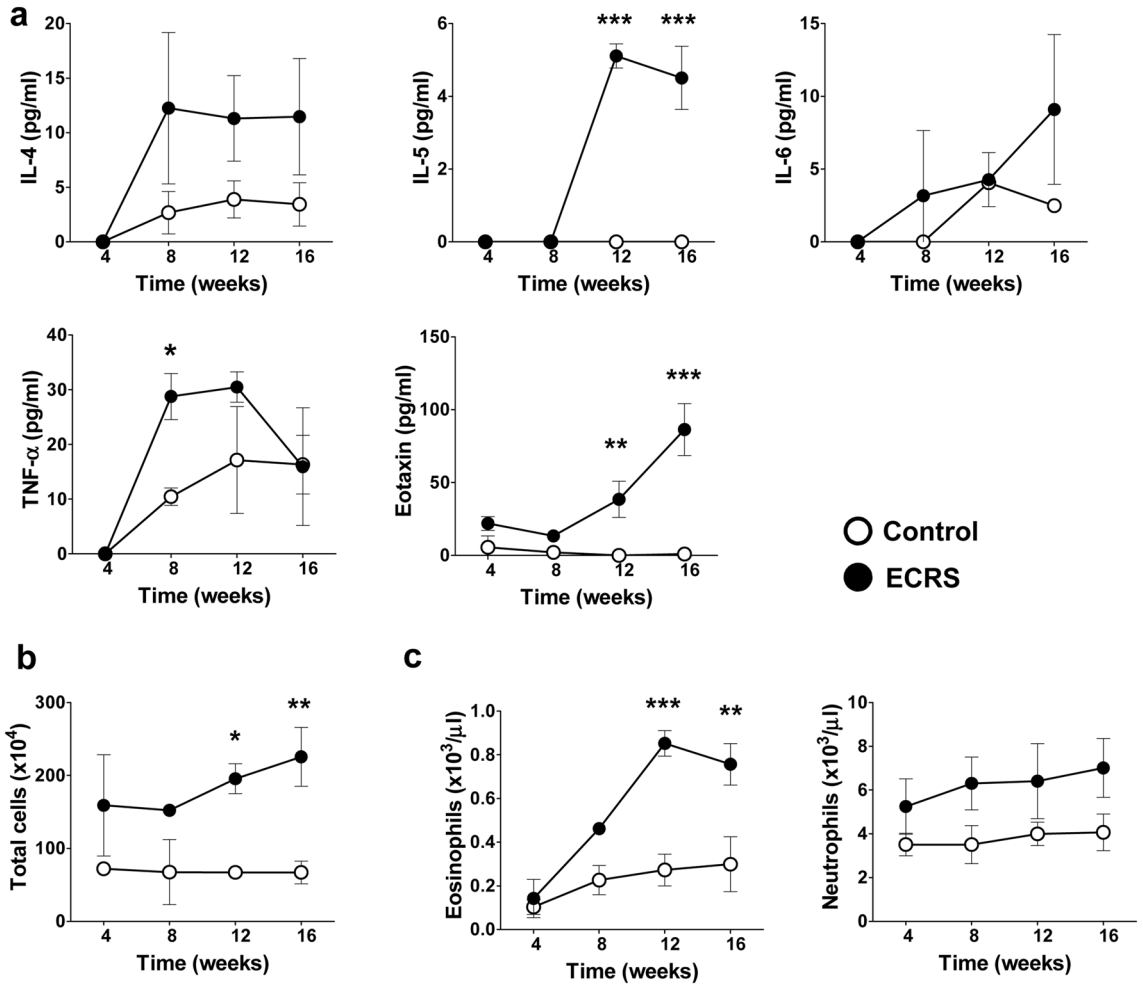

Fig. 5 Cytokine levels and cell counts from the nasal lavage fluid and blood. **a** The levels of T-helper 2 cytokines (IL-4 and IL-5), eotaxin (CCL11), pro-inflammatory cytokines (IL-6 and TNF-α), and IFN-r and IL-17 (not detected) from the nasal lavage fluid in the control and ECRS groups. **b** Total cell counts of the nasal lavage fluid. **c** Blood neutrophil and eosinophil counts. Data are expressed as mean ± SD. $*p<0.05$, $**p<0.01$, $***p<0.001$ between the control and ECRS groups

Although we could not detect all of the histopathological findings found in human nasal tissue [27, 38, 39], major findings were detected in the ECRS murine model in the present study. We found significant increases in eosinophil infiltration, epithelial thickening, and disruption in the ECRS group compared to those of controls as of 8 weeks, whereas the goblet cell hyperplasia, polyp-like lesions, tissue eosinophil aggregates, and blood eosinophils, as well as the levels of IL-5 and eotaxin in the nasal lavage fluid were considerably elevated as of 12 weeks. This latter time point has particular clinical relevance because peripheral blood eosinophilia is closely related to tissue eosinophilia and considered to be a predictor for ECRS [38, 40, 41], tissue eosinophil aggregates are driving factor for increased prednisone requirements after surgery [27], IL-5 is a key cytokine dictating nasal polyp and comorbid asthma [42], and eotaxin is a crucial chemotactic factor for eosinophils in ECRS [43]. In addition, instillation of inhalant allergens for 16 weeks exacerbated the tissue eosinophil infiltration, and eotaxin increase in the nasal lavage fluid. Tissue eosinophilia is strongly associated with disease severity and poorer quality-of-life improvements after treatment [27, 39]. Thus, our results demonstrate that exposure of airborne allergens for 12 weeks or more is sufficient for inducing ECRS in a murine model, coinciding with the duration in the current definition of human ECRS. This finding is also in line with earlier observations that exposure to allergens for 12 weeks [12, 14] or more [30, 31] was sufficient for the generation of ECRS in mice. Although some ECRS models were established during a period of less than 12 weeks, these models could not accurately reflect chronic airway remodeling, an important feature of ECRS, such as polyp-like lesions [16, 44].

Interestingly, the eosinophil population of the spleen of the ECRS group was significantly elevated at 16 weeks compared to that of the control, even though we did not sensitize the mice to the allergens by a systemic route. This may reflect the characteristics of ECRS that are commonly associated with systemic diseases such as asthma and aspirin-exacerbated respiratory disease [5, 6], which could be verified by examination of the systemic levels of total and allergen-specific IgE.

Moreover, this is the first study to analyze the number of eosinophils and goblet cells in various areas of the nasal cavity. Both eosinophils and goblet cells were more frequently detected in the nasal septum than in the maxillary turbinate. These results are in contrast to a previous study of a bacterial sinusitis murine model in which the goblet cells were distributed in the nasal septum as well as in the superior maxillary turbinate without a significant difference [45]. This discrepancy might be related to the different methods and durations for generation of sinusitis in the two models, as this previous model was established using Merocel nasal packing and inoculation of *Bacteroides fragilis* for 4 weeks. However, more investigation is warranted to define the mechanism leading to the abundant infiltration of inflammatory cells in the nasal septum observed in the present study.

There are some limitations to the present study. First, previous ECRS models showed a conflicting T cell immune response, including a Th2-specific feature [14] or mixed Th1/Th2/Th17 feature [13]. This discrepancy might indicate heterogeneous characteristics of ECRS; although the Th2 type response is dominant in most populations, a mixed Th2/Th17 type response has been reported to be common in Asians [46–48]. Our ECRS model might reflect the Th2 response given that the levels of IL-4, IL-5, and eotaxin in the nasal lavage fluid were elevated, while IFN-γ and IL-17 were undetectable. However, the specific T cell immunity mechanism remains unclear, which could be resolved by additional studies of their mRNA levels in the nasal mucosa or supplemental histopathology such as immunohistochemistry. Second, we could not find Charcot–Leyden crystals [17, 39], which are typically present in allergic fungal sinusitis, despite administration of fungal allergens. Therefore, further studies are needed to investigate the presence of crystals from the inflammatory eosinophilic exudate in mice. Third, this study is descriptive and does not clarify the mechanism in depth, because we focused on the generation of ECRS model in this study. We are planning further research on the fundamental mechanism of development of ECRS by multiple allergens, such as using mice deficient in IL-5 or eotaxin, or dose-dependent study of allergens. Fourth, the sample size in each experimental group was relatively small. However, other studies of sinusitis murine model also used fewer than ten mice per group. Finally, the mixture of four allergens can be complicated in the experimental method.

Despite these limitations, this comprehensive study on a newly developed ECRS model provides significant advantages for research compared to available models since it is more pathophysiologically relevant and includes common inhalant allergens that cause ECRS in humans. Accordingly, this model might better reflect the natural condition in which human airways are consistently exposed to several environmental factors simultaneously, including multiple airborne allergens. We also evaluated the influence of the exposure duration of multiple allergens by consecutive time-course analysis and the detailed histology of ECRS in various areas of the nasal cavity. CRS is a heterogeneous inflammatory disease, thus endotyping CRS is crucial for the personalized treatment of individuals [41, 48]. Eosinophils are associated with higher recurrence rate and development of systemic diseases. Therefore, this study can offer an excellent experimental platform for future studies of CRS pathophysiology based on endotyping by establishment of appropriate ECRS murine models.

Conclusions

We successfully developed a new murine model of ECRS using multiple pathophysiologically relevant airborne allergens. Prolonged exposure to airborne allergens for 12 weeks or more induced eosinophil infiltration and remodeling of the sinonasal epithelium. We expect that this multiple airborne allergen-induced ECRS murine model will contribute to gaining a deeper understanding of the pathophysiology of the heterogeneous nature of ECRS as well as help in investigating novel molecular targets for anti-inflammatory therapies for ECRS.

Funding This study was supported by the Bio & Medical Technology Development Program of the National Research Foundation of Korea (NRF), funded by the Ministry of Science, ICT & Future Planning (MSIP) (2016M3A9D5A01952414), and the NRF grant funded by the Korean Government (MSIP) (2016R1A5A2008630). This research was also supported by the NRF Grant funded by the Korean Government (Ministry of Science and ICT) (NRF-2018R1C1B6007431).

Compliance with ethical standards

Conflict of interest The authors have no conflicts of interest to disclose.

Ethical approval All applicable international, national, and/or institutional guidelines for the care and use of animals were followed. All procedures performed in this study involving animals were approved by the Ethics Committee and Institutional Animal Care and Use Committee of Yonsei University Health System (2017-0094), and the study was

conducted according to international guidelines (ARRIVE) on animal experiments.

References

1. Fokkens WJ, Lund VJ, Mullol J, Bachert C, Alobid I, Baroody F, Cohen N, Cervin A, Douglas R, Gevaert P, Georgalas C, Goossens H, Harvey R, Hellings P, Hopkins C, Jones N, Joos G, Kalogjera L, Kern B, Kowalski M, Price D, Riechelmann H, Schlosser R, Senior B, Thomas M, Toskala E, Voegels R, de Wang Y, Wormald PJ (2012) EPOS 2012: European position paper on rhinosinusitis and nasal polyps 2012. A summary for otorhinolaryngologists. Rhinology 50(1):1–12. https://doi.org/10.4193/Rhino50E2
2. Halawi AM, Smith SS, Chandra RK (2013) Chronic rhinosinusitis: epidemiology and cost. Allergy Asthma Proc 34(4):328–334. https://doi.org/10.2500/aap.2013.34.3675
3. Wang X, Zhang N, Bo M, Holtappels G, Zheng M, Lou H, Wang H, Zhang L, Bachert C (2016) Diversity of TH cytokine profiles in patients with chronic rhinosinusitis: a multicenter study in Europe, Asia, and Oceania. J Allergy Clin Immunol 138(5):1344–1353. https://doi.org/10.1016/j.jaci.2016.05.041
4. London NR Jr, Tharakan A, Ramanathan M Jr (2016) The role of innate immunity and aeroallergens in chronic rhinosinusitis. Adv Otorhinolaryngol 79:69–77. https://doi.org/10.1159/000445132
5. Jarvis D, Newson R, Lotvall J, Hastan D, Tomassen P, Keil T, Gjomarkaj M, Forsberg B, Gunnbjornsdottir M, Minov J, Brozek G, Dahlen SE, Toskala E, Kowalski ML, Olze H, Howarth P, Kramer U, Baelum J, Loureiro C, Kasper L, Bousquet PJ, Bousquet J, Bachert C, Fokkens W, Burney P (2012) Asthma in adults and its association with chronic rhinosinusitis: the GA2LEN survey in Europe. Allergy 67(1):91–98. https://doi.org/10.1111/j.1398-9995.2011.02709.x
6. Ishitoya J, Sakuma Y, Tsukuda M (2010) Eosinophilic chronic rhinosinusitis in Japan. Allergol Int 59(3):239–245. https://doi.org/10.2332/allergolint.10-RAI-0231
7. Zhang N, Van Zele T, Perez-Novo C, Van Bruaene N, Holtappels G, DeRuyck N, Van Cauwenberge P, Bachert C (2008) Different types of T-effector cells orchestrate mucosal inflammation in chronic sinus disease. J Allergy Clin Immunol 122(5):961–968. https://doi.org/10.1016/j.jaci.2008.07.008
8. Kato A (2015) Immunopathology of chronic rhinosinusitis. Allergol Int 64(2):121–130. https://doi.org/10.1016/j.alit.2014.12.006
9. Schleimer RP (2017) Immunopathogenesis of chronic rhinosinusitis and nasal polyposis. Annu Rev Pathol 12:331–357. https://doi.org/10.1146/annurev-pathol-052016-100401
10. Kim SJ, Lee KH, Kim SW, Cho JS, Park YK, Shin SY (2013) Changes in histological features of nasal polyps in a Korean population over a 17-year period. Otolaryngol Head Neck Surg 149(3):431–437. https://doi.org/10.1177/0194599813495363
11. Katotomichelakis M, Tantilipikorn P, Holtappels G, De Ruyck N, Feng L, Van Zele T, Muangsomboon S, Jareonchasri P, Bunnag C, Danielides V, Cuvelier CA, Hellings PW, Bachert C, Zhang N (2013) Inflammatory patterns in upper airway disease in the same geographical area may change over time. Am J Rhinol Allergy 27(5):354–360. https://doi.org/10.2500/ajra.2013.27.3922
12. Wang H, Lu X, Cao PP, Chu Y, Long XB, Zhang XH, You XJ, Cui YH, Liu Z (2008) Histological and immunological observations of bacterial and allergic chronic rhinosinusitis in the mouse. Am J Rhinol 22(4):343–348. https://doi.org/10.2500/ajr.2008.22.3184
13. Kim DW, Khalmuratova R, Hur DG, Jeon SY, Kim SW, Shin HW, Lee CH, Rhee CS (2011) *Staphylococcus aureus* enterotoxin B contributes to induction of nasal polypoid lesions in an allergic rhinosinusitis murine model. Am J Rhinol Allergy 25(6):e255–e261. https://doi.org/10.2500/ajra.2011.25.3727
14. Kim HC, Lim JY, Kim S, Kim JH, Jang YJ (2017) Development of a mouse model of eosinophilic chronic rhinosinusitis with nasal polyp by nasal instillation of an *Aspergillus* protease and ovalbumin. Eur Arch Otorhinolaryngol 274(11):3899–3906. https://doi.org/10.1007/s00405-017-4717-2
15. Nials AT, Uddin S (2008) Mouse models of allergic asthma: acute and chronic allergen challenge. Dis Model Mech 1(4–5):213–220. https://doi.org/10.1242/dmm.000323
16. Kim JH, Yi JS, Gong CH, Jang YJ (2014) Development of *Aspergillus* protease with ovalbumin-induced allergic chronic rhinosinusitis model in the mouse. Am J Rhinol Allergy 28(6):465–470. https://doi.org/10.2500/ajra.2014.28.4100
17. Lindsay R, Slaughter T, Britton-Webb J, Mog SR, Conran R, Tadros M, Earl N, Fox D, Roberts J, Bolger WE (2006) Development of a murine model of chronic rhinosinusitis. Otolaryngol Head Neck Surg 134(5):724–730. https://doi.org/10.1016/j.otohns.2005.11.048 **(discussion 731–732)**
18. Park SC, Hwang CS, Chung HJ, Purev M, Al Sharhan SS, Cho HJ, Yoon JH, Kim CH (2019) Geographic and demographic variations of inhalant allergen sensitization in Koreans and non-Koreans. Allergol Int 68(1):68–76. https://doi.org/10.1016/j.alit.2018.07.005
19. Lam K, Schleimer R, Kern RC (2015) The etiology and pathogenesis of chronic rhinosinusitis: a review of current hypotheses. Curr Allergy Asthma Rep 15(7):41. https://doi.org/10.1007/s11882-015-0540-2
20. Black PN, Udy AA, Brodie SM (2000) Sensitivity to fungal allergens is a risk factor for life-threatening asthma. Allergy 55(5):501–504
21. deShazo RD, Swain RE (1995) Diagnostic criteria for allergic fungal sinusitis. J Allergy Clin Immunol 96(1):24–35
22. Shin SH, Ponikau JU, Sherris DA, Congdon D, Frigas E, Homburger HA, Swanson MC, Gleich GJ, Kita H (2004) Chronic rhinosinusitis: an enhanced immune response to ubiquitous airborne fungi. J Allergy Clin Immunol 114(6):1369–1375. https://doi.org/10.1016/j.jaci.2004.08.012
23. Bartemes KR, Iijima K, Kobayashi T, Kephart GM, McKenzie AN, Kita H (2012) IL-33-responsive lineage-CD25+ CD44(hi) lymphoid cells mediate innate type 2 immunity and allergic inflammation in the lungs. J Immunol 188(3):1503–1513. https://doi.org/10.4049/jimmunol.1102832
24. Sachse F, Becker K, von Eiff C, Metze D, Rudack C (2010) *Staphylococcus aureus* invades the epithelium in nasal polyposis and induces IL-6 in nasal epithelial cells in vitro. Allergy 65(11):1430–1437. https://doi.org/10.1111/j.1398-9995.2010.02381.x
25. Khalmuratova R, Lee M, Kim DW, Park JW, Shin HW (2016) Induction of nasal polyps using house dust mite and Staphylococcal enterotoxin B in C57BL/6 mice. Allergol Immunopathol (Madr) 44(1):66–75. https://doi.org/10.1016/j.aller.2015.04.004
26. Jacob A, Chole RA (2006) Survey anatomy of the paranasal sinuses in the normal mouse. Laryngoscope 116(4):558–563. https://doi.org/10.1097/01.MLG.0000202085.23454.2F
27. Tajudeen BA, Ganti A, Kuhar HN, Mahdavinia M, Heilingoetter A, Gattuso P, Ghai R, Batra PS (2019) The presence of eosinophil aggregates correlates with increased postoperative prednisone requirement. Laryngoscope 129(4):794–799. https://doi.org/10.1002/lary.27693
28. Van Bruaene N, Derycke L, Perez-Novo CA, Gevaert P, Holtappels G, De Ruyck N, Cuvelier C, Van Cauwenberge P, Bachert C (2009) TGF-beta signaling and collagen deposition in chronic rhinosinusitis. J Allergy Clin Immunol 124(2):253–259. https://doi.org/10.1016/j.jaci.2009.04.013 **(259 e251–252)**
29. Cho SH, Oh SY, Zhu Z, Lee J, Lane AP (2012) Spontaneous eosinophilic nasal inflammation in a genetically-mutant mouse:

comparative study with an allergic inflammation model. PLoS One 7(4):e35114. https://doi.org/10.1371/journal.pone.0035114
30. Kouzaki H, Matsumoto K, Kikuoka H, Kato T, Tojima I, Shimizu S, Kita H, Shimizu T (2017) endogenous protease inhibitors in airway epithelial cells contribute to eosinophilic chronic rhinosinusitis. Am J Respir Crit Care Med 195(6):737–747. https://doi.org/10.1164/rccm.201603-0529OC
31. Kim DW, Eun KM, Jin HR, Cho SH, Kim DK (2016) Prolonged allergen exposure is associated with increased thymic stromal lymphopoietin expression and Th2-skewing in mouse models of chronic rhinosinusitis. Laryngoscope 126(8):E265–E272. https://doi.org/10.1002/lary.26004
32. Takai T, Kato T, Sakata Y, Yasueda H, Izuhara K, Okumura K, Ogawa H (2005) Recombinant Der p 1 and Der f 1 exhibit cysteine protease activity but no serine protease activity. Biochem Biophys Res Commun 328(4):944–952
33. Kauffman HF, Tomee JF, van de Riet MA, Timmerman AJ, Borger P (2000) Protease-dependent activation of epithelial cells by fungal allergens leads to morphologic changes and cytokine production. J Allergy Clin Immunol 105(6 Pt 1):1185–1193
34. Snelgrove RJ, Gregory LG, Peiro T, Akthar S, Campbell GA, Walker SA, Lloyd CM (2014) *Alternaria*-derived serine protease activity drives IL-33-mediated asthma exacerbations. J Allergy Clin Immunol 134(3):583–592e586. https://doi.org/10.1016/j.jaci.2014.02.002
35. Dubin G (2002) Extracellular proteases of *Staphylococcus* spp. Biol Chem 383(7–8):1075–1086
36. Takai T, Ikeda S (2011) Barrier dysfunction caused by environmental proteases in the pathogenesis of allergic diseases. Allergol Int 60(1):25–35. https://doi.org/10.2332/allergolint.10-RAI-0273
37. Balenga NA, Klichinsky M, Xie Z, Chan EC, Zhao M, Jude J, Laviolette M, Panettieri RA Jr, Druey KM (2015) A fungal protease allergen provokes airway hyper-responsiveness in asthma. Nat Commun 6:6763. https://doi.org/10.1038/ncomms7763
38. Brescia G, Alessandrini L, Zanotti C, Parrino D, Tealdo G, Torsello M, Zybine V, Giacomelli L, Barion U, Marioni G (2019) Histopathological and hematological changes in recurrent nasal polyposis. Int Forum Allergy Rhinol. https://doi.org/10.1002/alr.22314
39. Snidvongs K, Lam M, Sacks R, Earls P, Kalish L, Phillips PS, Pratt E, Harvey RJ (2012) Structured histopathology profiling of chronic rhinosinusitis in routine practice. Int Forum Allergy Rhinol 2(5):376–385. https://doi.org/10.1002/alr.21032
40. Tokunaga T, Sakashita M, Haruna T, Asaka D, Takeno S, Ikeda H, Nakayama T, Seki N, Ito S, Murata J, Sakuma Y, Yoshida N, Terada T, Morikura I, Sakaida H, Kondo K, Teraguchi K, Okano M, Otori N, Yoshikawa M, Hirakawa K, Haruna S, Himi T, Ikeda K, Ishitoya J, Iino Y, Kawata R, Kawauchi H, Kobayashi M, Yamasoba T, Miwa T, Urashima M, Tamari M, Noguchi E, Ninomiya T, Imoto Y, Morikawa T, Tomita K, Takabayashi T, Fujieda S (2015) Novel scoring system and algorithm for classifying chronic rhinosinusitis: the JESREC Study. Allergy 70(8):995–1003. https://doi.org/10.1111/all.12644
41. Brescia G, Sfriso P, Marioni G (2019) Role of blood inflammatory cells in chronic rhinosinusitis with nasal polyps. Acta Otolaryngol 139(1):48–51. https://doi.org/10.1080/00016489.2018.1538567
42. Tomassen P, Vandeplas G, Van Zele T, Cardell LO, Arebro J, Olze H, Forster-Ruhrmann U, Kowalski ML, Olszewska-Ziaber A, Holtappels G, De Ruyck N, Wang X, Van Drunen C, Mullol J, Hellings P, Hox V, Toskala E, Scadding G, Lund V, Zhang L, Fokkens W, Bachert C (2016) Inflammatory endotypes of chronic rhinosinusitis based on cluster analysis of biomarkers. J Allergy Clin Immunol 137(5):1449–1456e1444. https://doi.org/10.1016/j.jaci.2015.12.1324
43. Yao T, Kojima Y, Koyanagi A, Yokoi H, Saito T, Kawano K, Furukawa M, Kusunoki T, Ikeda K (2009) Eotaxin-1, -2, and -3 immunoreactivity and protein concentration in the nasal polyps of eosinophilic chronic rhinosinusitis patients. Laryngoscope 119(6):1053–1059. https://doi.org/10.1002/lary.20191
44. Tharakan A, Dobzanski A, London NR Jr, Khalil SM, Surya N, Lane AP, Ramanathan M Jr (2018) Characterization of a novel, papain-inducible murine model of eosinophilic rhinosinusitis. Int Forum Allergy Rhinol 8(4):513–521. https://doi.org/10.1002/alr.22072
45. Jacob A, Faddis BT, Chole RA (2001) Chronic bacterial rhinosinusitis: description of a mouse model. Arch Otolaryngol Head Neck Surg 127(6):657–664
46. Cao PP, Li HB, Wang BF, Wang SB, You XJ, Cui YH, Wang DY, Desrosiers M, Liu Z (2009) Distinct immunopathologic characteristics of various types of chronic rhinosinusitis in adult Chinese. J Allergy Clin Immunol 124(3):478–484. https://doi.org/10.1016/j.jaci.2009.05.017 **(484.e471–472)**
47. Saitoh T, Kusunoki T, Yao T, Kawano K, Kojima Y, Miyahara K, Onoda J, Yokoi H, Ikeda K (2010) Role of interleukin-17A in the eosinophil accumulation and mucosal remodeling in chronic rhinosinusitis with nasal polyps associated with asthma. Int Arch Allergy Immunol 151(1):8–16. https://doi.org/10.1159/000232566
48. Brescia G, Zanotti C, Parrino D, Barion U, Marioni G (2018) Nasal polyposis pathophysiology: endotype and phenotype open issues. Am J Otolaryngol 39(4):441–444. https://doi.org/10.1016/j.amjoto.2018.03.020

Publisher's Note Springer Nature remains neutral with regard to jurisdictional claims in published maps and institutional affiliations.

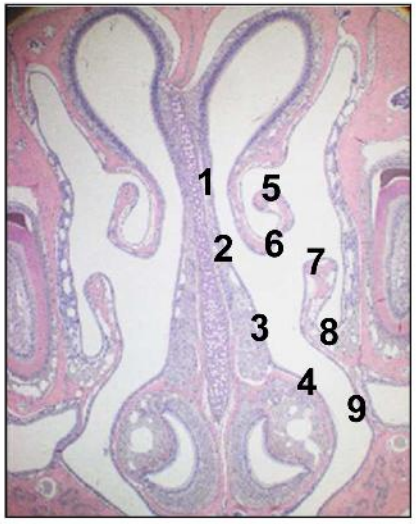
1
2
3
4
5
6
7
8
9

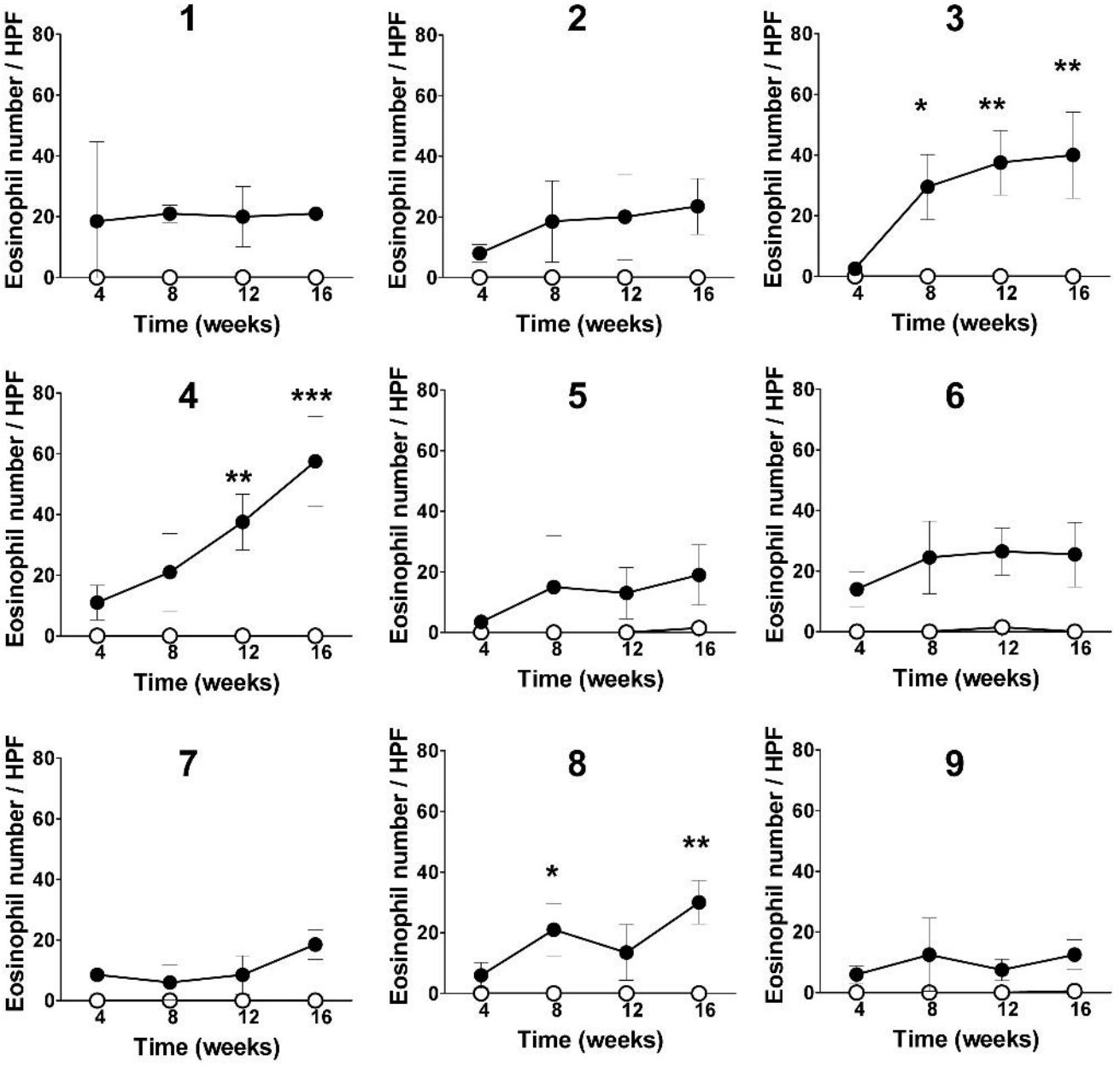
1
2
3
4
5
6
7
8
9
Eosinophil number / HPF
Time (weeks)
0
20
40
60
80
4
8
12
16
*
**
***
Control
ECRS

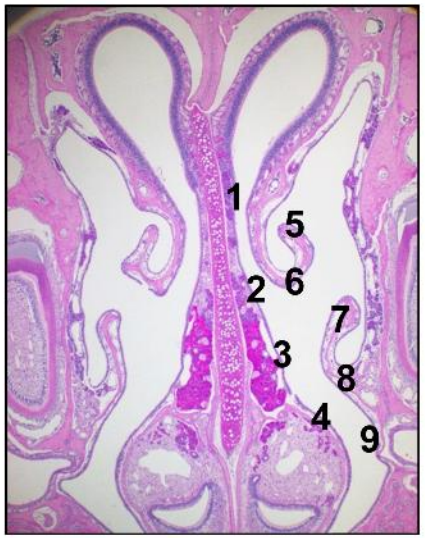
1
2
3
4
5
6
7
8
9

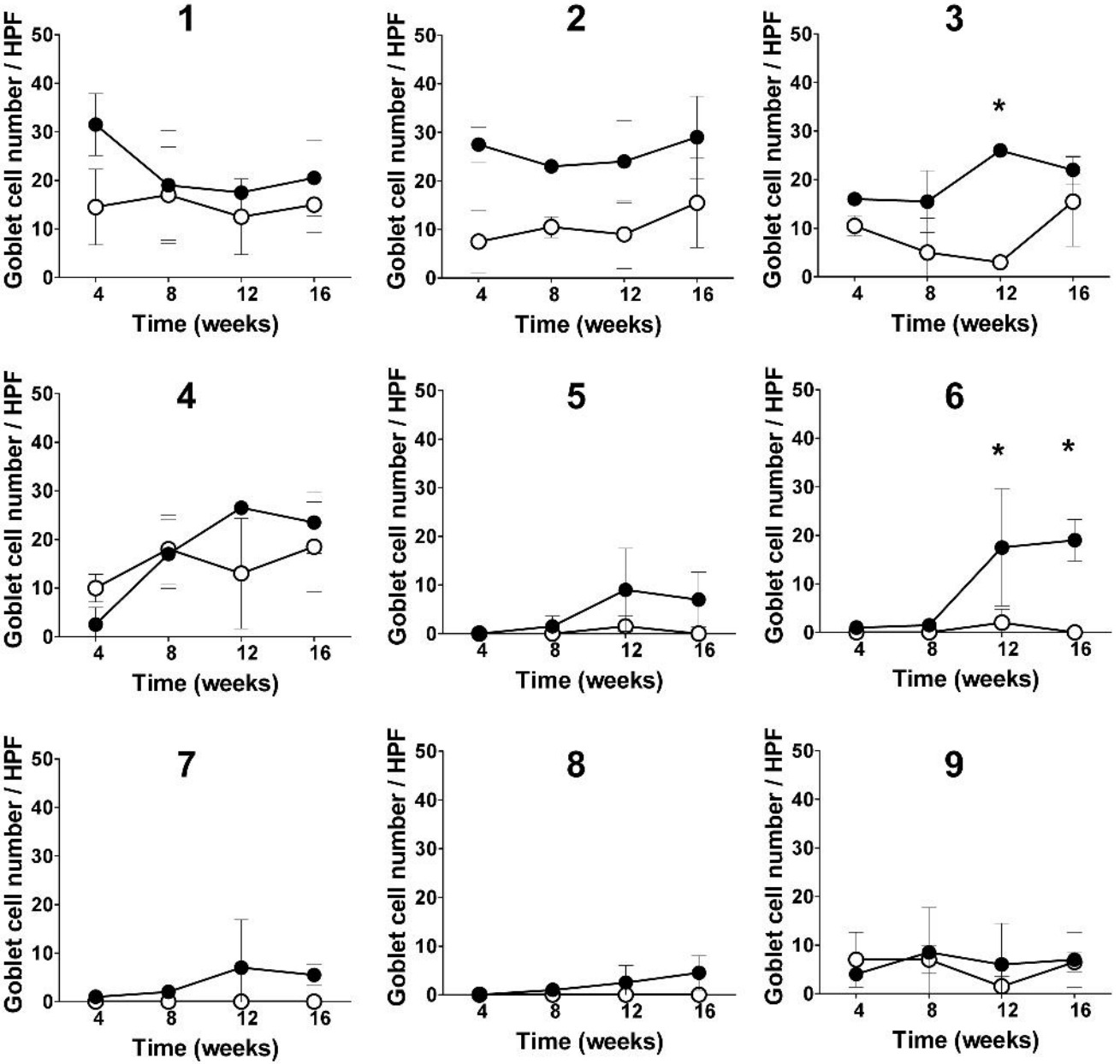
1
2
3
4
5
6
7
8
9
Goblet cell number / HPF
Time (weeks)
0
10
20
30
40
50
4
8
12
16
*
Control
ECRS

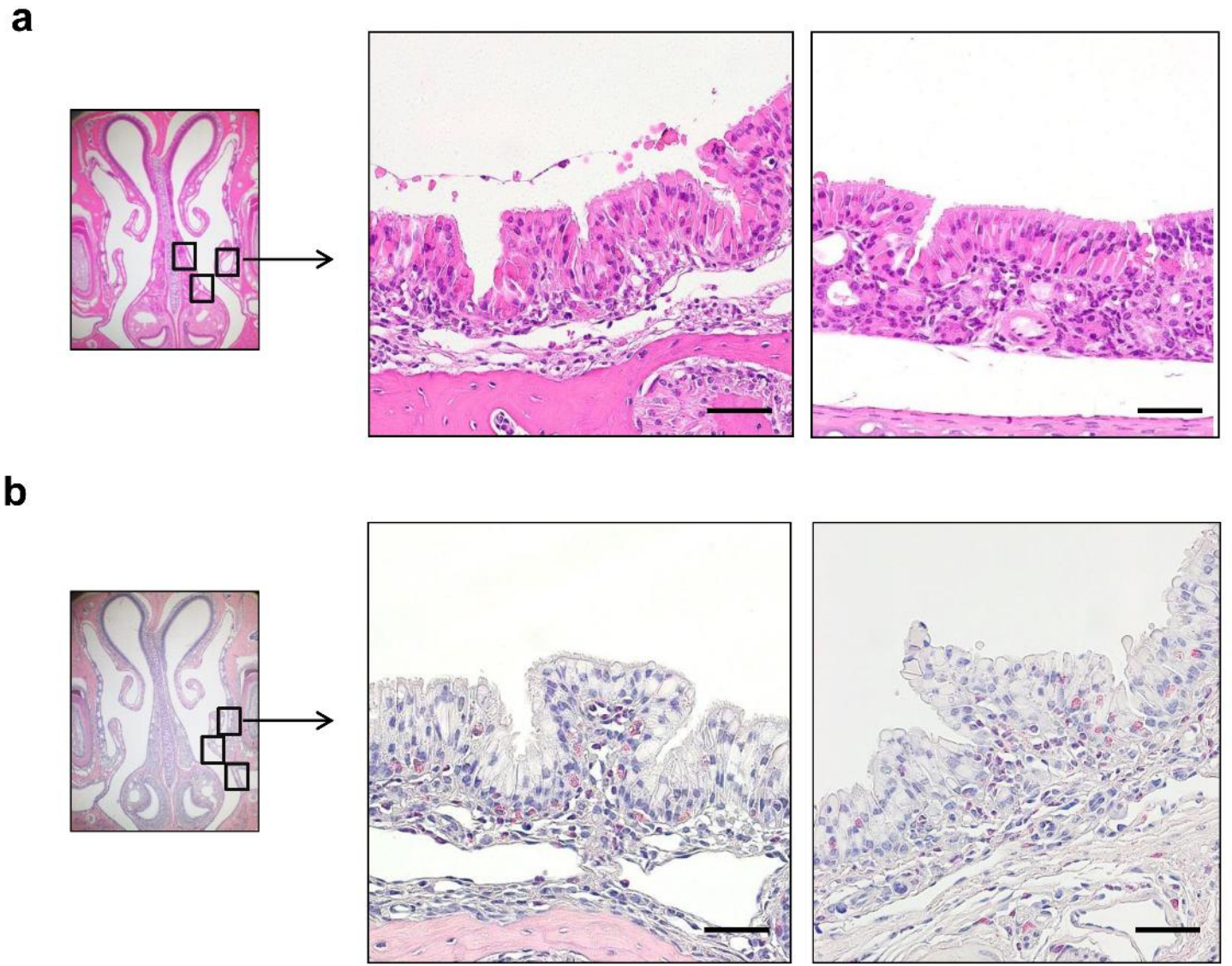
a
b

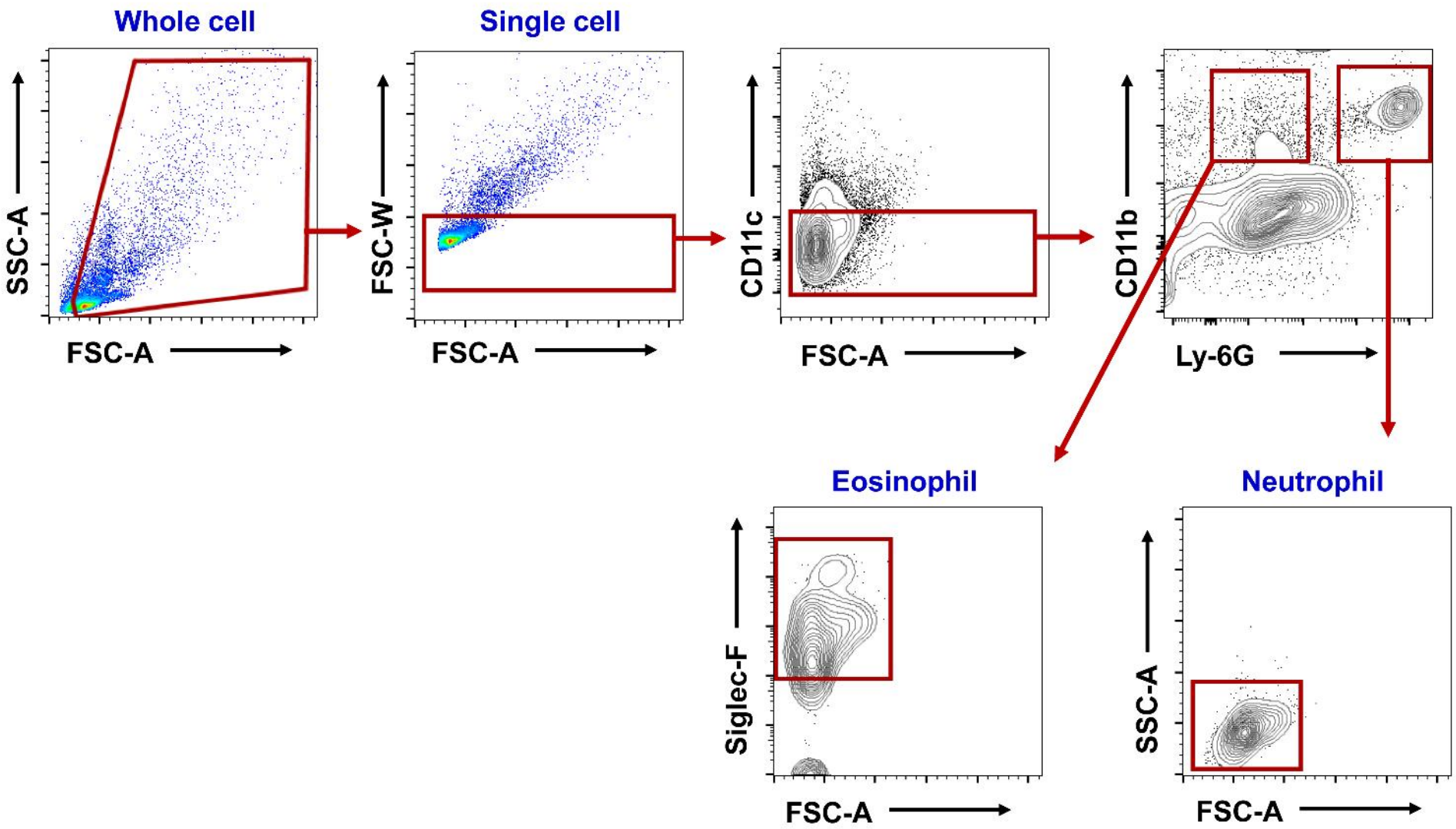
Whole cell
SSC-A
FSC-A
Single cell
FSC-W
FSC-A
CD11c
FSC-A
CD11b
Ly-6G
Eosinophil
Siglec-F
FSC-A
Neutrophil
SSC-A
FSC-A

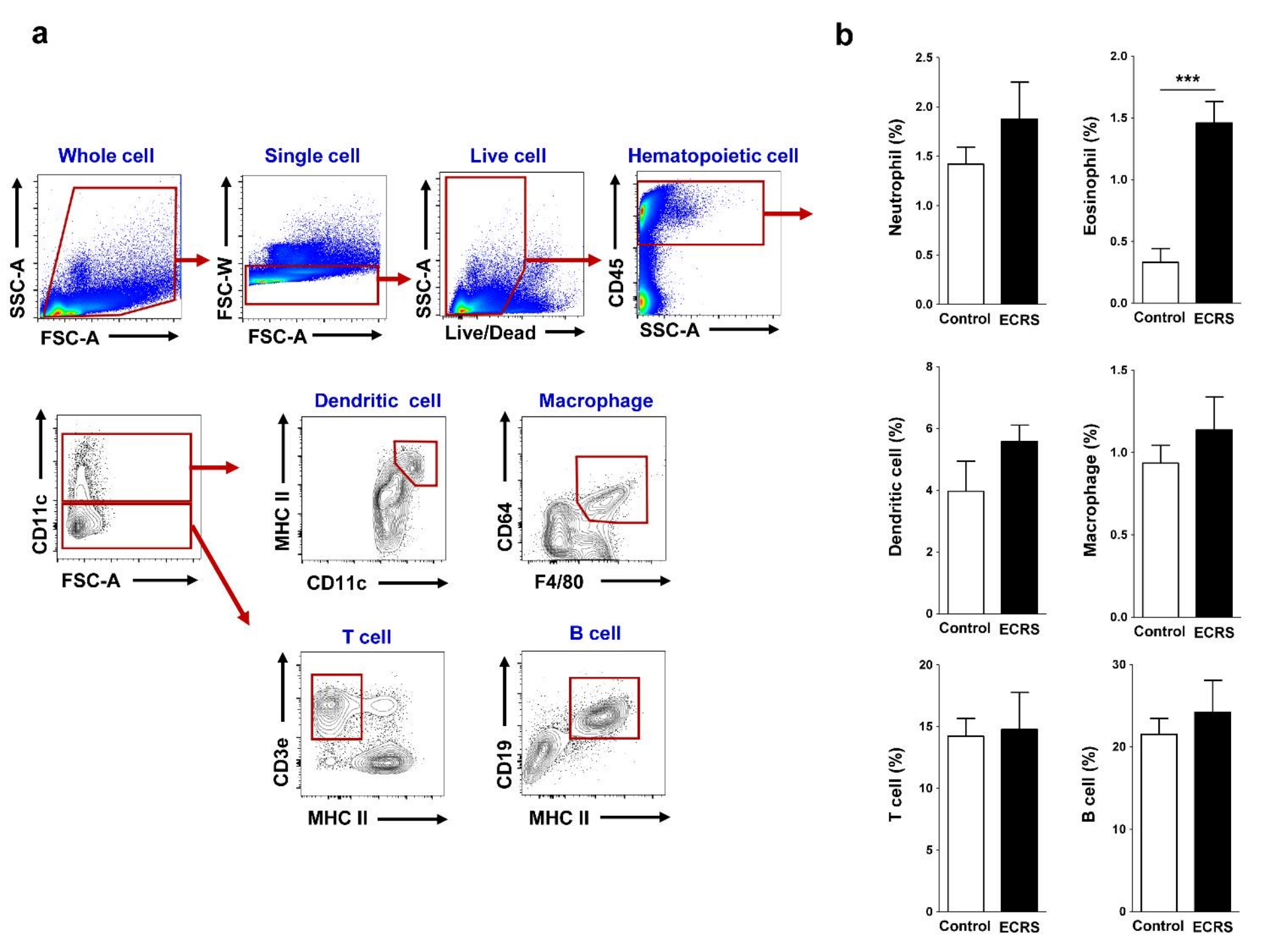
a
Whole cell
SSC-A
FSC-A
Single cell
FSC-W
FSC-A
Live cell
SSC-A
Live/Dead
Hematopoietic cell
CD45
SSC-A
CD11c
FSC-A
Dendritic cell
MHC II
CD11c
Macrophage
CD64
F4/80
T cell
CD3e
MHC II
B cell
CD19
MHC II
b
Neutrophil (%)
Control
ECRS
Eosinophil (%)
***
Control
ECRS
Dendritic cell (%)
Control
ECRS
Macrophage (%)
Control
ECRS
T cell (%)
Control
ECRS
B cell (%)
Control
ECRS