Allergo J Int
https://doi.org/10.1007/s40629-022-00209-6

"Adrenaline junkie": a case report of repeated use of epinephrine

Lorenzo Salvati · Chiara Allegrini · Benedetta Piccardi · Ivano Lombardo · Lorenzo Ciambellotti · Sonia Rizzello · Vanessa Palumbo · Federico Lavorini · Gianna Camiciottoli · Paola Parronchi

Received: 7 February 2022 / Accepted: 9 April 2022
© The Author(s) 2022

Keywords Drug-related side effects and adverse reactions · Safety · Efficacy · Severe asthma · Reversible cerebral vasoconstriction syndrome

Background

Epinephrine, the first-line treatment of anaphylaxis, is safe and effective when administered correctly [1–3]. Epinephrine acts as a non-selective agonist on α- and β-adrenergic receptors, causing vasoconstriction, increased peripheral vascular resistance, reduced mucosal oedema, increased heart rate and cardiac contractility, bronchodilation, and decreased mast cells' and basophils' degranulation [2]. Adverse events include cardiovascular, respiratory, neurologic, psychiatric, gastrointestinal, dermatologic and renal manifestations [3–5]. There is limited evidence on the safety of repeated administration of epinephrine, although around 10% of anaphylaxis reactions are treated with multiple doses of epinephrine [6–9]. Bronchodilator effect of epinephrine in severe bronchospasm has been widely investigated in the past, but no data are available on the safety of its repetitive use for an extended period of time in this setting [10–12].

Case presentation

A 40-year-old woman was seen on a follow-up visit in mid-February 2020 for poorly controlled severe allergic asthma. While performing pulmonary function tests, she complained worsening dyspnoea, wheezing and nonproductive cough. Symptoms improved after the administration of inhaled short-acting β2-agonist (SABA) and intravenous (iv) methylprednisolone (mPDN), but in the following hours two additional exacerbations occurred with SpO_2 dropping to 80%. SABA and iv steroids again provided full relief of symptoms. She was admitted to our hospital for further investigations.

She had a history of several asthma exacerbations requiring hospitalization between 2009 and 2012, with last hospital admission in mid-February 2019, oral allergy syndrome with kiwi fruit, and perennial allergic rhinoconjunctivitis with sensitization to grasses, wall pellitory, cypress, *Alternaria*, house dust mite and cat dander. She had never smoked tobacco, did not drink alcohol, neither used recreational drugs. She worked as a bank employee. Her mother had asthma.

L. Salvati and C. Allegrini contributed equally to the work.

Author Contribution All authors contributed to the study conception and design. All authors read and approved the final manuscript.

Supplementary Information The online version of this article (https://doi.org/10.1007/s40629-022-00209-6) contains supplementary material, which is available to authorized users.

L. Salvati · C. Allegrini · L. Ciambellotti · S. Rizzello · F. Lavorini · G. Camiciottoli · P. Parronchi (✉)
Department of Experimental and Clinical Medicine, University of Florence, Florence, Italy
paola.parronchi@unifi.it

L. Salvati · P. Parronchi
Immunology and Cell Therapies Unit, Careggi University Hospital, Florence, Italy

C. Allegrini · L. Ciambellotti · S. Rizzello · F. Lavorini · G. Camiciottoli
Pneumology Unit, Careggi University Hospital, Florence, Italy

B. Piccardi · V. Palumbo
Stroke Unit, Careggi University Hospital, Florence, Italy

I. Lombardo
Neuroradiology Unit, Careggi University Hospital, Florence, Italy

Published online: 12 May 2022

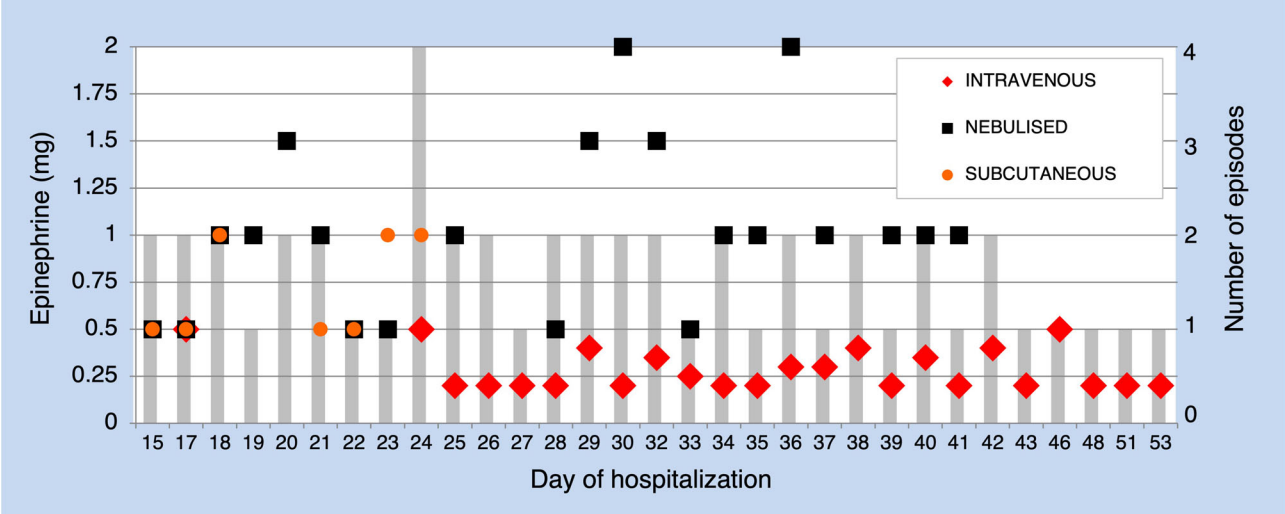

Fig. 1 Epinephrine administration during the hospital admission. From the 15th to the 53rd day of hospitalization the patient presented 50 episodes of bronchospasm and received a total of 6.85 mg epinephrine intravenously (*red diamonds*), 5 mg subcutaneously (*orange circles*), and 21.5 mg nebulized as inhalation aerosol (*black squares*). *Grey columns* indicate the number of episodes per day

Her body mass index was 27 kg/m^2. Her medications included beclomethasone/formoterol 100/6 µg 2 inhalations tid, oral anti-histamine qd and omalizumab 300 mg every month since 2014.

When admitted, she was afebrile and hemodynamically stable. Lung auscultation was notable for diffuse expiratory wheezing. She reported no fever, chills, sputum production, chest pain, headache, arthralgia, myalgia, heartburn, nausea, diarrhoea or vomiting. Chest radiograph and high-resolution computed tomographic scan were normal. Besides mild neutrophilic leukocytosis and increased total IgE level, hepatorenal function, inflammatory markers, and other laboratory test results were within normal limits (Supplementary Table 1). During hospital stay, despite maximal therapy (including mPDN 1 mg/kg per day, beclomethasone/formoterol 200/6 µg 2 inhalations tid, inhaled tiotropium bromide 5 µg bid, montelukast 10 mg qd, continuously iv aminophylline, magnesium sulfate 2 g iv qd and oxygen therapy as needed), she suffered almost daily episodes of bronchospasm with hypoxemia. The episodes were usually preceded by diffuse flushing, seldom with itching and urticaria on trunk and extremities, with rapid (10 min) resolution after epinephrine administration. During 54 days of hospitalization, she complained 67 episodes of acute dyspnoea with desaturation, 50 of them treated with epinephrine (Fig. 1). Notably, in many attacks, bronchospasm resulted from direct exposure to strong irritant odours. These could have acted as triggering factors, indeed her pulmonary conditions suddenly improved once they were fully eliminated from the environment. During the 67th and last episode, after a 200 µg iv bolus of epinephrine, the patient started complaining of mild headache following a 2-day history of hypoesthesia of the left side of the body. The neurologic examination was normal. Nonetheless, magnetic resonance angiography (MRA) showed multiple irregularities in the calibre of intracranial vessels (Fig. 2a). Cranial MRI revealed hyperintensities in both cerebral hemispheres (Fig. 2b, c) and transcranial Doppler (TCD) ultrasonography evidenced increased blood flow velocity. Nimodipine was started intravenously and then shifted orally with progressive symptoms improvement and significant blood flow deceleration on TCD.

Conclusion

This complex clinical presentation had no definite diagnosis. The scenario orientates towards difficult-to-treat asthma, exacerbated by exposure to triggering factors. During the hospital stay, the patient suffered almost daily attacks with relief only after epinephrine administration. Some episodes might indeed mimic idiopathic anaphylaxis, which is a diagnosis of exclusion [13]. Serum tryptase level was not measured after the events; however at baseline it was normal. Considering the self-limiting course of the disease, a clonal mast cell disorder or a carcinoid seemed unlikely. A psychiatric evaluation did not exclude a psychic component that could aggravate her clinical conditions; indeed, she was advised to follow psychotherapeutic treatment. Besides the respiratory manifestations, the dynamic vasospasm of cerebral vessels could have been determined by the repeated and numerous administration of epinephrine. Although the patient did not present the typical thunderclap headache, a diagnosis of reversible vasoconstriction syndrome was made [14, 15]. In fact, calcium channel blockers were resolutive and follow-up imaging studies performed 1 month (Fig. 2d–f) and 3 months

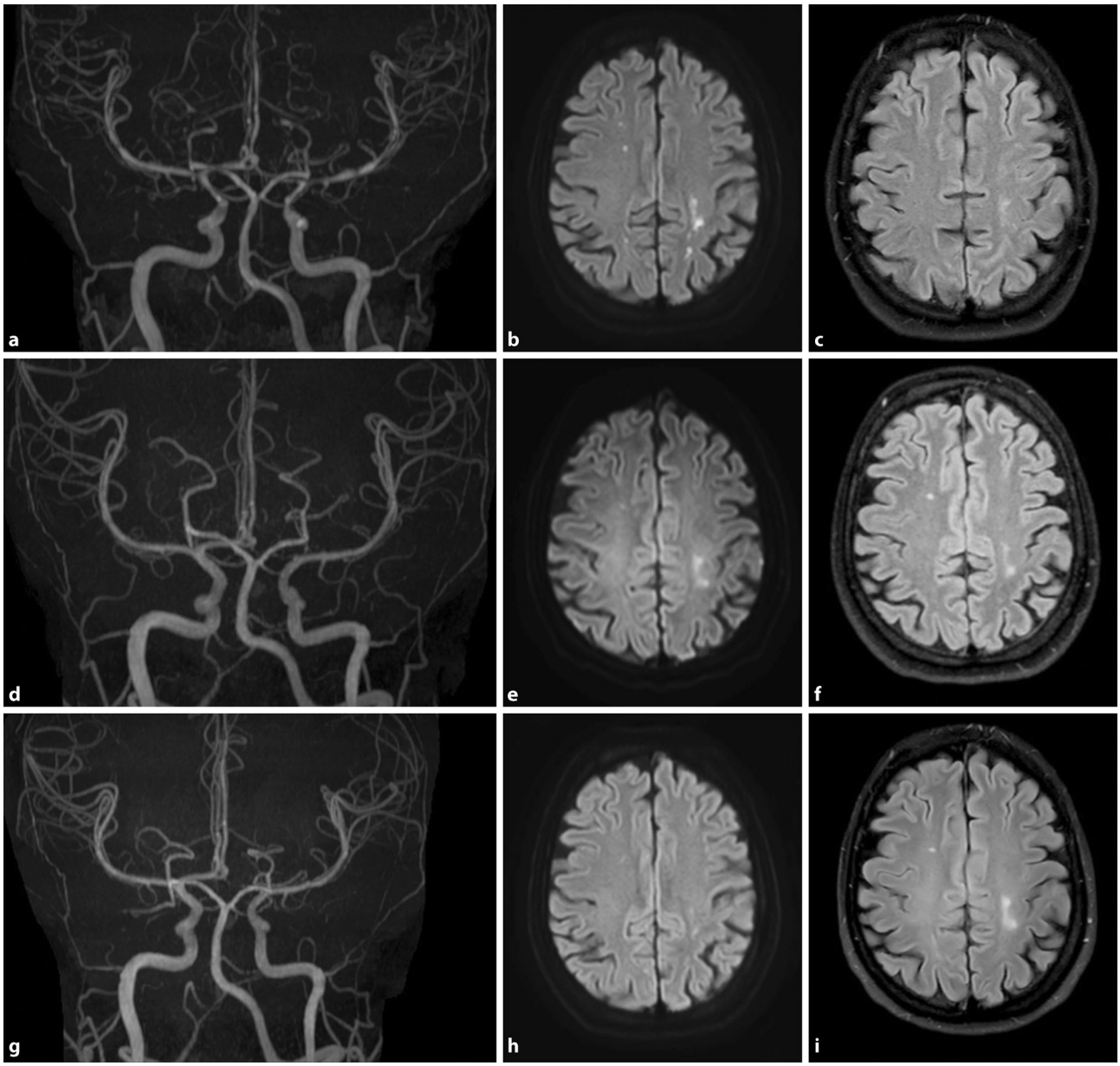

Fig. 2 Brain imaging. Magnetic resonance angiography (**a**) shows several narrowings involving large to medium-sized arteries followed by abnormally dilated segments of second-order and third-order branches. Watershed infarcts visualized in diffusion-weighted and fluid attenuated inversion recovery (FLAIR) images (**b** and **c**, respectively). Resolution of abnormalities at 1 month (**d–f**) and 3 month (**g–i**) follow-up imaging

later (Fig. 2g–i) showed almost complete resolution of vasoconstrictions.

In this unique case, the use of epinephrine was effective in managing multiple episodes of bronchospasm in a patient under maximal asthma therapy, but eventually a temporary adverse neurologic effect developed. Our clinical observation contributes to alerting on the potentially harmful effects of epinephrine even in young adults, particularly when administered repeatedly.

Acknowledgements All those who participated in the care of the patient.

Funding Open access funding provided by Università degli Studi di Firenze.

Conflict of interest L. Salvati, C. Allegrini, B. Piccardi, I. Lombardo, L. Ciambellotti, S. Rizzello, V. Palumbo, F. Lavorini, G. Camiciottoli and P. Parronchi declare that they have no competing interests.

Ethical standards All procedures performed were in accordance with the ethical standards of the institutional and/or national research committee and with the 1975 Helsinki declaration and its later amendments or comparable ethical standards. Informed consent was obtained from the participant included in the study.

Open Access This article is licensed under a Creative Commons Attribution 4.0 International License, which permits use, sharing, adaptation, distribution and reproduction in any medium or format, as long as you give appropriate credit to the original author(s) and the source, provide a link to the Creative Commons licence, and indicate if changes were made. The images or other third party material in this article are included in the article's Creative Commons licence, unless indicated otherwise in a credit line to the material. If material is not included in the article's Creative Commons licence and your intended use is not permitted by statutory regulation or exceeds the permitted use, you will need to obtain permission directly from the copyright holder. To view a copy of this licence, visit http://creativecommons.org/licenses/by/4.0/.

References

1. Muraro A, Worm M, Alviani C, Cardona V, DunnGalvin A, Garvey LH, et al. EAACI guidelines: Anaphylaxis (2021 update). Allergy. 2022;77:357–377. https://doi.org/10.1111/all.15032.
2. Shaker MS, Wallace DV, Golden DBK, Oppenheimer J, Bernstein JA, Campbell RL, et al. Anaphylaxis-a 2020 practice parameter update, systematic review, and grading of recommendations, assessment, development and evaluation (GRADE) analysis. J Allergy Clin Immunol. 2020;145:1082–1123. https://doi.org/10.1016/j.jaci.2020.01.017
3. Brown JC, Simons E, Rudders SA. Epinephrine in the management of anaphylaxis. J Allergy Clin Immunol Pract. 2020;8:1186–1195. https://doi.org/10.1016/j.jaip.2019.12.015
4. Cohen MB, Saunders SS, Wise SK, Nassif S, Platt MP. Pitfalls in the use of epinephrine for anaphylaxis: Patient and provider opportunities for improvement. Int Forum Allergy Rhinol. 2017;7:276–286. https://doi.org/10.1002/alr.21884
5. Simons KJ, Simons FE. Epinephrine and its use in anaphylaxis: Current issues. Curr Opin Allergy Clin Immunol. 2010;10:354–361. https://doi.org/10.1097/ACI.0b013e32833bc670
6. Manivannan V, Campbell RL, Bellolio MF, Stead LG, Li JTC, Decker WW. Factors associated with repeated use of epinephrine for the treatment of anaphylaxis. Ann Allergy Asthma Immunol. 2009;103:395–400. https://doi.org/10.1016/S1081-1206(10)60358-4
7. Carlson JN, Cook S, Djarv T, Woodin JA, Singletary E, Zideman DA. Second dose of epinephrine for anaphylaxis in the first aid setting: A scoping review. Cureus. 2020;12:e11401. https://doi.org/10.7759/cureus.11401
8. Liu X, Lee S, Lohse CM, Hardy CT, Campbell RL. Biphasic reactions in emergency department anaphylaxis patients: A prospective cohort study. J Allergy Clin Immunol Pract. 2020;8:1230–1238. https://doi.org/10.1016/j.jaip.2019.10.027
9. Patel N, Chong KW, Yip AYG, Ierodiakonou D, Bartra J, Boyle RJ, et al. Use of multiple epinephrine doses in anaphylaxis: A systematic review and meta-analysis. J Allergy Clin Immunol. 2021;148:1307–1315. https://doi.org/10.1016/j.jaci.2021.03.042
10. Melland B. The treatment of spasmodic asthma by the hypodermic injection of adrenalin. Lancet. 1910;175:1407–1411. https://doi.org/10.1016/S0140-6736(01)14446-6
11. Gotz VP, Brandstetter RD, Mar DD. Bronchodilatory effect of subcutaneous epinephrine in acute asthma. Ann Emerg Med. 1981;10:518–520. https://doi.org/10.1016/s0196-0644(81)80006-6
12. Benca J. Bronchospasm. In: Complications in Anesthesia. 2nd ed. 2007. Chapter 46. pp. 189–192. https://doi.org/10.1016/B978-1-4160-2215-2.50051-X
13. Fenny N, Grammer LC. Idiopathic anaphylaxis. Immunol Allergy Clin North Am. 2015;35:349–362. https://doi.org/10.1016/j.iac.2015.01.004
14. Ducros A. Reversible cerebral vasoconstriction syndrome. Lancet Neurol. 2012;11:906–917. https://doi.org/10.1016/S1474-4422(12)70135-7
15. Palma JA, Fontes-Villalba A, Irimia P, Garcia-Eulate R, Martinez-Vila E. Reversible cerebral vasoconstriction syndrome induced by adrenaline. Cephalalgia. 2012;32:500–504. https://doi.org/10.1177/0333102412444011

Supplementary Table 1. Laboratory Data

Variable	Admission	Discharge	Reference Range, Adults
Blood			
Hematocrit (%)	35	36.1	36–46
Hemoglobin (g/dL)	11.7	11.8	12–16
Red-cell count (per μL)	3,740,000	3,790,000	4,200,000–5,400,000
Mean corpuscolar volume (fl)	94.7	95.3	81–94
Red blood cell distribution width (%)	12.8	13.3	11.8–14.8
White-cell count (per μL)	**13100**	9060	4000–10000
Differential count			
Neutrophils (per μL)	**10,320**	6480	1500–7500
Lymphocytes (per μL)	1,950	1860	1000–4800
Monocytes (per μL)	790	700	300–1200
Eosinophils (per μL)	10	10	0–700
Basophils (per μL)	30	20	0–200
Platelet count (per μL)	308,000	289,000	140,000–440,000
Prothrombin time (sec)	11.7	12.3	9.5–12
Prothrombin time (%)	95	89	70-130
Prothrombin-time international normalized ratio	1.0	1.09	0.8–1.2
Activated-partial thromboplastin time (sec)	22.5	26.9	22–38
Activated-partial thromboplastin time (ratio)	0.76	0.91	0.73–1.27
Sodium (mEq/L)	140	139	135–145
Potassium (mEq/L)	4.5	3.9	3.5–5.1
Chloride (mEq/L)	103	100	95–110
Calcium (mg/dL)	8.9	8.6	8.6–10.2
Magnesium (mg/dL)	1.8	1.7	1.7–2.5
Creatinine (mg/dL)	0.66	0.58	0.5–1.10
Glucose (mg/dL)	100	97	65–110
Fibrinogen (mg/dL)	196	216	200–400
Alanine aminotransferase (U/L)	28	48	10–35
Total bilirubin	0.4	0.4	0.2–1
Lactate dehydrogenase (U/L)	163	203	135–214
C-reactive protein (mg/L)	<5	<5	<5
Total IgE (KU/L)	359	82.8	0–85

Variable	Admission	Reference Range, Adults
Eosinophil cationic protein (μg/L)	11	0–15
Basal serum tryptase (μg/L)	3.5	0–13.4
NT-proBNP (pg/mL)	65	1–125
Erythrocyte sedimentation rate (mm/hr)	3	2–30
Procalcitonin (ng/mL)	0.06	<0.5
Troponin T (pg/mL)	<3	<14
Protein		
Total (g/dL)	6.7	6–8.2
Albumin (%)	58.4	55.8–66.1
α1-globulins (%)	3.4	2.9–4.9
α2-globulins (%)	11.6	7.1–11.8
β1-globulins (%)	5.4	4.7–7.2

β2-globulins (%)	4.8	3.2–6.5
γ-globulins (%)	16.4	11.1–18.8
IgG (mg/dL)	1180	700–1600
IgA (mg/dL)	271	70-400
IgM (mg/dL)	69	40-230
IgG1 (mg/dL)	750	490–1140
IgG2 (mg/dL)	357	150–640
IgG3 (mg/dL)	79	20–110
IgG4 (mg/dL)	35	8–82
Complement C4 (g/L)	0.13	0.1–0.4
Antinuclear antibodies (IFI on HEp2 cells)	1:80; speckled pattern	1:80
ENA CTD-screen (ratio)	0.2	0–1
Antibodies to anti-neutrophil cytoplasm (ANCA)	Not present	Not present
anti-PR3 antibodies (UI/mL)	0.3	0–3
anti-MPO antibodies (UI/mL)	0.2	0–5
Anti-Respiratory Syncytial Virus antibodies (IgA)	Not present	Not present
Anti-Parainfluenza virus 1-2-3 antibodies	Not present	Not present
Galactomannan antigen	Negative	Negative
1-3-β-D-Glucan (pg/mL)	Negative	Negative
Influenza Virus A (PCR)	Negative	Negative
Influenza Virus B (PCR)	Negative	Negative
SARS-CoV-2 (PCR)	Negative	Negative
Soluble *Legionella pneumophila* antigens	Not present	Not present
Soluble *Streptococcus pneumoniae* antigens	Not present	Not present
IgG Anti-*Strongyloides* antibodies	Not present	Not present
IgG anti-*Toxocara* antibodies	Not present	Not present
Ova and parasite stool test	Negative	–
Fecal cultures	Negative	–
Anisakis-specific IgE (KU/L)	6.98	<0.10
Velvet grass-specific IgE (KU/L)	5.25	<0.10
Wall pellitory-specific IgE (KU/L)	2.98	<0.10
Cat dander-specific IgE (KU/L)	0.52	<0.10
House dust mite-specific IgE (KU/L)	0.22	<0.10
Milk-specific IgE (KU/L)	0.17	<0.10
Egg white-specific IgE (KU/L)	0.11	<0.10
Shrimp-specific IgE (KU/L)	0.02	<0.10
Latex-specific IgE (KU/L)	0.02	<0.10
rBet v 1 (KU/L)	0.01	<0.10
rBet v 2 (KU/L)	0.02	<0.10
rPru p 3 (KU/L)	0.03	<0.10
rTri a 19 (KU/L)	0.02	<0.10
rTri a 14 (KU/L)	0.01	<0.10
Alpha-gal (KU/L)	0	<0.10
Arterial blood gases		
Fraction of inspired oxygen (%)	21	
pH	7.44	7.35–7.45
$PaCO_2$ (mm Hg)	37	32–45
PaO_2 (mm Hg)	91	83–108

Urine		
Color	Yellow	Yellow
Clarity	Clear	Clear
pH	6	5.0–6.5
Specific gravity	1.023	1.015–1.025
Protein	Negative	Negative
Glucose	Negative	Negative
Ketones	Negative	Negative
Bilirubin	Negative	Negative
Nitrite	Negative	Negative
Leukocyte esterase	250	Negative
Red cells (per µL)	10	<20
Leukocytes (per µL)	127	<18