Kounis syndrome secondary to food allergy

Introduction

Kounis syndrome is defined as the concurrence of acute coronary syndromes in the setting of an allergic insult. This rare syndrome is not well recognized by physicians. In most reports exogenous adrenaline has been administered, giving a possible aetiology. This article reports a case of a 59-year-old woman who developed transient ST elevation in anterior leads during a severe allergic reaction to food. No adrenaline was administered. Coronary angiogram showed normal coronaries, suggesting vasospasm or direct myocardial injury as the mechanism. This case is one of only a few reports describing Kounis syndrome related to food allergy.

Discussion

Stress-induced cardiomyopathy has been recognized in a wide array of clinical situations involving neurohormonal dysregulation with high levels of circulating catecholamines. Transient cardiomyopathy has also been observed during anaphylactic shock. Kounis syndrome has been defined as an acute coronary syndrome in the context of an acute allergic reaction (Kounis, 2006; Alevizos et al, 2014). Currently, only a few cases have been reported in the literature, most following an allergic reaction to drugs or insect sting. In most reports exogenous adrenaline was administered.

Haemodynamic compromise as part of a severe allergic reaction, although not present in this case report, might in itself result in cardiac ischaemia. However, severe allergic reaction with mast cell degranulation results in the release of various inflammatory mediators including histamine, neutral proteases, arachidonic acid products and a variety of cytokines and chemokines, as well as endogenous catecholamines. Such mediators can induce either coronary artery spasm which can progress to acute myocardial infarction or atheromatous plaque erosion or rupture culminating in coronary thrombosis (Kounis, 2013). A report described a

Dr B Nachmias *is Senior Resident and* **Professor D Leibowitz** *is Senior Consultant in the Department of Internal Medicine, Hadassah Mount Scopus Hebrew University Medical Center, Jerusalem, 91120 Israel*

Correspondence to: Dr B Nachmias (Nachmias_B@yahoo.com)

Figure 1. Emergency medical technician electrocardiogram recordings: (a) on arrival, (b) sequential after a few minutes, (c) on resolution.

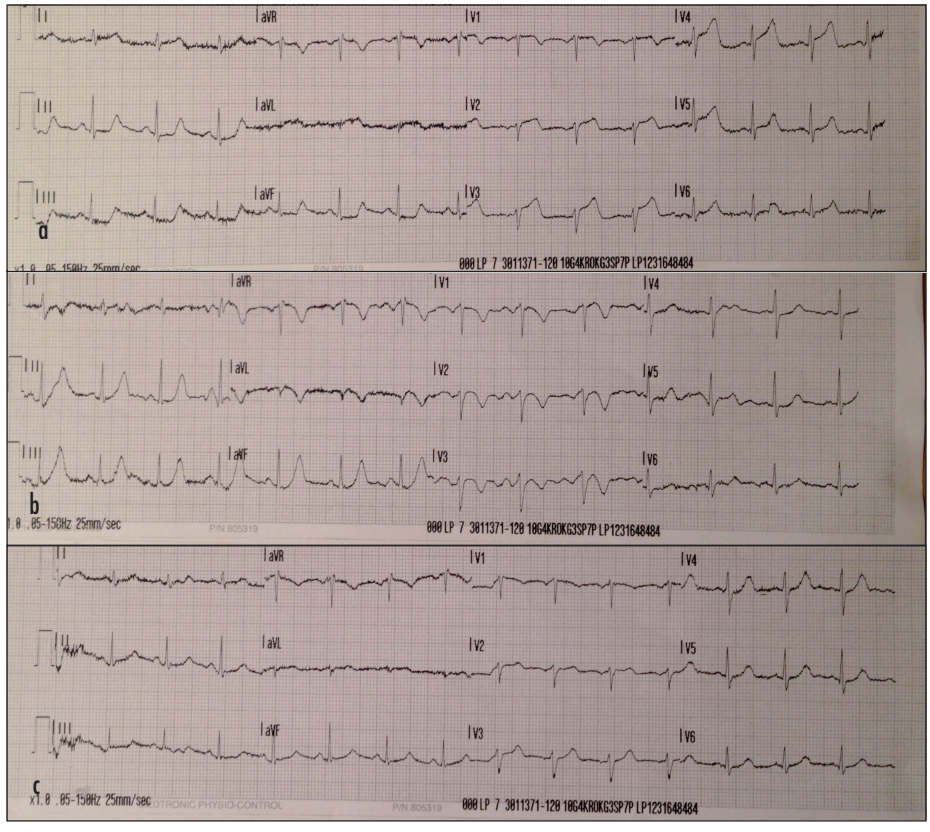

Case Report

A 59-year-old woman was eating salad with mustard dressing at a restaurant when she began feeling generalized warmth and palpitations followed by diffuse erythema and light-headedness. The patient called an ambulance and after an electrocardiogram had been performed was transferred to the emergency room. As the patient maintained blood pressure (blood pressure 110/90 mmHg) and no airway or respiratory compromise was noted, no adrenaline was administered. Her previous medical history was significant for hypertension, smoking and hyperlipidaemia. Several minor allergic reactions manifesting as urticaria were noted in the past. There was no known history of ischaemic heart disease. The patient denied chest pain but the initial electrocardiogram demonstrated ST elevations in anterior leads with reciprocal ST depressions (*Figure 1*). On admission to the emergency room the patient had normal vital signs, with diffuse urticaria and erythema. Sequential electrocardiogram showed resolution of the ST elevations.

The patient was treated for acute coronary syndrome with aspirin, clopidogrel and low molecular weight heparin. Given the severe allergic reaction treatment with steroids was initiated, but at no time was subcutaneous adrenalin administered. High sensitive troponin level was negative and no eosinophilia was noted. Echo demonstrated normal left ventricular function with no wall motion abnormalities. Coronary angiography demonstrated normal coronary arteries. The patient was discharged in good condition with recommendations to continue aspirin and gradually taper steroid therapy. Follow up at the allergy clinic did not reveal any specific allergen by skinprick test.

© 2014 MA Healthcare Ltd

case in which Kounis syndrome was the first manifestation of systemic mastocytosis, further supporting the role of mast cells in the pathophysiology of cardiac insult (Lleonart et al, 2013).

High levels of catecholamines also contribute to the transient left ventricle dysfunction. Severe allergic reactions are accompanied by endogenous secretion of catecholamines. In addition exogenous adrenaline is frequently administered as therapy. One of the postulated mechanisms of takotsubo or stress cardiomyopathy is high levels of catecholamines causing acute myocardial injury. Similarly, phaeochromocytoma patients experiencing high levels of catecholamines also have been shown to develop a takotsubo-like cardiomyopathy (Naderi et al, 2012). It is important to note that the classic echocardiographic finding in takotsubo of apical ballooning may not always be present. Previous reports have described takotsubo cardiomyopathy following an allergic reaction. In most of these reports adrenaline administered to the patient was thought to be the trigger (Dewachter et al, 2011; Santoro et al, 2012). Several reports have demonstrated coronary vasospasm in response to adrenaline administration (Battaglia and Nammas, 2010).

Alternatively, a report suggested that 'stunned' injured myocardium and not vasospasm is the primary mechanism (Morel et al, 2010). The case presented explored the role of adrenaline in the cardiac injury of a young patient with a severe allergic reaction who received an accidently high dose of adrenaline and afterward developed ST elevation and haemodynamic collapse. Interestingly, the coronary angiogram was normal while ST elevation was still observed.

It therefore appears that during severe allergic reaction, ventricular contractile dysfunction may be caused by both mast cell activation and sympathetic activation with elevated catecholamine levels. Several allergens have been reported to trigger Kounis syndrome, including hymenoptera sting (Ioannidis et al, 2007), antibiotics (Ilhan et al, 2013) and one report of food allergy (Kounis, 2006).

To the best of the authors' knowledge this is only the second report of Kounis syndrome as a result of food allergy. This case demonstrates that Kounis syndrome should be considered in the differential diagnosis of acute coronary syndrome during an allergic reaction to food, even in the absence of exogenous administration of adrenaline. **BJHM**

Alevizos M, Karagkouni A, Panagiotidou S, Vasiadi M, Theoharides TC (2014) Stress triggers coronary mast cells leading to cardiac events. *Ann Allergy Asthma Immunol* **112**: 309–16 (doi: 10.1016/j.anai.2013.08.025)

Battaglia S, Nammas W (2010) Wandering coronary stenoses: adrenaline-induced coronary artery spasm in a patient resuscitated from cardiac arrest. *Catheter Cardiovasc Interv* **75**: 1056–9 (doi: 10.1002/ccd.22409)

Dewachter P, Tanase C, Levesque E, Nicaise-Roland P, Chollet-Martin S, Mouton-Faivre C, Benhamou D (2011) Apical ballooning syndrome following perioperative anaphylaxis is likely related to high doses of epinephrine. *J Anesth* **25**: 282–5 (doi: 10.1007/s00540-010-1085-0)

Ilhan E, Akbulut T, Gursurer M (2013) An underdiagnosed syndrome; Kounis syndrome secondary to amoxicillin/clavulanic acid use in a 16 year-old child. *Int J Cardiol* **167**: e90–1 (doi: 10.1016/ijcard.2013.03.158)

Ioannidis TI, Mazarakis A, Notaras SP et al (2007) Hymenoptera sting-induced Kounis syndrome: effects of aspirin and beta-blocker administration. *Int J Cardiol* **121**: 105–8 (doi: 10.1016/ijcard.2006.08.039)

Kounis NG (2006) Kounis syndrome (allergic angina and allergic myocardial infarction): a natural paradigm? *Int J Cardiol* **110**: 7–14 (doi: 10.1016/ijcard.2005.08.007)

Kounis NG (2013) Coronary hypersensitivity disorder: the Kounis syndrome. *Clin Ther* **35**: 563–71 (doi: 10.1016/jclinthera.2013.02.022)

Lleonart R, Andres B, Makatsori M, Rubio-Rivas M, Pujol R, Corominas M (2013) Systemic mastocytosis presenting as Kounis syndrome. *Ann Allergy Asthma Immunol* **111**: 570–1 (doi: 10.1016/j.anai.2013.09.009)

Morel O, Jesel L, Morel N, Nguyen A, Trinh A, Ohlmann P, Imperiale A (2010) Transient left ventricular dysfunction syndrome during anaphylactic shock: vasospasm, Kounis syndrome or epinephrine-induced stunned myocardium? *Int J Cardiol* **145**: 501–3 (doi: 10.1016/ijcard.2009.10.046)

Naderi N, Amin A, Setayesh A, Pouraliakbar H, Mozaffari K, Maleki M (2012) Pheochromocytoma-induced reverse tako-tsubo with rapid recovery of left ventricular function. *Cardiol J* **19**: 527–31 (doi: 10.5603/CJ.2012.0097)

Santoro F, Correale M, Ieva R, Caiaffa MF, Pappalardo I, Di Biase M, Brunetti ND (2012) Tako-tsubo cardiomyopathy following an allergic asthma attack after cephalosporin administration. *Int J Cardiol* **159**: e20–1 (doi: 10.1016/ijcard.2011.11.106)

LEARNING POINTS

- This case describes a rare clinical scenario of food allergy presenting with transient ST elevation on electrocardiogram, a phenomenon known as Kounis syndrome.
- The pathophysiology of Kounis syndrome is related to mast cell activation and sympathetic neurohormones.
- Unlike previous reports of Kounis syndrome resulting from food allergy, no exogenous adrenaline was given to this patient.
- Clinicians should consider the diagnosis of Kounis syndrome in patients with transient ST elevation in the setting of food allergy.

Forthcoming case reports

When ischaemia is not ischaemia

O'Sullivan-McLeod syndrome: clinical features, neuroradiology, and nosology

A case of the prolapsed facial nerve into the middle ear cavity

'Coffee ground vomiting': an unusual cause for a common presentation

© 2014 MA Healthcare Ltd

Copyright of British Journal of Hospital Medicine (17508460) is the property of Mark Allen Publishing Ltd and its content may not be copied or emailed to multiple sites or posted to a listserv without the copyright holder's express written permission. However, users may print, download, or email articles for individual use.