OPEN

Dermatopathic Lymphadenopathy With Increased IgG4-Positive Plasma Cells

Shoko Nakayama, MD, PhD, Taiji Yokote, MD, PhD, Toshikazu Akioka, MD, Takuji Miyoshi, MD, PhD, Yuji Hirata, MD, PhD, Nobuya Hiraoka, MD, PhD, Kazuki Iwaki, MD, Ayami Takayama, MD, Uta Nishiwaki, MD, Yuki Masuda, MD, Toshiaki Hanafusa, MD, PhD, Yasuichiro Nishimura, PhD, and Motomu Tsuji, MD, PhD

Abstract: Both dermatopathic lymphadenopathy (DL) and immunoglobulin G4-related disease (IgG4-RD) are frequently complicated with allergic diseases. However, the relationship between DL and IgG4-RD is not well known. To clarify this relationship on the basis of clinical and pathological findings, including IgG4-positive (IgG4+) plasma cell infiltration in lymph nodes (LNs) of DL patients, we analyzed LNs of 11 DL patients using immunostaining of IgG, IgG4, forkhead box P3 (FOXP3), transforming growth factor (TGF)-β, interferon (IFN)-γ, and matrix metalloproteinase (MMP)-1, MMP-8, and MMP-13. Toluidine blue staining was also performed to identify mast cells. Of 3 patients with a high ratio of IgG4+/IgG+ cells (>40%) and elevated serum IgG4 levels, 2 developed IgG4-RD, whereas the other patient did not. Of 8 patients with a low ratio of IgG4+/IgG+ cells (<40%) or no infiltration of IgG4+ cells, 5 who could be followed did not develop IgG4-RD. The numbers of mast cells were similar to those of TGF-β-positive cells, and serial sections showed that mast cells possibly produce TGF-β. LNs of DL patients with a high ratio of IgG4+/IgG+ cells had significantly more mast cells and TGF-β-positive cells than those of patients with a low ratio of IgG4+/IgG+ cells or no infiltration of IgG4+ cells. However, no fibrosis was observed in LNs of both groups. IFN-γ was positive in interdigitating dendritic cells, Langerhans cells, and macrophages. MMP-1, MMP-8, or MMP-13 was expressed in macrophages. The lack of fibrosis in LNs may have been due to the production of IFN-γ, MMP-1, MMP-8, or MMP-13. Thus, DL with increased IgG4+ cells seems to be a phenotype of IgG4-RD in LNs.

(*Medicine* 94(22):e866)

Abbreviations: ATLL = adult T-cell leukemia/lymphoma, DL = dermatopathic lymphadenopathy, FOXP3 = forkhead box P3, H&E = hematoxylin and eosin, HPF = high-power field, IDCs = interdigitating dendritic cells, IFN-γ = interferon-γ, IgG4-RD = Immunoglobulin G4-related disease, LN = lymph node, MMP = matrix metalloproteinase, MTX = methotrexate, PET = positron emission tomography, SDs = standard deviations, TGF-β = transforming growth factor-β.

Editor: Zhengshan Chen.
Received: October 25, 2014; revised: March 11, 2015; accepted: April 11, 2015.
From the Department of Internal Medicine (I) (SN, TY, TA, TM, YH, NH, KI, AT, UN, YM, TH); Division of Mathematics (YN); Division of Surgical Pathology (MT), Osaka Medical College, Osaka, Japan.
Correspondence: Shoko Nakayama, Department of Internal Medicine (I), Osaka Medical College, 2-7 Daigakumachi, Takatsuki City, Osaka 569-0801, Japan (e-mail: in1304@poh.osaka-med.ac.jp).
Our manuscript is a unique submission and is not being considered for publication by any other source in any medium. Further, the manuscript has not been published, in part or in full, in any form.
The authors report no conflicts of interest.
Copyright © 2015 Wolters Kluwer Health, Inc. All rights reserved.
This is an open access article distributed under the Creative Commons Attribution-NonCommercial-NoDerivatives License 4.0, where it is permissible to download, share and reproduce the work in any medium, provided it is properly cited. The work cannot be changed in any way or used commercially.
ISSN: 0025-7974
DOI: 10.1097/MD.0000000000000866

INTRODUCTION

Dermatopathic lymphadenitis (DL) is a rare type of benign reactive lymphatic hyperdysplasia associated with skin lesions of the exfoliative or eczematoid type, including pemphigus, psoriasis, eczema, atopic dermatitis, and allergic skin diseases.[1] DL is often observed in inguinal and axially lymph nodes (LNs) but may be found in LNs anywhere in the body. These LNs are moderately enlarged, firm, movable, and rather painless.[2] A diagnosis of DL ultimately depends on histological findings; these include interfollicular and paracortical hyperplasia of LNs by infiltration of interdigitating dendritic cells (IDCs), Langerhans cells, macrophages, and T cells. Melanin granule-laden macrophages are often scattered in these LNs. These findings are associated with LNs that drain the sites of skin irritation, inflammation, or infection. The time interval between the appearance of skin manifestations and LNs of DL varies; however, DL has been occasionally reported in patients without active dermatopathies.[3,4]

Kamisawa et al[5] proposed a new disease entity in 2006 that was characterized by elevated serum IgG4 levels, tumefactive inflammation of organs, infiltration of IgG4-positive (IgG4+) plasma cells, and fibrosis in the affected tissue and with a favorable response to steroid therapy. This disease has become known as IgG4-related disease (IgG4-RD).[6] Although IgG4-RD mainly affects extranodal sites, particularly glandular organs/tissues such as the pancreas, salivary glands, lacrimal glands, and soft tissues, lymphadenopathy is one of the common findings. In fact, up to 80% of patients with IgG4-RD are found to have localized or systemic lymphadenopathy on imaging.[7] Moreover, lymphadenopathy occasionally appears as the first manifestation of IgG4-RD.[8]

Thus, it is thought that there are 4 clinical scenarios for which lymphadenopathy occurs in IgG4-RD (IgG4-related lymphadenopathy): regional LNs are serendipitously found in excision specimens of organs affected by IgG4-RD; lymphadenopathy is found as a part of the presentation of IgG4-RD by clinical examination or imaging studies; lymphadenopathy appears within weeks to years after the onset of preceding IgG4-RD; and lymphadenopathy is found as the initial manifestation without preceding extranodal IgG4-RD, and these patients develop extranodal involvement after varying time

intervals. Therefore, lymphadenopathy of this type is considered as a primary lesion of IgG4-RD.[8,9]

Histologically, IgG4-related lymphadenopathy can exhibit a broad morphological spectrum and is currently classified into 5 types: type I, multicentric Castleman disease-like; type II, follicular hyperplasia; type III, interfollicular expansion; type IV, progressive transformation of germinal centers; and type V, inflammatory pseudotumor-like. However, typing can be complicated by the possible overlap of patterns in individual cases.[9,10]

IgG4-RD is also known to be frequently complicated with allergic diseases and sometimes shows elevated serum IgE levels. In contrast, allergic diseases such as atopic dermatitis, asthma, some parasitic diseases, and bullous skin diseases sometimes manifest with elevated serum IgG4 levels.[11–13] However, any relationship between DL and IgG4-RD is not well known. Therefore, in the present study, we examined the relationship between patients' clinical findings and the grades of infiltration of IgG4+ cells into LNs, and we discuss the histological characteristics in LNs of DL, mainly in terms of infiltrating cells.

MATERIALS AND METHODS

Case Samples

We examined all specimens that were obtained from LNs of 11 DL patients who were diagnosed between 1999 and 2013 at the Osaka Medical College Hospital. Ethical approval was obtained from the Ethics Committee of Osaka Medical College.

Histopathology and Immunostaining

LNs were fixed in 10% buffered formalin, embedded in paraffin, cut into 4-μm-thick sections, and stained with hematoxylin and eosin (H&E). Toluidine blue staining was used to identify mast cells. Immunohistological staining was performed using EnVision G/2 system/AP (DAKO, Glostrup, Denmark) for interferon (IFN)-γ (H145; Santa Cruz Biotechnology, Santa Cruz, CA), transforming growth factor (TGF)-β (TGFB17; Novocastra, Newcastle, UK), matrix metalloproteinase (MMP)-1 (ab38929; Abcam Inc, Cambridge, MA), MMP-8 (GeneTex, Inc, Irvine, CA), and MMP-13 (N3C1; GeneTex) and using Envision HRP (DAKO) for CD1a (MTB1; Novocastra, Newcastle, UK), IgG (A57H; Nichirei, Tokyo, Japan), and IgG4 (HP6025; Nichirei). We also performed double staining for the pairs CD4 (4b12; DAKO)/CD8 (C8/144B; Nichirei), CD68 (KP1; DAKO)/S100 protein (PS1; Nichirei), forkhead box P3 (FOXP3) (236A/E7; Abcam Inc)/CD25 (4C9; Novocastra), and FOXP3/TGF-β using both Envision HRP (DAKO) and EnVision G/2 system/AP (DAKO).

To enumerate IgG4+ or IgG+ cells, the areas with the highest density of positive cells were evaluated in one high-power field (HPF), and the ratio of infiltrating IgG4+ plasma cells to IgG+ plasma cells (IgG4+/IgG+ cells) was determined. The ratio of IgG4+/IgG+ cells was considered significantly elevated when it was >40%.[8] The LN specimens were divided into 2 groups: DL with a high ratio of IgG4+/IgG+ cells (>40%) and DL with a low ratio of IgG4+/IgG+ cells (<40%) or no IgG4+ cell infiltration. The numbers of mast cells or TGF-β-positive cells in the entire lesion of each LN were counted under a microscope. An area of LNs was measured by objective quantitative analysis using the WinROOF image processing software program (MITANI Corporation, Tokyo, Japan). The number of mast cells or TGF-β-positive cells was expressed per square millimeter (mm^2).

Statistical Analysis

Results for continuous variables are given as means ± stanstandard deviations (SDs) or medians. Patients' ages, the numbers of mast cells/mm^2, and the numbers of TGF-β-positive cells/mm^2 in LNs were compared between the 2 groups of patients using χ^2 tests. P values <0.05 were considered significant. Statistical analyses were performed using JMP Pro 11 (SAS Institute, Inc, Cary, NC).

RESULTS

Patients' Clinical Characteristics

Table 1 summarizes the patients' clinical characteristics, laboratory results, pathological findings, and clinical outcomes. The average age of the 11 DL patients was 61 years (range: 13–72 years). There was no significant difference in age between the 2 groups of patients: 64 ± 13 years for DL patients with a high ratio of IgG4+/IgG+ cells and 69 ± 7 years for DL patients with a low ratio of IgG4+/IgG+ cells or no IgG4+ cell infiltration ($P = 0.7709$). Of these 11 patients, 8 had a skin disease such as psoriasis vulgaris, atopic dermatitis, erythema multiforme, or allergic dermatitis. Three had no skin disease. Serum IgG4 levels for the patients with a high ratio of IgG4+/IgG+ cells was elevated to 176, 173, and 156 mg/dL for patients 1, 2, and 3, respectively (normal; 4.8–105 mg/dL). IgG4 levels were not measured for the other patients.

Patients' Clinical Courses

For case 1, a patient without any conspicuous skin disease, swelling of the right inguinal LN was found, and the biopsied specimen was diagnosed as DL. At 1 month after this biopsy, retroperitoneal fibrosis was identified by a computed tomography (CT) scan. The tissue was biopsied and histologically showed fibrosis, a large number of IgG4+ cells, and a high ratio (51.4%) of IgG4+/IgG+ cells (Figure 1A and B). A diagnosis of IgG4-related retroperitoneal fibrosis was made. He was treated with steroid therapy for 3 years and has been well without any clinical symptoms.

For case 2, a patient with psoriasis vulgaris, swelling of the right inguinal LN was found and was histologically diagnosed as having DL. After 5 months, swelling of the para-aortic LNs newly appeared on a follow-up CT scan. The biopsied specimen from the paraaortic LN obtained by laparoscopy showed fibrosis and a high ratio (48.2%) of IgG4+/IgG+ cells (Figure 2A and B). No gene rearrangements were found for T-cell receptors or the immunoglobulin heavy chain J region. A diagnosis of IgG4-related lymphadenopathy, type V, was made.[9,10] He was followed for 8 months, and his paraaortic LNs decreased in size with steroid therapy.

For case 3, a patient who had been treated with steroid therapy for severe atopic dermatitis and asthma for 5 years, swelling of bilateral axillary and inguinal LNs was found. The right inguinal LN was biopsied and diagnosed as DL. A whole-body positron emission tomography (PET)-CT scan showed no extranodal involvement. He was treated with steroid therapy for atopic dermatitis and asthma for another 10 months, and he has been well.

For case 4, a patient who had been treated with steroid and methotrexate (MTX) therapy for rheumatoid arthritis for 18 years, swelling of bilateral axillary and left inguinal LNs was found. The left inguinal LN was biopsied and diagnosed as DL.

Copyright © 2015 Wolters Kluwer Health, Inc. All rights reserved.

TABLE 1. Clinical Findings For 11 DL patients

Case	Sex	Age	Biopsied Lymph Node	Skin Disease	Systemic Disease	IgG4/IgG (%)	Serum IgG4 Level, mg/dL	No. of Mast Cells/mm^2	No. of TGF-β-positive Cells/mm^2	Other Laboratory Findings	Clinical outcome After Diagnosis of DL	Follow-up Period
1	M	66	Inguinal lymph node	None	None	62.8	176 (4.8–105)	4.4	6.1	IgG 1807 (870–1700) mg/dL IgA 419 (110–410) mg/dL IgM 30 (35–220) mg/dL IgE 484 (<340) mg/dL IL-2 receptor 1360 (220–530) U/mL	One month later, retroperitoneal fibrosis was found. He has been treated with steroid therapy and has been well.	3 years
2	M	66	Inguinal lymph node	Psoriasis vulgaris	None	65.3	173	15.6	16.7	IgG 2071 mg/dL IgA 346 mg/dL IgM 178 mg/dL IL-2 receptor 1520 U/mL	Five months later, IgG4-related lymph-adenopathy of paraaortic lymph node was found. He has been treated with steroid therapy. The lymph node decreased in size.	8 months
3	M	60	Inguinal lymph node	Atopic dermatitis treated with steroid therapy for 5 years	Asthma	52.7	156	11.0	13.3	IgG 1817 mg/dL IgA 287 mg/dL	He has been treated with steroid therapy for severe atopic dermatitis and asthma, and he has been well.	10 months

Copyright © 2015 Wolters Kluwer Health, Inc. All rights reserved.

Case	Sex	Age	Biopsied Lymph Node	Skin Disease	Systemic Disease	IgG4/IgG (%)	Serum IgG4 Level, mg/dL	No. of Mast Cells/mm^2	No. of TGF-β-positive Cells/mm^2	Other Laboratory Findings	Clinical outcome After Diagnosis of DL	Follow-up Period
4	M	71	Inguinal lymph node	None	Rheumatoid arthritis treated with steroid and MTX therapy for 18 years	1.5	ND	4.3	5.4	IgM 54 mg/dL IgE 49709 mg/dL MMP-3 377 ng/mL (36.9–121) mg/dL	He has been treated with steroid therapy for RA and has been well.	3 years
5	M	27	Inguinal lymph node	Atopic dermatitis	None.	0	ND	1.0	0.7	IgG 1128 mg/dL IgA 174 mg/dL IgM 335 mg/dL IgE 12432 mg/dL	He had been well for 5 years without medication; however, after that, the follow-up was discon tinued.	5 years
6	F	13	Inguinal lymph node	Allergic dermatitis	None	0	ND	0.5	0.9	IL-2 receptor 1890 U/mL IL-2 receptor 4070 U/mL	Well without medication.	9 years
7	M	71	Inguinal lymph node	Erythema multiforme	None	0	ND	3.5	3.9	ANA antibody 1:80 titer (1:20)	Fourteen months later, the swel ling of the right brachium lymph node appeared. It was biopsied and diagnosed as ATLL. He was treated with CHOP therapy and lymph node swelling disap peared. He has been well.	4 years
8	M	70	Cervical lymph node	None.	None	2.3	ND	1.9	1.9	IgG 836 mg/dL IgA 249 mg/dL IgM 89 mg/dL None	No follow-up.	None

Copyright © 2015 Wolters Kluwer Health, Inc. All rights reserved.

Case	Sex	Age	Biopsied Lymph Node	Skin Disease	Systemic Disease	IgG4/IgG (%)	Serum IgG4 Level, mg/dL	No. of Mast Cells/mm^2	No. of TGF-β-positive Cells/mm^2	Other Laboratory Findings	Clinical outcome After Diagnosis of DL	Follow-up Period
9	M	83	Inguinal lymph node	Allergic dermatitis treated with steroid therapy for a month	None	1.7	ND	2.5	2.4	WBC 4740 (3300–8190)/μL Eos 36.3% IL2 receptor 2360 U/mL ANA antibody positive	He had been treated with steroid therapy and was well. After 3 months, the follow-up was discontinued.	3 months
10	M	72	Inguinal lymph node	Psoriasis vulgaris	None	2.9	ND	2.6	3.8	ANA antibody 1: 80 titer IL-2 receptor 1380 U/mL	He has been treated with etretinate and mequitazine for psoriasis vulgaris and has been well.	8 years
11	M	69	Cervical lymph node	Allergic dermatitis	None	2.5	ND	1.7	2.5	None	No follow-up	None.

ANA = antinuclear antibodies, ATLL = adult T-cell leukemia/lymphoma, CHOP = cyclophosphamide, hydroxydaunorubicin, oncovin, and prednisolone, DL = dermatopathic lymphadenopathy, IL = interleukin, MMP = matrix metalloproteinase, MTX = methotrexate, RA = rheumatoid arthritis, TGF = transforming growth factor.

Copyright © 2015 Wolters Kluwer Health, Inc. All rights reserved.

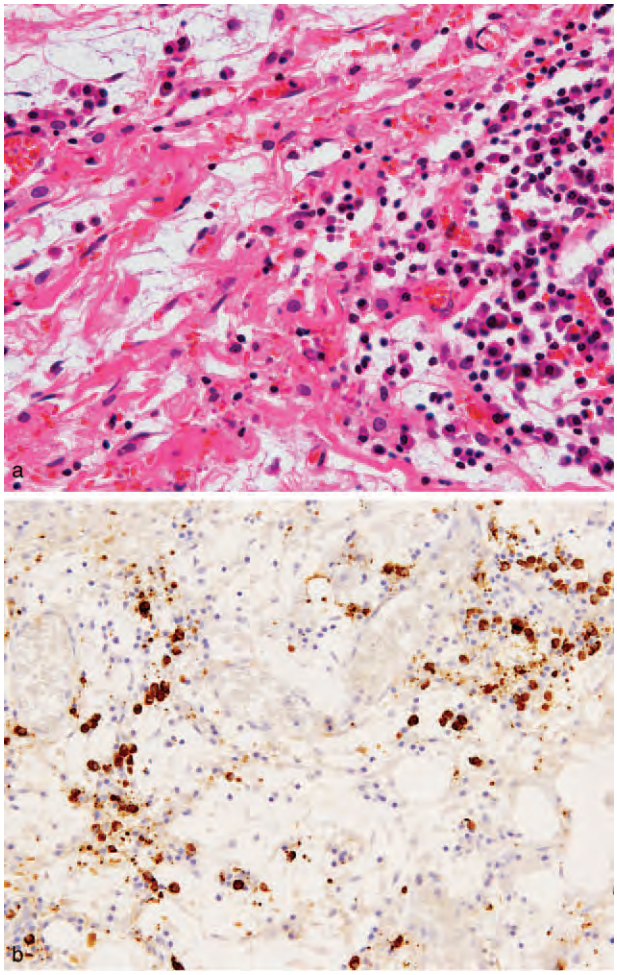

FIGURE 1. (A) Histological findings of the retroperitoneal mass demonstrating marked fibrosis with dense perivascular infiltration of lymphocytes and plasma cells. (hematoxylin and eosin [HE] staining; objective magnification, 40×). (B) IgG4 immunostaining of the retroperitoneal mass demonstrating abundant infiltration of IgG4-positive plasma cells (objective magnification, 20×).

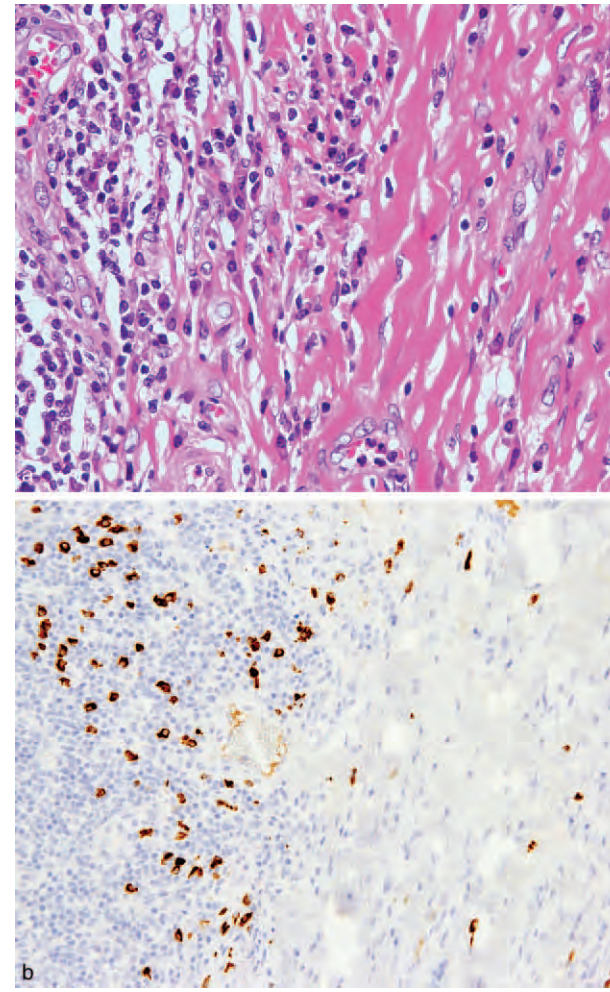

FIGURE 2. (A) Histological findings of the para-aortic LN demonstrating dense fibrosis with infiltration of lymphocytes and plasma cells, implying Type V IgG4-related lymphadenopathy. (HE staining; objective magnification, 40×). (B) IgG4 immunostaining of the para-aortic LN demonstrating abundant infiltration of IgG4-positive plasma cells (objective magnification, 20×). LN = lymph node.

He was treated with steroid therapy for rheumatoid arthritis for another 3 years, and he has been well.

For case 5, a patient with atopic dermatitis, swelling of bilateral cervical, inguinal, and left axillary LNs was found. The biopsied right inguinal LN was diagnosed as DL. He was followed without medication for 5 years, and he was well, although subsequent follow-up was discontinued.

For case 6, a patient with allergic dermatitis, swelling of bilateral inguinal LNs was found. The left inguinal LN was biopsied and diagnosed as DL. She was followed without medication for 9 years, and she has been well.

For case 7, a patient with erythema multiforme, swelling of bilateral inguinal LNs was found. Histological examination of the right inguinal LN showed DL. After 14 months, swelling of the right brachium LN newly appeared. This was biopsied and diagnosed as adult T-cell leukemia/lymphoma on the basis of monoclonal integration of human T-cell lymphotropic virus 1 proviral DNA by Southern blot analysis. He was treated with cyclophosphamide, hydroxydaunorubicin, oncovin, and prednisolone (CHOP therapy). Swelling of LN disappeared, and he has been well for 4 years.

For case 8, a patient with no skin disease, swelling of the left cervical LN was found. The histological diagnosis was DL. He did not receive any medications and was no longer followed.

For case 9, a patient with allergic dermatitis with focal skin Langerhans cell histocytosis who had been treated with steroid therapy for a month, swelling of the right inguinal LN was found. The biopsied right inguinal LN was DL. He was followed and had been well for another 3 months with steroid therapy, although subsequent follow-up was discontinued.

For case 10, a patient with psoriasis vulgaris, swelling of bilateral inguinal LNs was found. The right inguinal LN was biopsied and diagnosed as DL. He was followed for 8 years without medication, and he has been well.

For case 11, a patient with allergic dermatitis, swelling of the left cervical LN was found. This was biopsied and diagnosed as DL. He did not receive any medications and was no longer followed.

Copyright © 2015 Wolters Kluwer Health, Inc. All rights reserved.

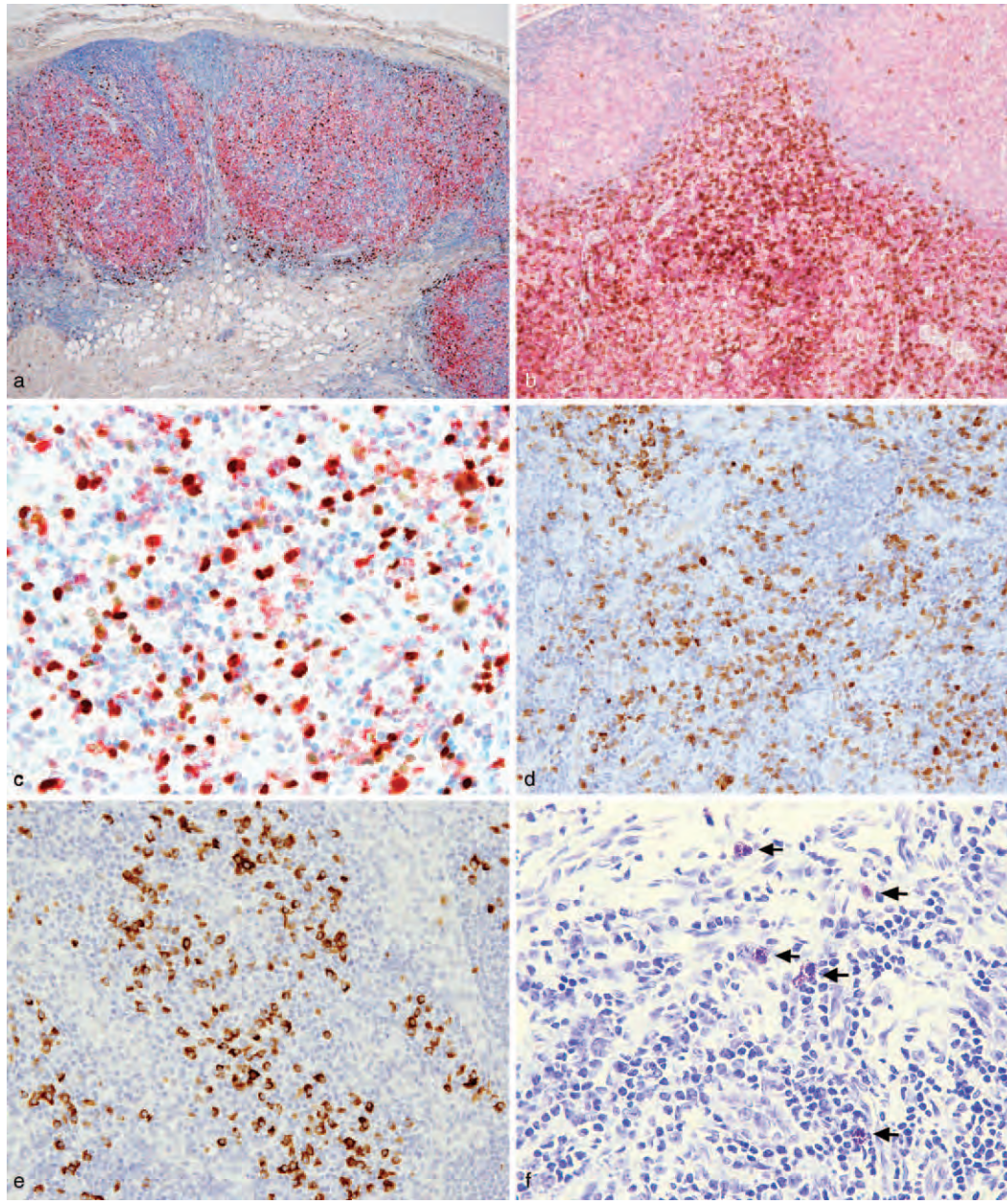

FIGURE 3. Histological analysis of representative LN specimens from DL patients. (A) CD68/S100 protein double immunohistochemical staining. Many S100 protein-positive IDCs and Langerhans cells (red cytoplasm) are observed in the pale-staining areas within the interfollicular areas and paracortex. Macrophages (brown cytoplasm) are mixed among S100 protein-positive cells and have infiltrated the areas surrounding these cells. (b) CD4/CD8 double immunohistochemical staining. Many CD4-positive cells (red cells) and CD8-positive cells (brown cytoplasm) have mainly infiltrated the interfollicular spaces and the areas around the pale-staining areas. (C) FOXP3/CD25 double immunohistochemical staining. Many both FOXP3- (brown nucleus) and CD25-positive (red cytoplasm) Treg cells are also observed. Immunohistochemical staining for (D) IgG and (E) IgG4 in LN with a high ratio of IgG4+/IgG+ cells (case 1). (F) Toluidine blue staining. Some mast cells showing metachromasy (arrow) are scattered within the interfollicular spaces and paracortex in LN (case 2). (G) Immunohistochemical staining for TGF-β in LN with a high ratio of IgG4+/IgG+ cells (case 2). Some TGF-β-positive cells are scattered within the interfollicular spaces and paracortex. (H) FOXP3/TGF-β double immunohistochemical staining. FOXP3-positive (brown nucleus) and TGF-β-positive cells (red cytoplasm) are found separately, and double-positive cells are not observed. (I) Toluidine blue staining and immunohistochemical staining for TGF-β in serial sections. A mast cell (left: arrow) positive for TGF-β (right: arrow). (J) Immunohistochemical staining for IFN-γ. IFN-γ expression is positive in cells in pale-staining areas, including IDCs, Langerhans cells, and macrophages. (K, L, and M) Immunohistochemical staining for MMP-1, MMP-8, and MMP-13. Macrophages are positive for (K) MMP-1, (L) MMP-8, and (M) MMP-13. Note that many cells in the pale-staining areas are negative for these MMPs. (A, objective magnification, 4×; B, objective magnification, 10×; C, F, G, J, K, L, M, objective magnification, 40×; D, E, objective magnification, 20×; H, I, objective magnification, 100×). DL = dermatopathic lymphadenopathy, IFN = interferon, LN = lymph node, MMP = matrix metalloproteinase, TGF = transforming growth factor.

Copyright © 2015 Wolters Kluwer Health, Inc. All rights reserved.

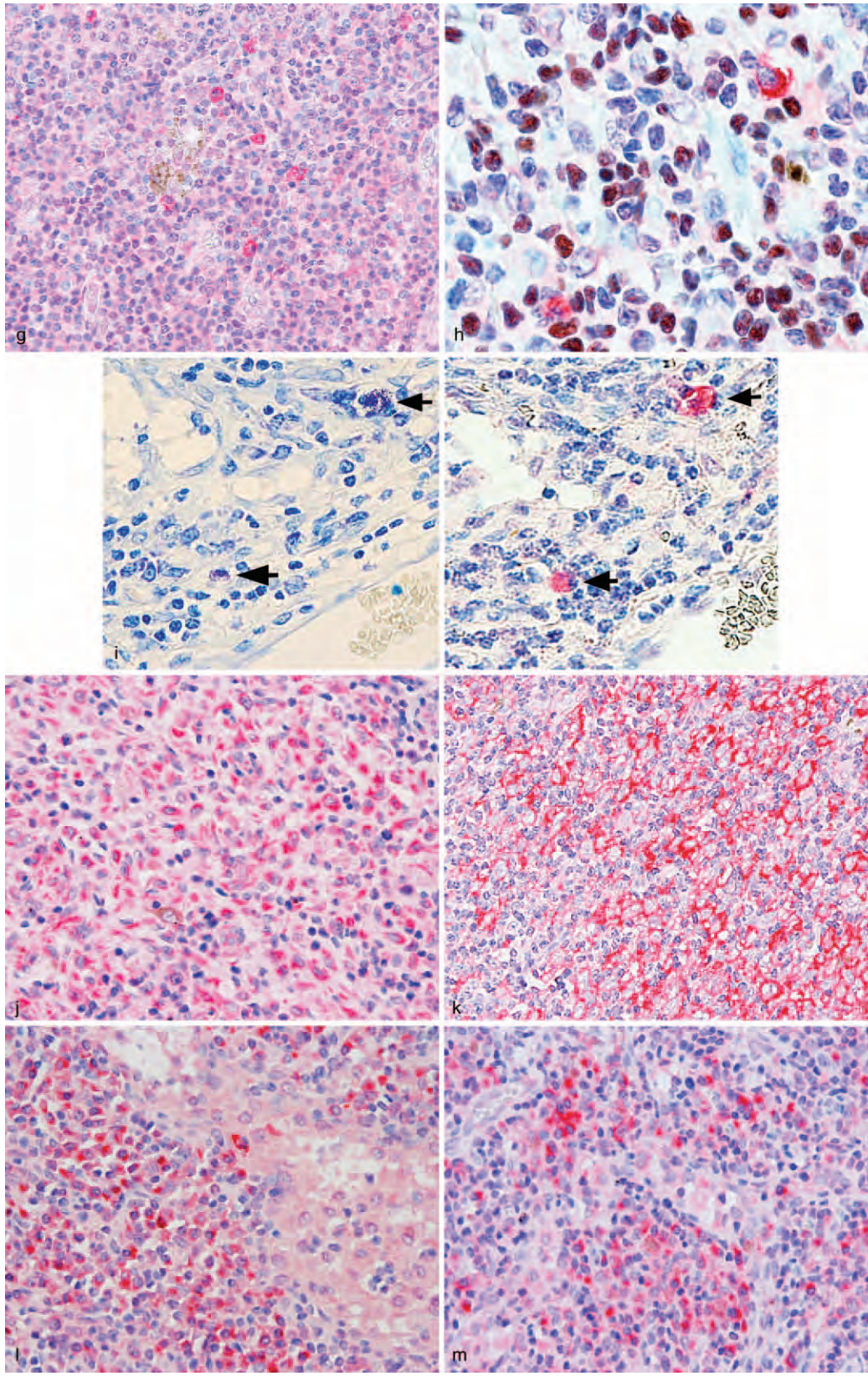

FIGURE 3. (Continued)

Copyright © 2015 Wolters Kluwer Health, Inc. All rights reserved.

Histological and Immunohistochemical Results for LNs of DL

Nodular expansion of the interfollicular spaces and paracortex by confluent pale-staining areas composed of numerous Langerhans cells that were both S100 protein- and CD1a-positive and IDCs that were S100 protein-positive but CD1a-negative were seen. CD68-positive macrophages were mixed among IDCs and Langerhans cells and accumulated around the pale-staining areas (Figure 3A). Some melanin granule-containing macrophages were scattered in all LNs. Many reactive small lymphocytes, particularly CD4-positive T cells that outnumbered CD8-positive T cells, had infiltrated the interfollicular spaces and paracortex (Figure 3B). FOXP3/CD25 double-positive Treg cells were also observed in these areas (Figure 3C). In some LNs, IgG+ or IgG4+ plasma cells had infiltrated the interfollicular spaces and paracortex.

The 11 DL patients were divided into 2 groups on the basis of the grade of infiltration of IgG4+ cells: 3 with a high ratio (>40%) of IgG4+/IgG+ cells and 8 with a low ratio (<40%) of IgG4+/IgG+ cells or no infiltration of IgG4+ cells. LNs of cases 1, 2, and 3 had high ratios of IgG4+/IgG+ cells at 62.8%, 65.3%, and 52.7%, respectively (Figure 3D and E). LNs of cases 4 to 11 had 0% to 2.9% (mean 1.4%) of IgG4+/IgG+ cells (Table 1). Sclerosis and phlebitis were not observed in any LNs, regardless of a high or low ratio of IgG4+/IgG+ cells. Some mast cells were scattered within the interfollicular spaces and paracortex of LNs (for all 11 LNs, mean of $4.46 \pm 4.65/mm^2$), and the mean number of mast cells/mm^2 was significantly higher in the group with a high ratio of IgG4+/IgG+ cells ($10.31 \pm 1.66/mm^2$; Figure 3F) than in the group with a low ratio of IgG4+/IgG+ cells or no infiltration of IgG4+ cells ($2.26 \pm 1.02/mm^2$; $P = 0.0025$; Table 1 and Figure 4A).

Some TGF-β-positive cells were scattered in LNs of both groups (for all 11 LNs, mean of $5.22 \pm 5.16/mm^2$), and there was a significantly higher infiltration of TGF-β-positive cells in the group with a high ratio of IgG4+/IgG+ cells ($12.00 \pm 1.68/mm^2$; Figure 3G) than in the group with a low ratio of IgG4+/IgG+ cells or no infiltration of IgG4+ cells ($2.68 \pm 1.03/mm^2$; $P = 0.0011$; Table 1 and Figure 4B). The number of TGF-β-positive cells was much lesser than that of FOXP3/CD25 double-positive regulatory T cells (Treg cells). Moreover, FOXP3/TGF-β3 double staining revealed that TGF-β-positive cells were different from FOXP3-positive cells and there were no FOXP3/TGF-β double-positive cells (Figure 3H). The distribution and population of TGF-β-positive cells were similar to those of mast cells, and in serial sections, mast cells appeared to be positive for TGF-β (Figure 3I). IFN-γ expression was positive for IDCs, Langerhans cells, and macrophages in addition to a small number of lymphocytes (Figure 3J). MMP-1, MMP-8-, or MMP-13-positive macrophages were also observed in LNs (Figure 3K, L, M).

DISCUSSION

DL is a benign histopathological disease associated with skin diseases. Although a patient's history and clinical examination could raise a suspicion, histological examination of biopsied LNs is mandatory for the diagnosis of DL. Dermatopathic LNs are characterized by infiltrations of IDCs, Langerhans cells, macrophages, melanin granule-laden macrophages, and T cells.[3] After Langerhans cells are exposed to antigens in the skin, they migrate to regional LNs where they interact with CD4-positive helper T cells to present antigen and initiate an immune response in conjunction with IDCs and macrophages. This series of immune reactions can be induced by destruction of the epidermis, inflammatory cytokines, and other agents, including bacterial components.[14]

On the contrary, IgG4-RD is likely autoimmune in nature and a fibroinflammatory disorder that involves various organs and tissues. The proposed diagnostic criteria are as follows: clinical examination showing characteristic diffuse/localized swelling or masses in single or multiple organs; elevated serum IgG4 levels (≥135 mg/dL); and histological findings of marked infiltration of lymphocytes and plasma cells, >10 IgG4+ cells/HPF, a ratio of IgG4+/IgG+ plasma cells of >40%, and fibrosis.[15,16] The pathogenesis of this disease, including IgG4 involvement, has not been elucidated.

Fibrosis is an important histological finding for the diagnosis of IgG4-RD. Although the mechanism underlying fibrosis development also remains unclear, the growth factor TGF-β is known to play an important role in fibrosis via its effects on the

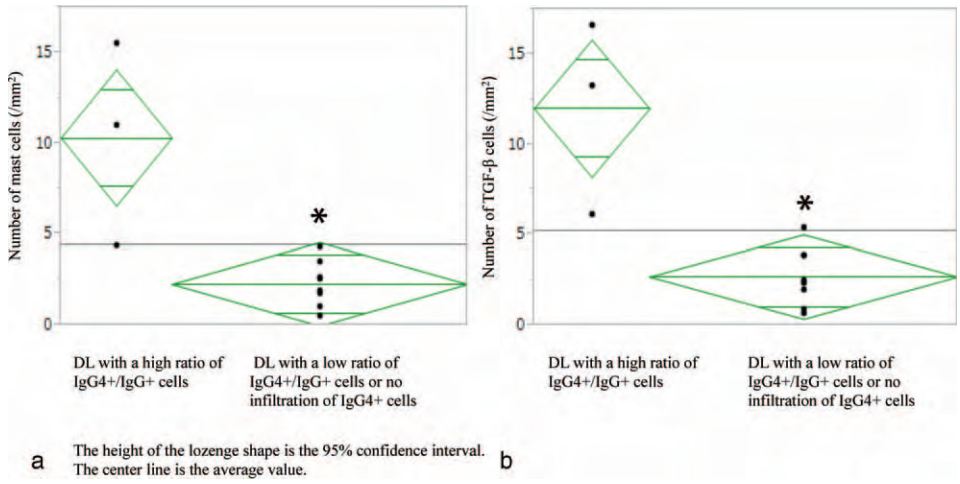

FIGURE 4. Numbers of (A) mast cells and (B) TGF-β-positive cells/mm^2 in DL patients with a high ratio of infiltrating IgG4+ plasma cells to IgG+ cells (IgG4+/IgG+ cells) and in DL patients with a low ratio of IgG4+/IgG+ cells or no infiltration of IgG4+ cells. The numbers of both cell types are greater in DL with a high ratio of IgG4+/IgG+ cells than in DL with a low ratio of IgG4+/IgG+ cells or no infiltration of IgG4+ cells. $^*P < 0.05$. DL = dermatopathic lymphadenopathy, TGF = transforming growth factor.

Copyright © 2015 Wolters Kluwer Health, Inc. All rights reserved.

proliferation of fibroblasts in IgG4-RD.[17] Infiltration of FOXP3/CD25 double-positive Treg cells that release TGF-β has been thought to be related to fibrosis in affected sites.[6] However, it has been recently reported that mast cells but not Treg cells at the affected sites produce TGF-β and play a role in fibrosis in IgG4-RD.[18]

In the present study, three of 11 cases (27%) showed infiltration by a large number of IgG4-positive cells and a high ratio of IgG4+/IgG+ cells of >40%. Except for no fibrosis, these 3 cases met the criteria for IgG4-RD: swelling of organs (LNs), elevated serum IgG4 levels (>135 mg/dL), a ratio of IgG4+/IgG+ cells of >40%, and >10 IgG4+ cells/HPF. Our findings also suggested that mast cells and not Treg cells produced TGF-β on the basis of the following histological findings: FOXP3-positive cells were negative for TGF-β with FOXP3/TGF-β double staining; the population and location of mast cells were similar to those of TGF-β-positive cells; and mast cells appeared to be identical to TGF-β-positive cells in serial sections. The number of mast cells and TGF-β-positive cells was significantly increased in the group of DL patients with a high ratio of IgG4+/IgG+ cells than that in the group of patients with a low ratio of IgG4+/IgG+ cells or no infiltration of IgG4+ cells. However, despite these findings, fibrosis characteristic of extranodal IgG4-RD was not observed in both these groups.

Fibrogenesis is known to be inhibited by IFN-γ and MMPs. IFN-γ can inhibit fibroblast proliferation and reduce extracellular matrix deposition.[19] IFN-γ is produced by TH1 cells, a subgroup of CD4-positive helper T cells, and antigen-presenting cells such as monocytes/macrophages and dendritic cells, the main cellular components of LNs of DL.[20,21] Among MMPs, a family of zinc-dependent proteases, MMP-1, MMP-8, and MMP-13 are classified as collagenases that play essential roles in breaking down components of the extracellular matrix and participate in collagen degradation.[22] Macrophages have been known to produce these MMPs.[23–25] Therefore, we performed immunostaining of IFN-γ and MMPs 1, 8, and 13 on LNs of DL patients. As a result, in addition to a small number of lymphocytes, many IDCs, Langerhans cells, and macrophages were positive for IFN-γ, and macrophages were positive for MMP-1, MMP-8, or MMP-13 in LNs of DL. Thus, these findings indicate that the lack of fibrosis in LNs of DL with a high ratio of IgG4+/IgG+ cells might be a result of IFN-γ and MMPs produced by IDCs, Langerhans cells, and macrophages.

DL is considered as benign and requires no intervention. In the present study, of 8 patients with a low ratio of IgG4+/IgG+ cells or no infiltration of IgG4+ cells, 5 who could be followed did not develop IgG4-RD within the follow-up periods. In contrast, of 3 cases of DL with a high ratio of IgG4+/IgG+ cells, one became complicated with retroperitoneal fibrosis at a month after the diagnosis of DL, whereas another developed IgG4-lymphadenopathy at 5 months after the diagnosis of DL.

Because IgG4-RD is systemic and progressive, a timely diagnosis is necessary. Without appropriate treatment, this disease will progress and result in a loss of function of potentially any exocrine gland as well as local destruction because of mass-forming lesions and fibrosis. Therefore, in cases without clinical and characteristic morphological features at the time of diagnosis, the presence of excess of IgG4-positive plasma cells in LNs of DL may be non-specific and this finding should not prompt treatment initiation in these patients.[26] The findings of the present study suggest that pathologists, hematologists, and dermatologists need to recognize DL with increased IgG4-positive plasma cells and carefully conduct follow-up of these DL patients to ensure timely treatment initiation in the event of future development of IgG4-RD. For further characterization, additional studies with larger sample sizes are required.

ACKNOWLEDGMENTS

None.

REFERENCES

1. Huwitt E. Dermatopathic lymphadenitis: focal granulomatous lymphadenitis associated with chronic generalized skin disorder. *J Invest Dermatol.* 1942;5:197–204.
2. Ioachim HL, Medeiros LJ. Dermatopathic lymphadenopathy. *Ioachim's Lymph Node Pathology*. Philadelphia: Lipincott Company; 2009:223–226.
3. Cooper RA, Dawson PJ, Rambo ON. Dermatopathic lymphadenopathy a clinicopathologic analysis of LN biopsy over a fifteen-year period. *Calif Med.* 1967;106:170–175.
4. Gould E, Porto R, Albores-Saavedra J, et al. Dermatopathic lymphadenitis. The spectrum and significance of its morphologic features. *Arch Pathol Lab Med.* 1988;112:1145–1150.
5. Kamisawa T, Nakajima H, Egawa N, et al. IgG4-related sclerosing disease incorporating sclerosing pancreatitis, cholangitis, sialadenitis and retroperitoneal fibrosis with lymphadenopathy. *Pancreatology.* 2006;6:132–137.
6. Stone JH, Zen Y, Deshpande V. IgG4-related disease. *N Engl J Med.* 2012;366:539–551.
7. Hamano H, Arakura N, Muraki T, et al. Prevalence and distribution of extrapancreatic lesions complicating autoimmune pancreatitis. *J Gastroenterol.* 2006;41:1197–1205.
8. Cheuk W, Yuen HK, Chu SY, et al. Lymphadenopathy of IgG4-related sclerosing disease. *Am J Surg Pathol.* 2008;32:671–681.
9. Cheuk W, Chan JK. Lymphadenopathy of IgG4-related disease: an underdiagnosed and overdiagnosed entity. *Semin Diagn Pathol.* 2012;29:226–234.
10. Sato Y, Notohara K, Kojima M, et al. IgG4-related disease: historical overview and pathology of hematological disorders. *Pathol Int.* 2010;60:247–258.
11. Aalberse RC, Van Milligen F, Tan KY, et al. Allergen-specific IgG4 in atopic disease. *Allergy.* 1993;48:559–569.
12. Rock B, Martins CR, Theofilopoulos AN, et al. The pathogenic effect of IgG4 autoantibodies in endemic pemphigus foliaceus (fogo selvagem). *N Eng J Med.* 1989;320:1463–1467.
13. Sitaru C, Mihai S, Zillikens D. The relevance of the IgG subclass of autoantibodies for blister induction in autoimmune bullous skin diseases. *Arch Drmatol Res.* 2007;299:1–8.
14. O'Malley DP, George TI, Orazi A, Abbondanzo SL. Dermatopathic lymphadenitis. In Atlas of benign and reactive conditions of LN and spleen. AFIP ARP Press, Washington DC, pp143-145.
15. Deshpande V, Zen Y, Chan JK, et al. Consensus statement on the pathology of IgG4-related disease. *Mod Pathol.* 2012;25:1181–1192.
16. Umehara H, Okazaki K, Masaki Y, et al. Comprehensive diagnostic criteria for IgG4-related disease (IgG4-RD), 2011. *Mod Rheumatol.* 2012;22:21–30.
17. Detlefsen S, Sipos B, Zhao J, et al. Autoimmune pancreatitis: expression and cellular source of profibrotic cytokines and their receptors. *Am J Surg Pathol.* 2008;32:986–995.
18. Takeuchi M, Sato Y, Ohno K, et al. T helper 2 and regulatory T-cell cytokine production by mast cells: a key factor in the pathogenesis of IgG4-related disease. *Mod Pathol.* 2014;27:1126–1136.
19. Narayanan AS, Whithey J, Souza A, et al. Effect of gamma-interferon on collagen synthesis by normal and fibrotic human lung fibroblasts. *Chest.* 1992;101:1326–1331.

Copyright © 2015 Wolters Kluwer Health, Inc. All rights reserved.

20. Frucht DM, Fukao T, Bogdan C, et al. IFN-gamma production by antigen-presenting cells: mechanisms emerge. *Trends Immunol.* 2001;22:556–560.
21. Gessani S, Belardelli F. IFN-gamma expression in macrophages and its possible biological significance. *Cytokine Growth Factor Rev.* 1998;9:117–123.
22. Murphy G, Nagase H. Progress in matrix metalloproteinase research. *Mol Aspects Med.* 2008;29:290–308.
23. Fallowfield JA, Mizuno M, Kendall TJ, et al. Scar-associated macrophages are a major source of hepatic matrix metalloproteinase-13 and facilitate the resolution of murine hepatic fibrosis. *J Immunol.* 2007;178:5288–5295.
24. Van Lint P, Libert C. C Matrix metalloproteinase-8: cleavage can be decisive. *Cytokine Growth Factor Rev.* 2006;17:217–223.
25. Sukhova GK, Schönbeck U, Rabkin E, et al. Evidence for increased collagenolysis by interstitial collagenases-1 and -3 in vulnerable human atheromatous plaques. *Circulation.* 1999;99:2503–2509.
26. Martinez LL, Friedländer E, van der Laak JA, et al. Abundance of IgG4+ plasma cells in isolated reactive lymphadenopathy is no indication of IgG4-related disease. *Am J Clin Pathol.* 2014;142:459–466.

Copyright © 2015 Wolters Kluwer Health, Inc. All rights reserved.