Patient Oriented Problem Solving (POPS) Case Report

Recurrent fevers and failure to thrive in an infant

David R. Scott, M.D.,[1] Sarah Chan,[2] Johanna Chang, M.D.,[3,4] Lori Broderick, M.D., Ph.D.,[3] and Hal M. Hoffman, M.D.[3,4,5]

ABSTRACT

We describe a 2-year old boy with consanguineous parents who recently emigrated from India and presented with oral ulcers and lymphadenopathy. He also had a history of recurrent fevers, polyarticular arthritis, chronic diarrhea, failure to thrive, and developmental delay. Infectious workup revealed herpes simplex virus 1 viremia and radiological evaluation revealed osteopenia and erosions involving multiple joints. We describe the immunologic and genetic evaluation of this patient and discuss the diagnostic and therapeutic approach to an infant with recurrent fevers.

(Allergy Asthma Proc 34:473–479, 2013; doi: 10.2500/aap.2013.34.3672)

CASE PRESENTATION

S. Chan and D.R. Scott contributed equally to this work.

Chief Complaint

Recurrent fevers in a patient with oral ulcers, chronic diarrhea, and failure to thrive.

History of Present Illness

Our patient is a 2-year old Indian boy who presented with 5 days of aphthous ulcers and generalized lymphadenopathy. History revealed chronic recurrent fevers, diarrhea, polyarticular arthritis, global developmental delays, and failure to thrive. He had debilitating deformities of the elbows, wrists, and knees and was unable to crawl, stand, or walk. Laboratory analysis revealed a leukocytosis, microcytic anemia, thrombocytopenia, and elevated acute-phase reactants. The allergy and immunology service was consulted for evaluation of his unexplained recurrent fevers.

Medical History

The patient was born in India at full term by C-section complicated by NICU admission for meconium aspiration. At 44 days of life he developed intermittent fevers and diarrhea without an identified etiology. At 2 months of age he was admitted to a hospital in India with fever, diarrhea, and progressive swelling of multiple joints, including bilateral elbows, wrists, ankles, and proximal interphalangeal joints of the fingers. Ultrasound suggested multifocal osteomyelitis involving the upper and lower extremities. Bone biopsy revealed sterile pyogenic osteomyelitis. All synovial fluid and bone cultures remained negative and no infectious etiology was identified. He was discharged with an extended course of empiric broad-spectrum antibiotics with minimal improvement.

At 9 months of age, he began to manifest recurrent fevers to 103°F, initially occurring every 6 hours, but subsequently decreasing in frequency to every 3 days, which persisted until the time of his presentation. Fevers occurred without associated symptoms other than irritability and decreased energy. No diagnosis was identified and he was treated symptomatically with paracetamol.

The patient received his routine childhood vaccinations according to the Indian vaccination schedule, including a bacille Calmette-Guérin vaccine with no abnormal immunization reactions. He had no history of recurrent infections, including no previous pneumonia or sinusitis.

Social History

The patient was born and raised in southern India and moved to San Diego, CA, with his parents 2 months before presentation. He had no other siblings.

Family History

There was no family history of recurrent fevers, immunodeficiency, early childhood deaths, or develop-

From the [1]Scripps Clinic, Department of Medicine, San Diego, California, [2]University of California-San Diego School of Medicine, San Diego, California, [3]Department of Medicine, University of California–San Diego, San Diego, California, [4]Department of Pediatrics, University of California–San Diego and Rady Children's Hospital, San Diego, California, and [5]San Diego Branch, Ludwig Institute of Cancer Research, La Jolla, California

HM Hoffman has a financial conflict of interest with SOBI, the manufacturer of anakinra. The remaining authors have no conflicts of interest to declare pertaining to this article

Address correspondence and reprint requests to David R. Scott, M.D., Scripps Clinic, 8311 Valley Centre Drive, S99, San Diego, CA, 92130
E-mail address: deardrscott@gmail.com

Copyright © 2013, OceanSide Publications, Inc., U.S.A.

DO NOT COPY

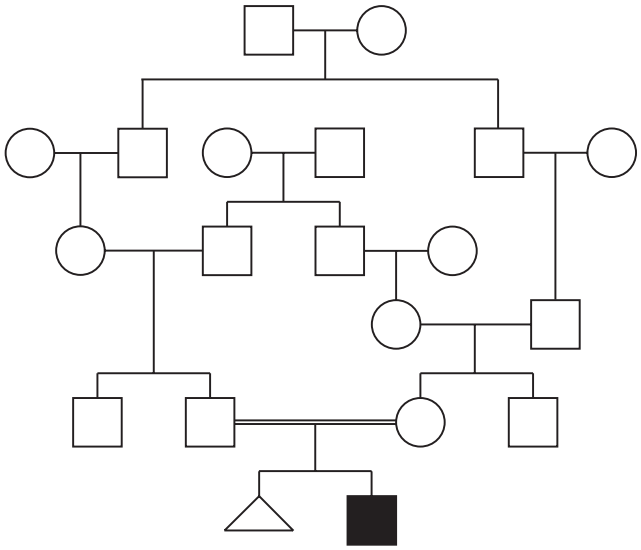

Figure 1. Family pedigree revealing multiple levels of parental consanguinity. No other family members were affected, but there was a history of prior miscarriage, indicated by triangle. Shaded box designates our patient. Double connecting line indicates consanguinity.

Figure 2. Facial structure of the patient showing frontal bossing characteristic of mevalonate kinase deficiency (M).

mental delays. His parents were both healthy without any medical problems. However, family history was notable for consanguinity over multiple generations and one prior miscarriage (Fig. 1). His mother's maternal grandfather and father's father are brothers and his mother's paternal grandfather and father's maternal grandfather are also brothers.

Physical Examination

On initial evaluation, he was irritable but consolable by his mother, with weight at the 0.1 percentile for age. On physical exam, he appeared thin and small with frontal bossing (Fig. 2). His exam was notable for an open anterior fontanelle, submandibular and cervical lymphadenopathy, and palpable hepatosplenomegaly. His oropharynx showed multiple ulcerative lesions. His extremities revealed hypotonia; rocker bottom feet; and swelling of the ankles, elbows, and proximal interphalangeal joints of some fingers (Fig. 3).

Laboratory and Other Diagnostic Findings

The initial laboratory and diagnostic evaluation is summarized in Table 1. Skeletal survey indicated an Erlenmeyer flask appearance of the long bones and a pointed appearance of the proximal metacarpals (Fig. 4).

QUESTIONS

What Is the Differential Diagnosis?

The differential diagnosis for chronic relapsing fevers in an infant is broad, including immunodeficiency, chronic infection, autoimmune diseases, autoinflammatory disease, and malignancy (Table 2). The presence of systemic multitissue inflammation with previous negative infectious workup was most suggestive of an autoinflammatory illness. Furthermore, his early onset multisystem involvement and severe developmental delay pointed toward an inherited syndrome.

What Additional Laboratory Data or Investigations Would Be Most Helpful in Arriving at a Diagnosis in This Patient?

a. Bone marrow biopsy
b. T-cell function studies
c. *NLRP3* gene mutational analysis
d. Serum IgD level
e. *Mevalonate kinase* (*MVK*) gene mutational analysis

Genetic testing for *MVK* gene mutations would be confirmatory for mevalonate kinase deficiency (MKD). Serum IgD levels may be measured, but lack sensitivity and, unless extremely elevated, are not specific for MKD.[1–3] Workup to help rule out other inborn errors of metabolism would include plasma and urine amino acid levels, urine organic acids, and plasma acylcarnitine profile. Lymph node biopsy and bone marrow biopsy would be appropriate to exclude malignancy or myelodysplastic syndrome, although these would be less likely in this patient.

DO NOT COPY

Figure 3. Photographs of the patient revealing swelling of elbows and proximal interphalangeal joints of some fingers, as well as rocker bottom feet and swelling of the ankles. Scars from previous surgical incisions can also be seen.

DO NOT

Clinical Course

The patient was diagnosed with acute primary herpes simplex virus (HSV) 1 infection by peripheral blood polymerase chain reaction and was treated with acyclovir. His infectious workup remained otherwise unremarkable and no immunodeficiency was identified. It was concluded that his HSV-1 infection was unrelated to his underlying chronic illness.

Bone marrow biopsy showed a normal karyotype with no cytogenetic abnormalities, marrow failure, storage disease, or malignancy. Flow cytometry did not reveal any immunophenotypic abnormalities suggestive of a cellular immunodeficiency.

Quantitative immunoglobulins revealed elevated IgG, IgA, and IgM. However, serum IgD levels were normal at 21 mg/L (reference range, <179 mg/L). Urine organic acids obtained while he was symptomatic showed an elevation in mevalonic acid to 10 mmol/mol creatinine (reference range, 0–2).

The patient was started on anakinra at 3-mg/kg injections daily for suspected hyper-IgD syndrome (HIDS) or MVA with resolution of fevers within 24 hours and decreased joint swelling within 4 days. Genetic analysis confirmed a homozygous mutation of the *MVK* gene at position 1162 C>T within exon 10, resulting in a stop codon (C → T) at amino acid position 388.

With 10 months of anakinra, he has experienced marked clinical improvement, including increased weight gain, resolution of diarrhea, improved appetite,

Table 1 **Laboratory evaluation and studies**

Laboratory	Result (normal range)	Other Diagnostic Evaluation	
Immunoglobulins		Infectious Disease Evaluation	
IgG	2100 mg/dL (413–1112)	Hepatitis B Surface Ag	Negative
IgA	300 mg/dL (21–117)	Hepatitis B Core IgM	Negative
IgM	253 mg/dL (30–146)	Hepatitis C IgG Ab	Negative
IgD	21 mg/dL (0–179)	HIV-1/HIV-2 Ab	Negative
IgE	524 kU/L (0–12.0)	CMV IgG	Positive
Urine organic acids		CMV IgM	Negative
Mevalonic acid	10 (0–2)	EBV IgG/IgM	Negative
Suberic acid	15 (0–7)	Peripheral blood HSV PCR	Positive, type 1
Hematologic		Blood bacterial culture	Negative
WBC	14 K/uL (4.0–12.0)	Blood fungal culture	Negative
Neutrophils	6.05 K/uL (1.5–5.5)		
Lymphocytes	6.7 K/uL (2.0–5.8)	Pathology	
Hemoglobin	5.5 GM/dL (11.5–14.5)	Axillary lymph node	Reactive follicular lymphoid hyperplasia with sinus histiocytosis
MCV	68.2 fL (76.0–90.0)		
Platelets	80 K/uL (140–440)		
Inflammatory markers			
ESR	>140 millimeter (0–15)	Imaging	
CRP	84 mg/L (0.0–09.9)	MRI Brain	Moderate diffuse cerebral, cerebellar and brainstem volume loss with ventriculomegaly
Chemistry			
Alk phosphatase	381 U/L (145–320)		
Total Protein	9.0 g/dL (5.9–7.0)		
AST	832 U/L (20–60)	CT neck/abdomen and pelvis	Hepatosplenomegaly and lymphadenopathy of the neck, pelvic sidewalls and inguinal area
ALT	913 U/L (5–45)		
Total bilirubin	0.6 mg/dL (0.1–1.0)		
Complement			
C3	270 mg/dL (58–119)	Skeletal survey	Osteopenia, flaring of metaphyses with inflammatory changes in the periosteum and joint destruction
C4	39 mg/dL (17–48)		

WBC = white blood cell count; MCV = ; ESR = ; CRP = ; MRI = magnetic resonance imaging; HIV = ; CMV = ; EBV = ; HSV = herpes simplex virus; PCR = polymerase chain reaction; CT = computed tomography.

DO NOT COPY

Figure 4. Skeletal survey indicating diffuse osteopenia with an Erlenmeyer flask appearance of the long bones of the (A) arm, forearm and (C) femur. (B) The distal margin of the ulna is eroded and the radial head is dislocated. (B) The hands reveal expansion of the medullary cavity of the metacarpals and phalanges and a pointed appearance of the proximal metacarpals. (D) The feet and ankles reveal osteopenia and loss of volume of the talus with associated soft tissue swelling.

DO NOT COPY

and improved functional status. However, despite his clear clinical response to anakinra, he continues to have intermittent low-grade fevers and persistent elevation in his white blood cell count, CRP, ESR, and ferritin.

DISCUSSION

The constellation of findings including recurrent fevers, diarrhea, hepatosplenomegaly, developmental delay, arthritis, and failure to thrive was consistent with MKD and the presence of *MVK* mutations confirmed this diagnosis. MKD is a rare autosomal recessive disorder characterized by mutation of the *MVK* gene resulting in impaired activity of the enzyme MVK.[4–6] MVK catalyzes the conversion of mevalonic acid to 5-phosphomevalonate in the HMG-CoA reductase pathway, which results in the synthesis of isoprenoids, including non–sterol isoprenoids and sterols, such as cholesterol.[7] HIDS and MVA both result from *MVK* mutations and are distinguished based on residual enzyme activity, with HIDS typically associated with between 1 and 7% and MVA associated with <1% residual enzyme activity.[8–10] Although febrile attacks in MKD are often precipitated by immunizations, this was not observed in our patient.[2]

The pathophysiologic link between MVK dysfunction and observed clinical findings remains poorly defined.[6] It is thought that the dysregulation of the isoprenoid pathway may play a role by increasing proinflammatory cytokine, IL-1β secretion, although the precise mechanism is unclear. One postulated mechanism is that a shortage of non–sterol isoprenoid end products causes increased IL-1β secretion by peripheral blood mononuclear cells.[11]

Our patient's *MVK* mutation (R388X) is predicted to result in a truncated protein missing the last nine amino acids. This is the first case of documented homozygous R388X mutation. There are three previously

Table 2 **Defining characteristics of periodic fever syndromes considered in the differential diagnosis**

Condition	Fevers	Arthralgias	Destructive Arthritis	FTT	Developmental Delay	Dysmorphic	LAD	HSM	Cytopenias	↑ WBC	Autosomal Recessive
CAPS											
FCAS	◆	◆								◆	
MWS	◆	◆								◆	
NOMID	◆	◆	◆	◆	◆	◆	◆	◆		◆	
Other periodic fever syndromes											
TRAPS	◆	◆	◆							◆	
FMF	◆	◆					◆			◆	◆
MVA	◆	◆	±	◆	◆	◆	◆	◆		◆	◆
HIDS	◆	◆		±		±	◆	◆		◆	◆
PAPA	◆	◆	◆								
PFAPA	◆										
Other											
Malignancy	◆	◆		◆			◆	◆	◆	◆	
Myelodysplastic syndrome				◆			◆	◆	◆		
Chronic infection											
Bacterial	◆	◆		◆			◆	◆	◆	◆	
Tuberculosis	◆	◆		◆			◆	◆		◆	
Other fungal	◆	◆		◆			◆			◆	

CAPS = Cryopyrin-associated periodic syndromes; FTT = failure to thrive; LAD = lymphadenopathy; HSM = hepatosplenomegaly; FCAS = familial cold autoinflammatory syndrome; MWS = Muckle-Wells syndrome; NOMID = neonatal onset multisystem inflammatory disease; TRAPS = tumor necrosis factor receptor 1–associated periodic syndrome; FMF = familial Mediterranean fever; MVA = mevalonic aciduria; HIDS = hyper-IgD syndrome; PAPA = syndrome of pyogenic arthritis, pyoderma gangrenosum acne; PFAPA = periodic fever, aphthous stomatitis, pharyngitis, adenitis syndrome.

DO NOT COPY

published cases of heterozygous *MVK* mutations containing the R388X mutant allele.[7,6,12] One of these patients expressed a milder (V377I) mutation on the corresponding allele and had 4% residual MVK activity and a clinical phenotype consistent with HIDS.[7,6] The other two reported patients expressed more severe mutations on their corresponding alleles, I268T and G309S, with corresponding residual MVK activity of 0.7 and 0%, respectively.[12] Although we were unable to quantify residual MVK enzyme activity in this patient, one would anticipate it to be near undetectable.

Autoinflammatory disorders with some overlap in clinical presentation with our patient include neonatal onset multisystem inflammatory disorder or tumor necrosis factor receptor 1–associated periodic syndrome. To investigate the presence of either syndrome we performed sequencing of exon 3 of the *NLRP3* gene and exons 4 and 5 of the tumor necrosis factor receptor superfamily member 1A gene that did not reveal a mutation in either region.

Therapy for MKD remains poorly defined and is largely based on case reports. Reduction in the number of febrile crises has been shown with various immunomodulatory medications, including prednisone, etanercept (a tumor necrosis factor α inhibitor) and anakinra (an IL-1 receptor antagonist).[13–16] Bone marrow transplant has also been used.[17] Our patient showed improvement in joint swelling and mobility on anakinra, in addition to weight gain and fewer and milder febrile episodes.

Final Diagnosis

The final diagnosis was MKD.

SUMMARY AND CONCLUSIONS

Our patient with severe MKD represents the first case of a documented homozygous recessive R388X mutation. This case highlights the systemic inflammatory nature of this disease. MKD should be considered in any pediatric patient presenting with recurrent fevers, diarrhea, lymphadenopathy, polyarthralgia, and splenomegaly. Diagnostic investigation should include urinary organic acid levels and genetic testing for *MVK* mutations. This case also illustrates the importance of a thorough family history and serves as a reminder that parental consanguinity can be commonplace in some cultures. This patient's dramatic improvement with anakinra is also noteworthy and provides additional insight into the treatment of this rare condition.

REFERENCES

1. Houten SM, Kuis W, Duran M, et al. Mutations in *MVK*, encoding mevalonate kinase, cause hyperimmunoglobulinaemia D and periodic fever syndrome. Nat Genet 22:175–177, 1999.
2. Drenth JP, Haagsma CJ, and van der Meer JW. Hyperimmunoglobulinemia D and periodic fever syndrome. The clinical spectrum in a series of 50 patients. Medicine 73:133–144, 1994.
3. Medlej-Hashim M, Petit I, Adib S, et al. Familial Mediterranean Fever: association of elevated IgD plasma levels with specific MEFV mutations. European Journal of Human Genetics 9:849–854, 2001.
4. Hoffmann G Gibson KM, Brandt IK, et al. Mevalonic aciduria–an inborn error of cholesterol and nonsterol isoprene biosynthesis. N Engl J Med 314:1610–1614, 1986.
5. Drenth JP, Cuisset L, Grateau G, et al. Mutations in the gene encoding mevalonate kinase cause hyper-IgD and periodic fever syndrome. Nat Genet 22:178–181, 1999.
6. Frenkel J, Houten SM, Waterham HR, et al. Clinical and molecular variability in childhood periodic fever with hyperimmunoglobulinaemia D. Rheumatology (Oxford) 40:579–584, 2001.
7. Houten SM, Wanders RJ, and Waterham HR. Biochemical and genetic aspects of mevalonate kinase and its deficiency. Biochim Biophys Acta 1529:19–32, 2000.
8. Houten SM, Frenkel J, Rijkers GT, et al. Temperature dependence of mutant mevalonate kinase activity as a pathogenic factor in hyper-IgD and periodic fever syndrome. Hum Mol Genet 11:3115–3124, 2002.
9. Hoffmann GF, Charpentier C, Mayatepek E, et al. Clinical and biochemical phenotype in 11 patients with mevalonic aciduria. Pediatrics 91:915–921, 1993.
10. Simon A, Kremer HP, Wevers RA, et al. Mevalonate kinase deficiency: Evidence for a phenotypic continuum. Neurology 62:994–997, 2004.
11. Mandey SH, Kuijk LM, Frenkel J, and Waterham HR. A role for geranylgeranylation in interleukin-1β secretion. Arthritis Rheum 54:3690–3695, 2006.
12. Bader-Meunier B, Florkin B, Sibilia J, et al. Mevalonate kinase deficiency: A survey of 50 patients. Pediatrics 128:e152–e159, 2011.
13. Lequerré T, Vittecoq O, Pouplin S, et al. Mevalonate kinase deficiency syndrome with structural damage responsive to anakinra. Rheumatology (Oxford) 46:1860–1862, 2007.
14. Rigante D, Ansuini V, Bertoni B, et al. Treatment with anakinra in the hyperimmunoglobulinemia D/periodic fever syndrome. Rheumatol Int 1:97–100, 2006.
15. Takada K, Aksentijevich I, Mahadevan V, et al. Favorable preliminary experience with etanercept in two patients with the hyperimmunoglobulinemia D and periodic fever syndrome. Arthritis Rheum 9:2645–2651, 2003.
16. Bodar EJ, van der Hilst JC, Drenth JP, et al. Effect of entanercept and anakinra on inflammatory attacks in the hyper-IgD syndrome: Introducing a vaccination provocation model. Neth J Med 7:260–264, 2005.
17. Neven B, Valayannopoulos V, Quartier P, et al. Allogenic bone marrow transplantation in mevalonic aciduria. N Engl J Med 356:2700–1703, 2007. □

DO NOT COPY

Copyright of Allergy & Asthma Proceedings is the property of OceanSide Publications Inc. and its content may not be copied or emailed to multiple sites or posted to a listserv without the copyright holder's express written permission. However, users may print, download, or email articles for individual use.