American Journal of Emergency Medicine xxx (xxxx) xxx

Contents lists available at ScienceDirect

American Journal of Emergency Medicine

journal homepage: www.elsevier.com/locate/ajem

Vancomycin-induced Kounis Syndrome

Caleb Leibee, DO, Bahrenegash Getachew, MD, Michael R. Ehmann, MD, MPH, MS *

The Johns Hopkins University School of Medicine, Department of Emergency Medicine, 1830 E. Monument Street - Suite 6-100, Baltimore, MD 21287, United States of America

ARTICLE INFO

Article history:
Received 17 May 2019
Received in revised form 30 May 2019
Accepted 1 June 2019
Available online xxxx

Keywords:
Kounis Syndrome
Coronary vasospasm
Vancomycin
Allergens

ABSTRACT

Kounis Syndrome is a rare allergic reaction that results in coronary vasospasm and may occur in patients with and without coronary artery disease. A 57-year-old man receiving pre-operative vancomycin for osteomyelitis and gangrene of the foot experienced an episode of anginal symptoms associated with transient ischemic 12-lead electrocardiogram (ECG) changes. The patient's symptoms and ECG changes abated with discontinuation of vancomycin and subsequent coronary angiography revealed no evidence of coronary artery disease. Treatment of Kounis Syndrome begins with cessation of the causative agent. Consensus guidelines for the management of Kounis Syndrome have not been established but treatment should both dilate the coronary vessels and suppress the allergic response. Coronary vasospasm after administration of antibiotics, including vancomycin, is a rare but serious reaction. It is important that Emergency Physicians recognize Kounis Syndrome as an uncommon yet dramatic and consequential reaction to such a commonly-administered antibiotic.

© 2019 Elsevier Inc. All rights reserved.

1. Introduction

Allergic reactions most often present with manifestations of vasodilation and symptoms of mast cell degranulation. An uncommon allergic syndrome known as Kounis Syndrome, however, presents with coronary vasospasm – leading to "allergic angina" or "allergic myocardial infarction" [1]. The phenomenon was first reported in 1991 by Dr. Kounis and colleagues and has since been associated with various allergens [1-3]. The case reported herein focuses on the characteristics and treatment of this uncommon condition and is, to our knowledge, only the second published report of vancomycin-induced Kounis Syndrome and the first in the Emergency Medicine literature [2].

2. Case report

A 57-year-old man presented to the Emergency Department (ED) for toe pain. Past medical history included peripheral artery disease, diabetes mellitus, hypertension and active tobacco use. Current medications included clonidine and pregabalin. He was diagnosed with gangrene and osteomyelitis of the left second toe.

An infusion of vancomycin 15 mg/kg was begun intravenously. Before initiation of vancomycin, the patient reported an "allergy" to this medication from a prior exposure. He confirmed that he had been told at that time that this reaction was the well-described "red-man syndrome." [4] Therefore, to reduce the likelihood of recurrent adverse reaction, we prescribed a slower vancomycin infusion rate (2.5 h versus standard protocol 1.25 h).

Five minutes after starting the vancomycin infusion, the patient was found to be in extremis. He was incoherent and gripping the bed rails, profoundly diaphoretic, with a heart rate of 84 beats/min, blood pressure of 120/68 mm Hg and oxygen saturation of 94% on ambient air. There were no skin changes. The patient described chest and back pain associated with headache and warmth.

Vancomycin was discontinued and a 12-lead electrocardiogram (ECG) was immediately obtained (Fig. 1). The ECG demonstrated ST-segment elevation and hyper-acute T waves in the inferior leads with reciprocal ST segment depression in the high lateral leads suggestive of acute inferior myocardial infarction. Within 8 min, the patient's symptoms resolved and a second ECG was obtained (Fig. 2). The second ECG showed complete resolution of the ischemic ST-segment and T wave changes.

Immediately upon the change in his condition, the patient received 1L intravenous normal saline and, by 20 min, 50 mg intravenous diphenhydramine and 325 mg oral aspirin. Interventional cardiology was consulted and deferred emergent coronary angiography. Serum troponin-I measurements remained undetectable (<0.04 ng/mL) over the subsequent 6 h and were not drawn thereafter.

The patient was admitted for surgical management of his gangrenous toe. Pre-operative cardiac catheterization obtained in preparation for toe amputation revealed no coronary artery disease. Transthoracic echocardiogram was similarly unremarkable. The patient tolerated

* Corresponding author.
E-mail addresses: cleibee1@jhmi.edu (C. Leibee), bgetach2@jhmi.edu (B. Getachew), mehmann1@jhmi.edu (M.R. Ehmann).

https://doi.org/10.1016/j.ajem.2019.06.004
0735-6757/© 2019 Elsevier Inc. All rights reserved.

ARTICLE IN PRESS

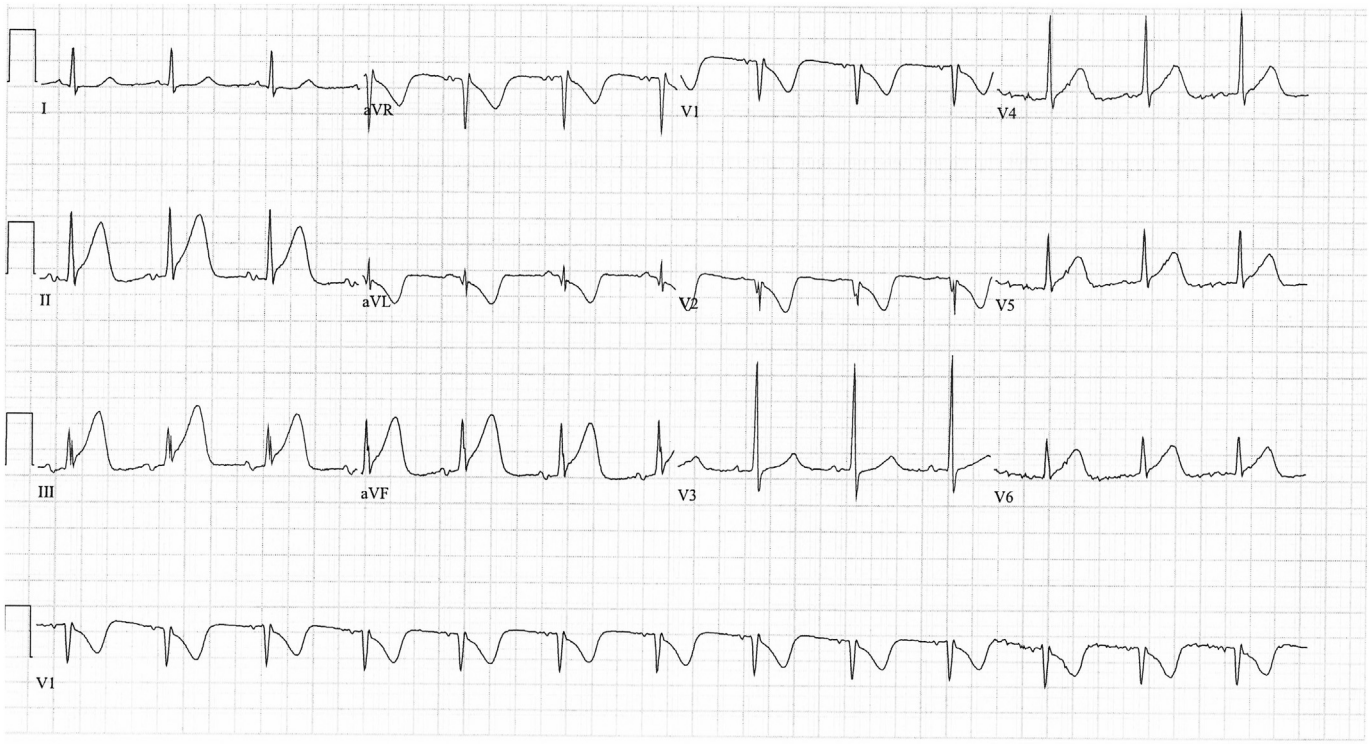

Fig. 1. Initial electrocardiogram (ECG). 12-lead ECG obtained approximately 2 min after vancomycin infusion was discontinued but while patient was still symptomatic; interpreted as normal sinus rhythm with ST-segment elevation and hyper-acute T waves in the inferior leads and reciprocal ST segment depression in the high lateral leads suggestive of acute inferior myocardial infarction.

linezolid and clindamycin without further complication. He underwent successful toe amputation and had no additional events during the remainder of his hospital course. He was discharged in good condition 11 days later.

3. Discussion

Kounis Syndrome is an unusual hypersensitivity reaction that leads to vasospasm of the coronary arteries and manifests with signs and

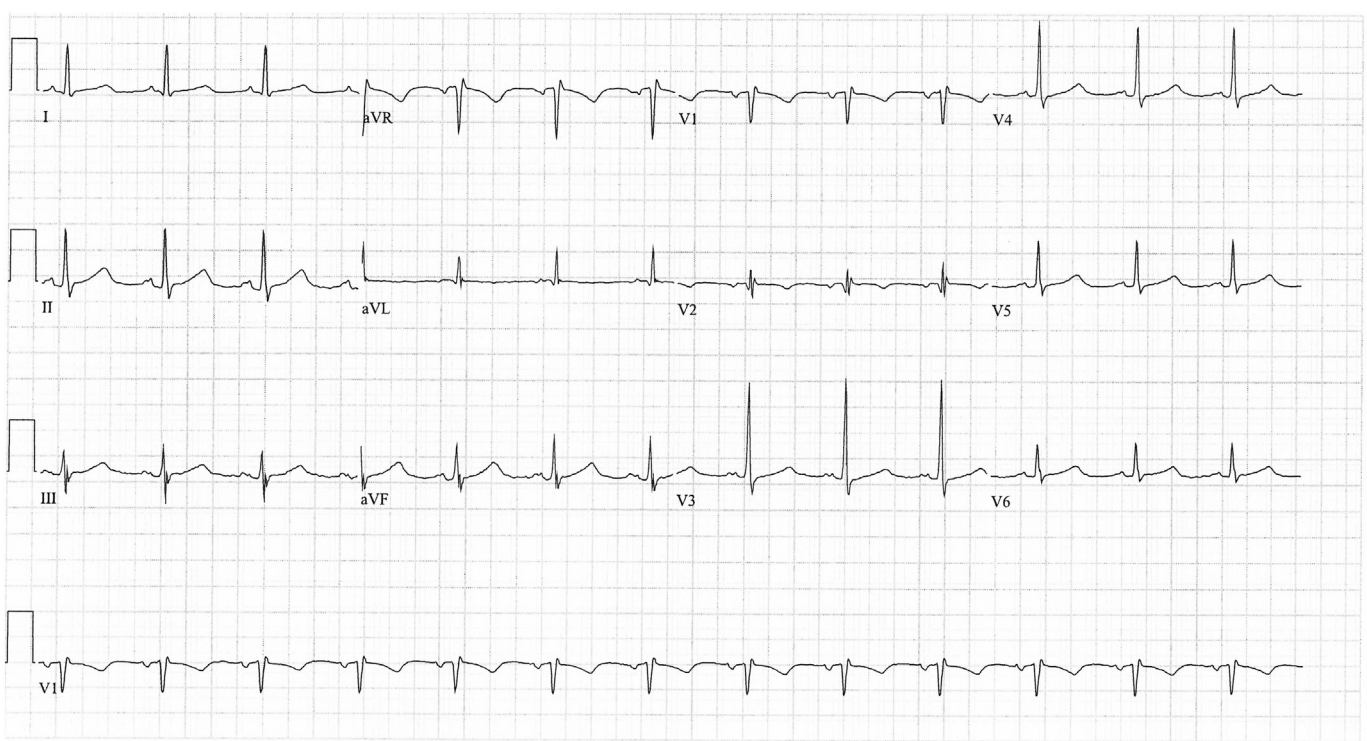

Fig. 2. Repeat electrocardiogram (ECG). 12-lead ECG obtained approximately 8 min after vancomycin infusion was discontinued and after patient's symptoms had resolved; interpreted as normal sinus rhythm with resolution of the ischemic ST-segment and T wave changes when compared to initial ECG (Fig. 1).

Please cite this article as: C. Leibee, B. Getachew and M.R. Ehmann, Vancomycin-induced Kounis Syndrome, American Journal of Emergency Medicine, https://doi.org/10.1016/j.ajem.2019.06.004

ARTICLE IN PRESS

symptoms of myocardial ischemia. There are several allergens reported in the literature that may precipitate this syndrome – including various foods, environmental exposures and multiple drugs [5-7]. The pathophysiology of Kounis Syndrome has been described as involving the same inflammatory pathway as the more commonly encountered vasodilatory allergic or anaphylactic reaction [3,6,8-10]. Mast cell degranulation leads to local and systemic release of several compounds, including histamine, tryptase, chymase, platelet activating factor and various cytokines and chemokines, such as leukotrienes and prostaglandins, that can lead to vasoconstriction and coronary artery spasm [9,10]. Furthermore, histamine can lead to coronary artery thrombus formation via platelet activation, potentiation of the platelet aggregatory effects of various mediators, and thrombin formation via increased expression of vascular smooth muscle tissue factor – an effect that is abrogated by treatment with H1 receptor antagonists [9].

This allergic response may occur in coronary arteries both with and without underlying disease [3,6,8]. Type I Kounis Syndrome occurs in patients with normal coronary arteries, no predisposing factors and no resulting cardiac enzyme elevation; Type II in patients with inactive underlying coronary artery disease for whom the allergic insult leads to vasospasm without elevation of cardiac enzymes; and Type III in patients with coronary stents for whom the allergic insult leads to instent thrombosis [3]. The case presented in this article describes Type I Kounis Syndrome given that the patient had no coronary artery disease on subsequent angiography and troponin-I measurements remained undetectable.

Treatment of Kounis Syndrome begins with the cessation of the causative agent. Ideally, therapies should dilate the coronary vessels and suppress the allergic response; recommendations include calcium channel blockade to alleviate vasospasm, nitroglycerin to dilate coronary vasculature, and antihistamines with corticosteroids to blunt allergic mediators [5,9]. Consensus guidelines, however, have not been established as most information about the treatment of Kounis Syndrome is derived from case reports and there are theoretical concerns regarding the treatment of this condition as either a pure acute coronary syndrome or an allergic reaction, as therapies for each may potentiate harm for the other [6,10]. For example, common treatments administered for acute coronary syndromes, such as morphine and beta blockers, may cause mast cell degranulation and unopposed alpha-adrenergic effects, respectively, and worsen the effects of Kounis Syndrome [10]. Similarly, epinephrine – a common first-line treatment for allergic reactions – may similarly exacerbate coronary vasospasm and should be used with caution [10].

4. Conclusion

Coronary vasospasm after administration of antibiotics, including vancomycin, is a rare but serious reaction. Vancomycin is a commonly administered antibiotic in the ED. It is important that Emergency Physicians are aware of Kounis Syndrome as an uncommon yet dramatic and consequential reaction to such a commonly administered antibiotic. Recommended treatment of Kounis Syndrome includes cessation of the causative agent and administration of medications to dilate the coronary vessels and suppress the allergic response but consensus guidelines are lacking.

Financial support

This work did not receive any specific grant from funding agencies in the public, commercial, or not-for-profit sectors.

Declaration of Competing Interest

CL, BG and MRE declare no conflicts of interest.

References

[1] Kounis NG, Zavras GM. Histamine-induced coronary artery spasm: the concept of allergic angina. Br J Clin Pract 1991;45(2):121–8.
[2] Martinez E, Sahni S, Cheema M, et al. Vancomycin-induced coronary artery spasm: a case of Kounis syndrome. BMJ Case Rep 2018:bcr-2017-222846.
[3] Kounis N, Mazarakis A, Tsigkas G, et al. Kounis syndrome: a new twist on an old disease. Future Cardiol 2011;7(6):805–24.
[4] Sivagnanam S, Deleu D. Red man syndrome. Crit Care 2003;7(2):119–20.
[5] Kounis NG, Kouni SN, Koutsojannis CM. Myocardial infarction after aspirin treatment, and Kounis syndrome. J R Soc Med 2005;98(6):296.
[6] Cevik C, Nugent K, Shome G, Kounis N. Treatment of Kounis syndrome. Int J Cardiol 2010;143(3):223–6.
[7] Memon S, Chhabra L, Masrur S, et al. Allergic acute coronary syndrome (Kounis syndrome). Proc (Bayl Univ Med Cent) 2015;28(3):358–62.
[8] Abdelghany M, Subedi R, Shah S, et al. Kounis syndrome: a review article on epidemiology, diagnostic findings, management and complications of allergic acute coronary syndrome. Int J Cardiol 2017;232:1–4.
[9] Kounis NG. Kounis syndrome (allergic angina and allergic myocardial infarction): a natural paradigm? Int J Cardiol 2006;110(1):7–14.
[10] Kounis NG. Coronary hypersensitivity disorder: the Kounis syndrome. Clin Ther 2013;35(5):563–71.

Please cite this article as: C. Leibee, B. Getachew and M.R. Ehmann, Vancomycin-induced Kounis Syndrome, American Journal of Emergency Medicine, https://doi.org/10.1016/j.ajem.2019.06.004