Case Report

DOI: 10.7860/JCDR/2015/12757.6064

An Unusual Complication with Use of Lignocaine: A Case Report

Dentistry Section

VIKAS S. MESHRAM[1], PRIYATAMA V. MESHRAM[2], PRAVIN N. LAMBADE[3], MANISH S. TIWARI[4]

ABSTRACT

Allergic responses to lignocaine (amide local anaesthesia) used in dentistry is extremely rare. It is widely used by Oral Maxillofacial surgeons to carry out various procedures safely, comfortably and efficiently. It is important for the practitioners to be aware that allergic reactions though very rare, can occur after injection of lignocaine intradermally for allergy testing. A proper diagnosis and management of such allergic reaction is very essential to avoid undesired consequences. We report a case of a 50-year-old male who suffered itching and generalized skin reaction within 5 minutes after administration of test dose of lignocaine intradermally for allergy testing. Clinical presentation, Diagnosis & management of such allergic reaction are discussed. As local anaesthetic agents are commonly used drugs in day to day practice clinicians are encouraged to be familiar with the presentation of various allergic reactions and there management.

Keywords: Hypersensitivity, Lignocaine allergy, Skin testing

CASE REPORT

A 50-year-old male reported to the Department of Oral & Maxillofacial Surgery of Chhattisgarh dental college & research institute, Rajnadgaon for removal of a carious tooth in lower right region of the jaw. As a part of general protocol a detailed case history was taken prior to the procedure and skin testing for allergy was planned prior to the extraction. The patient's past medical history was unremarkable. The patient was informed of the possible complications and a written consent was taken. A test dose of 2% plain lignocaine HCL from a multidose vial was deposited intradermally to produce a 5-mm diameter wheal [Table/Fig-1a]; the area was marked. Blood pressure and vital signs were monitored closely after intradermal injection. Within a time period of five min after injection patient started showing symptoms of drug allergy. Initially there was localized erythema [Table/Fig-1b] at the site of the injection.

Within few minutes patient started complaining of itching over different body parts, the patient was apprehensive, anxious and started showing generalized skin reaction, he had multiple solid raised lesions or papules less than 1 cm in size, flat topped, on his neck, trunk and limbs [Table/Fig-2a&b]. Symptoms were resolved within one hour following treatment with antihistamine (Pheniramine maleate 25mg i.v.) and corticosteroid (dexamethasone 8mg i.v.). Later the extraction was performed using 0.5% bupivacaine after negative result of the skin testing with the same.

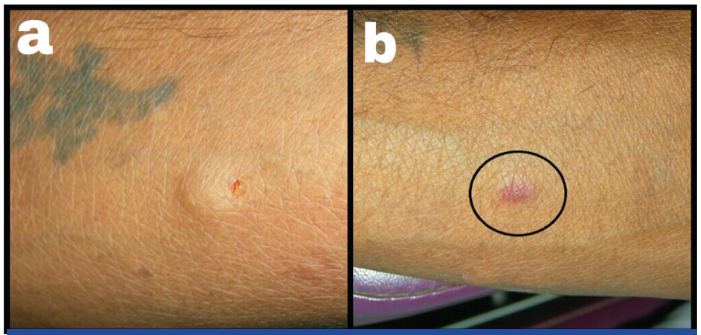

[Table/Fig-1a,b]: Intradermal testing for local anaesthetic allergy; a) deposition of local anaesthetic agent, b) Erythema at the site of skin test

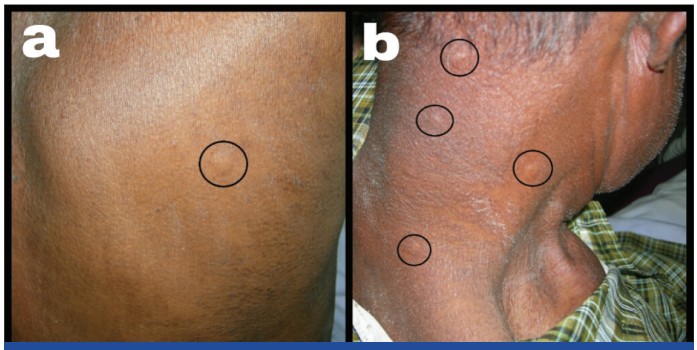

[Table/Fig-2a,b]: Papules on different body parts observed 5 minutes after deposition of 2% lignocaine; a) back, b) neck

DISCUSSION

Lignocaine was first introduced into the practice in 1946 [1] since then it has been used very commonly in routine clinical practice. Local anaesthetics are divided into two groups: (i) amide derivatives of xylidine and toluidine group (lignocaine, mepivacaine, prilocaine) and (ii) ester or benzoic and aminobenzoic derivatives (cocaine, benzocaine, procaine, tetracaine, butacaine).

The allergic reactions to the lignocaine is extremely rare, it has been estimated that true allergic reactions to local anaesthetics account for less than 1% of all adverse reactions to local anaesthetics [2,3]. Only a few cases of type I immediate hypersensitivity reaction [4] and type IV delayed hypersensitivity [5,6] to lignocaine have been reported in the literature.

Though in the indexed patient immediate symptoms were observed following the test dose, there were only preliminary symptoms like itching and presence of papules on various body parts. Thus the case was well managed with the use of antihistaminic and corticosteroids, without need of adrenaline which would have been chosen (adult dose, 0.3 – 1.0 ml 1:1000 solution, intramuscularly) in case of major alteration in vitals, which can be repeated every 5-10 min if required. Similar findings were observed by Noormalin et al., following a skin prick test using 2% lignocaine where the patient had generalized urticaria and erythmatous pruritic rash after 10 minutes of carrying out the test [4]. Nath et al., reported a case of delayed hypersensitivity with the use of 1% lignocaine [7].

Though the reaction was seen 24 hours later after administration of 1% lignocaine for implant removal from humerus, there were severe urticarial rashes over chest and neck of the patient.

Though lignocaine is considered as least allergic among the anaesthetic agents, still it can cause severe life threatening systemic manifestations. The reactions with the test dose were minimal in the reported patient but with the therapeutic dose it would have been very severe. Khalid et al., reported a case of classical type I hypersensitivity reaction in its most severe form i.e. anaphylaxis following use of Lignocaine for dental procedure [8]. There was positive skin prick test with preservative free plain 2% lignocaine solution. Thus the immediate reactions, particularly Type I are arduous and can lead to fatal consequences if left untreated. In general the more rapidly the sign and symptoms of allergy develop following the injection; the more intense the reaction is likely to be.

Allergy to the ester type local anaesthetics is more than the amide type of the local anaesthetics. Patients allergic to one type of the ester containing local anaesthetic are allergic to all the ester containing local anaesthetics [9]. Unlike ester type, allergy to an amide type of local anaesthetic agent does not contraindicate the use of another amide type of local anaesthetic agent [3]; still there are reported cases where lignocaine have shown cross sensitivity with Mepivacaine (Amide) [10]. Thus it would be unwise to use another amide local anaesthetic without hypersensitivity tests.

Allergic reactions due to other contents of the injection solution are more than the local anaesthetic agent itself. Paraben and bisulfites are widely used additives and well-documented antigenic stimulants [11]. It may be best to avoid a vasoconstrictor if there is a documented allergy to sulfites, as metabisulfite is added as an antioxidant whenever a vasoconstrictor is added. Of special interest in causing allergy is the bacteriostatic agent methylparaben. The parabens are added as bacteriostatic agents in all multiuse drugs [12].

Definitive testing was not feasible in the indexed patient due to the lack of resources making it difficult to find the main cause of allergy. For definitive results, a test dose of bupivacaine, from a multidose vial, as an alternative local anaesthetic agent was deposited intradermally which did not show any allergic reaction. Thus methylparaben was not the cause of allergy as it was a common constituent (as a bacteriostatic agent) in the test dose of both Lignocaine and Bupivacaine as both test solutions were obtained from multidose vials [12]. Thus we lead to a conclusion that Lignocaine was the sole agent responsible for the hypersensitivity reaction in the indexed patient.

There was no previous history of drug allergy in the present case, for the prevention of allergic reactions, clinician should take a thorough case history of any previous allergy to medications; patients with systemic diseases such as asthma, hay fever should be given special considerations. The local anaesthesia must not be used until the alleged allergy can be absolutely disproved. General anaesthesia is a safe method if used effectively; use of histamine blockers as local anaesthetics (1% diphenhydramine with 1:100,000 epinephrine) provides satisfactory anaesthesia [13]. Though rare, hypersensitivity reactions can occur secondary to local anaesthesia and may cause severe systemic adverse effects. Thus we strongly recommend skin testing in each patients requiring local anaesthesia.

CONCLUSION

Allergic reactions, though rare, can occur secondary to any local anaesthetic agent. These reactions may range from minor cutaneous manifestations to severe anaphylaxis reactions. Thus, we strongly recommend skin testing for allergy in each and every patients requiring local anaesthesia. One should keep a keen eye on patient's vitals and should be well equipped with emergency measures in order to render prompt treatment to the patients so as to avoid any undesired consequences in day to day clinical practice.

REFERENCES

[1] Curley RK, Macfarlane AW, King CM. Contact sensitivity to the amide anaesthetics lidocaine, prilocaine, and mepivacaine. *Arch Dermatol*. 1986;122:924-26.

[2] Bhole MV, Manson AL, Seneviratne SL, Misbah SA. IgE-medicated allergy to local anaesthetics: separating fact from perception: a UK perspective. *Br J Anaesth.* 2012;108:903-11.

[3] Ball IA. Allergic reactions to lignocaine. *Br Dent J.* 1999;186:224-26.

[4] Noormalin A, Shahnaz M, Rosmilah M, Mujahid SH, Gendeh BS. IgE-mediated hypersensitivity reaction to lignocaine – a case report. *Trop Biomed*. 2005;22:179–83.

[5] Evans LA, Pointing J, Wills EJ, Michalopoulos J, Adelstein S. Recurrent facial swelling following dental procedures. *Med J Aust*. 2002;177:522.

[6] Mackley CL, Marks JG Jr, Anderson BE. Delayed–type Hypersensitivity to lidocaine. *Archives of Dermatology* 2003;139:343-46.

[7] Nath R, Sharma S, Dutta A, Roy J, Singh T. Hypersensitivity to lignocaine: A case report. *IJMRHS.* 2013;2:1003-05.

[8] Al-Dosary K, Al-Qahtani A, Alangari A. Anaphylaxis to lidocaine with tolerance to articaine in a 12 year old girl. *Saudi Pharm J*. 2014;22:280-82.

[9] Harper NJN, Dixon T, Dugue P et al. Guidelines: Suspected anaphylactic reactions associated with anaesthesia. *Anaesthesia.* 2009;64:199-211.

[10] González-Delgado P, Antón R, Soriano V, Zapater P, Niveiro E. Cross-Reactivity among Amide-Type Local Anaesthetics in a Case of Allergy to Mepivacaine. *J Investig Allergol Clin Immunol*. 2006;16:311-13.

[11] Malamed SF. Handbook of Local Anaesthesia, 4th Edition, Philadelphia, Mosby-Year Book, Inc., 1997. pp.274-77.

[12] Eggleston S T, Lush L W. Understanding allergic reactions to local anaesthetics. *Ann Pharmacother* 1996;30:851–57.

[13] Orhan ME, Yüksel U, Bilgin F, Doğul A. Comparison of the local anaesthetic effects of chlorpheniramine, midazolam, lidocaine, and normal saline after intradermal injection. *Med Sci Monit*. 2007;13:I7-21.

PARTICULARS OF CONTRIBUTORS:

1. Professor, Department of Oral and Maxillofacial Surgery, Swargiya Dadasaheb Kalmegh Smruti Dental College and Hospital, Nagpur, India.
2. Associate Professor, Department of Conservative Dentistry and Endodontics, Swargiya Dadasaheb Kalmegh Smruti Dental College and Hospital, Nagpur, India.
3. Professor and Head of Department, Department of Oral and Maxillofacial Surgery, Swargiya Dadasaheb Kalmegh Smruti Dental College and Hospital, Nagpur, India.
4. Junior Resident, Department of Oral and Maxillofacial Surgery, Swargiya Dadasaheb Kalmegh Smruti Dental College and Hospital, Nagpur, India.

NAME, ADDRESS, E-MAIL ID OF THE CORRESPONDING AUTHOR:
Dr. Vikas Meshram,
Nirman Heritage, Flat No. 302, Srinath Sai Nagar, Omkar Nagar SQ. Manewada Ring Road,
Nagpur, Maharashtra-440027, India.
E-mail: drvikasm@gmail.com

FINANCIAL OR OTHER COMPETING INTERESTS: None.

Date of Submission: **Jan 02, 2015**
Date of Peer Review: **Apr 24, 2015**
Date of Acceptance: **Apr 27, 2015**
Date of Publishing: **Jun 01, 2015**