# "Pink Sign": The Importance of Short-Term Occlusive Testing in Suspected Cases of Contact Urticaria

Jahdonna Isaac, MSc, Ari M. Goldminz, MD, and Pamela L. Scheinman, MD

## PRECÍS

We report a case of fragrance-induced contact urticaria evaluated by short-term occlusive testing and identification of what we term the "pink sign."

## DISCUSSION

A 24-year-old clinical research assistant, wearing nitrile gloves at work and endorsing occasional hand dermatitis, had a 5-year history of intermittent, short-lived, itchy and "burning" rashes involving the face, neck, torso, and lower extremities. Her rashes occurred soon after specific airborne and food exposures and were occasionally associated with dyspnea. She was treated with diphenhydramine and albuterol as needed. Serum tryptase and chronic urticaria index were within normal limits; total serum IgE was 1163 IU/mL (≤100 IU/mL).

She was patch tested to our standard, cosmetic, fragrance, rubber, hair, and bakery series. Twenty minutes after patch placement, we observed a pink rim around several allergens through the paper tape. We carefully peeled away each strip showing urticarial wheals to cinnamic aldehyde, balsam of Peru, fragrance mix I, and benzoic acid (Fig. 1). At her final 72-hour read, she reacted to benzyl salicylate (+++), linalool (++), cocamidopropyl betaine (+), shellac (+), disperse yellow 9 (+), benzoyl peroxide (+), carmine (+), and juniperus oxycedrus extract (+). Four months after patch testing, her condition remained significantly improved with allergen avoidance and treatment with omalizumab, ranitidine, montelukast, and cetirizine. Nonsteroidal anti-inflammatory drugs, reported to block nonimmunologic contact urticaria (NICU) reactions,[1] were not used. She had 1 flare after exposure to a coworker wearing cologne.

*From the Department of Dermatology, Brigham and Women's Hospital, Boston, MA.*

*Address reprint requests to Ari M. Goldminz, MD, 850 Boylston St, Ste 437, Chestnut Hill, MA 02467. E-mail: agoldminz@bwh.harvard.edu.*

*A.M.G.'s spouse has stock in Johnson and Johnson. P.L.S. is a consultant for Patton Squire Boggs law firm. J.I. has no funding or conflicts of interest to declare.*

*J.I. and A.M.G. contributed equally to this study.*

**DOI: 10.1097/DER.0000000000000441**

*© 2019 American Contact Dermatitis Society. All Rights Reserved.*

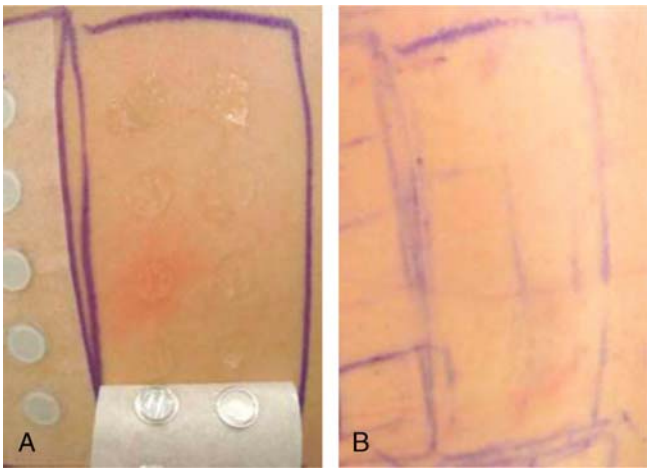


**Figure 1.** A, Urticarial reaction to benzoic acid observed 20 minutes after patch placement ("pink sign"). B, Absence of delayed reaction to benzoic acid 72 hours after patch placement.

Based on history, workup, and improvement with allergen avoidance plus medications, contact urticaria (CU), delayed-type hypersensitivity reactions, and chronic idiopathic urticaria may all have contributed to our patient's symptoms. Contact urticaria is a localized and transient hypersensitivity reaction to an allergen.[2] It is divided into 3 variants including immunological CU, NICU, and CU of unknown origin. Immunological CU is a type I, IgE-mediated hypersensitivity reaction that can be associated with anaphylaxis and systemic symptoms, whereas NICU is more localized and does not require previous sensitization.[2] Both types of CU have been associated with fragrances.[2] Although we cannot rule out NICU completely, our patient may have experienced immunological CU given her systemic symptoms, urticaria to fragrance chemicals during 20 minutes of occlusion, and flare upon exposure to cologne.

In recognizing the potential for some allergens to induce both immediate and delayed reactions, von Krogh and Maibach[2] and Nijhawan and Jacob[3] detailed an algorithm for evaluation of CU that combines open- and closed-application tests on both affected and intact skin.[2,3]

Guerra et al[4] reported on avoidance of contact allergens resolving chronic urticaria, although this study was criticized[5] for short-term follow-up and no control group. Because patients may not present with classic "wheal-and-flare" hives, a high index of suspicion is required for diagnosis. We stress the importance of investigating for CU when history suggests immediate hypersensitivity reactions (ie, burning, stinging, hives, with or without shortness of breath, hoarseness). An examination for CU can be performed by carefully peeling back patches after 20 minutes of allergen occlusion. Importantly, our patient showed reactions at 20 minutes that were no longer present by 72 hours. We term this the "pink sign" and suggest it be



Copyright © 2019 American Contact Dermatitis Society. Unauthorized reproduction of this article is prohibited.

considered as an ancillary evaluation tool that can be performed in addition to standard patch testing protocols for the appropriate patient.

## PEARL

In suspected cases of CU, 20-minute occlusive testing may identify urticarial reactions (the "pink sign") that could otherwise be missed through conventional patch testing procedures.

## REFERENCES


1. Lahti A, Väänänen A, Kokkonen E, et al. Acetylsalicylic acid inhibits non-immunologic contact urticaria. *Contact Dermatitis* 1987;16(3):133–135.
2. von Krogh G, Maibach H. The contact urticaria syndrome—an updated review. *J Am Acad Dermatol* 1981;5(3):328–342.
3. Nijhawan BS, Jacob SE. The role of patch testing in contact urticaria. *J Am Acad Dermatol* 2008;59(2):354–355.
4. Guerra L, Rogkakou A, Massacane P, et al. Role of contact sensitization in chronic urticaria. *J Am Acad Dermatol* 2007;56(1):88–90.
5. Asero R, Cugno M, Tedeschi A. Chronic urticaria: one step forward and two steps back. *J Am Acad Dermatol* 2007;57(2):368–369.


# Allergic Contact Dermatitis to a Self-adherent Bandage Wrap in a Formaldehyde-allergic Patient

Yujie Linda Liou, DO*† and Erin M. Warshaw, MD*†‡

## PRECÍS

Self-adherent bandage wraps are popular wound dressings.

## DISCUSSION

A 59-year-old man with a persistent papular and vesicular rash was evaluated for suspected contact dermatitis. Upon questioning, he reported a history of dermatitis to both a self-adherent wrap applied after a blood draw and to another bandage product applied after a biopsy. The patient was patch tested to the North American Contact Dermatitis Group screening series in addition to our corticosteroid, emulsifiers, preservatives, textile dyes, several personal items, and an Andover Co-Flex NL bandage (as is, from our clinic).

Results on day 7 of patch testing revealed the following: +++ reaction to 2% formaldehyde; ++ reactions to 1% formaldehyde and formaldehyde releasers including quaternium-15, DMDM (1,3-Dimethylol-5,5-dimethylhydantoin) hydantoin, and diazolidinyl urea; and + reactions to other formaldehyde releasers including Grotan BK and melamine formaldehyde resin, as well as home products including permethrin cream (contains formaldehyde) and original Sarna lotion (contains DMDM [1,3-Dimethylol-5,5-dimethylhydantoin] hydantoin). He also had a mild reaction to the Co-Flex NL bandage (Fig. 1).

The Safety Data Sheet for Andover Co-Flex NL bandage declared polyolefin fibers, elastic yarns, natural rubber, tackifying resins, and pigments. Because of the patient's history of reacting to self-adherent bandages, positive patch reaction to the Co-Flex NL bandage, and strong sensitivity to formaldehyde, we hypothesized that formaldehyde may be present in the Co-Flex NL bandage. Two different types of commonly used self-adherent bandage wraps, 3M Coban LF and Andover Co-Flex NL, plus their packaging were tested using the chromotropic acid method (CAM).

Chromotropic acid gives off a purple discoloration when it reacts with formaldehyde in an acidic environment.[1] As little as 2.5 ppm of free formaldehyde can be detected by CAM.[2] The Andover Co-Flex NL bandage was mildly positive for formaldehyde release with CAM (Fig. 2). The 3M Coban LF bandage (contains 98% natural rubber), and the plastic packaging of both bandages tested negative for formaldehyde.

Self-adherent bandages are commonly used for wound care, especially in patients with chronic leg ulcers. Wound care dressings are thought to have very low potential in causing allergic contact dermatitis. Common sensitizers in bandages are rubber used in the elastic, colophony, and acrylates used in adhesives, as well as topical antibiotics that are embedded in bandages.[3] Although monomers of

**Figure 1.** Day 7 reaction to Andover Co-Flex NL self-adherent bandage applied moistened with water as is.

*From the *Veteran Affairs Medical Center; †Park Nicollet Contact Dermatitis Clinic; and ‡Department of Dermatology, University of Minnesota, Minneapolis, MN.*

*Correspondence: Yujie Linda Liou, DO, Park Nicollet Contact Dermatitis Clinic, 7550 34th Ave S #101, Minneapolis, MN 55450. E-mail: Yujie.li@med.lecom.edu.*

*No reprints available.*

*The authors have no funding or conflicts of interest to declare.*

*This material is the result of work supported with resources and the use of facilities at theMinneapolis Veterans Affairs Medical Center. The contents do not represent the views of the US Department of Veterans Affairs or the US Government.*

**DOI: 10.1097/DER.0000000000000448**

*© 2019 American Contact Dermatitis Society. All Rights Reserved.*

Copyright © 2019 American Contact Dermatitis Society. Unauthorized reproduction of this article is prohibited.




**Figure 2.** The Co-Flex NL bandage (c) shows a mild purple discoloration compared with positive (+) and negative (−) controls, indicating formaldehyde release.

*p*-tertiary butylphenol-formaldehyde resin may cause sensitization in adhesives of athletic tapes,[4] individuals with this allergy may not show cross-reactivity to formaldehyde.[5]

Our patient did not react to adhesives (colophony, acrylates, *p*-tertiary butylphenol-formaldehyde resin) or rubber accelerators on patch testing. We suspect that the release of formaldehyde from Co-Flex NL bandage, as confirmed by CAM, was the etiology of the patient's reactions to self-adherent bandages.

## ZEBRA

Patients and clinicians should be aware of self-adherent bandages as a potential source of formaldehyde.

## REFERENCES

1. Fregert S, Dahlquist I, Gruvberger B. A simple method for the detection of formaldehyde. *Contact Dermatitis* 1984;10(3):132–134.
2. Hauksson I, Pontén A, Gruvberger B, et al. Skincare products containing low concentrations of formaldehyde detected by the chromotropic acid method cannot be safely used in formaldehyde-allergic patients. *Br J Dermatol* 2016; 174(2):371–379.
3. Alavi A, Sibbald RG, Ladizinski B, et al. Wound-related allergic/irritant contact dermatitis. *Adv Skin Wound Care* 2016;29(6):278–286.
4. Shono M, Ezoe K, Kaniwa M-A, et al. Allergic contact dermatitis from para-tertiary-butylphenol-formaldehyde resin (PTBP-FR) in athletic tape and leather adhesive. *Contact Dermatitis* 1991;24(4):281–288.
5. Zimerson E, Bruze M. Contact allergy to the monomers in p-tert-butylphenol-formaldehyde resin. *Contact Dermatitis* 2002;47(3):147–153.

Copyright © 2019 American Contact Dermatitis Society. Unauthorized reproduction of this article is prohibited.