The Journal of Infectious Diseases

BRIEF REPORT

Immunoserologic Detection and Diagnostic Relevance of Cross-Reactive Autoantibodies in Coronavirus Disease 2019 Patients

María Teresa Schiaffino,[1] Marisa Di Natale,[1] Elena García-Martínez,[1] Joaquín Navarro,[1] José Luis Muñoz-Blanco,[2] Pablo Demelo-Rodríguez,[3] and Paloma Sánchez-Mateos[1,4]

[1]Servicio de Inmunología Clínica, Hospital General Universitario Gregorio Marañón, Madrid, Spain, [2]Servicio de Neurología, Hospital General Universitario Gregorio Marañón, Madrid, Spain, [3]Servicio de Medicina Interna, Hospital General Universitario Gregorio Marañón, Madrid, Spain, [4]Instituto de Investigación Sanitaria Gregorio Marañón (IiSGM), Madrid, Spain

Background. During the coronavirus disease 2019 (COVID-19) pandemic, we detected a new immunofluorescence (IF) pattern in serum autoantibody (autoAb) screening of laboratory-confirmed COVID-19 patients.

Methods. The IF pattern was composed of liver and gastric mucosa staining on rat kidney/liver/stomach sections.

Results. We describe 12 patients positive for the cross-reactive antibody, compared with a negative group of 43 hospitalized COVID-19 patients, finding association with either neurologic or thrombotic complications. In sequential pre- and post-COVID-19 serum samples, we confirmed autoAb seroconversion.

Conclusions. Our data indicate that autoAb screening in COVID-19 patients may be easily performed by IF and alert for autoreactive-mediated complications such as thrombotic or neurologic events.

Keywords. autoantibody; autoimmunity; COVID-19; immunofluorescence; molecular mimicry.

Coronavirus disease 2019 (COVID-19) is a severe acute respiratory infection caused by severe acute respiratory syndrome coronavirus 2 (SARS-CoV-2), which initiated in late 2019 in China and is spreading around the word during 2020 causing a global pandemic outbreak. Although a large percentage of infected patients are asymptomatic or develop mild to moderate flu-like symptoms, approximately 15% of patients progress to severe pneumonia associated with high fatality rates [1]. This second phase of the illness is triggered by an inappropriate inflammatory response with release of multiple cytokines including interleukin-6 [2]. Severe COVID-19 is characterized by unremitting fever, hyperferritinemia, and hypercoagulability and is reminiscent of some challenging systemic rheumatic diseases included in the hyperferritinemic syndrome [3]. Moreover, COVID-19 has recently been linked to autoinflammatoy and autoimmune conditions such as autoimmune cytopenias, Guillain-Barré syndrome (GBS), Kawasaki disease, and increased risk of thrombotic events associated with antiphospholipid antibody (Ab) [4]. However, the precise drivers of the immune dysfunction remain poorly defined, and the potential relevance of virus-induced autoimmune-mediated injury in COVID-19 clinical manifestations deserves further investigation.

The most frequent and conventional method for antinuclear Ab (ANA) detection is the indirect immunofluorescence (IF) assay on cryostat sections of rodent tissues and HEp-2 cells slides [5]. In addition to ANA screening, rat triple tissue sections (kidney, stomach, and liver) are useful in the diagnosis of autoimmune hepatic or gastric diseases where specific IF patterns, collectively known as nonorgan-specific autoantibodies (NOSA), help to identify a variety of autoantibody (autoAb) including antimitochondrial, antismooth muscle, antiliver-kidney microsome, antiliver cytosol type 1, or antigastric parietal cells autoAb.

Our institution, a large general hospital located in downtown Madrid with more than 1000-bed capacity, was fully dedicated to attend COVID-19 patients during the pandemic. In the course of routine autoAb screening on rat triple tissue sections, we have recognized a distinct IF pattern on liver and gastric mucosa, which was not attributed to previously described NOSA patterns. In this study, we report the new COVID-IF pattern, which is easily identifiable and very specific of COVID-19 and may be indicative of autoreactive Ab in a group of COVID-19 patients. Furthermore, identification of autoAb-induced pathogenesis in some neurologic or thrombotic post-COVID-19 complications may guide the application of appropriate immunomodulatory treatments.

MATERIALS AND METHODS

Patients and Samples

Patient data and samples were obtained in accordance with Ethics Committees of Instituto de Investigación Sanitaria Gregorio Marañón requirements. The patients' main characteristics are summarized in Table 1. Severe acute respiratory syndrome coronavirus 2 infection was confirmed by positive reverse-transcriptase polymerase chain reaction (RT-PCR) assay in all patients but 1 suspected patient, with negative

Received 15 June 2020; editorial decision 24 July 2020; accepted 31 July 2020; published online August 1, 2020.

Correspondence: Paloma Sánchez-Mateos, MD, PhD, Laboratorio de Inmuno-oncología, Instituto de Investigación Sanitaria Gregorio Marañón, c/Doctor Esquerdo, 46, Madrid, 28007 Spain (paloma.sanchezmateos@salud.madrid.org).

The Journal of Infectious Diseases® 2020;XX:1–5

© The Author(s) 2020. Published by Oxford University Press for the Infectious Diseases Society of America. All rights reserved. For permissions, e-mail: journals.permissions@oup.com.

DOI: 10.1093/infdis/jiaa485

Downloaded from https://academic.oup.com/jid/advance-article/doi/10.1093/infdis/jiaa485/5879761 by guest on 21 August 2020

Table 1. Clinical Characteristics of the Patients With or Without COVID-IF Pattern[a]

Characteristics	Positive COVID-IF Pattern (N = 12)	Negative COVID-IF Pattern (N = 41)	Total (N = 53)
Demographics Characteristics			
Age (years)*	73 (53–91)	61 (24–87)	64 (24–91)
Gender (F/M)	3/9	19/22	22/31
COVID-19 Signs and Symptoms			
Bilateral pneumonia	10/12 (83.3%)	35/41 (85.4%)	45/53 (84.9%)
Fever	8/12 (66.7%)	34/41 (82.9%)	42/53 (72.9%)
Cough	8/12 (66.7%)	32/41 (78%)	40/53 (75.5%)
Dyspnea	5/12 (41.7 %)	22/41 (53.7%)	27/53 (50.9%)
Diarrhoea	3/12 (25%)	7/41 (17.1%)	10/53 (18.9%)
PE/DVT**	8/12 (66.7%)	14/41 (34.1%)	22/53 (41.5%)
Neurological symptoms**	4/12 (33.3%)	4/41 (9.8%)	8/53 (15.1%)
Confusion	1/12 (8.3%)	0/41 (0)	1/53 (1.9%)
Anosmia	1/12 (8.3%)	2/41 (4.9%)	3/53 (5.7%)
Peripheric neuropathies	2/12 (16.7%)	2/41 (4.9%)	4/53 (7.5%)
Previous clinical history of autoimmunity	0/12 (0)	5/41 (12.2%)	5/53 (9.4%)
AST/ALT/GGT alterations	8/12 (66.7%)	32/41 (78%)	40/53 (75.5%)
AST >37 U/L	5/12 (41.7%)	20/41 (48.8%)	25/53 (47.2%)
ALT >41 U/L	6/12 (50%)	28/41 (68.3%)	34/53 (64.2%)
GGT >60 U/L	7/12 (58.3%)	26/41 (63.4%)	33/53 (62.3%)
C-reactive protein (mg/dL)	7.3 (±8.0)	9.7 (±10.2)	9.2 (±9.8)
Ferritin (μg/L)**	654.7 (±384.0)	1503.2 (±1875.7)	1310.4 (±1691.2)
Leukocytes count (cells/μL)	7650 (±3089)	6407 (±3420)	6689 (±3361)
Lymphocyte count (cells/μL)	1158 (±533)	1068 (±579)	1089 (±565)
Lymphocyte/μL <600	1/12 (8.3%)	6/41 (14.6%)	7/53 (13.2%)
Antiphospholipid antibodies	0/12 (0)	5/41 (12.2%)	5/53 (9.4%)
Anti-cardiolipin IgG	0/12 (0)	1/41 (2.4%)	1/53 (1.9%)
Anti-cardiolipin IgM	0/12 (0)	5/41 (12.2%)	5/53 (9.4%)
Anti-β2 glicoprotein IgG	0/12 (0)	1/41 (2.4%)	1/53 (1.9%)
Anti-β2 glicoprotein IgM	0/12 (0)	3/41 (7.3%)	3/53 (5.7%)
Antinuclear antibodies	0/12	2/41 (4.9%)	2/53 (3.8%)
Days postsymptom onset at collection	21.2	19.6	19.9

Abbreviations: ALT, alanine aminotransferase; AST, aspartate aminotransferase; COVID-19, coronavirus disease 2019; DVT, deep vein thrombosis; GGT, gamma glutamyl transferase; IF, immunofluorescence; Ig, immunoglobulin; PE, pulmonary embolism.

[a]Data are median (standard deviation) or n/N (%).

*$P < .01$.

**$P < .05$.

RT-PCR results, that was confirmed with positive serologic testing. Serum samples from 53 consecutive hospitalized patients were tested for autoAbs screening during March and April 2020. Cerebrospinal fluid (CSF) samples from 3 patients with severe neurologic complications and positive serum COVID-IF were also included.

Indirect Immunofluorescence

Samples were prepared in a QANTA-Lyser 160 EIA/IFA processor using commercial ready-made multispot slides with triple tissue sections (rat kidney/stomach/liver; Medica Company) according to the manufacturer's instructions. In brief, 100 μL prediluted sera (1/80 in phosphate-buffered saline) or CSF were added to each spot and incubated for 30 minutes at room temperature. Slides were then washed 3 times and incubated with goat antihuman immunoglobulins (anti-IgG/A/M) fluorescein isothiocyanate-labeled serum or with goat antihuman IgG (Inova Diagnostics) for another 30 minutes. After 3 more washes, nuclei were stained with 4',6-diamidino-2-phenylindole (DAPI), and slides were mounted in commercial mounting medium (Inova Diagnostics). Samples were examined under a fluorescence microscope. Imaging was performed using the glycerol ACS APO 20× NA0.60 immersion objective of a confocal fluorescence microscope (SPE; Leica Microsystems).

Statistical Analysis

The association between qualitative variables and the COVID-IF pattern was studied using Pearson's χ^2 test or Fisher's exact test. The comparison between numerical variables was performed with the non-parametric Mann-Whitney *U* test. All statistical analyses were performed using SPSS Statistics version 25.0 software. $P < .05$ was considered statistically significant.

Downloaded from https://academic.oup.com/jid/advance-article/doi/10.1093/infdis/jiaa485/5879761 by guest on 21 August 2020

RESULTS

From March to April 2020, during the COVID-19 pandemic outbreak in Madrid, we analyzed 53 consecutive hospitalized patients, with laboratory-confirmed COVID-19, for autoimmune laboratory testing. In the initial autoAb screening, we observed an unusual pattern of IF staining on rat triple tissue in 12 of 53 patient serum samples. We collected clinical and laboratory information of the first 12 cases displaying the particular IF pattern compared with 41 IF negative ones (Table 1). We found older age and higher incidence of neurologic and thrombotic events significantly associated with the positive COVD-IF pattern, whereas ferritin levels were higher in the negative pattern group. The presence of previous autoimmune diseases (1 autoimmune thyroiditis, 2 autoimmune cytopenias, 1 rheumatoid arthritis, and 1 systemic lupus erythematosus) was only observed in the negative IF group. Positive antiphospholipid Abs (cardiolipin and beta-2-glicoprotein) were detected in few patients in the negative IF group; therefore, they did not appear to be associated with the new COVID-IF pattern.

The unfamiliar IF pattern, shared by this group of 12 COVID-19 serum samples, was named COVID-IF and was composed of intense gastric mucosa and liver staining, with no involvement of other stomach layers or kidney. A strong staining around cells, indicative of plasma membrane reactivity, was detected around cells located at the bases of gastric glands (rich in chief cells) and around hepatocytes; representative images are shown in Figure 1A and B, respectively. The presence of cross-reacting serum Ab bound to rat tissues was revealed with either polyspecific anti-IgG/A/M or monospecific anti-IgG, but not with anti-IgA isotype (data not shown). These data suggest the presence of IgG/M isotype autoAb in the serum of a group of COVID-19 patients reacting with plasma membrane components of hepatocytes and gastric glandular cells. Furthermore, we had a pre-COVID-19 serum sample available from one of the COVID-IF-positive patients, collected 5 weeks before initiating symptoms, showing negative to positive seroconversion in pre- and post-COVID-19 sequential samples, respectively.

It is interesting to note that, in strong temporal association with SARS-CoV-2 infection, we found high titer positive COVID-IF IgG in the serum of 3 patients with severe neurological complications: 1 with GBS (Supplementary Figure), 1 with bilateral facial paralysis, and 1 with acute confusional state. Next, we assayed the CSF of these 3 serum-positive COVID-IF patients on rat triple tissue, and we found a CSF-positive COVID-IF pattern in the GBS patient and CSF negative in the other 2 patients. The correlation between serum and CSF autoAb supports a possible pathogenic role of intrathecal cross-reactive Ab in neurological complications associated to SARS-CoV-2 infection.

DISCUSSION

In some hospitalized COVID-19 patients, we found a particular IF pattern on rat tissues indicative of cross-reactive autoAb. In this study, we described the new IF pattern and the clinical features of the first 12 IF-positive cases, which were associated with a higher incidence of neurologic and thrombotic complications, compared with 41 IF-negative COVID-19 patients.

The 100% association of the new IF pattern with laboratory-confirmed COVID-19 and the temporal sequence of seroconversion of pre- and post-COVID-19 serum samples suggest a causal relationship between the autoreactive Ab and the SARSCoV-2 infection. In line with this, the positive COVID-IF pattern sera were collected with a media of 21 days postsymptom development, which is timely with antiviral IgG seroconversion within 19 days after symptom onset [6]. In our experience, the new IF pattern was not detected previously in other autoimmune or control serum samples and could not be ascribed to known patterns. The antigen recognized by the cross-reactive COVID-IF Ab is highly expressed by the plasma membrane of hepatocytes and gastric mucosa cells, which means that it is nonorgan-specific. A related IF pattern at the level of plasma membrane, but recognizing only hepatocytes, was previously reported associated to autoimmune liver diseases, indicating organ specificity of the liver-membrane autoAb [7]. Nevertheless, we did not find differences in liver enzyme levels between IF-positive and IF-negative COVID-19 patients. By contrast, our data point to association of positive COVID-IF cross-reactive Ab with neurologic and thrombotic events of severe COVID-19 patients.

An intriguing characteristic of COVID-19 is the wide array of complications of SARS-CoV-2 infection presented by some patients, involving multiple organs and systems; however, the mechanisms of damage are still incompletely explored. In addition to direct viral infection injury, the pathogenesis of SARS appears to be mediated by a proinflammatory state [2]. Interleukin-6, an important member of the cytokine storm, is positively correlated with the severity of COVID-19 symptoms. Another possible mechanism of inflammatory damage in the context of viral infections is triggering of an autoimmune response. Antibody-mediated thrombotic mechanisms such as development of antiphospholipid Ab have been reported in some COVID-19 patients [4]. However, we did not find association of anticardiolipin or anti-beta 2 glycoprotein I IgG/M in our cohort of COVID-19 patients with thromboembolic events [8]. Pathogens can induce autoimmunity via several well studied mechanisms, with the most postulated being molecular mimicry between pathogen and self-antigens [9]. In line with this hypothesis, GBS, which is a postinfectious, Ab-mediated disease [10], was a major neurologic complication associated with COVID-19 [11]. Our finding of positive COVID-IF IgG/M in the CSF sample of a GBS patient indicates

Downloaded from https://academic.oup.com/jid/advance-article/doi/10.1093/infdis/jiaa485/5879761 by guest on 21 August 2020

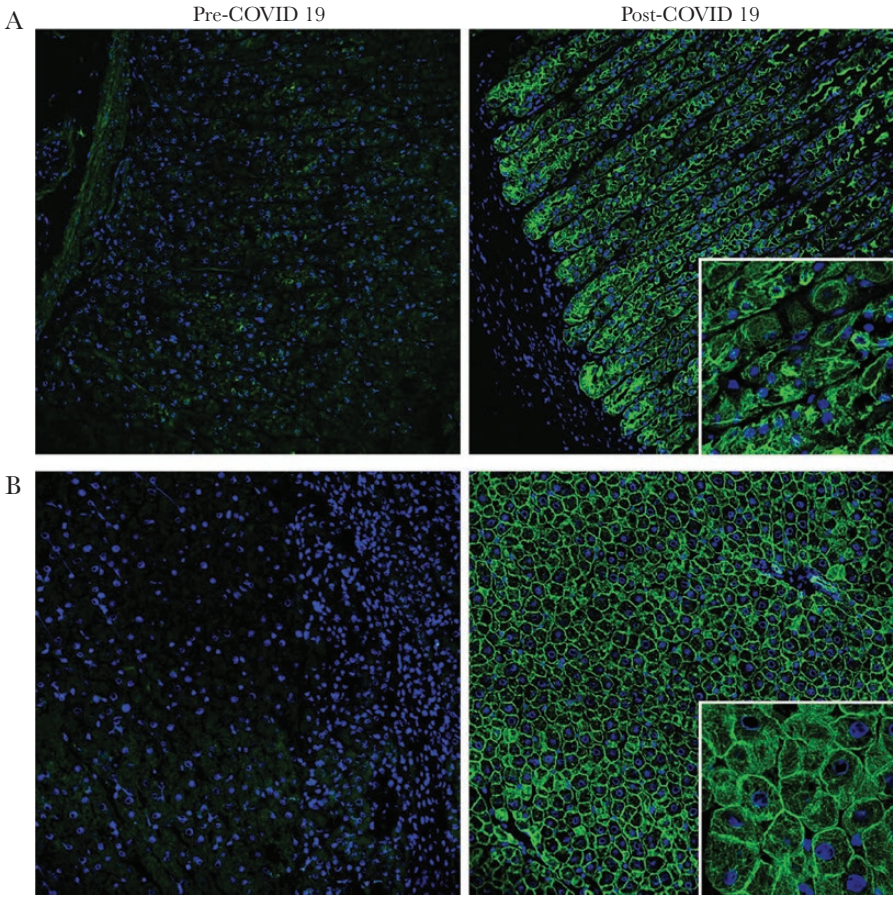

Figure 1. New immunofluorescence pattern detected after coronavirus disease 2019 (COVID-19) infection. Sequential serum samples from the same patient, before and after COVID-19, were incubated on rat triple tissue sections. Autoreactive antibodies (Abs) were revealed with goat antihuman IgG/A/M conjugated with fluorescein isothiocyanate (green). Cell nuclei were stained with 4′,6-diamidino-2-phenylindole ([DAPI] (blue). Double fluorescent (green and blue) images of stomach (A), showing the bases of gastric glands, rich in chief cell, or liver (B). No specific green fluorescence, indicative of autoreactive Ab absence, was detected with pre-COVID-19 serum sample (images on the left, as indicated). After the disease (right images), a new autoantibody was detected bound to the plasma membrane of gastric mucosa cells and hepatocytes (higher magnification in right panel inserts).

that autoreactive Ab associated with SARS-CoV2 infection were present intrathecally during acute disease, supporting a role in pathogenesis. Autoimmune tissue damage triggered by molecular mimicry between SARS-CoV-2 components and host autoantigens has recently been proposed [12]. Indeed, severe COVID-19 is associated with hypertension and diabetes, 2 comorbidities that induce chronic stress on endothelial cells and might predispose to molecular mimicry phenomena. Homology between self-proteins abnormally expressed on the plasma membrane of stressed endothelial cells and microbial antigens was previously demonstrated to trigger molecular mimicry [13]. Autoimmune reactions against endothelium can generate thrombosis and could be behind systemic vascular complications observed in severe COVID-19. We show a unique COVID-IF pattern associated with both thrombosis and neurologic complications that would involve a shared self-antigen expressed by the nervous and hemostatic systems. Further investigations are now in course in our laboratory to assess the molecular weight of the possible autoantigen and its specificity. Some glycolipids, such as sulfatides, are targets for most antiphospholipid Abs and are a major component of myelin in the nervous system and of plasma membrane of gastric mucosa cells and hepatocytes [14, 15]. However, we did not find reactivity with a commercially available dot-blot test for detection of antisulfatide auto-Ab (data not shown). A limit in the present study is that cross-reactive COVID-IF Igs were detected on rat tissues as an alternative to human tissues; however, most antigens are preserved across species, and rat is commonly used for autoAb screening. Additional limits are the low number of positive COVID-IF patients and the lack of follow-up data to know whether it is a transient autoimmune response, which was due to the urgency in communicating our finding to the medical community.

CONCLUSIONS

Indirect IF is a classic test for autoAb screening, widely accessible to most laboratories, which may allow easy identification cross-reactive Ab in COVID-19 patients. Positive COVID-IF

Downloaded from https://academic.oup.com/jid/advance-article/doi/10.1093/infdis/jiaa485/5879761 by guest on 21 August 2020

pattern might alert clinicians for higher risk of developing some severe complications such as thrombotic or neurologic events. Our work also uncovers the pathogenic relevance of postinfectious autoimmunity as another immune-mediated mechanism triggered by SARS-CoV-2 infection. Identification of a possible cross-reactive pathogenic Ab is important because some patients may benefit from immunomodulatory therapies such as plasma exchange or intravenous Igs.

Supplementary Data

Supplementary materials are available at *The Journal of Infectious Diseases online*. Consisting of data provided by the authors to benefit the reader, the posted materials are not copyedited and are the sole responsibility of the authors, so questions or comments should be addressed to the corresponding author.

Notes

Acknowledgments. We thank M. Viedma, N. Méndez, I. González, and B. Ramos for expert technical assistance, J. M. Bellón for help with statistical analyses, and R. Samaniego for confocal assistance.

Author contributions. M. T. S. and P. S.-M. contributed to conception and design. E. G.-M. and M. T. S. developed the methodology. J. L. M.-B. and P. D.-R. contributed to acquisition of clinical data. M. D. N. and M. T. S. contributed to analysis and interpretation of clinical data. P. S.-M. contributed to writing, review, and/or revision of the manuscript. P. S.-M. supervised the study.

Financial support. This work was partially funded by the Ministry of Science and Innovation ISCIII-FIS (Grant PI17/01324), cofinanced by European Regional Development Fund (ERDF)/Fonds Européen de Développement Regional (FEDER) Funds from the European Commission, "A way of making Europe."

Potential conflicts of interest. All authors: No reported conflicts of interest. All authors have submitted the ICMJE Form for Disclosure of Potential Conflicts of Interest.

References

1. Huang C, Wang Y, Li X, et al. Clinical features of patients infected with 2019 novel coronavirus in Wuhan, China. Lancet **2020**; 395:497–506.
2. Pedersen SF, Ho YC. SARS-CoV-2: a storm is raging. J Clin Invest **2020**; 130:2202–5.
3. Ruscitti P, Berardicurti O, Di Benedetto P, et al. Severe COVID-19, another piece in the puzzle of the hyperferritinemic syndrome. An immunomodulatory perspective to alleviate the storm. Front Immunol **2020**; 11:1130.
4. Rodríguez Y, Novelli L, Rojas M, et al. Autoinflammatory and autoimmune conditions at the crossroad of COVID-19. J Autoimmun **2020**; 16:102506. doi:10.1016/j.jaut.2020.102506
5. Conrad K, Roggenbuck D, Reinhold D, Sack U. Autoantibody diagnostics in clinical practice. Autoimmun Rev **2012**; 11:207–11.
6. Long QX, Liu BZ, Deng HJ. Antibody responses to SARS-CoV-2 in patients with COVID-19. **2020**; 26:845–8.
7. Hopf U, Meyer zum Büschenfelde KH, Arnold W. Detection of a liver-membrane autoantibody in HBsAg-negative chronic active hepatitis. N Engl J Med **1976**; 294:578–82.
8. Galeano-Valle F, Oblitas CM, Ferreiro-Mazón MM, et al. Antiphospholipid antibodies are not elevated in patients with severe COVID-19 pneumonia and venous thromboembolism. Thromb Res **2020**; 192:113–5.
9. Rojas M, Restrepo-Jiménez P, Monsalve DM, et al. Molecular mimicry and autoimmunity. J Autoimmun **2018**; 95:100–23.
10. Ang CW, De Klerk MA, Endtz HP, et al. Guillain-Barré syndrome- and Miller Fisher syndrome-associated *Campylobacter jejuni* lipopolysaccharides induce anti-GM1 and anti-GQ1b antibodies in rabbits. Infect Immun **2001**; 69:2462–9.
11. Toscano G, Palmerini F, Ravaglia S, et al. Guillain-Barré syndrome associated with SARS-CoV-2. N Engl J Med **2020**; 382:2574–6.
12. Cappello F, Gammazza AM, Dieli F, de Macario EC, Macario AJ. Does SARS-CoV-2 trigger stress-inducedautoimmunity by molecular mimicry? A hypothesis. J Clin Med **2020**; 9:E2038.
13. Cappello F, Conway de Macario E, Di Felice V, Zummo G, Macario AJ. *Chlamydia trachomatis* infection and anti-Hsp60 immunity: the two sides of the coin. PLoS Pathog **2009**; 5:e1000552.
14. Merten M, Motamedy S, Ramamurthy S, Arnett FC, Thiagarajan P. Sulfatides: targets for anti-phospholipid antibodies. Circulation **2003**; 108:2082–7.
15. Takahashi T, Suzuki T. Role of sulfatide in normal and pathological cells and tissues. J Lipid Res **2012**; 53:1437–50.

Downloaded from https://academic.oup.com/jid/advance-article/doi/10.1093/infdis/jiaa485/5879761 by guest on 21 August 2020

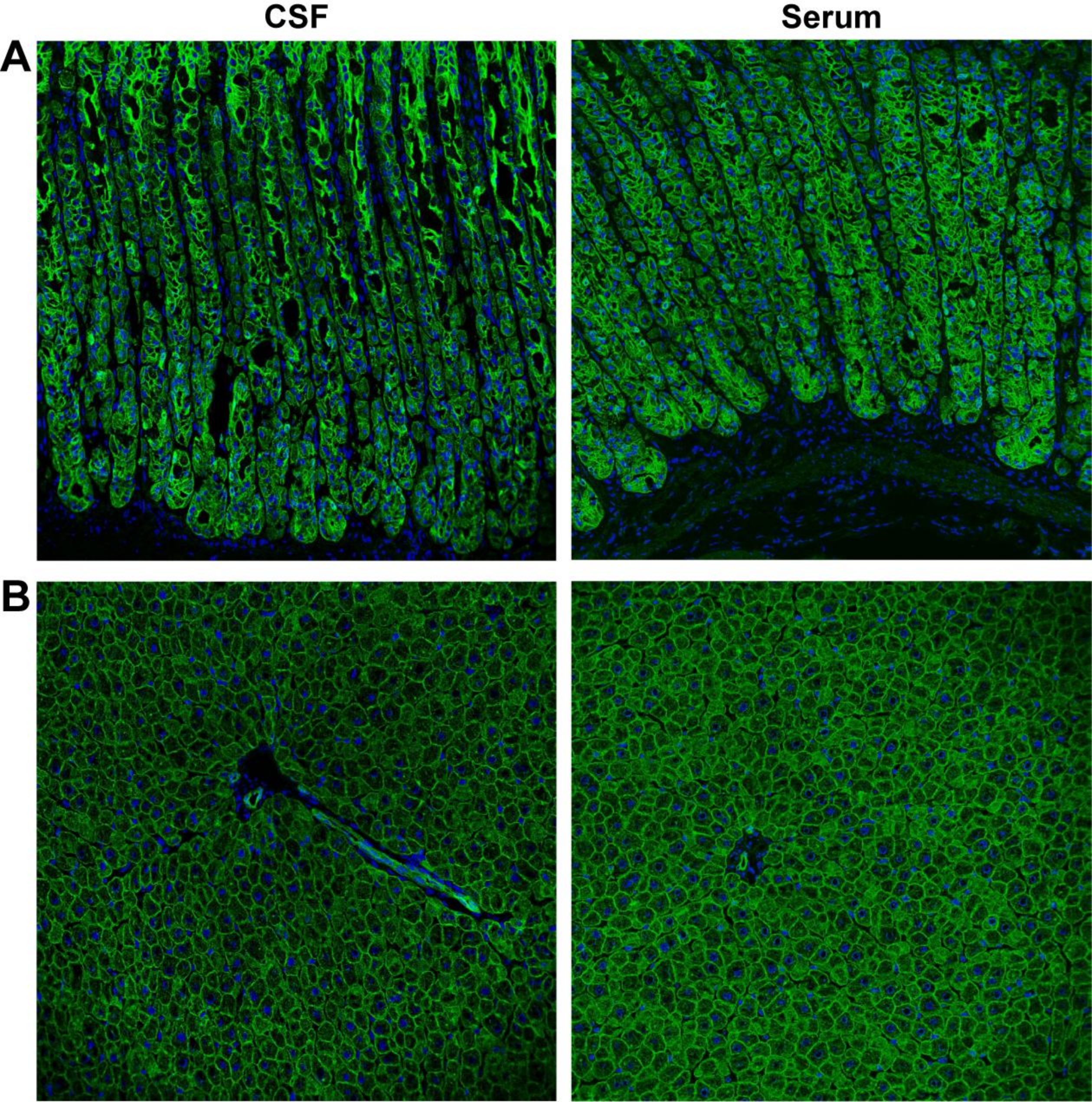
CSF
Serum
A
B