Case Reports

Intravascular Ultrasound-Guided Cardiac Intervention

in a Fontan Patient with Allergy to Contrast Media

Jun Muneuchi, MD
Seigo Okada, MD
Yusaku Nagatomo, MD
Chiaki Iida, MD
Ryouhei Matsuoka, MD
Masamitsu Shirozu, MD
Mamie Watanabe, MD

Allergy to contrast media is hazardous in patients who need multiple cardiac catheterizations. We describe the case of a 16-year-old boy who presented with fatigue and cyanosis. He had undergone a Fontan operation 14 years previously, after which he developed an allergy to iodinated contrast media. Contrast echocardiograms by manual injection of microbubbles suggested the presence of a venovenous collateral vessel from the brachiocephalic vein draining into the pulmonary vein. We used intravascular ultrasound as the sole imaging method to identify the target vessel and to guide deployment of an AMPLATZER Vascular Plug II. The patient experienced immediate improvement in his systemic saturation. Our experience shows that intravascular ultrasound may be a feasible alternative to standard imaging methods in patients with congenital heart disease who need cardiac interventional procedures and are allergic to contrast media. ***(Tex Heart Inst J 2017;44(5):373-5)***

Key words: *Adolescent; cardiac catheterization/methods; contrast media/adverse effects; coronary angiography/adverse effects; Fontan procedure; postoperative complications; treatment outcome; vascular access devices*

From: *Department of Pediatrics, Japan Community Healthcare Organization Kyushu Hospital, Kitakyushu 806-8501, Japan*

Address for reprints: *Jun Muneuchi, MD, Department of Pediatrics, Japan Community Healthcare Organization Kyushu Hospital, 1-8-1, Kishinoura, Yahatanishi-ku, Kitakyushu 806-8501, Japan*

E-mail: *jmune@msn.com*

© 2017 by the Texas Heart® Institute, Houston

Allergy to contrast media occurs rarely in pediatric patients, but it is a growing concern, particularly in those with complex congenital heart disease, because they need repeated cardiac catheterization procedures as they age. For example, patients who have had a Fontan operation to correct a single-ventricle defect may need balloon angioplasty, stent implantation, radiofrequency ablation, or closure of fenestrations or collateral vessels to maintain adequate circulation.[1-3] Therefore, finding alternatives to standard imaging methods is important for diagnosis and treatment of patients with an allergy to contrast media. We present the case of an adolescent Fontan patient with an allergy to contrast media in which intravascular ultrasound (IVUS) was the only imaging method used to identify a venovenous collateral vessel in a cyanotic and to guide deployment of a vascular plug.

Case Report

In June 2016, a 16-year-old boy who had been diagnosed with double-inlet left ventricle, experienced fatigue on exertion. His oxygen saturation level was 90% at rest and 85% during exercise. He had undergone pulmonary artery banding at 2 months of age, the implantation of a bidirectional Glenn shunt at 1 year, and a Fontan operation with an extracardiac conduit at 2 years. During the Fontan operation, he had developed palsy of the left phrenic nerve, which compromised his hemodynamic status. He also had a history of anaphylactic reaction to iodinated contrast media; at 3 years of age, he started to wheeze and became hypotensive just after the injection of contrast media during a follow-up cardiac catheterization.

Because echocardiograms and cardiac magnetic resonance images obtained without contrast failed to reveal the cause of the patient's cyanosis, we performed diagnostic cardiac catheterization under fluoroscopic guidance. His pulmonary artery pressure was 15 mmHg; pulmonary-to-systemic blood flow ratio, 0.89; and cardiac index (Fick method), 4.6 L/min/m^2. Contrast echocardiography with manually injected agitated saline solution was performed in the brachiocephalic vein, superior and inferior venae cavae, and hepatic veins. In the brachiocephalic vein, a large number of microbubbles drained into the left atrium, suggesting that a venovenous collateral vessel from the brachiocephalic vein was draining into the pulmonary vein. Under fluoroscopic guidance, a 6F Judkins left (JL) guiding catheter was introduced into the right femoral vein

and advanced to the brachiocephalic vein. The guiding catheter captured the orifice of a venovenous collateral vessel.

With the approval of our institutional review board and written informed consent from the patient's parents, we decided to occlude the vessel with an AMPLATZER™ Vascular Plug II (AVP II) (St. Jude Medical, Inc.; St. Paul, Minn) under IVUS guidance. A 0.014-in Aguru™ guidewire (Boston Scientific Corporation; Natick, Mass) and an Eagle Eye Platinum™ ST digital IVUS catheter (Koninklijke Philips N.V.; Best, The Netherlands) were advanced into the collateral vessel so that cross-sectional images of each section could be obtained (Fig. 1). The vessel diameters ranged from 3.4 to 5.8 mm. A side branch, which arose at the level of the collateral vessel, was used as a landmark during device placement (Fig. 1D). After the 6F JL guiding catheter was advanced as far as possible into the collateral vessel, a 10-mm AVP II was advanced through it. The device was carefully positioned to cover the entire length of the vessel (Fig. 2). Before releasing the device, we gently pushed and pulled on its cable to confirm its stability. After deployment, contrast echocardiograms with injection of microbubbles from the guiding catheter showed no microbubbles in the left atrium, and the patient's oxygen saturation level increased to 95%. The total procedural time was 200 min.

As of October 2016, the patient was being monitored in our outpatient clinic, and his oxygen saturation levels at rest and during exercise had improved.

Discussion

Intravascular ultrasound, accomplished by using a miniature ultrasonographic probe mounted on a catheter, produces detailed cross-sectional images of vessels. Clinically, IVUS has been used to evaluate coronary artery disease and as a supplement to standard angio-

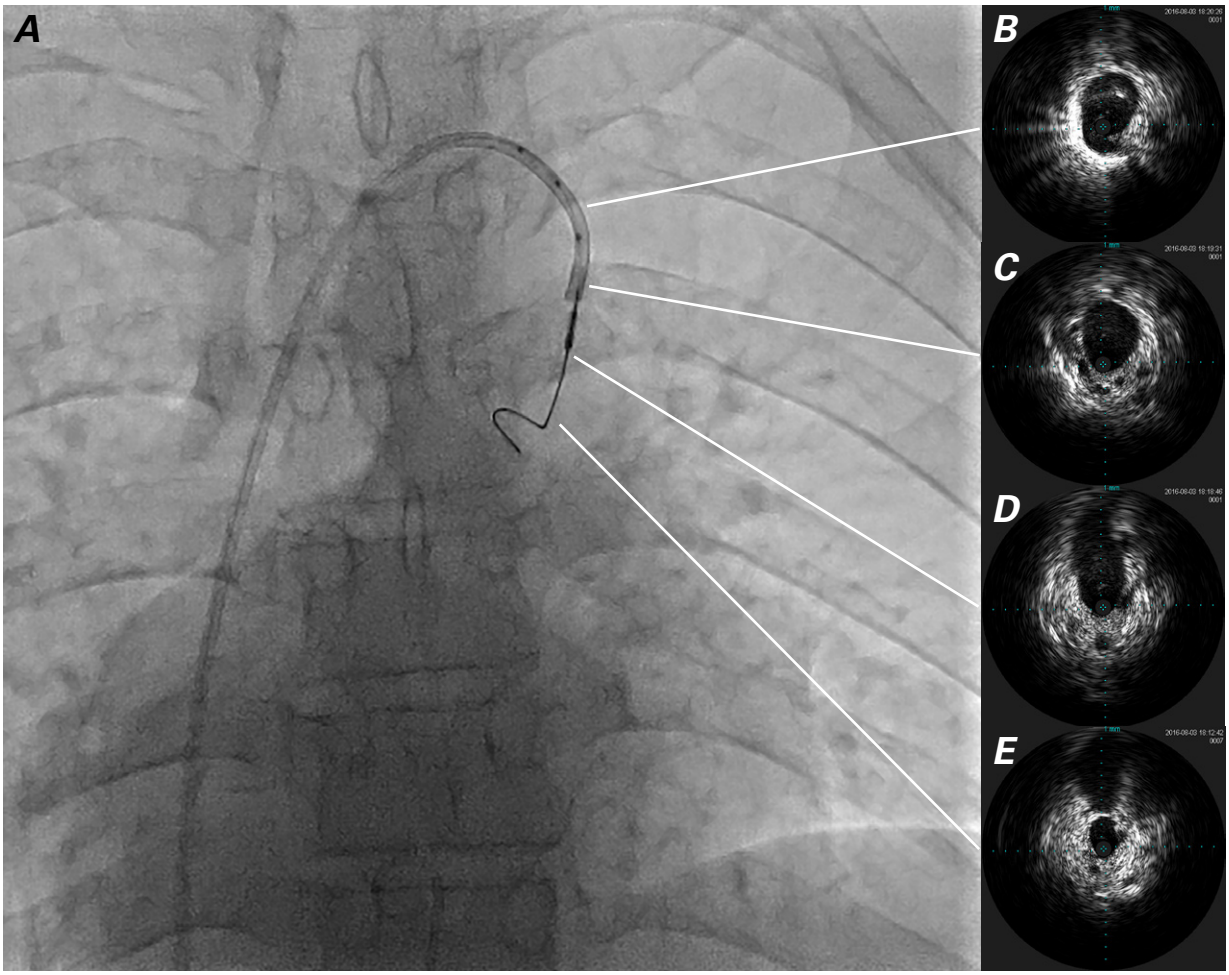

Fig. 1 ***A****) Fluoroscopic image shows the Judkins left guiding catheter and an intravascular ultrasound catheter advanced over a wire and into the venovenous collateral vessel. Intravascular ultrasonograms show cross-sectional images along the vessel, the diameters of which were* ***B****) 5.5 mm at its orifice,* ***C****) 5.8 mm at the tip of the Judkins catheter,* ***D****) 3.9 mm at the tip of the intravascular ultrasound catheter, and* ***E****) 3.4 mm at its distal end.*

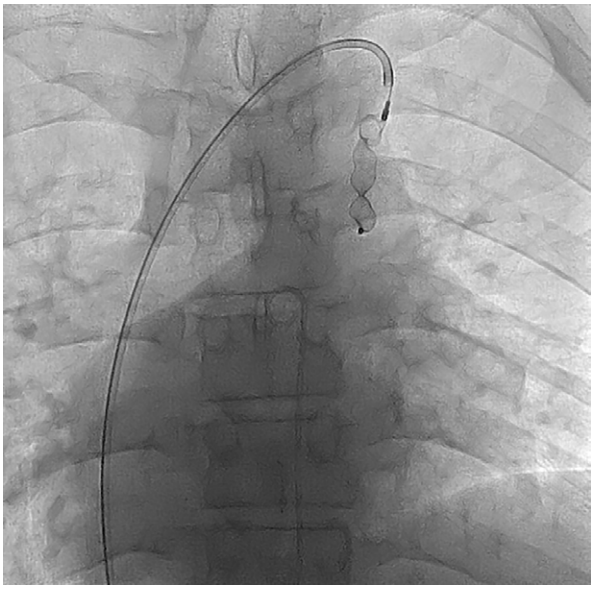

Fig. 2 *Fluoroscopic image shows the deployed 10-mm* AMPLATZER *Vascular Plug II, occluding the venovenous collateral vessel that had drained from the brachiocephalic vein into the pulmonary vein.*

graphic techniques in evaluating peripheral vascular disease. In 2014, Casey and colleagues[4] described the IVUS-guided angioplasty of a hemodialysis loop graft in a 57-year-old woman with a history of allergy to iodinated and gadolinium contrast media. In their case, IVUS provided adequate images of graft stenosis and guided the positioning of a 6-mm-diameter angioplasty balloon.

Our case shows that IVUS-guided catheter intervention can be used as an alternative to conventional angiography in patients with congenital heart disease. We were able to identify the venovenous collateral vessel that was causing cyanosis in our patient who had Fontan circulation. Moreover, intravascular ultrasound enabled us to precisely measure the diameter of the target vessel, to select an appropriate occlusion device, and to successfully deploy the AVP II. Intravascular ultrasound is not suitable for all patients with Fontan circulation because collateral vessels are often tortuous, making it difficult to advance and deploy an occluding device in an ideal position. In such instances, contrast transthoracic or transesophageal echocardiography with agitated saline solution could be used in conjunction with IVUS-guided catheter intervention.

Individuals with a history of allergy to contrast media have a high risk of allergic reaction upon repeat exposure. Cardiac disease, dehydration, hematologic and metabolic conditions, and extremes of age have also been mentioned as risk factors for contrast allergy.[5] Gadolinium, which is often used in magnetic resonance imaging, has been used in diagnostic and interventional vascular procedures to obtain satisfactory images in patients with allergy to iodinated contrast media,[6,7] but this is not the practice at our institution.

Our experience proves the feasibility of performing IVUS-guided interventional procedures in patients with Fontan anatomy and allergies to contrast media.

References

1. Mullins CE. Complications of diagnostic and therapeutic cardiac catheterizations. In: Cardiac catheterization in congenital heart disease: pediatric and adult. Malden (MA): Blackwell Futura; 2006. p. 895-924.
2. Kaulitz R, Ziemer G, Paul T, Peuster M, Bertram H, Hausdorf G. Fontan-type procedures: residual lesions and late interventions. Ann Thorac Surg 2002;74(3):778-85.
3. Goldstein BH, Holzer RJ, Trucco SM, Porras D, Murphy J, Foerster SR, et al. Practice variation in single-ventricle patients undergoing elective cardiac catheterization: a report from the Congenital Cardiac Catheterization Project on Outcomes (C3PO). Congenit Heart Dis 2016;11(2):122-35.
4. Casey PE, Miranda CJ, Al-Khaffaf H, Woodhead PM. Intravascular ultrasound-guided angioplasty of hemodialysis loop graft in a patient with contrast allergy. J Vasc Access 2014;15(5):424-6.
5. Bottinor W, Polkampally P, Jovin I. Adverse reactions to iodinated contrast media. Int J Angiol 2013;22(3):149-54.
6. Bokhari SW, Wen YH, Winters RJ. Gadolinium-based percutaneous coronary intervention in a patient with renal insufficiency. Catheter Cardiovasc Interv 2003;58(3):358-61.
7. Juneman E, Saleh L, Thai H, Goldman S, Movahed MR. Successful coronary angiography with adequate image acquisition using a combination of gadolinium and a power injector in a patient with severe iodine contrast allergy. Exp Clin Cardiol 2012;17(1):17-9.