The Triological Society
UPHOLDING THE NOBLE LEGACY

Premiere Publications from The Triological Society

Read all three of our prestigious publications, each offering high-quality content to keep you informed with the latest developments in the field.

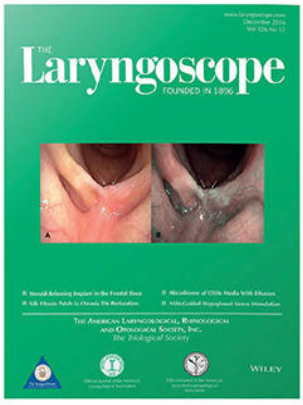

THE Laryngoscope
FOUNDED IN 1896

Editor-in-Chief: Samuel H. Selesnick, MD, FACS

The leading source for information in head and neck disorders.

Laryngoscope.com



Laryngoscope Investigative Otolaryngology
Open Access

Editor-in-Chief: D. Bradley Welling, MD, PhD, FACS

Rapid dissemination of the science and practice of otolaryngology-head and neck surgery.

InvestigativeOto.com



ENTtoday
A publication of the Triological Society

Editor-in-Chief: Alexander Chiu, MD

Must-have timely information that Otolaryngologist-head and neck surgeons can use in daily practice.

Enttoday.org

WILEY

Check for updates

The Laryngoscope
© 2021 The American Laryngological,
Rhinological and Otological Society, Inc..

Allergy-Related Sialodochitis: A Preliminary Cohort Study

Ya-Ning Zhao, DDS, SMD; Li-Qi Zhang, DDS, SMD; Ya-Qiong Zhang, DDS, SMD; Yan Chen, MD, DDS; Deng-Gao Liu, MD, DDS; Guang-Yan Yu, PhD, DDS

Objectives/Hypothesis: To explore the clinically feasible diagnosis criteria and treatment outcomes of allergy-related sialodochitis (ARS).

Study Design: Prospective Cohort Study.

Methods: Ninety-six consecutive patients were enrolled by the following criteria: 1) recurrent swelling of ≥2 large salivary glands that lasted for ≥3 months; 2) with mucus plug exudations; 3) with atopic diseases; 4) ductal stenosis and/or ectasia. Sixty-four patients with elevation of peripheral blood eosinophil (PBE) and/or serum IgE level comprised group A (highly-suspected ARS group), while the remaining 32 comprised group B (patients without confirmed evidence of ARS). These patients were treated with interventional endoscopy. A chronic obstructive sialadenitis symptom (COSS) questionnaire was used to quantify the treatment outcomes.

Results: In group A, Serum IgE was elevated in 84.4% of patients and PBE was elevated in 34.4% of patients. Percentage of submandibular gland involvement was higher in group A than group B (48.4% vs. 18.8%). On sialograms, the snowflake changes of branch ducts were seen in higher percentage of group A compared with group B (59% vs. 35% for parotid glands, 27% vs. 8% for submandibular glands, respectively). Mucus plug smears showed abundant eosinophils in 14 group A patients. Biopsy of five group A patients revealed significant eosinophil infiltration around the main and interlobular ducts. During follow-up, the COSS scores were significantly decreased in both groups, and group B was improved better than group A.

Conclusion: PBE and serum IgE are important diagnostic indexes of ARS. Mucus plug smear or histopathology verifies the diagnosis. Interventional endoscopy is helpful for ARS cases.

Key Words: Eosinophil, immunoglobulin E, sialodochitis, allergy, sialendoscopy.

Level of Evidence: 3

***Laryngoscope*, 00:1–6, 2021**

INTRODUCTION

Chronic obstructive sialadenitis (COS) is characterized by repeated pain and swelling of salivary glands during meals, which often causes significant discomforts and negative quality of life.[1,2] The cause is still unclear, which might include developmental anomalies, scar stricture, radiation injury, allergy, and autoimmune factors.[3] With the development of endoscopy, the recalcitrant symptoms are significantly relieved in 80% to 90% of these patients.[4] However, 10% to 20% of these patients are refractory to the traditional and endoscopic approaches.[5]

Since 1879, recurrent major salivary gland swelling condition with mucus plugs and allergies were termed "sialodochitis fibrinosa," "allergic parotitis," or "eosinophilic sialodochitis (ES)," but only sporadic cases were reported.[6–11] In 2017, Baer reported 3 similar patients and 56 previously reported cases after a comprehensive search of the medical literature, and proposed criteria 1 to 7 for the diagnosis of ES.[7] Among these criteria, the mandatory features of ES included eosinophil-rich mucus plugs or histopathologic evidence of periductal eosinophil- and lymphocyte-rich inflammation.[7] Recently, Zhu et al. discovered significant expression of allergy-related cytokines and suggested allergy-related pathogenesis of ES.[12] All these confirmed the existence of a specific type of sialadenitis related to allergy. Therefore, ES might also be named as allergy-related sialodochitis (ARS).

Based on the principle of minimally invasive surgery and gland preservation, histological samples of ARS were often unsuitable for most cases. Further, a systematic cohort study related to treatment outcomes was lacking.[7–12] The aim of this study was to explore the clinically feasible diagnosis criteria and treatment options of ARS based on a relatively larger sample size.

MATERIALS AND METHODS

The study protocol was approved by the Ethics Committee for Human Experiments of the Peking University School of

From the Department of Oral and Maxillofacial Radiology (Y.-N.Z., L.-Q.Z., Y.-Q.Z., D.-G.L.), Peking University School and Hospital of Stomatology & National Engineering Laboratory for Digital and Material Technology of Stomatology & Beijing Key Laboratory of Digital Stomatology, Beijing, People's Republic of China; Department of Oral Pathology (Y.C.), Peking University School and Hospital of Stomatology & National Engineering Laboratory for Digital and Material Technology of Stomatology & Beijing Key Laboratory of Digital Stomatology, Beijing, People's Republic of China; and the Department of Oral and Maxillofacial Surgery (G.-Y.Y.), Peking University School and Hospital of Stomatology & National Engineering Laboratory for Digital and Material Technology of Stomatology & Beijing Key Laboratory of Digital Stomatology, Beijing, People's Republic of China.

Editor's Note: This Manuscript was accepted for publication on March 02 2021.

The authors have no funding, financial relationships, or conflicts of interest to disclose.

Send correspondence to Deng-Gao Liu, MD, DDS, Department of Oral and Maxillofacial Radiology, Peking University School and Hospital of Stomatology & National Engineering Laboratory for Digital and Material Technology of Stomatology & Beijing Key Laboratory of Digital Stomatology, #22 Zhongguancun South Street, Haidian District, Beijing 100081, People's Republic of China.

E-mail: kqldg@bjmu.edu.cn

DOI: 10.1002/lary.29508

Stomatology (PKUSSIRB-201840185). Informed consent was obtained from all patients.

Patients Selection

Inclusion criteria: 1) recurrent swelling of ≥2 large salivary glands that lasted for ≥3 months; 2) history of mucus plug exudations; 3) with comorbid atopic diseases; 4) aged 18 to 75 years; 5) existence of stenosis and/or ectasia in the ductal system.

Exclusion criteria: 1) neoplastic diseases or intraductal stones associated with the same gland; 2) history of radiation or radioactive iodine ; 3) IgG4-related sialadenitis; 4) Sjögren syndrome; 5) eosinophilic hyperplastic lymphogranuloma; 6) severe systemic diseases.

Study Design

For all the included patients, clinical signs and number of involved glands were recorded. History of the comorbid atopic diseases was also inquired. Sialography was performed for all the involved glands. Appearance of the main and branch ducts was analyzed independently by two experienced oral radiologists who reached a consensus by discussion. Moreover, routine blood cell and serum laboratory tests, as well as allergy and immune-related laboratory tests (total IgE, IgG and subtypes, IgA, IgM, serum allergen tests), were performed. If mucus plugs were available, smear cytology was performed, and eosinophils were observed by hematoxylin–eosin (HE) and Giemsa staining. For patients with severe symptoms, histopathologic examination of the involved salivary glands (HE staining) was performed after acquisition of the additional informed consent. The mucus plug smears and histopathologic slides of all cases were reviewed by one experienced pathologist.

Surgical Approaches and Follow-up Schedule

For the included patients, cases with elevated total serum IgE and/or elevated peripheral blood eosinophil (PBE) count were defined as group A (highly-suspected ARS group). An elevated PBE count was defined as $>0.52 \times 10^9$ cells/L or >8.0% of leukocytes. An elevated serum total-IgE was defined as >100 IU/ml. The remaining cases were defined as group B (patients without confirmed evidence of ARS). Patients in both groups were treated with interventional endoscopy. A 0.9 mm/1.15 mm Laduscope PD-ZS-0084 endoscope (PolyDiagnost, Pfaffenhofen, Germany) was used. The involved salivary gland ducts were explored and dilated with continuous infusion of saline/dexamethasone (100 ml/10 mg) mixture (approximately 25–30 ml/glands). Ductal debris and mucous plugs were removed by massage of the glands and use of grasping wire. If a stenotic lesion was observed, mechanical dilation was used for dilation of the stenotic duct. Finally, prednisone acetate (50 mg/glands) was infused. After operation, maintenance of oral hygiene, regular gland massage, as well as avoidance of irritating foods and allergens were suggested. In both groups, intraductal administration of prednisone acetate (50 mg/glands) was performed once a month for 3 months. For patients with poor improvement of symptoms, an anti-allergic drug levocetirizine was prescribed (5 mg/day) for 2 weeks. Six months after the operation, clinical outcomes were evaluated by a 10-question chronic obstructive sialadenitis symptom (COSS) questionnaire, which was acquired preoperatively and 6 months after treatment. The following data were surveyed: swelling frequency, swelling severity, pain frequency, pain severity, itching severity, xerostomia, salty or purulent exudate, mucus plug exudate, interference with chewing, and interference with speech and daily activities. Each question used a Likert-type response scale (0–10). The sum of scores yielded a COSS score between 0 and 100. For a small part of patients who could not be revisited directly, the COSS questionnaire was surveyed by telephone calls or emails.

Treatment Evaluation and Statistical Analyses

Statistical analyses were performed using SPSS 25.0 (SPSS, Chicago, IL, USA). The mean ± standard deviation or median (Q1–Q3) was used for continuous variables (serum total IgE, and COSS scores, et al.), and compared by the independent *t*-test or Wilcoxon rank test between two groups. Categorical variables (patient number with raised PBE and sialograms, et al.) were compared using the chi-square or Fisher exact test. Difference was considered significant for a *P* value less than .05.

RESULTS

Clinical Features

A total of 96 patients (27 males and 69 females) were enrolled from March 2018 to December 2019. Their ages ranged from 27 to 71 years (median: 48 years). There were 64 cases in group A and 32 in group B.

The male–female ratio in group A was 23:41, which was significantly higher than that of group B (4:28, $P = .016$). The median age was 47 years in group A and 49 years in group B ($P = .275$). Overall, 91 parotid glands (PGs) and 60 submandibular glands (SMGs) were affected in group A, while 54 PGs and 12 SMGs were affected in group B. The average number of affected glands was 2.36 ± 0.93 in group A, which was slightly greater compared with group B (2.06 ± 0.63; $P = .027$). Regarding number of glands, the percentage of SMG involvement was higher in group A compared with group B (39.7% vs. 18.2%, $P = .002$). As for number of patients, percentage of SMG involvement was also higher in group A than that in group B (31/64, 48.4% vs. 6/32, 18.8%, $P = .005$). The median symptom duration was 24 and 27 months in group A and B, respectively ($P = .656$). The comorbid allergic diseases included allergic rhinitis, asthma, eczema, urticaria (Table I). Twenty-one patients in group A and 11 in group B had a history of anti-allergic medication.

Laboratory Findings

In group A, 42 patients had elevated total IgE but normal PBE; 10 had normal total IgE but elevated PBE; 12 had both elevated total IgE and PBE (Table I). in addition, the level of one or a combination of serum IgG1, IgG2, IgG3, IgA, or IgM was slightly elevated in 13 patients of group A and one of group B. Serum IgG4 was slightly elevated in one group A patient, but IgG4-related siadadenitis was excluded by the clinical and ultrasonographic appearances. As for allergen screening, low to high positive reaction was present in 28 group A patients (28/37, 76%), while low positive reaction was present in 11 patients of group B (11/16, 69%).

TABLE I.
The Clinical and Laboratory Features of Two Groups.

	Group A	Group B
Affected glands		
Number of affected glands	91 PGs, 60 SMGs	54PGs, 12SMGs
Bilateral PGs, n	33	26
Bilateral SMGs, n	17	5
PGs and SMGs, n	14	1
Atopic disease		
Allergic rhinitis, n	56	27
Asthma, n	13	3
Eczema, n	9	2
Urticaria, n	12	2
Laboratory exminations		
Raised IgE only, n (value)	42 (239.00, 152.88–364.55 IU/ml)	
Raised PBE only, n (value)	10 (53.48 ± 24.47 IU/ml)	
Raised PBE and IgE, n (value)	12 (527.38 ± 361.31 IU/ml)	
Normal PBE and IgE, n (value)		32 (35.44, 19.85–64.72 IU/ml)

Ig = immunoglobulin; IgE = serum total-IgE; n = patient number; PBE = peripheral blood eosinophil; PG = parotid gland; SMG = submandibular gland.

Imaging Characteristics

Apart from one SMG with severe ductal stenosis, sialography was successfully performed in all the affected glands. Sialographic appearances were divided into three types: I, mild to severe stenosis of the main duct but otherwise approximately normal; II, ectasia and stenosis of the main and branch ducts (Fig. 1); III, snowflake or flocculent changes of branch ducts with coexistence of ectasia and/or stenosis of the main duct (Fig. 2). As for PGs, group A had higher percentage of type III sialograms than group B (59% vs. 35%, P = .005). As for SMGs, type I sialograms were absent, and group A had also higher percentage of type III sialograms than group B (27% vs. 8%). (Table II).

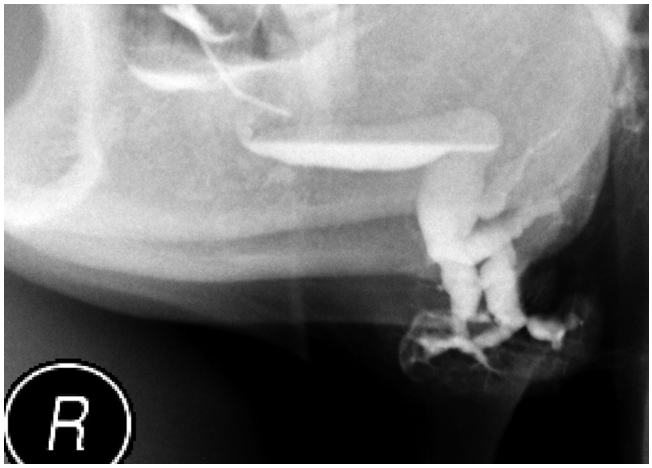

Fig 1. Sialogram of the right submandibuler gland showed ectasia and stenosis of the main and branch ducts (type II).

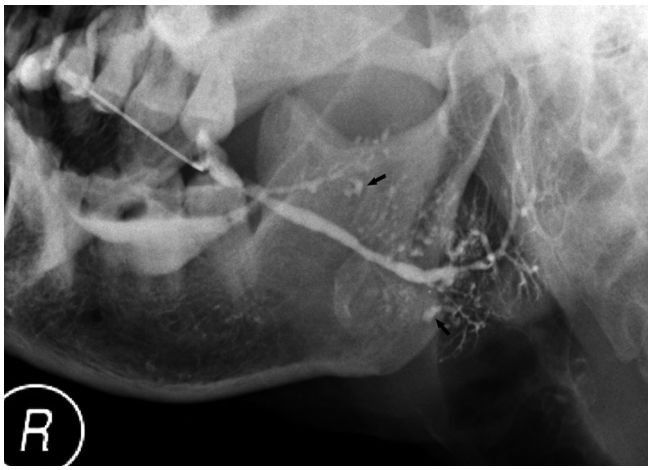

Fig 2. Sialogram of the right parotid gland showed the snowflake appearance of the branch ducts (black arrows), as well as ectasia and stenosis of the main duct (type III).

TABLE II.
Sialographic Appearances of Two Groups (n, %).

		Type I	Type II	Type III	Total
PG	Group A	12 (13%)	25 (28%)	54 (59%)	91
	Group B	5 (9%)	30 (56%)	19 (35%)	54
SMG	Group A	—	43 (73%)	16 (27%)	59*
	Group B	—	11 (92%)	1 (8%)	12

*Sialographic procedure failed in one of the 60 affected submandibular glands.
n = number; PG = parotid gland; SMG = submandibular gland.

Cytological and Pathological Findings

Sixteen patients in group A and four in group B underwent mucus plug smear tests. Abundant eosinophils were seen in 14 group A patients (Fig. 3), while

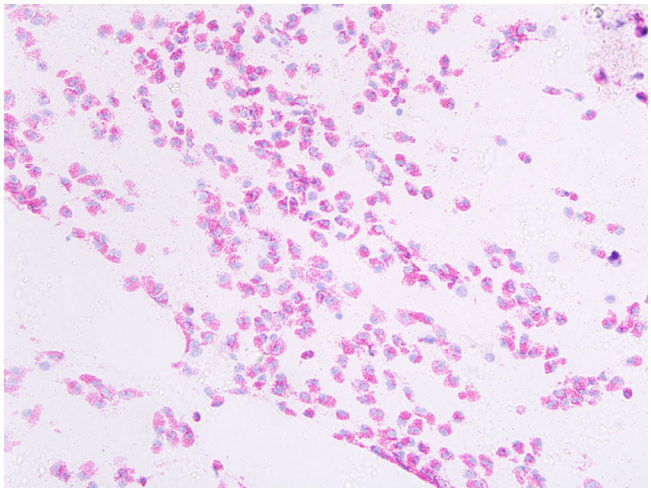

Fig 3. Mucus plug cytology by hematoxylin–eosin staining showed abundant eosinophils (×400). [Color figure can be viewed in the online issue, which is available at www.laryngoscope.com.]

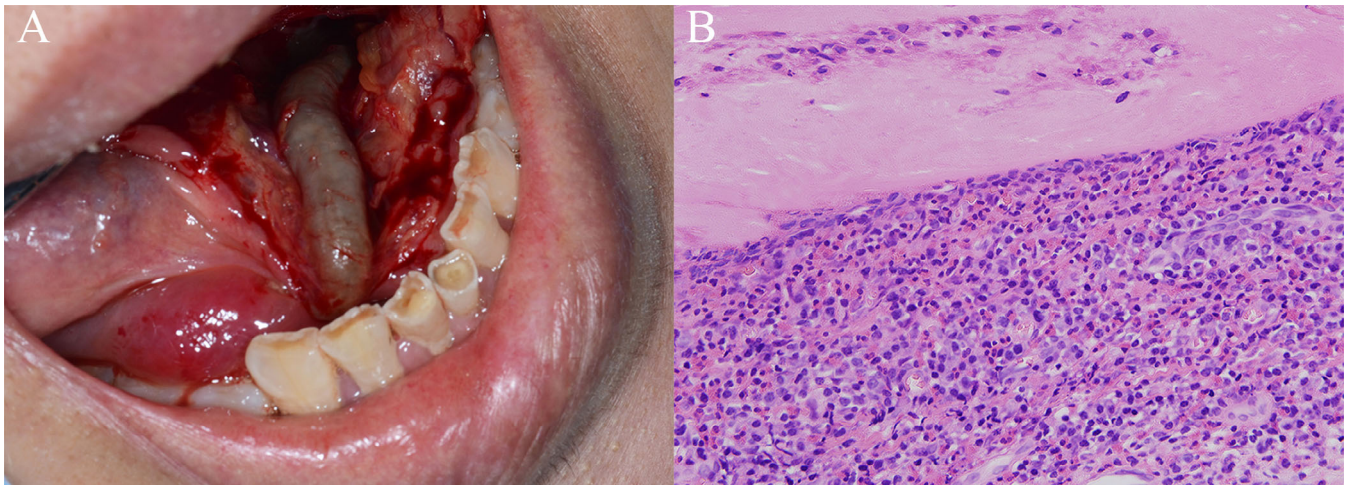

Fig 4. A 57-year old female patient with comorbid allergic rhinitis complained of long-term recurrent swelling of four major salivary glands. Mucus plug exudation lasted for several years after removal of the left submandibuler gland. (The sialograms were demonstrated as Figs. 1 and 2). A, During removal operation, the residual main duct was seen to be firm and dilated, and the lumen was filled with mud-like mucus plugs. B, Eosinophil infiltration and lymphocyte-rich inflammation were evident in the ductal wall (HE, ×400). [Color figure can be viewed in the online issue, which is available at www.laryngoscope.com.]

eosinophils were seen only in one of group B patients. Histopathologic examination was performed in five group A patients, including incisional biopsy in three SMG cases via an intraoral approach, and main duct removal in two SMG cases. In the three biopsy samples, eosinophil infiltration was seen around the interlobular ducts, while the acini were generally unaffected. Both duct removal cases had a long history of four major gland swelling with comorbid allergic rhinitis. Strikingly, both of them complained of disgustingly recurrent swelling and mucus exudation for several years after removal of the left SMG. Therefore, removal of the residual main duct was proposed. During operation, the residual main ducts were seen to be firm and dilated (Fig. 4A), and the lumens were filled with mud-like mucus plugs. Histologically, eosinophil infiltration and lymphocyte-rich inflammation were evident in the ductal wall (Fig. 4B), associated with scattered eosinophils in the intraductal mucus plugs.

Endoscopic Findings and Treatment Outcomes

Endoscopic procedures were successfully performed for all the affected glands. Endoscopic appearances of the main ducts were approximately consistent with their sialograms. Inflammatory, web-associated or fibrous stenoses were always seen in the distal 1/3 region of the main duct, and ectasia was often found in the middle to proximal 1/3 region. Strikingly, long and firm mucus plugs were more frequently found in group A. All patients sustained the procedures uneventfully. During the average 6-months follow-up, anti-allergic medications were prescribed for 15 group A patients, while none took anti-allergic medication in group B. All the patients completed the COSS questionnaire. Wilcox sum rank test showed that the COSS scores were significantly decreased in both groups ($P < .001$), and the decrease of scores was lower in group A compared with group B ($P = .013$) (Table III).

DISCUSSION

ARS (or ES) should be regarded as a separate type of chronic inflammatory disease of the salivary glands, which is different from the conventional COS. Since the first report of "sialodochitis fibrinosa" by Kussmaul, similar cases with eosinophil-rich mucus plugs in the major salivary glands and elevated PBE were subsequently reported.[7–11,13,14] These cases were also named as "allergic parotitis" in the mid-20th century.[6,15] Despite this, there were no well-recognized diagnostic criteria and treatment evaluations for these specific cases.

In 2017, Baer reviewed a case series of 59 ES patients defined as recurrent painful major salivary gland swelling associated with eosinophil-rich mucus plugs or histopathologic finding of periductal eosinophilic infiltration.[7] Allergic symptoms were present in 39 cases, and Elevated PBE and IgE levels were present in >70% of those cases. In Baer's definition of ES, the mandatory features included eosinophil-rich mucus plugs or histological evidence. Our center had used sialendoscopy for >15 years, and had treated >1,500 patients with different types of sialadenitis. There was an increasing percentage of patients who often complained of itchy swelling of multiple major salivary glands, often associated with long and firm mucus plugs. Most of these patients had atopic

TABLE III.
Pre- and Post- Treatment COSS Questionnaire Scores of Two Groups.

	Group A	Group B	*P*
Pre-treatment, m (Q1–Q3)	62.5 (49.5–76.8)	55.0 (45.3–63.8)	.045
Post-treatment, m (Q1–Q3)	36.0 (22.3–49.0)	21.5 (9.5–32.8)	.000
Decrease Value, m (Q1–Q3)	22.5 (9.5–36.5)	35.0 (20.0–43.8)	.013

COSS = Chronic Obstructive Sialadenitis Symptom; m = median; Q1–Q3 = first quartile–third quartile.

diseases during inquiry. The incidence rate of ARS might be underestimated, in view of the increased morbidity of allergic diseases caused by environmental issues in recent years.[12,16]

The present study revealed several clinical features of ARS. The percentage of male patients in the group A was significantly higher compared with group B, that is, relatively more male patients might suffer from ARS, which was similar to the result of Baer et al.[7,12] Besides, group A involved more salivary glands compared with group B, which was consistent with the results of Baer et al. and Zhu et al.[7,12] Moreover, percentage of submandibular gland involvement was higher in group A than that in group B. The underlying mechanisms needed further investigation.[15,17–19]

Among the total 96 patients, only 12 had simultaneous elevation of IgE and PBE. The relatively lower percentage of coexistence of elevated IgE and PBE might be explained by the fact that 1/3 of patients had a history of anti-allergic medications for the comorbid atopic diseases, which might decrease the count of PBE or serum total IgE.[12] Therefore, we proposed that increase of either PBE or serum IgE as a compromise to define ARS patients. It was somewhat confusing to use the term "eosinophilic sialodochitis" just based on increased serum IgE level alone. Therefore, the term "ARS" was used as a substitute.

Sialograms could specifically show the abnormal changes of the main and branch ducts in obstructive sialodochitis. In patients included in this study, appearance of the sialograms was divided into three types. Type I and II sialograms showed findings similar to conventional sialodochitis, which was not specific for ARS. Type III sialograms, that is, snowflake or flocculent changes of branch ducts accompanied by irregular stenosis and ectasia of the main duct, occurred probably because of the mucus plugs obstructed in the interlobar ducts. The higher percentage of type III sialograms in group A could be attributed to the elevation of IgE or PBE and frequent exudations of mucus plugs.[12,20,21] Despite this, sialograms varied greatly among cases and glands, and could only be used as a reference for the diagnosis of ARS. Further evidences were needed to confirm whether type III represented the typical sialograms of ARS cases.

The histopathology of ES (or ARS) had some striking features.[7,12] This disease primarily involved the larger ductal structures and spared the parenchyma, which was in some way similar to that of bronchial asthma and eosinophilic esophagitis, characterized by luminal stenosis comorbid with allergens.[22] According to Baer, the most intense inflammation of ES involved the large ducts closest to the oral cavity, suggesting a possible exposure to refluxed intra-oral allergens.[23] This was also found in our cases, especially in the two SMG cases, who had long-term symptoms of the ducts after removal of main gland. According to Zhu et al., another histological feature was epithelial mucous metaplasia of the main and interlobular ducts, which might be the pathological basis for recurrent mucus exudations.[12] In Zhu's study, IgE-positive cells and tryptase-positive mast cells were frequently seen, and the allergy-related cytokines (interleukin-4, interleukin-13, and eotaxin) were highly expressed around the large ducts.[12] All these suggested an allergic etiology of this disease.

For ARS (or ES) patients, the reported treatments included anti-allergic medications, systemic corticosteroid, intraductal irrigation of saline, steroid and/or antibiotics, dochoplasty, and sialoendoscopy, as well as glandular resection.[7] In the present study, the included cases were treated mainly with interventional endoscopy and intraductal steroid irrigation. The treatment effects were evaluated via a simplified COSS questionnaire. The COSS questionnaire was a survey instrument that could potentially be used to assess the impact of treatment options.[24,25] The results showed that the symptoms were significantly relieved in both groups after treatment. Although approximately 30% patients in both groups who had used anti-allergic medications had recalcitrant symptoms before endoscopic procedures, the symptoms were significantly improved following treatment. It can be inferred that endoscopic procedures played an important role in the treatment options. The improvement of scores was worse in group A compared with group B. This indicated that the elevation of IgE and PBE might aggravate the treatment difficulties.[26,27] It should be stated that evaluation of treatment outcomes was based mainly upon subjective indexes. Objective evidences such as laboratory tests and histologic findings were necessary in future study.

Based upon the aforementioned, we suggested the following clinical diagnostic criteria for ARS: 1) recurrent swelling of major salivary glands for ≥3 months; 2) at least two major salivary glands affected; 3) comorbid with allergic disease; 4) ectasia and/or stenosis of the main and branch ducts; 5) elevation of PBE or serum total IgE; 6) intraductal mucus plugs with eosinophils infiltration; 7) eosinophil-rich inflammation around the large ducts; and 8) exclusion of IgG4-related disease and Kimura's disease. Criteria 1 to 4 were not specific but should be fulfilled. Criterion 5 was the serological index for the suspicion of ARS. Criterion 6 or 7 could further verify the diagnosis. In the present study, mucus plugs were occasionally obtained, and most patients with these inflammatory lesions were reluctant to undergo an open surgery for biopsy. Therefore, criterion 1 to 5 were satisfied in all group A patients, but only some of them met the criterion 6 or 7. As for most cases with IgG4-related sialadenitis and Kimura's disease, the clinical, laboratory, and imaging features were quite different, which were helpful for the differentiation.[28,29] Although division of the two groups was insufficient to distinguish true ES patients, it might be useful for treatment and prognosis evaluation of these cases.

There existed several limitations in this study: inadequate allergen testing, low rate of mucus plug smears and histological examinations, and lack of standardized use of anti-allergic medications. Further, it should be stated that the laboratory tests reflected the current but not longstanding results, which might lead to a bias of grouping. All these needed to be improved in future study.

CONCLUSION

As a special type of sialadenitis, the diagnostic criteria and treatment options of ES (or ARS) should be different from conventional COS. For those patients with frequent swelling of multiple major salivary glands and comorbid atopic diseases, elevation of PBE and serum IgE are important clinical indexes for the preliminary suspicion of ES. Mucus plug smear and histopathology can further verify the diagnosis. Interventional endoscopy is helpful for relief of symptoms in such cases. Use of anti-allergic medications and avoidance of allergens might further favor those with recalcitrant symptoms.

REFERENCES

1. Koch M, Iro H. Salivary duct stenosis: diagnosis and treatment. *Acta Otorhinolaryngol Ital* 2017;37:132–141.
2. Lee LI, Pawar RR, Whitley S, Makdissi J. Incidence of different causes of benign obstruction of the salivary glands: retrospective analysis of 493 cases using fluoroscopy and digital subtraction sialography. *Br J Oral Maxillofac Surg* 2015;53:54–57.
3. Vashishta R, Gillespie MB. Salivary endoscopy for idiopathic chronic sialadenitis. *Laryngoscope* 2013;123:3016–3020.
4. Delagnes EA, Aubin-Pouliot A, Zheng M, Chang JL, Ryan WR. Sialadenitis without sialolithiasis: prospective outcomes after sialendoscopy-assisted salivary duct surgery. *Laryngoscope* 2017;127:1073–1079.
5. Plonowska KA, Gurman ZR, Humphrey A, Chang JL, Ryan WR. One-year outcomes of sialendoscopic-assisted salivary duct surgery for sialadenitis without sialolithiasis. *Laryngoscope* 2019;129:890–896.
6. Bookman R. Allergic parotitis. *Calif Med* 1950;72:179.
7. Baer AN, Okuhama A, Eisele DW, Tversky JR, Gniadek TJ. Eosinophilic sialodochitis: redefinition of 'allergic parotitis' and 'sialodochitis fibrinosa'. *Oral Dis* 2017;23:840–848.
8. Chikamatsu K, Shino M, Fukuda Y, Sakakura K, Furuya N. Recurring bilateral parotid gland swelling: two cases of sialodochitis fibrinosa. *J Laryngol Otol* 2006;120:330–333.
9. Shimada T, Okano H, Hisa Y. A case of severe dilatation of the parotid duct due to fibrinous sialodochitis. *Acta Otolaryngol* 2006;126:1112–1114.
10. Flores RBJ, Brea AB, Sanabria SAA, et al. Sialodochitis fibrinosa (kussmaul disease) report of 3 cases and literature review. *Medicine* 2016;95:e5132.
11. Pollak N, Templer JW, Esebua M, Diaz-Arias AA, Zitsch RP. Episodic painful parotid swelling caused by sialodochitis with eosinophilic inflammation: a new entity. *Otolaryngol Head Neck Surg* 2009;140:132–133.
12. Zhu WX, Chen Y, Liu DG, Yu GY. Eosinophilic Sialodochitis: A type of chronic obstructive sialadenitis related to allergy. *Laryngoscope* 2020;131: E800–E806.
13. Ammar-Khodja A. Kussmaul's fibrinous sialodochitis. apropos of an unusual case. *Rev Laryngol Otol Rhinol* 1971;92:847–848.
14. Ray A, Burgin SJ, Spector ME. A rare case of Kussmaul disease (Sialodochitis Fibrinosa). *J Case Rep Med* 2015;4:1–3.
15. Harkness P. Submandibular salivary disease: a proposed allergic aetiology. *J Laryngol Otol* 1995;109:66–67.
16. Wang XD, Zheng M, Lou HF, et al. An increased prevalence of self-reported allergic rhinitis in major Chinese cities from 2005 to 2011. *Allergy* 2016; 71:1170–1180.
17. Darling MR, Phillips VM, Erasmus JH. Bilateral submandibular salivary gland swelling—a report of chronic sialodochitis with eosinophilia. *SADJ* 2002;57:104–106.
18. Nagai Y, Shiraishi D, Tanaka Y, et al. Transportation of sublingual antigens across sublingual ductal epithelial cells to the ductal antigen-presenting cells in mice. *Clin Exp Allergy* 2015;45:677–686.
19. Harrison JD, Epivatianos A, Bhatia SN. Role of microliths in the aetiology of chronic submandibular sialadenitis: a clinicopathological investigation of 154 cases. *Histopathology* 1997;31:237–251.
20. Rosenberg HF, Phipps S, Foster PS. Eosinophil trafficking in allergy and asthma. *J Allergy Clin Immunol* 2007;119:1303–1310.quiz 1311-1302.
21. Stone KD, Prussin C, Metcalfe DD. IgE, mast cells, basophils, and eosinophils. *J Allergy Clin Immunol* 2010;125:S73–S80.
22. Jiao D, Ishimura N, Maruyama R, et al. Similarities and differences among eosinophilic esophagitis, proton-pump inhibitor-responsive esophageal eosinophilia, and reflux esophagitis: comparisons of clinical, endoscopic, and histopathological findings in Japanese patients. *J Gastroenterol* 2017; 52:203–210.
23. Okuda MOY, Unno T. Sialodochitis fibrinosa (Kussmaul). *Jibi to Rinshō (Otologia Fukuoka)* 1975;21:635–639.
24. Aubin-Pouliot A, Delagnes EA, Eisele DW, Chang JL, Ryan WR. The Chronic Obstructive Sialadenitis Symptoms Questionnaire to assess sialendoscopy-assisted surgery. *Laryngoscope* 2016;126:93–99.
25. Aubin-Pouliot A, Delagnes EA, Chang JL, Ryan WR. Sialendoscopy-assisted surgery and the chronic obstructive sialadenitis symptoms questionnaire: a prospective study. *Laryngoscope* 2016;126:1343–1348.
26. Chipps BE, Newbold P, Hirsch I, Trudo F, Goldman M. Benralizumab efficacy by atopy status and serum immunoglobulin E for patients with severe, uncontrolled asthma. *Ann Allergy Asthma Immunol* 2018;120: 504–511.e504.
27. Dantzer JA, Wood RA. The use of omalizumab in allergen immunotherapy. *Clin Exp Allergy* 2018;48:232–240.
28. Umehara H, Okazaki K, Masaki Y, et al. Comprehensive diagnostic criteria for IgG4-related disease (IgG4-RD), 2011. *Mod Rheumatol* 2012;22:21–30.
29. Buder K, Ruppert S, Trautmann A, Bröcker EB, Goebeler M, Kerstan A. Angiolymphoid hyperplasia with eosinophilia and Kimura's disease—a clinical and histopathological comparison. *J Dtsch Dermatol Ges* 2014;12: 224–228.