Case Report

Treatment of adult Class II division 2 patient with metal hypersensitivity

Seiji Haraguchi[a]; Takashi Yamashiro[b]

ABSTRACT

This case report describes the orthodontic treatment of an adult female with an Angle Class II division 2 malocclusion with a severe deep bite and a congenitally missing lower incisor. The use of available orthodontic devices and materials was limited because the patient had metal allergies. Following a careful examination and case analysis, the preadjusted edgewise appliances and the microscrew implants were placed after the upper first premolars were extracted. After active treatment, a good facial profile and occlusion were achieved. These results have been maintained for 2 years following completion of the active treatment. (*Angle Orthod.* 2014;84:902–909.)

KEY WORDS: Deep bite; Metal allergy; Temporary anchorage devices

INTRODUCTION

Treatment of a Class II division 2 malocclusion is a challenging issue for orthodontists. These cases are often characterized by severe, traumatic deep overbites with lingually inclined upper incisors. Following careful diagnosis and treatment planning, the first step of treatment is usually to start improving the deep bite by intrusion and proclination of the incisors or extrusion of the molars or both. However, uncontrolled molar extrusion causes clockwise rotation of the lower jaw, which may worsen the Class II molar relationship and bring on a retrognathic profile. In cases presenting during a growth period, the anterior growth of the mandible can be used to improve the antero-posterior discrepancy with maintenance of an adequate vertical skeletal relationship. However, adult patients no longer experience catch-up growth and often need a surgical approach for correction. Recent innovations have expanded the limits of orthodontic treatment known as the ''envelope of discrepancy'' presented by Proffit, Ackerman, and White.[1,2] For example, superelastic nickel-titanium wires and microscrew implants can be useful for intruding over erupted incisors, and they have contributed to better treatment outcomes without the need for orthognathic surgery and with a decreased treatment time.[3] However, a large number of patients present with a metal allergy. In particular, nickel sensitivity was observed in 4.5% of the general population.[4] An immune response to implants has also commonly been reported in the literature.[5–7] Those patients with a metal allergy for whom the latest materials are contraindicated should be considered for alternative treatment options.

This article describes the treatment of an adult patient with Class II division 2 malocclusion with metal hypersensitivity. We report the diagnosis, treatment planning, and treatment results.

CASE REPORT

A 28-year-old female patient was referred for orthodontic consultation with the chief complaint of ''my upper teeth stick out,'' and she was also concerned that her upper incisors sometimes injured her lower gums (Figure 1A). According to the questionnaire administered prior to treatment, the patient had an allergy to the metals in jewelry. A skin patch test performed in the Department of Dermatology at the Osaka University Hospital showed that she had hypersensitivity to nickel, cobalt, and chromium. A clinical examination showed a straight soft tissue facial profile (Figure 2A). The intraoral examination (Figure 1A) showed crowding of the upper anterior teeth and a congenitally missing lower incisor. The occlusion was an Angle Class II molar relationship, and the patient had an extremely deep overbite (16.0 mm). The lower incisors were elongated and the Curve of Spee was steep (6.0 mm). The panoramic radiograph (Figure 3A) showed horizontally impacted

[a] Private Practice, Takarazuka, Japan.

[b] Professor and Chair, Department of Orthodontics and Dentofacial Orthopedics, Graduate School of Dentistry, Osaka University, Osaka, Japan.

Corresponding author: Dr Seiji Haraguchi, Orthobrains Orthodontic Services, 1-13-16 Yamamotonaka, Takarazuka 665-0883, Japan
(e-mail: shara@orthobrains.com)

Accepted: January 2014. Submitted: August 2013.
Published Online: April 15, 2014
© 2014 by The EH Angle Education and Research Foundation, Inc.

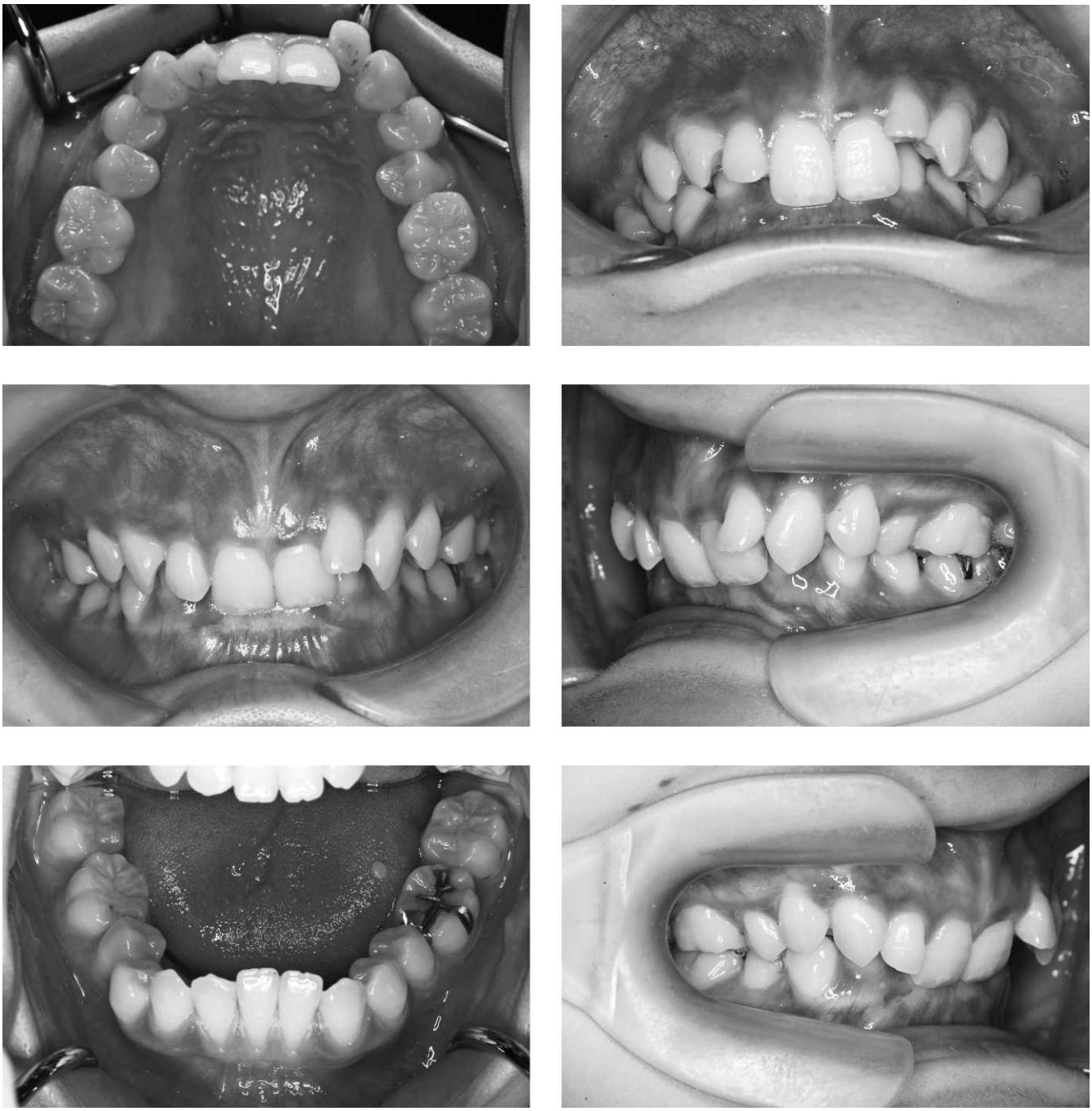

Figure 1A. Intraoral photographs: (A) pretreatment; (B) posttreatment; and (C) 2 years after debonding.

lower third molars on both sides. A lateral cephalometric analysis (Table 1) revealed a skeletal Class 2 jaw base relationship (ANB = 8.5°), with the mandible in a retrognathic position (SNB = 73.8°). The mandibular body length was average (Go-Me = 69.5 mm), and the mandibular plane angle was small (FMA = 22.6°) with respect to the Japanese normative mean.[8] Both the upper and lower incisors were lingually inclined (U1-FH = 71.3°, L1-Mp = 82.8°).

Diagnosis and Treatment Objectives

The case was diagnosed as an Angle Class II division 2 malocclusion with a severe deep bite. The treatment objectives were to improve the deep overbite by means of leveling the upper and lower arches while maintaining the facial height in order to obtain an appropriate interincisal angle, to reduce the antero-posterior skeletal discrepancy, and to obtain a good

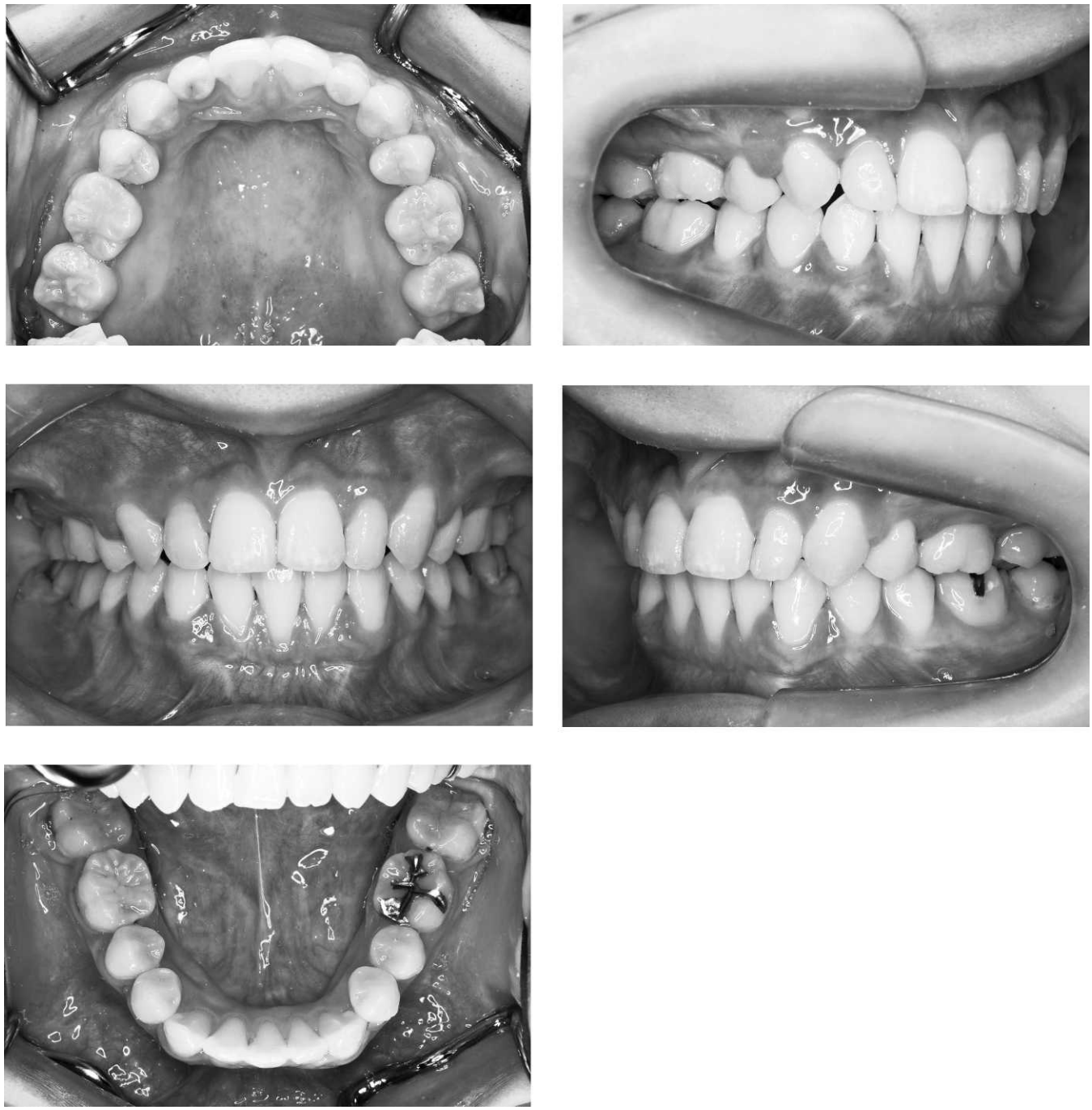

Figure 1B.

facial profile. Special care was also required to avoid complications associated with the patient's metal allergy.

The treatment plan was determined and included the following steps:

- Extraction of the upper first premolars; the lower arch was to be aligned with three incisors;
- Alignment of the upper and lower arches using preadjusted edgewise appliances; and
- Utilization of microscrew implants as absolute anchors for the retraction of the maxillary anteriors and intrusion of the incisors.

Treatment Progress

Following the extraction of the upper first premolars, 0.022-inch slot preadjusted edgewise brackets (Equilibrium ti, Dentaurum, Ispringen, Germany) were

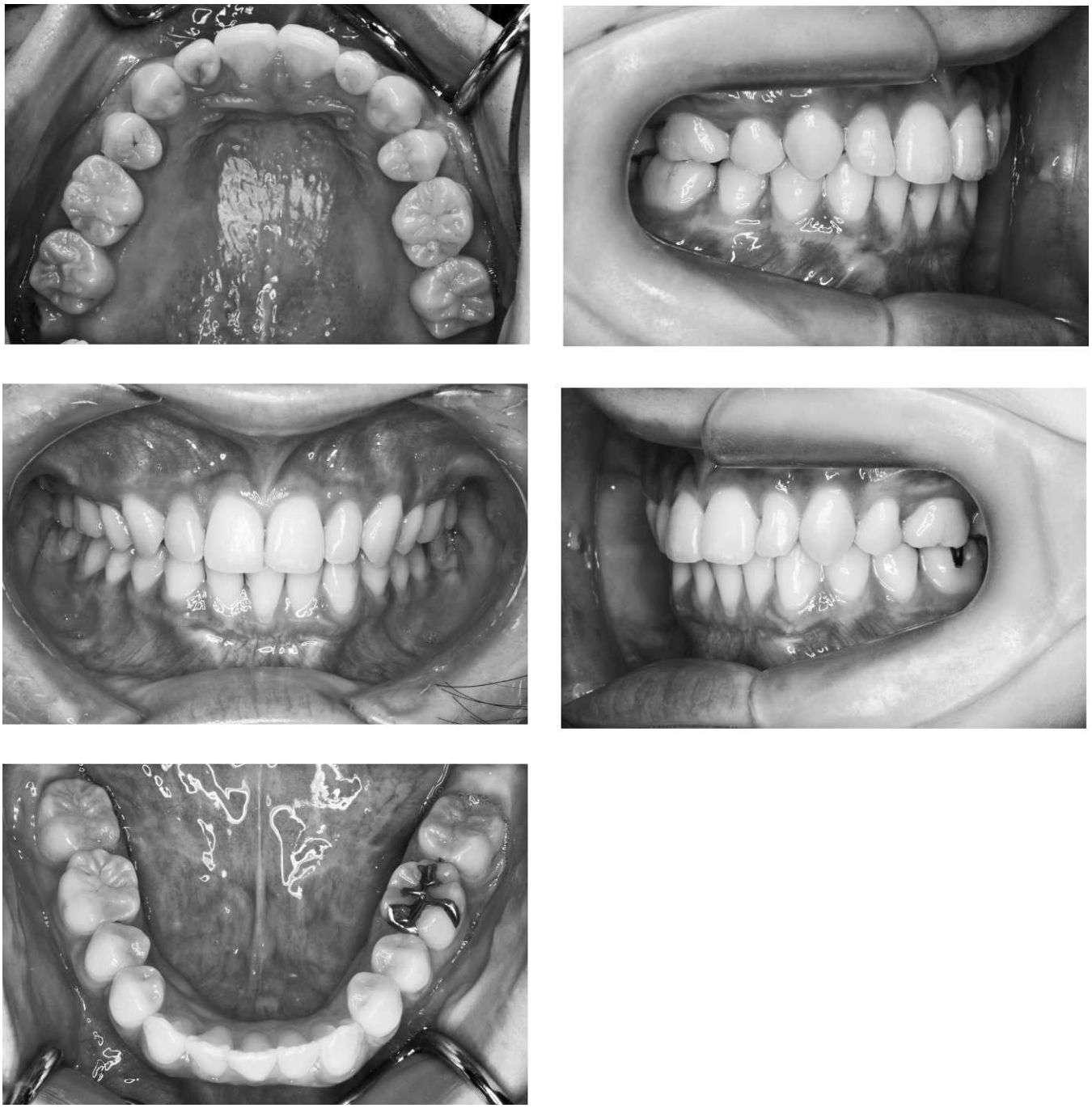

Figure 1C.

placed on the upper dental arch. As a result of the patient's metal allergy, brackets made of pure titanium were chosen, and all of the archwires applied were nickel-free beta titanium wires (CNA BetaIII Archwires, Ortho Organizers Inc, Carlsbad, Calif). Titanium microscrews (Dual-Top Anchor System, 8.0 mm in length, 1.6 mm in diameter; Jeil Medical Corporation, Seoul, Korea) were also placed bilaterally 1.5 mm mesial to the root of the upper second premolar. These titanium alloys did not contain the sensitized metals. Then 0.016-inch beta titanium wire with added multiple vertical and horizontal loops was used for aligning the upper incisors. After 4 months of alignment, a 0.017 × 0.025-inch intrusion arch was placed in the upper arch to level the maxillary occlusal plane.

Microscrew implants were utilized for the intrusion of the upper incisors and retraction of the upper anteriors throughout the active treatment period. Subsequently,



Figure 2. Facial photographs: (A) pretreatment; (B) posttreatment; and (C) 2 years after debonding.

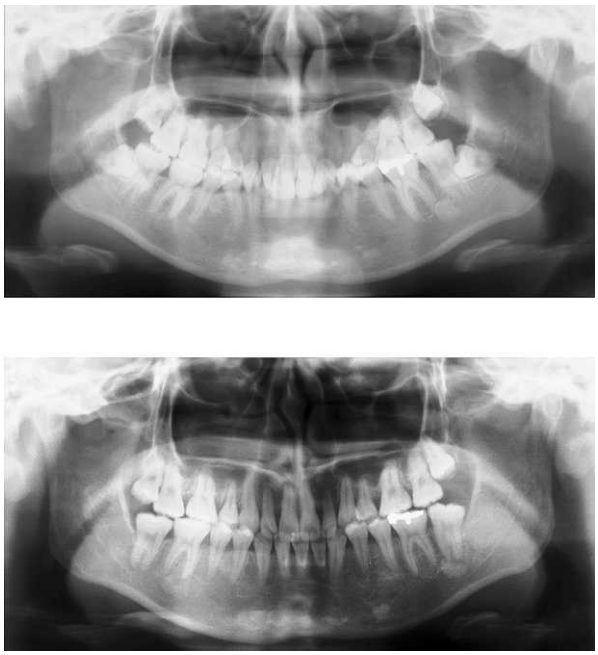

Figure 3. Panoramic radiographs: (A) pre-treatment; (B) post-treatment.

acrylic posterior bite blocks were placed with glass ionomer cement on the upper molars (Figure 4). The bite blocks, which were carefully adjusted to have flat occlusal contact for the opposing teeth, enabled the correct placement of the brackets (Envision Composite Bracket System, Ortho Organizers Inc) on the lower teeth. The bite blocks were removed 3 months after adequate leveling and alignment had been achieved in the lower arch. The overbite of the anterior teeth was overcorrected. All of the appliances were removed 26 months after the start of treatment. Circumferential retainers were used for retention.

Treatment Results

The treatment objectives set in the pretreatment planning were achieved. The clinical examination after 2 years of retention revealed that the orthodontic treatment provided good intercuspation of the teeth (Figure 1C). The traumatic deep overbite and extremely steep Curve of Spee were improved. The skeletal Class 2 jaw base relationship changed to a Class 1 relationship, and the mandibular plane angle was maintained (Table 1). The excessively large interincisal angle at the pretreatment period (183.3°) was decreased to within the normal range (124.8°). After active treatment, the patient also had a straight-type harmonious profile (Figure 2B). Abnormal symptoms associated with metal hypersensitivity were not observed during the active treatment and retention periods.

DISCUSSION

Adult Class II division 2 malocclusion often involves a deficiency of the mandible, making it difficult to achieve the soft tissue objectives without orthognathic mandibular advancement. Cases with mild to moderate skeletal discrepancies and an acceptable soft tissue prognosis only allow camouflage treatment. According to Proffit et al.,[9] there are four criteria to use to decide if Class II postadolescent patients can be treated successfully with orthodontics alone. They reported that the cases with an overjet greater than 10 mm, a pogonion-nasion perpendicular distance over 18 mm, a gonion-pogonion distance of less than 70 mm, and a facial height greater

Table 1. Cephalometric Measurements[a]

				Normative Mean (Japanese Female Adult)	
Measurements	Pretreatment	Posttreatment	Retention	Mean	SD
Angular, °					
SNA	82.4	78.2	78.2	80.8	3.6
SNB	73.8	74.1	74.1	77.9	4.5
ANB	8.6	4.1	4.1	2.8	2.4
Mp-FH	22.6	23.0	22.8	37.1	4.6
U1-FH	71.3	110.1	110.5		3.6
L1-Mp	82.8	102.1	101.9	112.3	8.3
L1-FH	74.6	54.9	55.3	93.4	6.8
IIA	183.3	124.8	124.8	123.6	10.7
Linear, mm					
S-N	69.1	69.1	69.1	67.9	3.7
Ptm-A/PP	49.1	45.3	45.3	47.9	2.8
Go-Me	69.5	69.5	69.5	71.4	4.1
Ar-Go	49.0	49.0	49.0	47.3	3.3
Ar-Me	105.1	105.1	105.1	106.6	5.7
Overjet	2.3	4.0	4.2	3.1	1.1
Overbite	16.0	2.9	3.0	3.3	1.9

[a] SD indicates standard deviation.

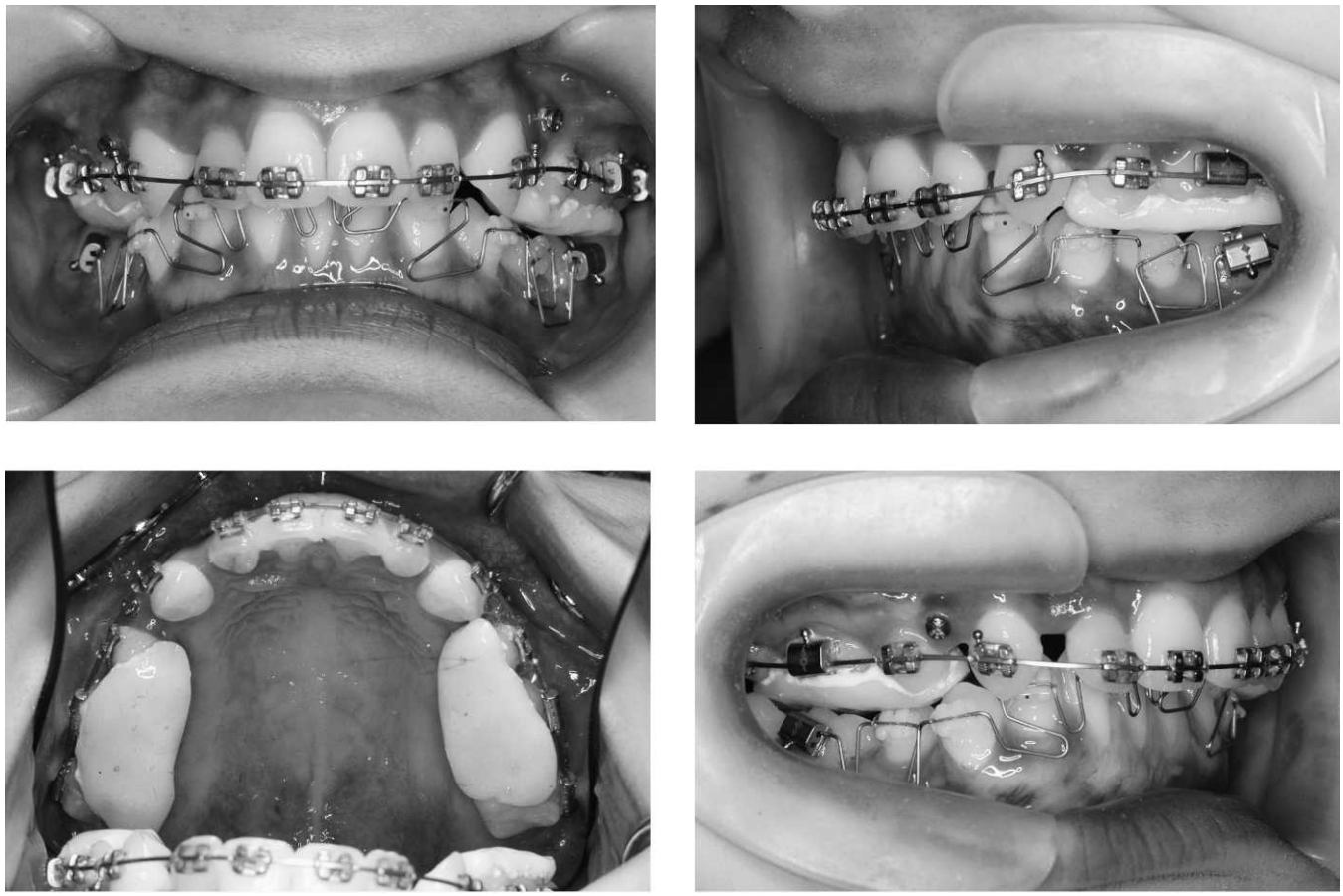

Figure 4. The deep bite was opened by the placement of the posterior bite blocks.

than 125 mm are likely to fail the camouflage treatment. The present case did not meet these criteria when the racial differences are taken into account (overjet = 2.3 mm, pogonion-nasion perpendicular distance = 9.0 mm, gonion-pogonion distance = 78 mm, and facial height = 125 mm in the present case). The criterion regarding the facial height indicates that the unsuccessfully treated patients had a high mandibular plane angle; the present case had a low mandibular plane angle with respect to the Japanese normative mean. Recently, microscrew implants have been applied to treat Class II patients, and they have been producing good results. The microscrew implant provides absolute anchorage, which makes it comparatively easy to retract the protruded anterior teeth or to intrude the incisors without increasing the vertical facial height. This means that the importance of the ''overjet'' and the ''facial height'' in the aforementioned criteria may be decreasing. On the other hand, the position of the chin seems to be a crucial factor in choosing treatment alternatives. Even if the occlusion can be corrected with orthodontic treatment only, the patients with deficient chins cannot achieve a good facial profile without surgery. We suppose that one of the reasons for the success of the present treatment without orthognathic surgery was that the patient had a well-developed chin projection.

Metal allergy is a challenging problem when it comes to orthodontic treatment. An allergy to nickel is commonly seen in the general population, more frequently in females than in males.[4] This allergy has increased with the more frequent use of nickel-containing jewelry. Titanium allergy is uncommon but does exist. Previous studies[10,11] have reported that various implant materials made of titanium alloy induced metal hypersensitivity. A patch test evaluation is the gold standard for examining patients for metal hypersensitivity. Regarding the pretreatment examination, the patients with a reported history of metal dermatitis should be evaluated by patch testing.[10] Additional treatment options need to be developed for the patients with metal hypersensitivity.

REFERENCES

1. Proffit WR, Ackerman JL. Diagnosis and treatment planning in orthodontics. In: Graber TM, Swain BF, eds. *Orthodontics: Current Principles and Techniques*. St Louis, Mo: CV Mosby Co; 1985.

2. Proffit WR, White RP. *Surgical-Orthodontic Treatment*. St Louis, Mo: CV Mosby Co; 1991.
3. Kim TW, Kim H, Lee SJ. Correction of deep overbite and gummy smile by using a mini-implant with a segmented wire in a growing Class II division 2 patient. *Am J Orthod Dentofacial Orthop*. 2006;130:676–685.
4. Peltonen L. Nickel sensitivity in the general population. *Contact Dermatitis*. 1979;5:27–32.
5. Merritt K, Rodrigo JJ. Immune response to synthetic materials. Sensitization of patients receiving orthopaedic implants. *Clin Orthop*. 1996;326:71–79.
6. Sicilia A, Cuesta S, Coma G, Arregui I, Guisasola C, Ruiz E. Titanium allergy in dental implant patients: a clinical study on 1500 consecutive patients. *Clin Oral Implants Res*. 2008;19: 823–835.
7. Egusa H, Ko N, Shimazu T, Yatani H. Suspected association of an allergic reaction with titanium dental implants: a clinical report. *J Prosthet Dent*. 2008;100: 344–347.
8. Wada K. A study on the individual growth of maxillofacial skeleton by means of lateral cephalometric roentgenograms. *J Osaka Univ Dent School*. 1977;22:239–269.
9. Proffit WR, Phillips C, Tulloch JF, Medland PH. Surgical versus orthodontic correction of skeletal Class II malocclusion in adolescents: effects and indications. *Int J Adult Orthod Orthognath Surg*. 1992;7:209–220.
10. Schalock PC, Menné T, Johansen JD, et al. Hypersensitivity reactions to metallic implants—diagnostic algorithm and suggested patch test series for clinical use. *Contact Dermatitis*. 2012;66:4–19.
11. Javed F, Al-Hezaimi K, Almas K, Romanos GE. Is titanium sensitivity associated with allergic reactions in patients with dental implants? A systematic review. *Clin Implant Dent Relat Res*. 2013;15:47–52.