Respiratory Medicine Case Reports 26 (2019) 136–141

Contents lists available at ScienceDirect

Respiratory Medicine Case Reports

journal homepage: www.elsevier.com/locate/rmcr

Case report

The anatomic substrate of irreversible airway obstruction and barotrauma in a case of hurricane-triggered fatal status asthmaticus during puerperium: Lessons from an autopsy

Christopher A. Febres-Aldana[a,*], Sabrina Oneto[a], Marc Csete[b], Cristina Vincentelli[a,c]

[a] Arkadi M. Rywlin M.D. Department of Pathology and Laboratory Medicine, Mount Sinai Medical Center, Miami Beach, FL, USA
[b] Department of Critical Care, Mount Sinai Medical Center, Miami Beach, FL, USA
[c] Herbert Wertheim College of Medicine, Florida International University, Miami, FL, USA

ARTICLE INFO

Keywords:
Fatal asthma
Airway remodeling
Barotrauma
Thunderstorm
Hurricane
Autopsy

ABSTRACT

Non-fully reversible airway obstruction in fatal asthma is often seen in association with profound structural changes of the bronchial wall, termed airway remodeling. Evidence suggests that heavy precipitation events can trigger epidemics of severe asthma. We present a case of fatal asthma in a young woman with no prior near-fatal exacerbations and postulate that the patient's extensive airway remodeling and puerperal state (susceptibility factors), in combination with a massive allergen challenge during a hurricane landfall (triggering factor), played a central role in her death. The autopsy revealed diffuse obstruction of proximal and distal bronchi by mucous plugs together with transmural chronic inflammation, tissue eosinophilia, extensive goblet cell hyperplasia with MUC-5 expression and airway smooth muscle (ASM) thickening. The observed distribution of airway remodeling was heterogeneous with sparing of the lingula, which exhibited hyperinflation and expansion of perivascular spaces indicative of dissecting air. The massive stagnation of mucus and significant inter-airway structural heterogeneity created an anatomical substrate for unequal airflow distribution facilitating the development of barotrauma. Although not considered conventional risk factors for fatal asthma, we believe that in this case, the patient's puerperal state in conjunction with an extreme environmental event dispersing aeroallergens were major contributors to the development of a fatal asthma attack. Our autopsy findings suggest that effective strategies to evacuate stagnated mucus and induce relaxation of thickened ASM are crucial in the management of life-threatening asthma exacerbations.

1. Introduction

The term “asthma” describes a spectrum of chronic inflammatory diseases of the lower airway that manifest with airflow obstruction that is reversible and can fluctuate over time [1]. Asthma mortality has rapidly declined since the incorporation of inhaled corticosteroids into treatment protocols. However, there are still approximately 4000 deaths attributable to asthma per year in the United States [2,3]. Deaths from status asthmaticus are more commonly encountered in patients with poorly controlled disease or prior near-fatal exacerbations requiring endotracheal intubation [3,4]. Our comprehension of the clinical and molecular features associated with these severe phenotypes is still insufficient. Postmortem and biopsy studies have shown that the pattern of airway damage in severe asthma is heterogeneous, and that profound structural changes of the bronchial wall, termed “airway remodeling”, appear to be the anatomical substrate for irreversible or barely reversible airway obstruction in some subgroups of asthmatics [5,6].

The relationship between airway remodeling, inflammation and hyperresponsiveness is not fully understood [7]. Increased frequency in exacerbations is a feature of severe asthma phenotypes accompanied by airway remodeling. However, it is unclear how airway remodeling could cause a rapidly developing status asthmaticus. Interestingly, hormonal-related changes secondary to pregnancy can lead to an increase in airway hyperresponsiveness during the postpartum period, but the underlying histopathologic changes are yet to be described [8]. We report a case of a young woman who developed fatal status asthmaticus complicated with barotrauma at two months postpartum. The autopsy findings were those of allergic asthma associated with extensive airway remodeling. This structural alteration was spatially heterogeneous creating an anatomical substrate for barotrauma. Additionally, the onset of the patient's symptoms coincided with a

* Corresponding author. Department of Pathology and Laboratory Medicine, Mount Sinai Medical Center, 4300 Alton Road, Miami Beach, FL, 33140, USA.
E-mail address: christopher.febres@msmc.com (C.A. Febres-Aldana).

https://doi.org/10.1016/j.rmcr.2018.12.013
Received 17 December 2018; Accepted 19 December 2018
2213-0071/ © 2018 The Authors. Published by Elsevier Ltd. This is an open access article under the CC BY-NC-ND license (http://creativecommons.org/licenses/BY-NC-ND/4.0/).

category 4 hurricane landfall on the state of Florida. There is evidence that heavy precipitation events such as thunderstorms can trigger epidemics of asthma with increasing severity, maybe due to significant allergen challenge [9]. We postulate that the combination of airway remodeling and puerperal state (susceptibility factors) and massive aeroallergen challenge during a hurricane (triggering factor) had a central role in leading to a lethal outcome in this case.

2. Case report

A 24-year-old African-American woman with history of asthma presented at two months postpartum with dyspnea and wheezing. The patient denied smoking, previous episodes of severe asthma or prior exacerbations requiring intubation. Two days prior to the onset of asthma exacerbation symptoms, she developed rhinorrhea and dry cough coinciding with the landfall of a category 4 hurricane on Florida. The patient was admitted due to respiratory failure (pH: 7.24, pCO_2: 57 mmHg, HCO_3: 24.4 mEq/L, base excess (BEB): −3.8 mEq/L), with a pO_2 of 221 mmHg at a fraction of inspired oxygen (FiO_2) of 70%, and an increased alveolar-arterial oxygen gradient (A-aDO_2: 207 mmHg, expected for age: 10 mmHg). A chest X-ray and a CT-pulmonary angiogram at the time of admission showed no significant findings. Multiple consecutive rounds of ipratropium-albuterol nebulizer treatments, intravenous terbutaline, dexamethasone, methylprednisolone and magnesium did not improve her symptoms. The patient was transported from the emergency room to the ICU on Bipap ventilation. Upon arrival in the ICU the patient was emergently intubated when her breathing pattern remained severely labored with minimal air exchange noted on auscultation. Once placed on mechanical ventilatory support, the patient was sedated while continuing high dose steroids and continuous bronchodilators. Paralytics were added and later a ketamine infusion in an effort to reverse severe bronchoconstriction. Adequate ventilation was unachievable due to severe bronchospasm and the subsequent increase in airway resistance. Peak inspiratory pressures (PIP) remained severely elevated (> 50 cmH2O), despite trials of multiple ventilation modes with close attention to limiting lung injury, while attempting to achieve effective ventilation. Gas exchange deteriorated with progression of hypercapnia and respiratory acidosis (pH: 6.83; pCO2: 140 mmHg). Subsequently, the patient developed unrelenting barotrauma with subcutaneous air, pneumomediastinum and a left pneumothorax. The patient could not be ventilated with either mechanical support or manual Ambu-bag ventilation and died 24 hours after admission.

3. Autopsy findings

A “lung restricted” autopsy was performed. On external examination, cyanosis and diffuse subcutaneous emphysema were noted. The thorax was distended and the lungs were collapsed, consistent with bilateral pneumothoraces. The right lung weighted 570 g (RR: 360–570 g) and left 270 g (RR: 325–480 g). Both lungs showed congestion and diffuse atelectasis except for the lingula, which appeared hyperinflated. Additionally, there was evidence of pneumoperitoneum and pneumomediastinum, as well as pericardial and peritoneal pneumatosis. The pulmonary vasculature was patent with no thromboemboli. The bronchi and intrapulmonary airways exhibited diffuse occlusion by inspissated green mucous plugs (Fig. 1). Postmortem cultures of bronchial secretions and lung parenchyma were negative for bacteria, viruses and fungal organisms.

Microscopic examination of the mucous plugs revealed dense mucinous material admixed with numerous eosinophils among other inflammatory cells, sloughed epithelial cells, Charcot-Leyden crystals and Curschmann spirals. The bronchi showed transmural chronic inflammation with numerous eosinophils, mucosal goblet cell hyperplasia, extensive epithelial shedding, basement membrane thickening, submucosal edema with increased numbers of capillaries and airway smooth muscle (ASM) thickening. These findings were more florid in the proximal bronchi. The changes in the distal airway were heterogeneous, showing few patchy areas lacking inflammation and remodeling. Mucosal hyperplasia of goblet cells expressing mucin 5 (MUC-5) was particularly distinct in the airways showing mucous plugging, while patent airways showed lesser amounts of goblet cells and absent MUC-5 expression (Fig. 1). ASM thickening was accompanied by degranulating eosinophils, more evident in the proximal bronchi. Immunohistochemical stains for smooth muscle actin (SMA-1A4) and smooth muscle-myosin heavy chain (sm-MHC) showed a pattern consistent with bronchial smooth muscle hyperplasia (Fig. 2). Immunohistochemistry for Ki-67 (MIB-1) revealed a proliferative response to injury in the surface respiratory epithelium, submucosal glands, and rarely in ASM and airway stromal cells in comparison to airways of non-asthmatic patients (controls), (Fig. 3). The lingula showed an absence of significant airway inflammation or remodeling; however, alveolar overdistension and focal expansion of perivascular spaces indicative of dissecting air were noted (Fig. 4).

4. Discussion

4.1. The clinicopathological heterogeneity of fatal asthma

Asthma can lead to several acute life-threatening pulmonary complications such as atelectasis, pneumothorax, barotrauma, respiratory muscle exhaustion, among others [4]. Although severe asthma exacerbations are seen more frequently in patients with poorly controlled asthma, fatal cases can also occur sporadically and whether the baseline level of disease activity is mild, moderate, or severe, demonstrating the clinical heterogeneity of so-called asthma endotypes (mechanistic pathways) and phenotypes (clinical presentations) [1,10]. The primary mechanism of airway narrowing in asthmatics involves an excessive contraction of ASM due to vagal stimulation and cytokine-induced hyperresponsiveness. As seen as in this case, the occurrence of fatal asthma is associated with poorly reversible or irreversible airway obstruction rapidly leading to respiratory failure. Two clinicopathological patterns of fatal asthma have been described, with slow onset of symptoms and with sudden wheezing [4]. Asthmatics with slow onset of symptoms and late hospital arrival tend to show absence of immediate response to bronchodilators. In this subgroup of patients, histopathology demonstrates extensive mucous plugging and eosinophil-rich inflammation. The late hospital arrival has been attributed to a decreased perception of dyspnea despite of severe airway obstruction. In contrast, there are asthmatics that present with sudden exacerbations and show a faster response to bronchodilators. Mucous plugs are virtually absent in this subgroup and the inflammatory response is predominantly neutrophilic. Infections, both viral and bacterial, have been associated with this pattern of presentation. In the present case, the patient's clinical presentation fits in the first category, which is that of fatal allergic asthma.

4.2. Airway remodeling is a heterogeneous process

The subtypes of inflammatory response do not appear to determine the severity of disease in some asthmatics [1]. Rather, in poorly controlled asthma the persistent inflammation resulting in repeated cellular injury, together with the chronic excessive bronchoconstriction, can induce structural changes in the airways that perpetuate the immune dysfunction and abnormal ASM responses creating a feedback loop [7]. The patient's autopsy revealed typical features of airway remodeling including basement membrane thickening, goblet cell hyperplasia and ASM thickening. Airway remodeling is a repair process in response to chronic inflammation, which is associated with the proliferation of bronchial epithelial cells and ASM in severe asthma [11,12]. Experimental studies have shown that remodeling is accompanied by alterations in the airway function including abnormal

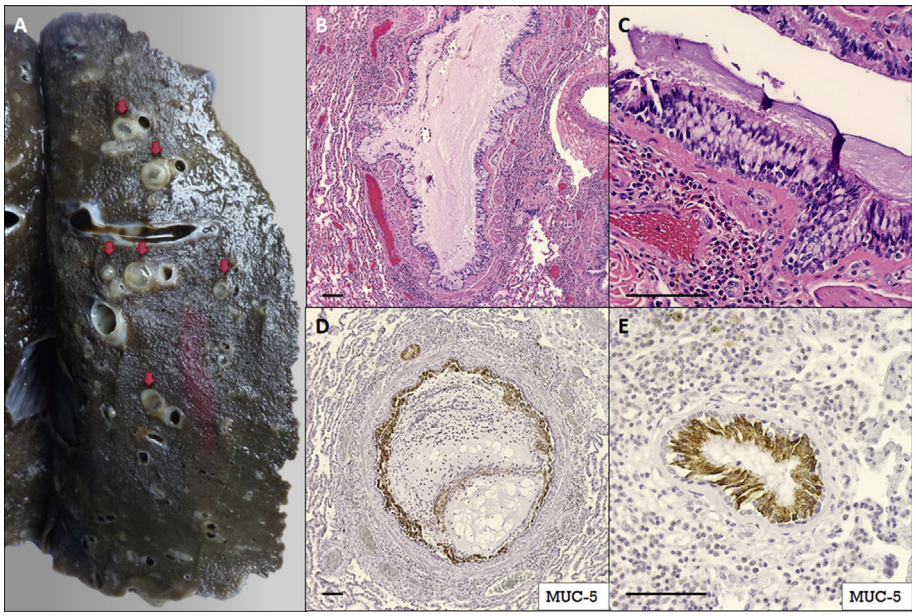

Fig. 1. Mucous plugs obstructing intrapulmonary bronchi. A. Dilated bronchi containing inspissated mucous plugs (arrows) and lung atelectasis, right lower lobe, post-fixation. B. Bronchus with extensive goblet cell hyperplasia. C. Pseudostratified ciliated bronchial epithelium from a distal bronchus with goblet cell hyperplasia and few intraepithelial eosinophils, thickened basement membrane, and submucosal chronic inflammation with numerous eosinophils. D and E. Immunohistochemistry for MUC-5 highlighting widespread goblet cell hyperplasia in the proximal and distal bronchi, respectively. Bar: 100 μm.

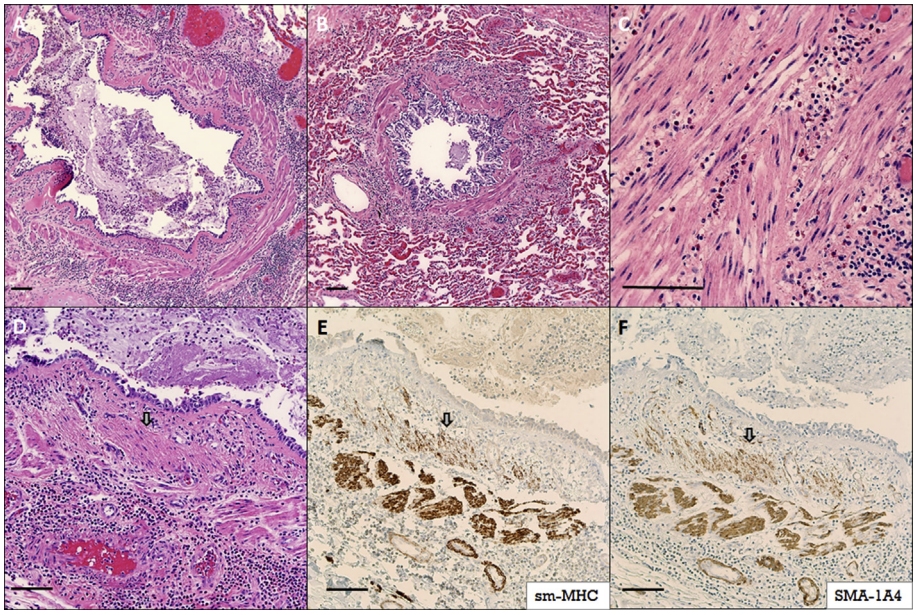

Fig. 2. Airway smooth muscle (ASM) hyperplasia. A and B. Proximal and distal bronchi, respectively, with thickened ASM and transmural chronic inflammation rich in eosinophils. C. ASM with degranulating eosinophils. D-F. Hyperplastic bundles of ASM, highlighted by immunohistochemistry for sm-MHC and SMA-1A4. Bar: 100 μm.

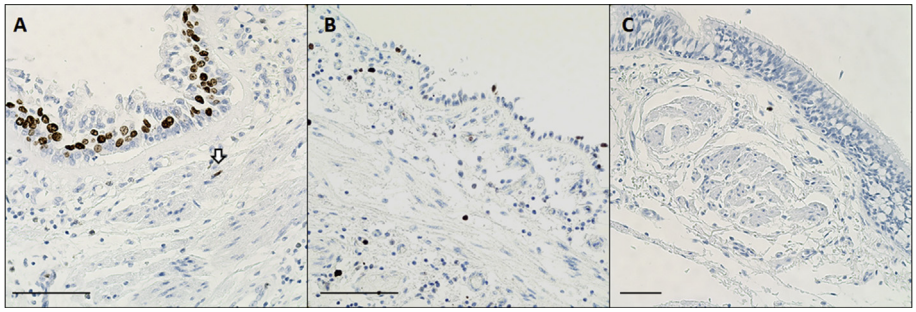

Fig. 3. Ki-67 (MIB-1) immunohistochemistry showing increased cellular proliferation in the patient's airway. Patient's airway (A) compared to airway sections from an age-, gender-, ethnicity-matched non-asthmatic controls (B, C). Bar: 100 μm.

mucous secretion, ASM hypercontractility and impairment of ASM relaxation [13]. However, airway remodeling is not always present in asthmatics, probably due to genetic polymorphisms (i.e., *ADAM33*, *ESR1*, *PLAUR*, and *VEGF*) playing a role in modifying how the airway reacts to injury [14]. The factors and circumstances leading to fatal asthma are diverse; therefore, tissue remodeling is a contributing factor more than the cause [4].

It is unclear which components of airway remodeling are more

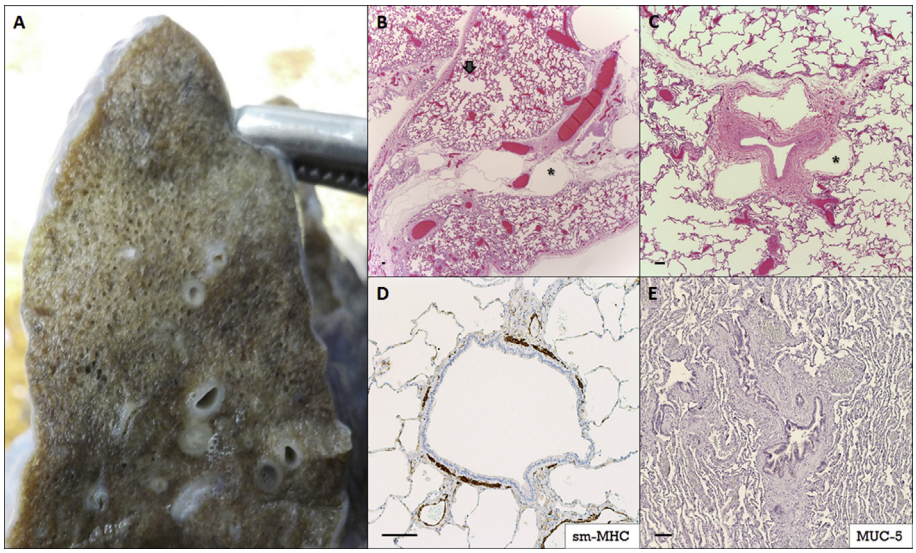

Fig. 4. Lingula sparing as a likely source of barotrauma. A. Dilated air spaces and patent bronchi, lingula, post-fixation. B and C. Alveolar overdistension (pseudo-emphysematous changes, arrow) and perivascular dissecting air (asterisks). D. Distal bronchus with normal smooth muscle thickness highlighted by immunohistochemistry for sm-MHC. E. Normal-appearing bronchial mucosa lacking goblet cell hyperplasia and MUC-5 expression. Bar: 100 μm.

significant for the emergence of poorly reversible airway obstruction. In the present case, our findings indicate that mucous plugging itself caused complete luminal occlusion in several proximal bronchi including the right mainstem bronchus. Also, excessive constriction of a thickened ASM, possibly in association with downregulation of relaxing pathways, contributed to the development of bronchoconstriction nonresponsive to bronchodilators. The ASM wraps up around the airway following a helical pattern rather than a concentric arrangement [15]. Thus, a thickened and fully contracted ASM decreases the luminal area but does not cause full obstruction. Stagnation of inspissated mucus can occlude the airway lumen explaining the lack of effectiveness of bronchodilators. As a matter of fact, asthmatics with exacerbations not associated with mucous plugging show a better response to bronchodilators [4]. Normally, goblet cells and submucosal glands release mucus into the airway lumen. In asthma, however, there is an increased number in mucosal goblet cells which is accompanied by alterations in secreted mucins [16]. The production of MUC-5AC is upregulated while MUC-5B is downregulated, along with decreased mucin glycosylation [17]. Extracellular MUC-5AC-containing domains of mucus tether to the MUC-5AC-producing cells interfering with mucociliary clearance, resulting in plugging the airway and causing asphyxia [16,18]. The ciliary beating is preserved, and the impairment of mucus clearance is due to failure to propel the adhered mucus. This is in contrast to other diseases such as cystic fibrosis or primary ciliary dyskinesia, where the primary mechanism of mucus accumulation is absent or decreased cilia motility. Alterations in protease and antiprotease expression in asthma can further contribute to stagnation of mucus [16].

ASM thickening also contributed to the patient's weak response to bronchodilators. ASM can undergo phenotypical changes characterized by altered intracellular calcium signaling and increased expression of contractile proteins as in hypertrophy. Additionally, hyperplasia can further contribute by increasing the number of units available to elicit a contractile response. Thickening of smooth muscle may influence the passive tone and airway stiffness changing the airflow dynamics during the respiratory cycle. Hyperplasia, hypertrophy, or both have been implicated in increasing the ASM mass [19]. Smooth muscle hypertrophy in proximal bronchi is a feature of both nonfatal and fatal asthma, but smooth muscle hyperplasia in proximal and distal bronchi seems to be more frequent in fatal cases [20]. Although we cannot rule out ASM hypertrophy, the increased numbers of ASM bundles suggests that hyperplasia was the significant contributor to the ASM thickening seen in our patient. The potential molecular mechanisms of ASM remodeling involve phenotypical changes in smooth muscle cells triggered by inflammatory mediators and persistent bronchoconstriction resulting in mechanical stress [5,21]. Additionally, downregulation of relaxation pathways with persistent phosphorylation of myosin light-chain kinase could have a role in nonresponsive bronchoconstriction [21,22].

The airway remodeling observed in this case was heterogeneous. The gross and microscopic findings in the lingula were those of hyperinflation and barotrauma, but there was no evidence of asthma-related changes such as inflammation or airway remodeling. Although it is known that proximal and distal bronchi can display different responses to injury, to our knowledge, complete sparing of lung segments has not been reported in asthma. The airway wall dimensions and ASM thickness in humans exhibit significant baseline heterogeneity [23]. Airways of similar diameter show variations in their airway wall and ASM areas. Airway remodeling increases this inter-airway heterogeneity that can further amplify airway narrowing after ASM activation [24,25]. Our autopsy findings demonstrate the impact of inter-airway heterogeneity on the distribution of ventilation. The airway is an interconnected system rather than a collection of independent units. The airflow depends on the pressure gradient and the airway resistance. According to the Poiseuille's law, the resistance is inversely proportional to the airway radius to the fourth power. A small decrease in airway radius will cause a profound decrease in the airflow through that unit. Thus, the ventilation will be re-distributed towards areas with a larger airway radius, causing atelectasis of alveoli connected to bronchi with a decreased lumen and thickened walls along with overdistension of alveoli connected to bronchi with a larger lumen. This theoretical framework elucidates why the lingula was hyperinflated and most likely the source of barotrauma.

The absence of airway remodeling in the lingula remains unexplained. Tissue remodeling required days to weeks to years develop [5,13,15,21,22]. A single acute exacerbation is not considered to be a sufficient stimulus to induce significant structural changes in asthma. Increased proliferation of bronchial epithelium can be observed as early as at 2 days after allergen challenge in patients with mild asthma [26]. However, accentuated proliferative responses with epithelial and ASM hyperplasia is characteristic of patients with longstanding severe asthma [11,12]. Thus, the presence of extensive airway remodeling and tissue eosinophilia suggests that our patient may have been suffering from uncontrolled allergic asthma with mild symptoms and poor perception of dyspnea. Hypothetically, unequal allergen deposition across the airway could be a source of variability in the severity of local inflammation. However, it seems unlikely that allergens could never reach specific lung compartments. It is known though that preexistent

inter-airway structural heterogeneity generates constraints in the distribution of mechanical forces limiting and promoting the remodeling to some bronchi [7,24]. Interestingly, children hospitalized for early-life bronchiolitis are susceptible to recurrent wheezing and reduced pulmonary function within the first decade of life and possibly adulthood [27,28]. It is likely that previous injury events such as bronchitis, bronchiolitis, or asthma exacerbations throughout the life of one individual may shape the airway wall structure increasing the vulnerability for remodeling that perpetuates abnormal reactions to subsequent injury events.

4.3. The role of sex hormones in asthma

The prevalence of asthma switches at puberty from boys having the highest prevalence as children to women having the highest prevalence as adults [29]. Approximately 30–40% of women report peri-menstrual worsening of asthma symptoms associated with an increase in the fractional exhaled nitric oxide, a non-invasive measure that correlates with eosinophilic inflammation [29]. Furthermore, a higher frequency of near-fatal asthma episodes on the first day of menstruation has been reported [30]. Women in the postpartum period have been reported to develop increased airway hyperresponsiveness and worsening of asthma control [8]. Changes during pregnancy appear to be more variable with reports of decreased, increased or no change in asthma symptoms [29]. The gender disparity in asthma prevalence and symptoms has been attributed to immunomodulatory effects of sex hormones. There is experimental evidence that progesterone can facilitate the action of bronchodilators [31]. In addition, polymorphism within *ESR1*, a gene encoding estrogen receptor (ER) alpha, has been associated with an excess functional decline in asthmatics [14]. These findings support that sex hormones may play a role in asthma, and possibly in our case. To our knowledge, no studies have addressed how sex hormones may affect airway structure in asthma related to the menstrual cycle, pregnancy or puerperium.

4.4. Storms, hurricanes and asthma exacerbations

There is epidemiological evidence that thunderstorms are associated with allergic asthma outbreaks with increasing severity in Europe and Asia [9]. While this association has not been confirmed in the United States, it is not uncommon to find in the news reports of an increase in exacerbations of respiratory or allergic illnesses during hurricane aftermaths. Interestingly, the patient's symptoms started when a strong hurricane made landfall on the state of Florida. Changes in airwaves, as well as the rise in wind intensity, could have caused a massive air dispersion of allergens triggering an allergic response. This is supported by previous observations suggesting that asthmatics who stay at home with closed windows and avoid outside air exposure are less likely to develop an exacerbation [32]. It appears that only patients with allergic-type asthma are affected by thunderstorms. Upon review of the literature we found a case report of near-fatal asthma exacerbation in a pregnant woman allergic to pollen during a thunderstorm, suggesting that some subgroups of asthmatics may be more susceptible to develop severe crisis during these environmental events [33].

5. Conclusion

Recognition of puerperium and extreme environmental conditions as nonconventional risk factors for fatal asthma is relevant for the early management of life-threatening exacerbations. Our autopsy findings show that extensive airway remodeling can be present in puerperal allergic asthma. Presentation during the postpartum period suggests that sex hormones may play a role in the development of airway hyperresponsiveness. Massive stagnation of mucus secondary to mucosal goblet cell hyperplasia, along with ASM thickening, caused occlusion of the airway explaining the ineffectiveness of bronchodilators and rapid lethal outcome. Hyperplasia, and possibly hypertrophy, contributed to the increment in the ASM mass. Furthermore, the autopsy revealed significant inter-airway structural heterogeneity including complete sparing of a lung segment, creating an anatomical substrate for unequal airflow distribution and subsequent barotrauma. Effective strategies to evacuate inspissated mucus and induce relaxation of thickened ASM are crucial in the management of life-threatening asthma exacerbations. In the United States, the correlation between hurricane landfalls and severe asthma outbreaks remains to be determined.

Statement of ethics

The authors have no ethical conflicts to disclose.

Disclosure statement

The authors have no conflicts of interest to declare.

Funding sources

None to declare.

Author contributions

C.A.F.A performed the autopsy, wrote the manuscript, designed the figures, and reviewed the literature. S.O. participated in the autopsy performance. M.C. was the primary intensivist. C.V. was the primary pathologist. All authors collectively drafted and approved the final version of this manuscript.

Acknowledgement

None to disclose.

Appendix A. Supplementary data

Supplementary data to this article can be found online at https://doi.org/10.1016/j.rmcr.2018.12.013.

References

[1] M.E. Kuruvilla, F.E. Lee, G.B. Lee, Understanding asthma phenotypes, endotypes, and mechanisms of disease, Clin. Rev. Allergy Immunol. (2018 Sep 11) [In press]. PMID: 30206782.
[2] L. Dwyer-Lindgren, A. Bertozzi-Villa, R.W. Stubbs, C. Morozoff, S. Shirude, M. Naghavi, et al., Trends and patterns of differences in chronic respiratory disease mortality among US Counties, 1980-2014, JAMA 318 (12) (2017 Sep 26) 1136–1149 PMID: 28973621.
[3] G. D'Amato, C. Vitale, A. Molino, A. Stanziola, A. Sanduzzi, A. Vatrella, et al., Asthma-related deaths, Multidiscip. Respir. Med. 11 (2016 Oct 12) 37 PMID: 27752310.
[4] S. Papiris, A. Kotanidou, K. Malagari, C. Roussos, Clinical review: severe asthma, Crit. Care 6 (1) (2002 Feb) 30–44 PMID: 11940264.
[5] H.E. Trejo Bittar, S.A. Yousem, S.E. Wenzel, Pathobiology of severe asthma, Annu. Rev. Pathol. 10 (2015) 511–545 PMID: 25423350.
[6] K. Malmström, J. Lohi, A. Sajantila, F.L. Jahnsen, M. Kajosaari, S. Sarna, et al., Immunohistology and remodeling in fatal pediatric and adolescent asthma, Respir. Res. 18 (1) (2017 May 16) 94 PMID: 28511697.
[7] M.R. Hill, C.J. Philp, C.K. Billington, A.L. Tatler, S.R. Johnson, R.D. O'Dea, et al., A theoretical model of inflammation- and mechanotransduction-driven asthmatic airway remodelling, Biomechanics Model. Mechanobiol. 17 (5) (2018 Oct) 1451–1470 PMID: 29968161.
[8] Z. Ali, L. Nilas, C.S. Ulrik, Postpartum airway responsiveness and exacerbation of asthma during pregnancy— a pilot study, J. Asthma Allergy 10 (2017 Oct 3) 261–267 PMID: 29042800.
[9] G. D'Amato, S.T. Holgate, R. Pawankar, D.K. Ledford, L. Cecchi, M. Al-Ahmad, et al., Meteorological conditions, climate change, new emerging factors, and asthma and related allergic disorders. A statement of the World Allergy Organization, World Allergy Organ J. 8 (1) (2015 Jul 14) 25 PMID: 26207160.
[10] R.D. Restrepo, J. Peters, Near-fatal asthma: recognition and management, Curr. Opin. Pulm. Med. 14 (1) (2008 Jan) 13–23 PMID: 18043271.
[11] L.E.X. Cohen, J. Tarsi, T. Ramkumar, T.K. Horiuchi, R. Cochran, et al., Epithelial cell proliferation contributes to airway remodeling in severe asthma, Am. J. Respir.

Crit. Care Med. 176 (2) (2007 Jul 15) 138–145 PMID: 17463414.
[12] M.1 Hassan, T. Jo, P.A. Risse, B. Tolloczko, C. Lemière, R. Olivenstein, et al., Airway smooth muscle remodeling is a dynamic process in severe long-standing asthma, J. Allergy Clin. Immunol. 125 (5) (2010 May) 1037–1045 e3. PMID: 20451038.
[13] H. Fehrenbach, C. Wagner, M. Wegmann, Airway remodeling in asthma: what really matters, Cell Tissue Res. 367 (3) (2017 Mar) 551–569 PMID: 28190087.
[14] G.H. Koppelman, I. Sayers, Evidence of a genetic contribution to lung function decline in asthma, J. Allergy Clin. Immunol. 128 (3) (2011 Sep) 479–484 PMID: 21752436.
[15] K. Rydell-Törmänen, P.A. Risse, V. Kanabar, R. Bagchi, M.P. Czubryt, J.R. Johnson, Smooth muscle in tissue remodeling and hyper-reactivity: airways and arteries, Pulm. Pharmacol. Therapeut. 26 (1) (2013 Feb) 13–23 PMID: 22561160.
[16] L.R. Bonser, D.J. Erle, Airway mucus and asthma: the role of MUC5AC and MUC5B, J. Clin. Med. 6 (12) (2017 Nov 29) PMID: 29186064.
[17] K.G. Welsh, K. Rousseau, G. Fisher, L.R. Bonser, P. Bradding, C.E. Brightling, et al., MUC5AC and a glycosylated variant of MUC5B alter mucin composition in children with acute asthma, Chest 152 (4) (2017 Oct) 771–779 PMID: 28716644.
[18] L.R. Bonser, L. Zlock, W. Finkbeiner, D.J. Erle, Epithelial tethering of MUC5AC-rich mucus impairs mucociliary transport in asthma, J. Clin. Invest. 126 (6) (2016 Jun 1) 2367–2371 PMID: 27183390.
[19] M. Ebina, T. Takahashi, T. Chiba, M. Motomiya, Cellular hypertrophy and hyperplasia of airway smooth muscles underlying bronchial asthma. A 3-D morphometric study, Am. Rev. Respir. Dis. 148 (3) (1993 Sep) 720–726 PMID: 8368645.
[20] A.L. James, J.G. Elliot, R.L. Jones, M.L. Carroll, T. Mauad, T.R. Bai, et al., Airway smooth muscle hypertrophy and hyperplasia in asthma, Am. J. Respir. Crit. Care Med. 185 (10) (2012 May 15) 1058–1064 PMID: 22403800.
[21] L. Benayoun, A. Druilhe, M.C. Dombret, M. Aubier, M. Pretolani, Airway structural alterations selectively associated with severe asthma, Am. J. Respir. Crit. Care Med. 167 (10) (2003 May 15) 1360–1368 PMID: 12531777.
[22] C. Febres-Aldana, R. Fernandez-Ruiz, F.A. Placeres-Uray, R.G. Alfonzo, M. Alfonzo, I.A. Becemberg, Pathobiology of airway smooth muscle remodeling, VITAE Acad. Bioméd. Digit. 64 (2015) 1–45. Available from: http://vitae.ucv.ve/pdfs/VITAE_5197.pdf.
[23] C.D. Pascoe, C.Y. Seow, T.L. Hackett, P.D. Paré, G.M. Donovan, Heterogeneity of airway wall dimensions in humans: a critical determinant of lung function in asthmatics and nonasthmatics, Am. J. Physiol. Lung Cell Mol. Physiol. 312 (3) (2017 Mar 1) L425–L431 PMID: 28062484.
[24] G.M. Donovan, Inter-airway structural heterogeneity interacts with dynamic heterogeneity to determine lung function and flow patterns in both asthmatic and control simulated lungs, J. Theor. Biol. 435 (2017 Dec 21) 98–105 PMID: 28867222.
[25] G.M. Donovan, J.G. Elliot, F.H.Y. Green, A.L. James, P.B. Noble, Unraveling a clinical paradox: why does bronchial thermoplasty work in asthma? Am. J. Respir. Cell Mol. Biol. 59 (3) (2018 Sep) 355–362 PMID: 29668295.
[26] F.L. Ricciardolo, A. Di Stefano, J.H. van Krieken, J.K. Sont, A. van Schadewijk, K.F. Rabe, et al., Proliferation and inflammation in bronchial epithelium after allergen in atopic asthmatics, Clin. Exp. Allergy 33 (7) (2003 Jul) 905–911 PMID: 12859446.
[27] H.O. Fjaerli, T. Farstad, G. Rød, G.K. Ufert, P. Gulbrandsen, B. Nakstad, Acute bronchiolitis in infancy as risk factor for wheezing and reduced pulmonary function by seven years in Akershus County, Norway, BMC Pediatr. 5 (2005 Aug 18) 31 PMID: 16109158.
[28] B. Fauroux, E.A.F. Simões, P.A. Checchia, B. Paes, J. Figueras-Aloy, P. Manzoni, et al., The burden and long-term respiratory morbidity associated with respiratory syncytial virus infection in early childhood, Infect. Dis. Ther. 6 (2) (2017 Jun) 173–197 PMID: 28357706.
[29] J.A. Yung, H. Fuseini, D.C. Newcomb, Hormones, sex, and asthma, Ann. Allergy Asthma Immunol. 120 (5) (2018 May) 488–494 PMID: 29410216.
[30] E. Martinez-Moragón, V. Plaza, J. Serrano, C. Picado, J.B. Galdiz, A. López-Viña, et al., Near-fatal asthma related to menstruation, J. Allergy Clin. Immunol. 113 (2) (2004 Feb) 242–244 PMID: 14767436.
[31] V. Sathish, Y.N. Martin, Y.S. Prakash, Sex steroid signaling: implications for lung diseases, Pharmacol. Ther. 150 (2015 Jun) 94–108 PMID: 25595323.
[32] G. D'Amato, C. Vitale, M. D'Amato, L. Cecchi, G. Liccardi, A. Molino, et al., Thunderstorm-related asthma: what happens and why, Clin. Exp. Allergy 46 (3) (2016 Mar) 390–396 PMID: 26765082.
[33] G. D'Amato, A. Corrado, L. Cecchi, G. Liccardi, A. Stanziola, I. Annesi-Maesano, et al., A relapse of near-fatal thunderstorm-asthma in pregnancy, Eur. Ann. Allergy Clin. Immunol. 45 (3) (2013 May) 116–117 PMID: 23862404.