Germline CBM-opathies: From immunodeficiency to atopy

Henry Y. Lu, BSc,[a,b] Catherine M. Biggs, MD,[a,b] Geraldine Blanchard-Rohner, MD, DPhil,[a] Shan-Yu Fung, PhD,[c,d] Mehul Sharma, MSc,[a] and Stuart E. Turvey, MBBS, DPhil[a,b] *Vancouver, British Columbia, Canada, and Tianjin, China*

INFORMATION FOR CATEGORY 1 CME CREDIT

Credit can now be obtained, free for a limited time, by reading the review articles in this issue. Please note the following instructions.

Method of Physician Participation in Learning Process: The core material for these activities can be read in this issue of the Journal or online at the JACI Web site: www.jacionline.org. The accompanying tests may only be submitted online at www.jacionline.org. Fax or other copies will not be accepted.

Date of Original Release: May 2019. Credit may be obtained for these courses until April 30, 2020.

Copyright Statement: Copyright © 2019-2020. All rights reserved.

Overall Purpose/Goal: To provide excellent reviews on key aspects of allergic disease to those who research, treat, or manage allergic disease.

Target Audience: Physicians and researchers within the field of allergic disease.

Accreditation/Provider Statements and Credit Designation: The American Academy of Allergy, Asthma & Immunology (AAAAI) is accredited by the Accreditation Council for Continuing Medical Education (ACCME) to provide continuing medical education for physicians. The AAAAI designates this journal-based CME activity for a maximum of 1.00 *AMA PRA Category 1 Credit*™. Physicians should claim only the credit commensurate with the extent of their participation in the activity.

List of Design Committee Members: Henry Y. Lu, BSc, Catherine M. Biggs, MD, Geraldine Blanchard-Rohner, MD, DPhil, Shan-Yu Fung, PhD, Mehul Sharma, MSc, and Stuart E. Turvey, MBBS, DPhil (authors); Zuhair K. Ballas, MD (editor)

Disclosure of Significant Relationships with Relevant Commercial Companies/Organizations: The authors declare that they have no relevant conflicts of interest. Z. K. Ballas (editor) disclosed no relevant financial relationships.

Activity Objectives:

1. To better understand the clinical presentation and implications of germline CBM-opathies.
2. To review optimal evaluation and management of a broad spectrum of human diseases categorized under germline CBM-opathies.

Recognition of Commercial Support: This CME activity has not received external commercial support.

List of CME Exam Authors: Neelam Phadke, MD, Jocelyn Farmer, MD, PhD, Sara Barmettler, MD, Ohn Chow, MD, PhD, Nicole LaHood, MD, David Pyle, MD, PhD, and Aleena Banerji, MD

Disclosure of Significant Relationships with Relevant Commercial Companies/Organizations: The exam authors disclosed no relevant financial relationships.

Caspase recruitment domain (CARD) protein–B cell CLL/lymphoma 10 (BCL10)–MALT1 paracaspase (MALT1) [CBM] complexes are critical signaling adaptors that facilitate immune and inflammatory responses downstream of both cell surface and intracellular receptors. Germline mutations that alter the function of members of this complex (termed CBM-opathies) cause a broad array of clinical phenotypes, ranging from profound combined immunodeficiency to B-cell lymphocytosis. With an increasing number of patients being described in recent years, the clinical spectrum of diseases associated with CBM-opathies is rapidly expanding and becoming unexpectedly heterogeneous. Here we review major discoveries that have shaped our understanding of CBM complex biology, and we provide an overview of the clinical presentation, diagnostic approach, and treatment options for those carrying germline mutations affecting CARD9, CARD11, CARD14, BCL10, and MALT1. (J Allergy Clin Immunol 2019;143:1661-73.)

Key words: *CBM-opathies, CARD9, CARD11, CARD14, BCL10, MALT1, primary immunodeficiencies, combined immunodeficiency, congenital B-cell lymphocytosis, primary atopic disease*

From [a]the Department of Pediatrics, British Columbia Children's Hospital, and [b]the Experimental Medicine Program, Faculty of Medicine, University of British Columbia, Vancouver, and [c]the Department of Immunology and [d]the Key Laboratory of Immune Microenvironment and Disease (Ministry of Education), Tianjin Medical University.

Supported in part by the Canadian Institutes of Health Research (CIHR); Genome British Columbia (SIP007 to S.E.T.); the Canadian Allergy, Asthma and Immunology Foundation; and the British Columbia Children's Hospital Foundation. S.E.T. holds the Canada Research Chair in Pediatric Precision Health and the Aubrey J. Tingle Professorship in Pediatric Immunology. C.M.B. is a Health Professional-Investigator of the Michael Smith Foundation for Health Research and is supported by the AllerGen Emerging Clinician-Scientist Research Fellowship. H.Y.L. is funded by a University of British Columbia Four Year Doctoral Fellowship.

Received for publication January 24, 2019; revised March 9, 2019; accepted for publication March 15, 2019.

Corresponding author: Stuart E. Turvey, MBBS, DPhil, FRCPC, BC Children's Hospital, 950 West 28th Ave, Vancouver, British Columbia V5Z 4H4, Canada. E-mail: sturvey@cw.bc.ca.

The CrossMark symbol notifies online readers when updates have been made to the article such as errata or minor corrections

0091-6749/$36.00

© 2019 American Academy of Allergy, Asthma & Immunology

https://doi.org/10.1016/j.jaci.2019.03.009

Abbreviations used

BCL10:	B-cell CLL/lymphoma 10
BCR:	B-cell receptor
BENTA:	B-cell expansion with NF-κB and T-cell anergy
CADINS:	CARD11-associated atopy with dominant interference of NF-κB signaling
CARD:	Caspase recruitment domain
CBM:	CARD-BCL10-MALT1
CC:	Coiled-coil
CID:	Combined immunodeficiency
CNS:	Central nervous system
DN:	Dominant negative
DOCK8:	Dedicator of cytokinesis 8
GOF:	Gain of function
HSCT:	Hematopoietic stem cell transplantation
IFD:	Invasive fungal disease
IκBα:	NF-κB inhibitor α
IKK:	Inhibitor of NF-κB kinase
IVIG:	Intravenous immunoglobulin
LOF:	Loss of function
MALT1:	MALT1 paracaspase
mTOR:	Mammalian target of rapamycin
mTORC:	Mechanistic target of rapamycin complex
NF-κB:	Nuclear factor κB
NGS:	Next-generation sequencing
NK:	Natural killer
PDZ:	Postsynaptic density protein, *Drosophila* disc large tumor suppressor, zonula occludens-1 protein domain
PID:	Primary immunodeficiency disease
PJP:	*Pneumocystis jirovecii* pneumonia
PRP:	Pityriasis rubra pilaris
PsV:	Psoriasis vulgaris
STAT:	Signal transducer and activator of transcription
TCR:	T-cell receptor
Treg:	Regulatory T

Human immunity is tightly regulated by complex networks of signals emanating from cellular receptors. Specific receptor-ligand associations trigger a cascade of protein-protein interactions and posttranslational modifications (eg, phosphorylation and ubiquitination), which lead to the activation of critical transcription factors that modulate the expression of immunologic and inflammatory genes. Aberrant signaling and regulation of these processes lead to pathology.

The caspase recruitment domain (CARD) protein–B cell CLL/lymphoma 10 (BCL10)–MALT1 paracaspase (MALT1) [CBM] signalosomes are multimeric protein complexes that facilitate cell activation, proliferation, and survival by transducing signals from diverse receptors to nuclear factor κB (NF-κB) and mitogen-activated protein kinase pathways (Fig 1).[1] Four discrete CBM complexes (differentiated by the type of CARD family protein incorporated) have been identified. Specifically, we will review the CBM complexes that incorporate CARD9, CARD10, CARD11, and CARD14. These CARD family members are large, structurally and functionally homologous scaffold proteins that share important protein oligomerization–associated CARD and coiled-coil (CC) domains (Figs 2 and 3).[2] CARD10, CARD11, and CARD14 additionally possess linker and membrane-associated guanylate kinase-like (MAGUK) regions (consisting of postsynaptic density protein, *Drosophila* disc large tumor suppressor, zonula occludens-1 protein domain [PDZ]; SRC homology 3; and guanylate kinase-like domains), which are absent in CARD9 (Fig 3).[2]

Each CARD protein has unique tissue and cellular distribution and associates with constitutively preassembled and ubiquitously expressed BCL10 and MALT1 heterodimers to form CBM complexes (Fig 2).[2] BCL10 is the central adaptor of these complexes and interacts with CARD proteins through CARD-CARD interactions and associates with MALT1 through its serine/threonine-rich region (Fig 3).[3] MALT1 is unusual in that it has 2 functions: (1) a protein scaffold to facilitate recruitment of downstream signaling proteins, such as TNF receptor–associated factor 6, and (2) a protease that cleaves a specific repertoire of proteins that regulate cell signaling (eg, TNF-α–induced protein 3 [A20/TNFAIP3] or cylindromatosis) to fine-tune the inflammatory response (Fig 1).[4]

Each CBM complex transduces signals from unique cells and receptors (Fig 2). CARD9-BCL10-MALT1 is found in neutrophils, macrophages, and dendritic cells and acts downstream of surface and cytosolic pattern recognition receptors and innate immune receptors, such as dectin-1, dectin-2, mincle, nucleotide-binding oligomerization domain containing 2, RAD50 double-strand break repair protein, and retinoic acid–inducible gene I.[5] It is a major regulator of antifungal immunity, including fungal sensing, T_H17 induction, proinflammatory cytokine production, neutrophil recruitment for fungal killing, and homeostatic control of the gut microbiota.[2,5]

CARD10-BCL10-MALT1 is expressed broadly in nonhematopoietic tissues, such as the heart, lungs, and kidneys and functions downstream of G protein–coupled receptors, such as angiotensin II receptor, lysophosphatidic acid receptor, and platelet-activating factor receptor.[6] It predominantly functions to mediate inflammatory responses in the hepatic, cardiovascular, and respiratory systems in the context of infectious, metabolic, or hormonal stimuli.[2] This includes controlling the recruitment of immune cells, proinflammatory cytokine production, and endothelial adhesiveness and permeability.[2]

CARD11-BCL10-MALT1 is expressed at high levels in B and T lymphocytes and acts downstream of the B-cell receptor (BCR) and T-cell receptor (TCR) antigen receptors.[1,2,7] This complex is crucial for regulating lymphocyte differentiation and humoral responses.

CARD14-BCL10-MALT1 is expressed at high levels in keratinocytes, Langerhans cells, and dermal endothelial cells and mediates signaling downstream of the IL-17 receptor and dectin-1.[8] Its physiologic role is not as clearly defined as those of other CBM complexes, but it has been implicated in pathogen recognition and proinflammatory cytokine signaling.[2]

SIGNALING BY THE CBM COMPLEXES

In general, ligand binding to receptors that use CARD9, CARD11, and CARD14 induces a signaling cascade leading to the activation of protein kinase C family members, which phosphorylate and activate CARD proteins (Figs 1 and 2). Of the CBM complexes, the assembly of the CARD11-BCL10-MALT1 complex in lymphocytes is best understood, although it is thought that other CBM complexes likely assemble in a similar manner and are also tightly regulated by posttranslational modifications, such as phosphorylation and ubiquitination.[2] Phosphorylation of CARD11 in its linker region causes it to

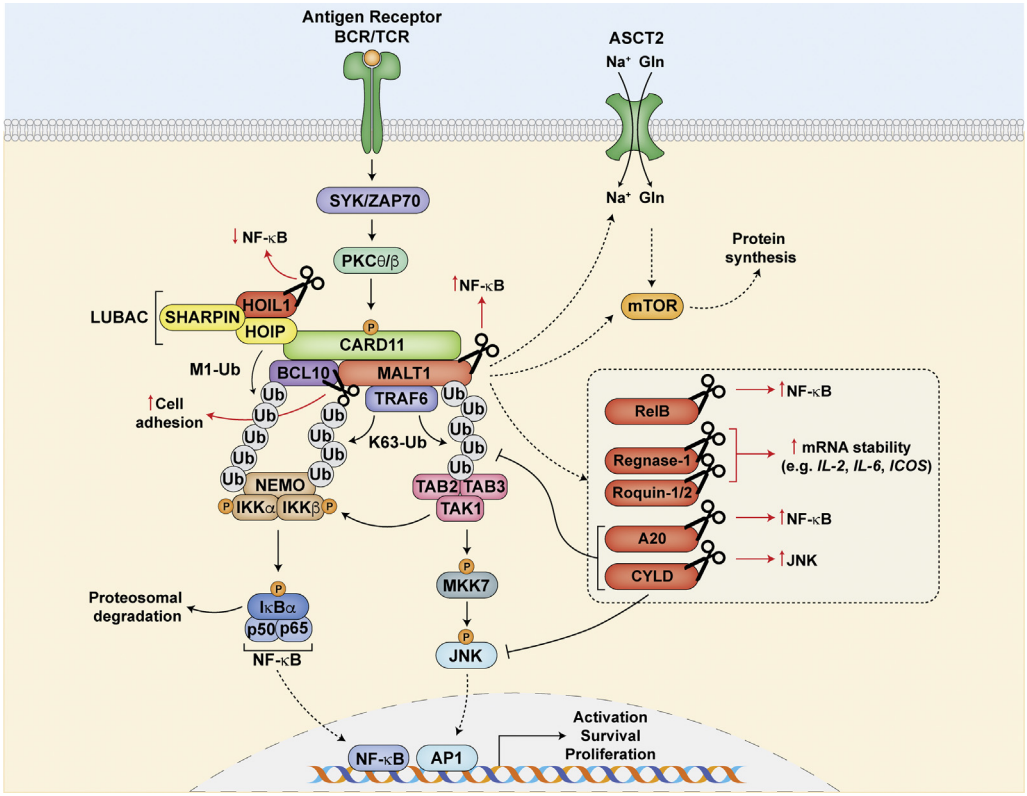

FIG 1. Role of the CBM complex in signal transduction. Scheme illustrating the principal functions of the CBM complex in activating and regulating NF-κB, JNK, and mTOR. *Scissors* indicate MALT1 paracaspase activity and substrates. *Red arrows* represent the consequences of MALT1-dependent cleavage. In general, antigen receptor stimulation leads to phosphorylation of CARD11 in its linker domain, causing it to convert from an inactive to an active conformation. This leads to the recruitment and assembly of the CBM complex. This facilitates the recruitment of ubiquitin regulatory proteins/complexes (LUBAC and TRAF6), which ligate unique ubiquitin chains to BCL10, MALT1, and NEMO. This creates binding sites for the IKK complex (NEMO and IKKα/β) and TGF-β–activated kinase 1 (MAP3K7) binding protein 2/3–TAK1, leading to the activation of NF-κB and JNK. In addition, this complex has an NF-κB–independent role in upregulating ASCT2 expression, regulating glutamine metabolism, and activating mTOR. *AP-1*, Activator protein 1; *ASCT2*, alanine-serine-cysteine transporter 2; *JNK*, c-Jun N-terminal kinase; *K63-Ub*, lysine 63–linked ubiquitin; *LUBAC*, linear ubiquitin chain assembly complex; *M1-Ub*, linear ubiquitin; *NEMO*, NF-κB essential modulator; *TAB2/3*, TGF-β–activated kinase 1 (MAP3K7) binding protein 2/3; *TRAF6*, TNF receptor–associated factor 6; *Ub*, ubiquitin.

convert from an autoinhibited state to an active conformation,[7] which allows for oligomerization, recruitment of BCL10-MALT1 heterodimers, and formation of a filamentous structure.[9] This facilitates recruitment of ubiquitin-regulatory proteins, such as the linear ubiquitin chain assembly complex, TNF receptor–associated factor 6, ubiquitin-conjugating enzyme E2, and tripartite motif–containing 62. These proteins catalyze the formation of linear, K63-linked, or K27-linked ubiquitin chains that attach to proteins, such as BCL10, MALT1, CARD9, and NF-κB essential modulator (NEMO/IKKγ; Fig 1).[2] This posttranslational modification generates new binding sites for ubiquitin-binding proteins, such as TGF-β–activated kinase 1 (MAP3K7) binding protein 2/3 (associated with TGF-β–activated kinase 1 [TAK1]) and NEMO (associated with inhibitor of NF-κB kinase [IKK] α/β), which brings these complexes close together, allowing TAK1 to phosphorylate IKKα/β (Fig 1).[1] The activated IKK complex acts to phosphorylate NF-κB inhibitor α (IκBα), leading to its proteosomal degradation. NF-κB, which is usually maintained in the cytoplasm by IκBα, is now liberated and translocates into the nucleus to induce specific gene expression (Fig 1).[1]

In addition to NF-κB, the CBM complex is also able to activate the mitogen-activated protein kinase and mammalian target of rapamycin (mTOR) pathways, which regulate lymphocyte proliferation and differentiation. More specifically, the CARD11-BCL10-MALT1 complex is able to mediate glutamine transport and T-cell metabolism independent of NF-κB by regulating expression of the alanine-serine-cysteine transporter 2 glutamine transporter and associating with mTOR to activate mechanistic target of rapamycin complex (mTORC) 1 and ribosomal protein S6 (Fig 1).[10,11] This CBM complex is also able to activate c-Jun N-terminal kinase by recruiting mitogen-activated protein kinase kinase 7 and TAK1, ultimately resulting in accumulation of c-Jun and activation of activator

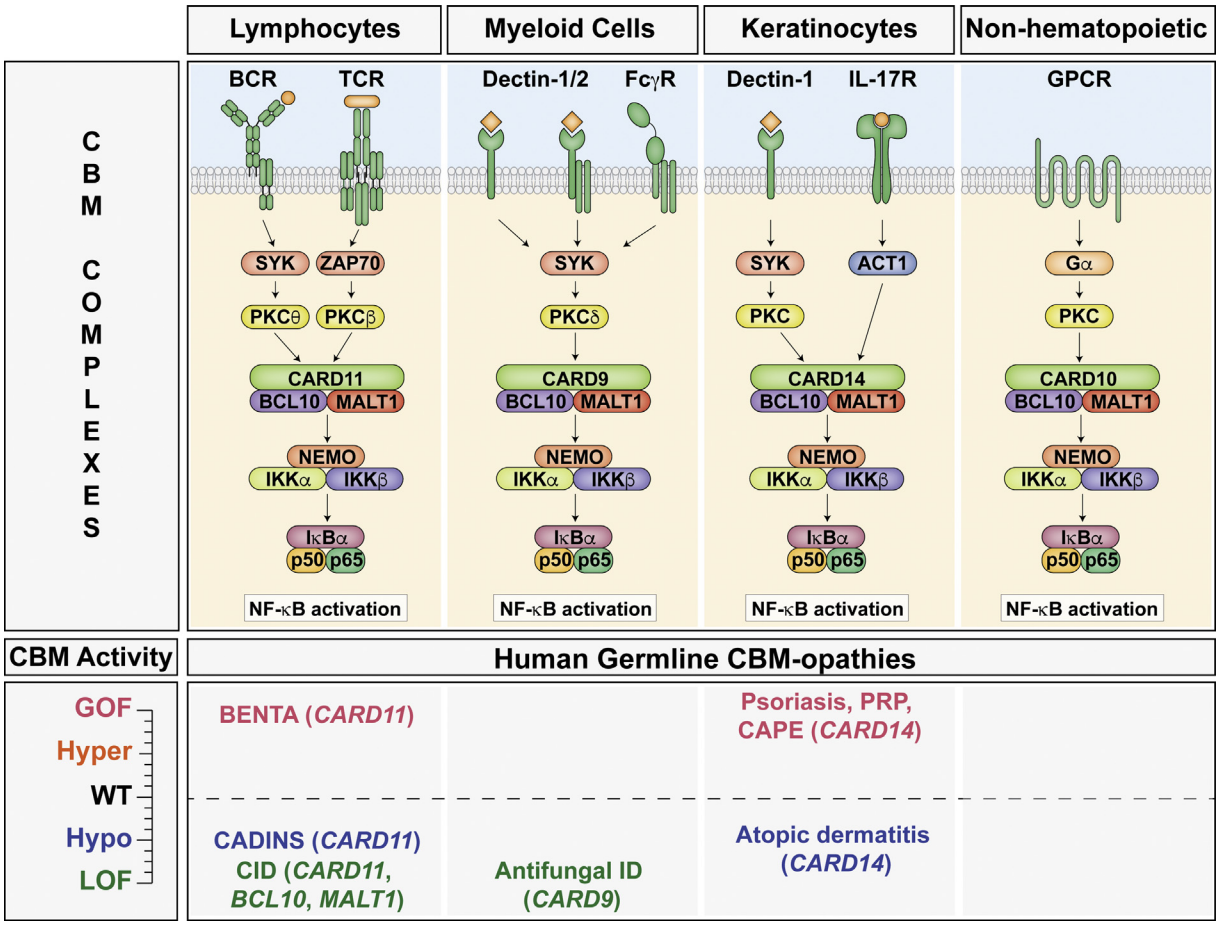

FIG 2. Cellular expression of CBM complexes and clinical manifestations associated with mutation-dependent variation in CBM activity. Simplified representation of unique CBM complexes found downstream of their respective receptors and cell types and their activation of NF-κB. *GPCR*, G protein–coupled receptor; *hyper*, hyperactivation; *hypo*, hypomorphic; *ID*, immunodeficiency; *LOF*, loss of function; *WT*, wild-type.

protein 1 (Fig 1).[1] Collectively, activation of CBM complexes regulates cellular activation, proliferation, metabolism, and survival.

DISCOVERY OF THE CBM COMPLEXES AND GERMLINE CBM-OPATHIES

Our current understanding of how CBM complexes regulate human immunity and physiology is built on a vast body of translational research, which was spurred by the identification of MALT lymphoma in 1983.[12] Since then, the past 35 years have witnessed remarkable medical and scientific progress and milestones that have transformed our understanding of MALT lymphomagenesis and human immunity.[13] In particular, starting with the clinical observation that gastric MALT lymphoma was strongly associated with *Helicobacter pylori* infection,[14] it was later discovered that MALT lymphoma proliferation was driven by inflammation and *H pylori*–specific T cells[15] and that patients with low-grade MALT lymphoma underwent clinical regression after eradication of *H pylori* infection with antibiotics.[16] Importantly, it was the subsequent efforts to understand the molecular basis of MALT lymphoma that paved the way for the discovery of CBM complex proteins, which we now know are not only critical regulators of innate and adaptive immunity but also the cause of a variety of primary immunodeficiency diseases (PIDs) and primary atopic disorders.

In the 1990s, 2 major chromosomal translocations in patients with MALT lymphoma were identified: t(11;18)(q21;q21)[17-19] and t(1;14)(p22;q32).[20,21] Cloning these breakpoints drove the discovery of CBM genes. In particular, the t(11;18)(q21;q21) breakpoint led to a fusion protein containing inhibitor of apoptosis 2 *(API2)* and MALT1 *(API2-MALT1)*, whereas the t(1;14)(p22;q32) breakpoint led to *BCL10* being placed under the control of the immunoglobulin heavy chain *(IGH)* gene enhancer *(IGH-BCL10)*. Both translocations were found to result in constitutive activation of NF-κB, a crucial transcription factor that mediates immune cell activation, proliferation, and survival.[22,23] These studies marked the discovery of the *MALT1*[17-19] and *BCL10*[20,21] genes.

Soon after, with the observation that both *API2-MALT1* and *IGH-BCL10* affected a common signaling pathway (ie, NF-κB), various groups identified that MALT1 and BCL10 constitutively coassociated and synergistically activated NF-κB (Figs 1 and 2).[22-24] Because BCL10 possessed an N-terminal CARD domain thought to be important for its activation and CARD-CARD interactions were known to mediate protein-protein interactions necessary for signal transduction, it was clear that there was a yet unidentified upstream regulator. Accordingly, various groups

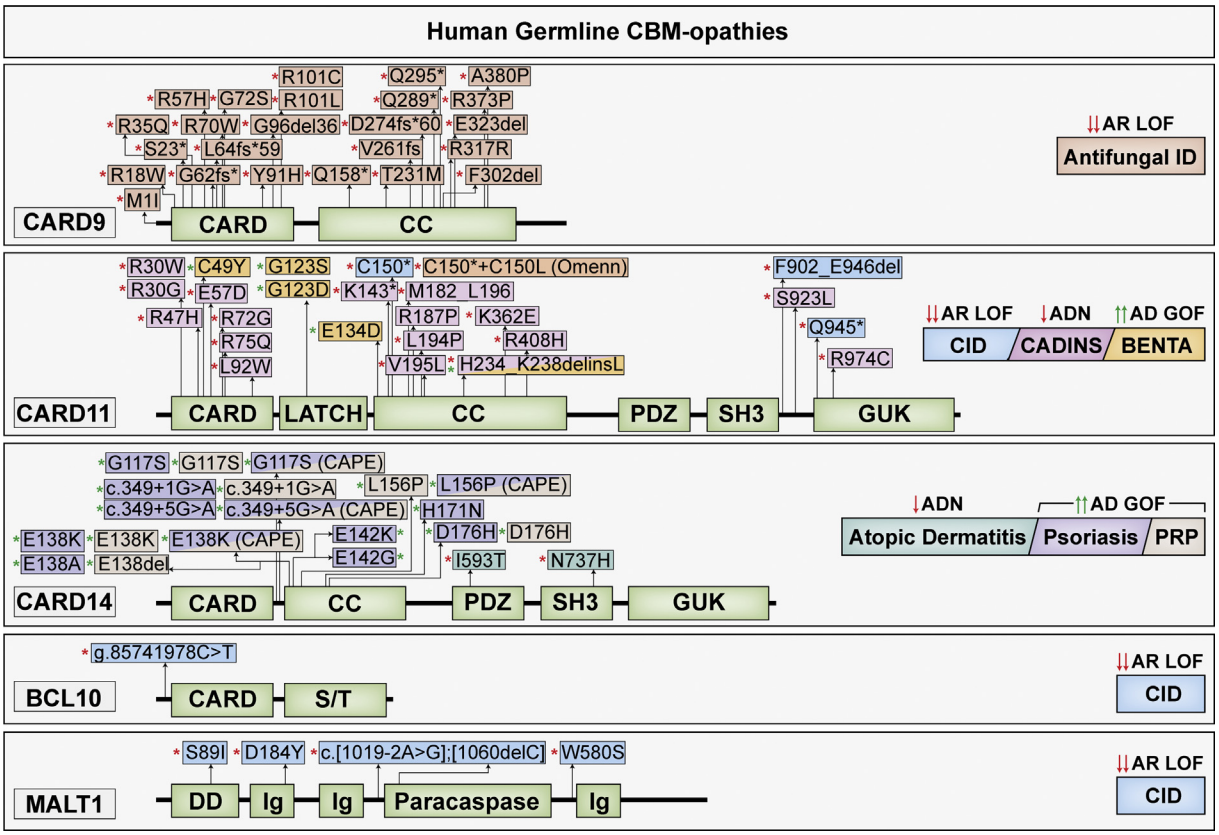

FIG 3. Germline mutations associated with CBM-opathies. Schematic representation of protein domains found in CARD9, CARD11, CARD14, BCL10 and MALT1. Annotated are reported germline mutations that cause antifungal immunodeficiency *(ID)*, CID, CADINS, BENTA, atopic dermatitis, psoriasis, PRP, and CARD14-associated papulosquamous eruption *(CAPE)*. *Double red downward arrows* indicate biallelic complete LOF, a *single red downward arrow* indicates autosomal dominant negative/hypomorphic function, and *double green upward arrows* indicate autosomal dominant GOF. *Red asterisks* beside mutations represent general LOF, and *green asterisks* represent general GOF. *AD*, Autosomal dominant; *ADN*, autosomal dominant negative; *AR*, autosomal recessive; *DD*, death domain; *GUK*, guanylate kinase–like domain; *SH3*, SRC homology 3 domain; *S/T*, serine/threonine-rich domain.

used a combination of mammalian 2-hybrid screens and bioinformatics to search for CARD-containing proteins that could oligomerize and interact with BCL10 to activate NF-κB. In the early 2000s, this gave rise to the CARD family of proteins: CARD9,[25] CARD10,[26] CARD11,[27-29] CARD14.[27]

Experimental knockout mouse models soon provided genetic evidence for the role of CBM proteins in activating major cell-signaling pathways, including NF-κB, c-Jun N-terminal kinase, and mTOR,[30-38] establishing the foundational knowledge that has empowered the recent identification of patients with mutations in each of these components (termed CBM-opathies).[1,39-49] As a result, it is clear that CBM complexes have a prominent role in regulating human immunity and immunopathology.

SPECTRUM OF HUMAN DISEASE CAUSED BY GERMLINE *CARD11* MUTATIONS

Biallelic loss-of-function mutations in *CARD11* cause profound combined immunodeficiency

Clinical and laboratory features. First described in 2013,[40,41] germline biallelic complete loss-of-function (LOF) mutations in *CARD11* cause profound combined immunodeficiency (CID) (for a detailed comparison of these cases, see Lu et al[1]). Three unique mutations have been reported: p.Gln945*,[41] p.Phe902_Glu946del,[40] and p.Cys150* (Fig 3).[50] These mutations were localized to the CC[50] and guanylate kinase–like domains[40,41] and resulted in either undetectable or truncated CARD11 protein expression. Patients presented within the first year of life with severe opportunistic viral or fungal pneumonia (*Pneumocystis jirovecii* pneumonia [PJP] is the most common) and respiratory symptoms (tachypnea and dyspnea) (Table I).[40,41,50] Similar to the phenotype of *Card11*$^{-/-}$ mice,[32,33] total B- and T-cell counts were generally reported to be normal, whereas regulatory T (Treg) cell counts were completely absent, and B-cell development was halted at the transitional stage.[40,41,50] In addition, T-cell proliferation was markedly reduced in response to PHA and anti-CD3/CD28 stimulation, whereas B-cell proliferation to pokeweed mitogen was normal. Consequently, patients had severely impaired humoral immunity, including profound hypogammaglobulinemia and absent protective vaccine titers.[40,41,50] Furthermore, *in vitro* investigation of patients' lymphocyte function demonstrated impairment of both proinflammatory cytokine secretion (eg, IL-2) and activation marker expression (eg, CD25), together with failure to activate the canonical NF-κB pathway.

TABLE I. Clinical hallmarks of human germline CBM-opathies

Common features of human germline CBM-opathies								
Gene	**CARD9**	**CARD11**			**CARD14**		**BCL10**	**MALT1**
Associated germline CBM-opathies	Antifungal ID	CID	CADINS	BENTA	Psoriasis/PRP	Atopic dermatitis	CID	CID
Inheritance	AR, biallelic	AR, biallelic	AD, heterozygous DN	AD, heterozygous	AD, heterozygous	AD, heterozygous DN	AR, biallelic	AR, biallelic
Functional effect	Loss	Loss	Hypomorphic	Gain	Gain	Hypomorphic	Loss	Loss
Protein expression	Absent, truncated, dysfunctional	Absent, truncated	Dysfunctional	Dysfunctional	Dysfunctional	Dysfunctional	Absent	Absent, truncated
Clinical features	Susceptibility to superficial and invasive fungal infections (particularly of CNS) with normal resistance to other pathogens	Severe opportunistic viral/fungal respiratory infections (particularly PJP), respiratory symptoms (tachypnea, dyspnea)	Atopic disease (atopic dermatitis, asthma), cutaneous viral infections, and respiratory tract infections	Early-onset polyclonal B-cell proliferation, splenomegaly, lymphadenopathy, recurrent sinopulmonary infections, and viral infections	PsV, generalized pustular psoriasis, PRP, CARD14-associated papulosquamous eruption	Atopic disease (severe atopic dermatitis, food allergies, asthma, allergic rhinitis), recurrent pyogenic/viral skin infections, recurrent respiratory tract infections	Otitis, gastroenteritis, diarrhea, colitis, persistent viral, bacterial, fungal infections of GI, CNS, and respiratory tract	Failure to thrive, abnormal facies, recurrent bacterial/viral/fungal infections affecting skin, lungs, and GI, enteropathy, periodontal disease, atopic dermatitis
Cell proportions	Normal lymphocyte and phagocyte numbers, ↓ T_H17	Normal total lymphocytes, absent Treg cells, ↑ naive B cells, ↓ memory B cells	Normal B and T cells, ↑ eosinophils	↑ B cells, ↑ mature naive B cells, ↑ immature transitional B cells, ↓ class-switched and memory B cells, normal T cells, ↑ double negative	Possible infiltrating lymphocytes/phagocytes	Normal	Normal total lymphocytes, absent Treg cells, ↑ naive B and T cells, ↓ memory B and T cells	Normal total lymphocytes, absent Treg cells, normal B cells, ↑ CD3, CD4, CD8 T cells
Immunoglobulin	↑ IgE	Panhypogammaglobulinemia, ↓ specific immunoglobulins	↑ IgE	Variable	—	↑↑ IgE	↓ IgG, IgA, IgM	↓ IgM, ↑ IgE, ↓ specific immunoglobulins
Mitogen proliferation	Normal	↓ T-cell proliferation	↓ T-cell proliferation	↓ T-cell proliferation	—	Not reported	↓ T-cell proliferation	↓ T-cell proliferation
NF-κB response	↓	↓↓↓	↓	↑	↑	↓	↓↓↓	↓↓↓
Treatment options	Antifungals, GM-CSF/G-CSF, HSCT	HSCT, IVIG, antimicrobial prophylaxis	Antimicrobial prophylaxis, IVIG, biologics (eg, dupilumab, omalizumab)	Antimicrobial prophylaxis, IVIG, cytoreductive drugs (eg, rituximab)	Topical and systemic immunomodulatory agents (eg, corticosteroids, methotrexate), biologics (eg, infliximab, ustekinumab)	Phototherapy and topical, systemic, and adjunctive atopic dermatitis therapy	HSCT, IVIG, antimicrobial prophylaxis	HSCT, IVIG, antimicrobial prophylaxis

Tabulation of notable clinical, laboratory, and *in vitro* findings among the CBM-opathies are shown. Features found in at least 50% of patients are indicated.
AD, Autosomal dominant; *AR*, autosomal recessive; *G-CSF*, granulocyte colony-stimulating factor; *GI*, gastrointestinal tract; *ID*, immunodeficiency; *RSV*, respiratory syncytial virus.

Intriguingly, there is now evidence that not only are the clinical phenotypes associated with germline autosomal dominant *CARD11* mutations expanding (discussed below) but phenotypes associated with full CARD11 deficiency are also becoming broader. In 2015, somatic reversion in a patient with CARD11 deficiency was linked to Omenn syndrome in a Turkish girl.[50] She was found to have the same p.Cys150* mutation in *CARD11* as her brother but additionally possessed a somatic second-site reversion (p.Cys150Leu; Fig 3), which partially restored CARD11 protein expression and function. She presented with features of both CARD11 deficiency (respiratory tract infections, panhypogammaglobulinemia, impaired T-cell proliferation, absent vaccine titers, and diminished Treg cell counts) and Omenn syndrome (progressive eczema, generalized erythroderma, hepatosplenomegaly, lymphadenopathy, and increased IgE levels).[50] Recently, our group has also identified a novel phenotype associated with CARD11 deficiency in a patient with a SCID phenotype and severe inflammatory gastrointestinal disease, further illustrating the broadening landscape of phenotypes that can be attributed to biallelic LOF *CARD11* mutations (H. Lu and S. Turvey, unpublished).

Diagnosis and management. Patients who present early in life with severe viral/fungal respiratory tract infections (especially PJP) but have normal total B- and T-cell numbers; absent/diminished Treg cell and memory B-cell numbers; impaired T-cell proliferation in response to T-cell mitogens, such as PHA and anti-CD3/CD28; and hypogammaglobulinemia should be evaluated for possible CARD11 deficiency.[1] A genetic diagnosis can often be secured by using next-generation sequencing (NGS) techniques, such as whole-exome sequencing, whole-genome sequencing, or an immunodeficiency gene panel. For novel variants, functional validation using methods to assess CARD11 protein expression, NF-κB phosphorylation, and IκBα degradation will often be required to confirm a diagnosis.[51]

Current data indicate that CARD11 deficiency is fatal within the first few years of life, with the most common causes of death

being respiratory failure and pneumonia.[1] On confirmation of CARD11 deficiency, hematopoietic stem cell transplantation (HSCT) should be pursued as soon as possible, particularly given that the only long-term survivors reported to date are 2 patients who underwent successful transplantation.[40,41] While awaiting definitive therapy, patients should receive both PJP prophylaxis (eg, trimethoprim/sulfamethoxazole) and immunoglobulin replacement therapy.

Heterozygous dominant negative mutations in *CARD11* cause CARD11-associated atopy with dominant interference of NF-κB signaling

Clinical and laboratory features. Although complete LOF *CARD11* mutations cause profound CID, heterozygous dominant negative (DN) mutations lead to a distinct clinical entity referred to as CARD11-associated atopy with dominant interference of NF-κB signaling (CADINS).[1,43,52-54] First described in 2017, this condition is characterized by atopy and variable autoimmune and/or infectious manifestations. Before this recent discovery, genetic evidence for CARD11 as a potential modulator of atopic disease came from a combination of both murine and genome-wide association studies. Specifically, *Card11*$^{un/un}$ (unmodulated) mice with hypomorphic *Card11* point mutations had spontaneous atopy and dermatitis,[55] while human genome-wide association studies identified *CARD11* as a risk locus for atopic dermatitis.[43,55,56]

CADINS is associated with a broad range of clinical manifestations bearing some similarities to other PIDs and immunodysregulatory syndromes (Table I).[43,52,53,57] Similar to dedicator of cytokinesis 8 (DOCK8) deficiency, the most common clinical features seen in patients with CADINS include atopic disease, cutaneous viral infections, and respiratory tract infections.[52,58] Some patients with CADINS also display skeletal features classically associated with autosomal DN signal transducer and activator of transcription (STAT) 3 mutations (broad nose and retained teeth), whereas others have presented with failure to thrive, diarrhea, and severe atopic dermatitis reminiscent of immune dysregulation, polyendocrinopathy, enteropathy, X-linked–like syndrome.[52,59] Atopy has been reported in close to 90% of cases, with atopic dermatitis and asthma being the most common, followed by food allergy, eosinophilic esophagitis, and allergic rhinoconjunctivitis.[52,57] Cutaneous viral infections are seen in the majority of patients, and implicated viruses include varicella zoster, molluscum contagiosum, herpes simplex, and human papilloma. Additional clinical features include autoimmunity, neutropenia, oral ulcers, and lymphoma.[52,57]

Immune evaluation typically reveals normal absolute T-cell and natural killer (NK) cell numbers with normal/low B-cell numbers, impaired T-cell proliferative responses, hypogammaglobulinemia, and impaired specific antibody responses.[52] Eosinophil counts and IgE levels are frequently increased, and cytokine profiling might reveal T_H2 skewing with impaired IFN-γ and increased IL-4 and IL-13 secretion.[43] Further *in vitro* studies of DN *CARD11* mutations demonstrated impaired NF-κB and variably impaired mTORC1 activation.[1,43,53,57]

Diagnosis and management. CADINS should be considered in patients with atopic disease, in particular when associated with cutaneous viral and/or respiratory tract infections.[1,52] Clinical heterogeneity has led to some patients presenting without atopy; therefore CADINS should also be considered when any of the reported clinical features are present in a family with a dominant inheritance pattern.[1,52] Screening for CADINS can involve assessing NF-κB signaling in primary T cells (eg, IκBα degradation and p65 phosphorylation in response to T-cell activation), although this is only likely to be available in a research setting.[1,52] Sequencing of *CARD11* should be performed when functional test results are abnormal or unavailable.[1] Current evidence suggests that the probability of an identified variant exerting a DN effect is greatest when the variant lies in the CARD and N-terminal CC domains (Fig 3). However, functional validation of any newly identified variant is recommended.[52]

Management of CADINS involves evaluating for and treating any existing atopic, infectious, malignant, and autoimmune disorders. Antimicrobial prophylaxis and intravenous immunoglobulin (IVIG) can be considered depending on the patient's immune profile and infectious history. Biologics targeting allergic immune dysregulation, such as dupilumab or mepolizumab, might be useful in patients with severe atopic disease. Promising *in vitro* data have shown that glutamine supplementation of CARD11 DN primary cells increases mTORC1 activation and partially restores T-cell proliferation and IFN-γ production.[43] Therefore further study is warranted to determine whether glutamine might provide a clinical benefit to patients with CADINS.

Heterozygous gain-of-function mutations in *CARD11* cause B-cell expansion with NF-κB and T-cell anergy

Clinical and laboratory features. Clinical consequences arise not only from deleterious mutations in *CARD11* but also from activating mutations. Somatic gain-of-function (GOF) *CARD11* mutations are associated with oncogenesis, most notably B-cell lymphomas, as well as cutaneous T-cell lymphomas and squamous cell carcinomas.[60-65] Germline heterozygous GOF *CARD11* mutations cause a B-cell lymphoproliferative disease and immunodeficiency referred to as B-cell expansion with NF-κB and T-cell anergy (BENTA).[42,66-69] First described clinically in 1971, *CARD11* mutations were identified as the genetic cause of BENTA in 2012.[1,42,70] Mutations conferring GOF activity are typically located in the CC or LATCH domains of CARD11 (Fig 3) and perturb interactions with the inhibitory linker domain, impairing autoinhibition.[1,67,71,72] This leads to spontaneous CARD11 aggregation, recruitment of the CBM complex, and constitutive activation of NF-κB.[42,67] Although CARD11 is critical for both TCR and BCR signaling, germline GOF mutations surprisingly have distinct effects on both cell types: lymphocytosis is restricted to the B-cell compartment, and T cells are hyporesponsive to TCR stimulation.[42]

Clinical features of BENTA include early-onset polyclonal B-cell proliferation, leading to splenomegaly and lymphadenopathy, recurrent sinopulmonary infections, and viral infections, including EBV, BK virus, and molluscum contagiosum viruses (Table I).[1] EBV can lead to acute symptomatic infections, as well as chronic viremia. However, the degree of viremia is typically low in comparison with that seen in patients with chronic active EBV or other PIDs that cause

susceptibility to this virus.[42,68,73,74] Autoimmunity in the form of cytopenias and autoantibody production only appears to affect a minority of patients.[42,68] Monoclonal B-cell expansion leading to cases of lymphoma and chronic lymphocytic leukemia in adulthood have also been described.[1,42]

Laboratory findings include B-cell lymphocytosis with increased immature transitional and mature naive B-cell numbers and markedly decreased class-switched/memory B-cell numbers.[1,68] Immunoglobulin levels vary from low to normal, and many patients are unable to mount protective responses to polysaccharide antigens or long-lived responses to conjugate vaccines, a feature attributed to the impaired ability of B cells to differentiate into plasmablasts and plasma cells.[75]

Diagnosis and management. B-cell lymphocytosis and splenomegaly at an early age should prompt consideration of BENTA.[1] Diagnosis is established by sequencing *CARD11*, with heterozygous variants located in the CC or LATCH domains being particularly suggestive (Fig 3). Novel variants can be cross-referenced to reported lymphoma-associated somatic mutations in catalogue of somatic mutations in cancer (COSMIC) to provide circumstantial support for GOF activity.[76] *In vitro* functional validation of any newly identified variants is recommended. Currently, this validation is likely only available in the research setting and often relies on transient expression of the mutant protein in a cell line, followed by evaluation for (constitutive) NF-κB activation.[1,42]

Management of BENTA is predominantly supportive and includes monitoring for malignant, autoimmune, and infectious complications. This might include assessing for monoclonal B-cell expansion by using flow cytometry and immunoglobulin heavy chain rearrangement analysis, as well as periodic assessment for infectious/autoimmune complications.[73] EBV viral loads can be followed because an increase might signify worsening T-cell and NK cell dysfunction that could also predispose to B-cell transformation.[1,73] Acute EBV infection has been successfully treated in one affected patient using IVIG, rituximab, corticosteroids, and acyclovir.[67,73] Immunoprophylaxis in the form of antibiotic prophylaxis and/or immunoglobulin replacement can be considered depending on the infectious history and clinical parameters. Splenectomy has been associated with a marked increase in peripheral B-cell counts and should be avoided if possible.[1,67,70] Cytoreductive agents, such as methotrexate and rituximab, might be considered to treat complications related to B-cell lymphocytosis. It has also been noted that B-cell levels tend to decrease with age in patients with BENTA.[1,67] Promising future directions include the potential use of targeted therapies that decrease hyperactive CBM signaling without completely abrogating NF-κB activation, such as MALT1 protease inhibitors.[1,73,77,78]

SPECTRUM OF HUMAN DISEASE CAUSED BY GERMLINE *CARD9* MUTATIONS

Biallelic LOF mutations in *CARD9* cause profound susceptibility to invasive fungal disease

Clinical and laboratory features. Germline biallelic LOF *CARD9* mutations are associated with an enhanced susceptibility to superficial and invasive fungal infections and normal resistance to other pathogens in otherwise healthy subjects (Table I).[79] Since its first description in a large consanguineous family in 2009,[39] more than 60 patients from 39 kindreds and 14 countries have been described with CARD9 deficiency.[79-81] A total of approximately 22 unique biallelic (homozygous and compound heterozygous) mutations have been observed in these patients, and they localize mostly to the promoter region or CARD and CC protein domains of CARD9 (Fig 3). These mutations generally did not affect *CARD9* transcript abundance but led to absent, truncated, or dysfunctional CARD9 protein expression.[79]

In addition to the diverse mutations described, there is clinical heterogeneity in terms of age of onset and fungal susceptibility. Although CARD9 deficiency displays complete penetrance in that all patients have fungal disease, the first infection might not occur until late adulthood.

A variety of fungi cause disease in patients with CARD9 deficiency and all reported cases have belonged to the Ascomycota phylum. Data indicate there is increased susceptibility to at least 7 fungal genera, including *Candida* species, *Trichophyton* species, *Phialophora* species, *Corynespora* species, *Aureobasidium* species, *Ochroconis* species, and *Exophiala* species, but CARD9 deficiency might also account for sporadic susceptibility to unusual fungi.[79] The majority of patients have invasive fungal disease (IFD) caused by only 1 fungus, and rarely do patients have IFD caused by different fungi over their lifetimes.[79] Patients can experience superficial and/or invasive infections from the same fungal organism. Characteristic features include chronic mucocutaneous candidiasis, invasive candidiasis (particularly involving the central nervous system [CNS]), invasive aspergillosis, extensive/deep dermatophytosis, and subcutaneous and invasive phaeohyphomycosis.[79]

Patients with CARD9 deficiency tend to have normal lymphocyte ($CD4^+$ T-cell, $CD8^+$ T-cell, B-cell, and NK) numbers, normal responses to mitogens (PHA), and normal phagocyte (PMN and monocyte) numbers and oxidative burst responses.[79] However, about half of these patients had increased IgE levels and hypereosinophilia in the absence of atopic disease. Although not all patient mutations underwent rigorous functional validation, in general, *in vitro* responses of PBMCs, monocytes, macrophages, and dendritic cells to fungal ligands, such as curdlan, zymosan, and *Candida albicans*, were impaired, as measured based on cytokine production, chemokine induction, NF-κB activation, and neutrophil recruitment.[79] In addition, the T_H17 axis (as assessed by IL-17 production and T_H17 numbers), which is critical for antifungal immunity, was found to be variably decreased.[79]

Diagnosis and management. Healthy subjects who present with unexplained invasive fungal infections and/or susceptibility to chronic mucocutaneous candidiasis without any acquired risk factors (HIV, malignancy, immunosuppression, and antibiotics) should be evaluated for *CARD9* mutations by using gene sequencing.[79] It is important to exclude other candidate genes that could have overlapping features with CARD9 deficiency, such as GATA-2 deficiency and *STAT1* GOF mutations. Because this is a recessive defect, confirmed diagnosis in a subject should prompt screening in family members and genetic counselling to pre-empt life-threatening fungal infections. If possible, functional validation of variants should be pursued, including assessing CARD9 protein expression and NF-κB activation; stimulating patients' PBMCs, neutrophils, or monocytes with fungi/fungal components (eg, zymosan and heat-killed *C albicans*); and measuring the secretion of proinflammatory cytokines, such as IL-6, IL-1β, TNF-α, and IL-17.[39,81,82]

Treatment of CARD9 deficiency primarily involves aggressive management of fungal infections, followed by secondary prophylaxis to prevent relapse. Primary prophylaxis in the form of oral fluconazole can be instituted in those with a diagnosis of CARD9 deficiency before disease onset (eg, in siblings of a patient who is identified by means of screening).[79] This will aid in preventing *Candida* species infections, but patients can still have other forms of IFDs and should undergo periodic monitoring for fungal infections. The choice and duration of antifungal treatment in infected patients is guided by the organism, infection severity, and location. Most patients relapse rapidly on treatment interruption, and thus longer courses or lifelong treatment might be required. Surgery is necessary in some cases to achieve source control (eg, brain abscesses).[79] In addition, adjunct subcutaneous administration of recombinant GM-CSF and granulocyte colony-stimulating factor has been efficacious for treating a small number of patients with refractory CNS candidiasis; however, others demonstrated no improvement or experienced disease worsening.[79,83] Therefore GM-CSF can be considered for refractory invasive infections but should be used with caution based on the limited reports of its use.[84] For CARD9-deficient patients with fungal infections refractory to both antifungals and adjunct treatment, HSCT can be considered; however, its utility in patients with CARD9 deficiency has not yet been established, and active fungal infection complicates any transplantation.[79,85]

SPECTRUM OF HUMAN DISEASE CAUSED BY GERMLINE *CARD14* MUTATIONS

Heterozygous DN LOF mutations in *CARD14* cause severe atopic dermatitis

Clinical and laboratory features. Autosomal dominant hypomorphic mutations in *CARD14* were very recently linked to severe atopic dermatitis (Table I).[44] In 2019, Peled et al[44] identified 4 patients with 2 unique mutations in *CARD14* affecting the PDZ (p.Ile593Thr) and SRC homology 3 (p.Asn737His) domains (Fig 3). Patients generally presented within the first year of life (3-12 months) with severe atopic dermatitis (SCORAD score >60) along with other atopic features, including markedly increased serum IgE levels, food allergies, asthma, and allergic rhinitis. Recurrent pyogenic and viral skin infections and respiratory tract infections were also commonly found in these patients. In general, laboratory values were unremarkable, with normal lymphocyte subsets (intermittent B-cell lymphopenia for 1 patient) and normal pneumococcal/polysaccharide responses. Two patients also had notable family histories of atopic dermatitis, allergies, allergic rhinitis, and asthma.[44] *In vitro*, these *CARD14* mutations led to impaired NF-κB activation, decreased inflammatory gene expression, and impaired epidermal secretion of antimicrobial peptides.[44]

Diagnosis and management. Patients presenting early in life with severe atopic dermatitis and other signs of atopy should be evaluated for primary atopic disorders, such as heterozygous DN *CARD11*, heterozygous DN *CARD14*, DN *STAT3*, and LOF *DOCK8* mutations.[86] Functional validation of novel *CARD14* variants can be achieved in a research setting by measuring NF-κB activation with a reporter assay or inflammatory gene expression by using quantitative PCR (eg, BD-1, BD-2, and CCL20).[44]

Patients who are heterozygous for DN *CARD14* mutations should first be managed according to guidelines from the American Academy of Dermatology.[87-90] From the small number of patients described thus far, it is clear that these patients had severe atopic dermatitis that was a challenge to control: one benefitted from wet-wrap therapy, and another showed improvement with mycophenolate mofetil and IVIG, but the third patient was resistant to phototherapy, bleach baths, and wet wraps.[44]

Heterozygous GOF mutations in *CARD14* cause psoriasis and pityriasis rubra pilaris

Clinical and laboratory features. Autosomal dominant GOF *CARD14* mutations are linked to psoriasis and the phenotypically related skin condition pityriasis rubra pilaris (PRP).[45-47,91] This link was first established in 2012 through genome-wide linkage analyses, which localized *CARD14* to the psoriasis risk locus called psoriasis susceptibility locus 2.[92] Since then, more than 10 GOF *CARD14* mutations have been linked to psoriatic skin disease, with even more variants found to be associated with this phenotype in linkage studies (Fig 3). However, many variants have not undergone rigorous functional validation, and it is unclear whether certain variants have a causative or a predisposing role in disease.[8,91] The majority of these mutations and variants were heterozygous (some were compound heterozygous/homozygous), and most localized to the CARD and CC domains of CARD14. This distribution of genetic variation is similar to that of *CARD11* in BENTA and in a similar fashion also disrupts CARD14 autoinhibition, causing constitutive assembly of CARD14-BCL10-MALT1 and NF-κB activation.[93] Of note, there is broad genetic and clinical heterogeneity among *CARD14* variants, including incomplete penetrance (asymptomatic healthy carriers) and specific variants (eg, p.Asp176His) being attributed to more than 1 type of skin disease.[91] Thus it is a possibility that these variants act as predisposing factors and additional genetic cofactors, and environmental stimuli are required for disease progression.[91]

CARD14 variants have been linked to psoriasis and a variety of psoriasiform inflammatory skin diseases, including psoriasis vulgaris (PsV), generalized pustular psoriasis, PRP, and the newly coined clinical entity of CARD14-associated papulosquamous eruption (Table I).[91] These diseases are differentiated by the morphology, distribution, immune cell infiltration, and anatomic location of lesions.[91] Briefly, PsV, the most common type, is characterized by well-delineated and raised oval red/salmon pink plaques covered with white scales that lead to acanthosis.[94] Generalized pustular psoriasis is characterized by sudden-onset widespread white pustules surrounded by erythematous skin along with infiltrating neutrophils and monocytes.[91,95] PRP is a rare form of psoriatic disease and is characterized by salmon-colored scaly plaques, islands of sparing unaffected skin, and palmoplantar keratoderma.[96] Patients with CARD14-associated papulosquamous eruption uniquely possess features of both psoriasis and PRP affecting the face (facial plaques on the cheeks, chin, and upper lip), ears (erythema), and palmoplantar keratoderma.[97]

Diagnosis and management. Early-onset PsV or PRP and a high level of suspicion might warrant sequencing of *CARD14* in the patient and family members to inform therapeutic decisions. Variants found in the CC and CARD domains are particularly suggestive of a possible GOF mutation.[91] Functional validation of variants identified, which is generally only available as a research tool, primarily relies on NF-κB reporter assays to assess for possible GOF activity.[91]

Psoriasis and PRP treatments are mostly supportive and traditionally have consisted of topical (eg, corticosteroids) and/or systemic (eg, methotrexate) immunomodulatory treatments, among others.[98,99] Biologics have also emerged as potent therapeutic options, targeting TNF-α (eg, infliximab), IL-12/IL-23p40 (eg, ustekinumab), and IL-17 (eg, secukinumab).[98,99] Recent promising results have demonstrated that both infliximab[100] and ustekinumab[97,101] could be particularly effective for treating patients with CARD14-associated psoriasis/PRP. In the future, therapeutic inhibition of MALT1 might be another exciting avenue for treating CARD14 GOF-mediated psoriatic skin disorders.[102]

HUMAN DISEASE CAUSED BY GERMLINE *BCL10* MUTATIONS

Biallelic LOF mutations in *BCL10* cause CID

Clinical and laboratory features. First described in 2014, germline LOF mutations in *BCL10* have been described in a single patient with CID and autoimmunity (Table I).[48] This occurred in a 3-year-old Amerindian boy who harbored a homozygous splice-site mutation in *BCL10* (g.85741978C>T; IVS1+1G>A; Fig 3), which resulted in no detectable BCL10 mRNA nor protein in the patient's cells. The patient presented with otitis, gastroenteritis, prolonged diarrhea, and chronic colitis, along with a history of uncontrolled viral/bacterial/fungal infections affecting the gastrointestinal tract, CNS, and respiratory tract. He eventually succumbed to respiratory failure at the age of 3 years.[1,48]

Laboratory findings revealed normal lymphocyte numbers, profoundly diminished Treg cell numbers, predominantly naive B- and T-cell numbers, impaired T-cell proliferation in response to anti-CD3/CD28, and hypogammaglobulinemia, mirroring the phenotype of *Bcl10*$^{-/-}$ mice.[36] In addition, *in vitro* investigation of the patient's cells revealed intact myeloid responses to Toll-like receptor stimulation but abolished fibroblast responses, as measured by cytokine production and NF-κB nuclear translocation.[48]

Diagnosis and management. Patients who present with broad immunodeficiency impairing fibroblasts, B cells, and T cells along with severe inflammatory gastrointestinal disease and respiratory tract infections should be considered for BCL10 deficiency. Based on murine studies and this single patient, it is likely that these patients will have absent Treg cells, hypogammaglobulinemia, and predominantly naive lymphocytes.[36,48] Sequencing *BCL10*, followed by functional assessment of novel variants, is necessary for the most accurate prognosis, therapy, and genetic counseling. Possible *in vitro* functional tests include assessing NF-κB activation and proinflammatory cytokine production in response to antigen receptor/Toll-like receptor stimulation.[48]

Treatment options specific to BCL10 deficiency remain unclear because only a single case has been identified to date. However, traditional approaches to treating CID, such as immunoglobulin replacement therapy and antimicrobial prophylaxis, are indicated, and HSCT should be strongly considered to restore BCL10 function.

HUMAN DISEASE CAUSED BY GERMLINE *MALT1* MUTATIONS

Biallelic LOF mutations in *MALT1* cause CID

Clinical and laboratory features. Germline biallelic LOF MALT1 mutations causing CID were first described in 2013 in a large consanguineous family.[49] Since then, a total of 6 MALT1-deficient patients have been reported (for a detailed comparison of these cases, please refer to Lu et al[1]) with 4 unique mutations: homozygous p.Trp580Ser, homozygous p.Ser89Ile, homozygous p.Asp184Tyr, and compound heterozygous c.[1019-2A>G];[1060delC]; Fig 3.[103-105] These mutations localized to the death, immunoglobulin-like 1, immunoglobulin-like 2, and paracaspase domains and led to absent or severely decreased MALT1 protein expression.

Patients typically presented with a combination of failure to thrive; recurrent bacterial/viral/fungal infections of the skin, respiratory tract, and gastrointestinal tract; periodontal disease (eg, aphthous ulcers, cheilitis, and gingivitis); dermatitis; and inflammatory gastrointestinal disease (Table I).[1,49,103-105] Laboratory phenotyping generally demonstrated normal lymphocyte and B-cell numbers (although typical B-cell maturation can be arrested); variably increased CD3$^+$, CD4$^+$, CD8$^+$ T-cell subsets; severely diminished Treg cell numbers; impaired T-cell proliferation in response to antigen receptor ligation/mitogens; variable immunoglobulin levels (decreased IgM or increased IgE levels); and decreased specific antibody titers. *In vitro* biochemical characterization of patients' cells showed impaired activation of NF-κB and decreased IL-2 secretion.

In addition, our group recently demonstrated that MALT1 proteolytic activity was abrogated in 1 patient,[103] and patients' cells were unable to cleave a newly discovered MALT1 paracaspase substrate called heme-oxidized IRP2 ubiquitin ligase 1.[106] Because heme-oxidized IRP2 ubiquitin ligase is a member of the linear ubiquitin chain assembly complex (Fig 1), which is a positive regulator of NF-κB and inflammation, the consequence of MALT1 deficiency is that no molecular brake can be applied on inflammation.[106] It is thought that this likely contributes to the autoinflammatory phenotype of many of these MALT1-deficient patients, a feature replicated in *Malt1* protease–deficient mice, which develop spontaneous autoinflammation in the gut.[107-109]

Diagnosis and management. Patients who present to the clinic with recurrent bacterial/viral sinopulmonary infections, inflammatory gastrointestinal disease, dermatitis, periodontal disease, and failure to thrive should be evaluated for possible MALT1 deficiency.[1] This can be accomplished by using directed Sanger sequencing or NGS techniques. For novel variants, informative functional validation includes assessing NF-κB activation and MALT1 cleavage of paracaspase substrates in response to antigen receptor stimulation.[103,106]

Left untreated, MALT1 deficiency is fatal; the first 2 recognized cases died of respiratory failure at the ages of 7 and 13 years.[49] Based on the reported cases, curative HSCT has been very effective for normalizing immune function and should be rapidly instigated in patients with confirmed MALT1 deficiency.[104,105,110] Immunoglobulin replacement and prophylactic antimicrobial agents should be used as a bridge to definitive therapy with HSCT.

CBM-OPATHIES: THERAPEUTIC AND CLINICAL IMPLICATIONS

The therapeutic approach to CBM-opathies parallels the diversity seen in their clinical manifestations and is informed

by sequelae associated with a particular immune defect. Complete abrogation of NF-κB signaling, as seen in biallelic LOF mutations of the CBM complex, warrants careful consideration of curative HSCT. Heterozygous mutations that lead to partially defective or enhanced signaling benefit from a thoughtful tailored approach that addresses the immune deficiency and dysregulation unique to the genotype and patient. Today this will likely involve a combination of regular monitoring (for malignancy, autoimmunity, and infections) and immunoprophylaxis (antimicrobials and/or immunoglobulin replacement). In the future, patients will likely benefit from a precision medicine approach, such as the use of specific inhibitors of the CBM complex, that may be used to treat GOF mutations.

The immunophenotypic spectrum seen across patients with CBM-opathies demonstrates the evolving complexities in diagnosing and managing PIDs and primary atopic disorders. Manifestations that vary in severity and encompass atopy, infection, autoimmunity, and malignancy indicate the importance of considering monogenic immune disorders when evaluating any patient. The discovery of both CADINS and LOF *CARD14* mutations highlight that severe atopic dermatitis, a relatively common pediatric condition, should raise suspicion for a monogenic immune disorder in certain clinical contexts, such as dominant familial inheritance associated with recurrent infections and/or autoimmunity.[1,44,52] The atopic disease caused by CBM-opathies is a timely reminder that unique monogenic disorders can closely mirror each other clinically, as evidenced by certain presentations of CADINS bearing resemblance to immune dysregulation, polyendocrinopathy, enteropathy, X-linked syndrome, DOCK8 deficiency, and autosomal dominant STAT3 deficiency.[52] A challenge for the field is the fact that mechanistic validation of newly identified variants remains a critical step in confirming their pathogenicity and informing useful genotype-phenotype correlations, but this validation is generally only available in the research setting.[51]

The critical value of functional validation was illustrated in a recent report of a family with a novel *CARD11* mutation displaying features suggestive of both dominant interference (atopic disease) and GOF (moderate B-cell lymphocytosis).[57] Functional studies provided an explanation for this paradox, revealing that the mutation caused constitutive NF-κB activity but also interfered with WT CARD11-induced NF-κB activation in response to antigen receptor ligation.[57]

CONCLUDING REMARKS

With increasing access to NGS technology for our patients, appreciation for heterogeneity in clinical presentations of CBM-opathies and other monogenic immune disorders will continue to expand. In the future, the characterization and description of novel CBM-opathies and related PIDs will help inform our understanding of the nuanced roles of each member of the CBM complex. This new knowledge will ultimately inform the development and implementation of precision medicine approaches targeting these proteins to improve the outcome of patients with autoimmunity, malignancy, and atopy.

What do we know?

- **CBM complex proteins interact to form a critical molecular bridge that regulates NF-κB activation in a remarkably broad array of immune and cellular contexts.**
- **Germline mutations that alter the function of members of the CBM complex are collectively termed CBM-opathies.**
- **Biallelic LOF mutations in *CARD11*, *BCL10*, and *MALT1* cause CID characterized by the unifying features of recurrent bacterial/viral infections, generally normal total B- and T-cell numbers, impaired TCR/BCR-mediated lymphocyte activation and proliferation, impaired NF-κB activation, absent Treg cells, and impaired specific antibody responses.**
- **Germline *CARD11* mutations can cause 3 distinct clinical conditions, CID, CADINS, and BENTA, depending on the nature of the mutation.**
- **MALT1 and BCL10 deficiency result in both CID and severe inflammatory gastrointestinal disease.**
- **CARD9 deficiency is highly heterogeneous and specifically leads to IFD caused by Ascomycota phylum fungi.**
- **Although hypomorphic mutations in *CARD11* and *CARD14* cause atopic dermatitis, GOF mutations are associated with BENTA and inflammatory psoriatic skin disease, respectively.**

What is still unknown?

- **Will targeted therapies that attenuate CBM signaling be a useful treatment modality for conditions caused by activating mutations in CBM complex genes?**
- **How does CARD11 deficiency predispose to PJP?**
- **Why does CARD9 deficiency increase susceptibility to infection by only one type of fungus in a given patient?**
- **Are *CARD14* GOF variants predisposing or causal factors in patients with psoriasis and PRP?**

REFERENCES

1. Lu HY, Bauman BM, Arjunaraja S, Dorjbal B, Milner JD, Snow AL, et al. The CBM-opathies—a rapidly expanding spectrum of human inborn errors of immunity caused by mutations in the CARD11-BCL10-MALT1 Complex. Front Immunol 2018;9:2078.
2. Ruland J, Hartjes L. CARD-BCL-10-MALT1 signalling in protective and pathological immunity. Nat Rev Immunol 2019;19:118-34.
3. Gehring T, Seeholzer T, Krappmann D. BCL10—bridging CARDs to immune activation. Front Immunol 2018;9:1539.
4. Juilland M, Thome M. Holding All the CARDs: how MALT1 controls CARMA/CARD-dependent signaling. Front Immunol 2018;9:1927.
5. Drummond RA, Franco LM, Lionakis MS. Human CARD9: a critical molecule of fungal immune surveillance. Front Immunol 2018;9:1836.
6. McAuley JR, Freeman TJ, Ekambaram P, Lucas PC, McAllister-Lucas LM. CARMA3 is a critical mediator of G protein-coupled receptor and receptor tyrosine kinase-driven solid tumor pathogenesis. Front Immunol 2018;9:1887.
7. Bedsaul JR, Carter NM, Deibel KE, Hutcherson SM, Jones TA, Wang Z, et al. Mechanisms of regulated and dysregulated CARD11 signaling in adaptive immunity and disease. Front Immunol 2018;9:2105.
8. Zotti T, Polvere I, Voccola S, Vito P, Stilo R. CARD14/CARMA2 signaling and its role in inflammatory skin disorders. Front Immunol 2018;9:2167.
9. Qiao Q, Yang C, Zheng C, Fontan L, David L, Yu X, et al. Structural architecture of the CARMA1/Bcl10/MALT1 signalosome: nucleation-induced filamentous assembly. Mol Cell 2013;51:766-79.
10. Nakaya M, Xiao Y, Zhou X, Chang JH, Chang M, Cheng X, et al. Inflammatory T cell responses rely on amino acid transporter ASCT2

facilitation of glutamine uptake and mTORC1 kinase activation. Immunity 2014;40:692-705.
11. Hamilton KS, Phong B, Corey C, Cheng J, Gorentla B, Zhong X, et al. T cell receptor-dependent activation of mTOR signaling in T cells is mediated by Carma1 and MALT1, but not Bcl10. Sci Signal 2014;7:ra55.
12. Isaacson P, Wright DH. Malignant lymphoma of mucosa-associated lymphoid tissue. A distinctive type of B-cell lymphoma. Cancer 1983;52:1410-6.
13. Isaacson PG, Du MQ. MALT lymphoma: from morphology to molecules. Nat Rev Cancer 2004;4:644-53.
14. Wotherspoon AC, Ortiz-Hidalgo C, Falzon MR, Isaacson PG. *Helicobacter pylori*-associated gastritis and primary B-cell gastric lymphoma. Lancet 1991;338:1175-6.
15. Hussell T, Isaacson PG, Crabtree JE, Spencer J. *Helicobacter pylori*-specific tumour-infiltrating T cells provide contact dependent help for the growth of malignant B cells in low-grade gastric lymphoma of mucosa-associated lymphoid tissue. J Pathol 1996;178:122-7.
16. Wotherspoon AC, Doglioni C, Diss TC, Pan L, Moschini A, de Boni M, et al. Regression of primary low-grade B-cell gastric lymphoma of mucosa-associated lymphoid tissue type after eradication of *Helicobacter pylori*. Lancet 1993;342:575-7.
17. Dierlamm J, Baens M, Wlodarska I, Stefanova-Ouzounova M, Hernandez JM, Hossfeld DK, et al. The apoptosis inhibitor gene API2 and a novel 18q gene, MLT, are recurrently rearranged in the t(11;18)(q21;q21) associated with mucosa-associated lymphoid tissue lymphomas. Blood 1999;93:3601-9.
18. Akagi T, Motegi M, Tamura A, Suzuki R, Hosokawa Y, Suzuki H, et al. A novel gene, MALT1 at 18q21, is involved in t(11;18) (q21;q21) found in low-grade B-cell lymphoma of mucosa-associated lymphoid tissue. Oncogene 1999;18:5785-94.
19. Morgan JA, Yin Y, Borowsky AD, Kuo F, Nourmand N, Koontz JI, et al. Breakpoints of the t(11;18)(q21;q21) in mucosa-associated lymphoid tissue (MALT) lymphoma lie within or near the previously undescribed gene MALT1 in chromosome 18. Cancer Res 1999;59:6205-13.
20. Willis TG, Jadayel DM, Du MQ, Peng H, Perry AR, Abdul-Rauf M, et al. Bcl10 is involved in t(1;14)(p22;q32) of MALT B cell lymphoma and mutated in multiple tumor types. Cell 1999;96:35-45.
21. Zhang Q, Siebert R, Yan M, Hinzmann B, Cui X, Xue L, et al. Inactivating mutations and overexpression of BCL10, a caspase recruitment domain-containing gene, in MALT lymphoma with t(1;14)(p22;q32). Nat Genet 1999;22:63-8.
22. Uren AG, O'Rourke K, Aravind LA, Pisabarro MT, Seshagiri S, Koonin EV, et al. Identification of paracaspases and metacaspases: two ancient families of caspase-like proteins, one of which plays a key role in MALT lymphoma. Mol Cell 2000;6:961-7.
23. Lucas PC, Yonezumi M, Inohara N, McAllister-Lucas LM, Abazeed ME, Chen FF, et al. Bcl10 and MALT1, independent targets of chromosomal translocation in malt lymphoma, cooperate in a novel NF-kappa B signaling pathway. J Biol Chem 2001;276:19012-9.
24. Lucas PC, McAllister-Lucas LM, Nunez G. NF-kappaB signaling in lymphocytes: a new cast of characters. J Cell Sci 2004;117:31-9.
25. Bertin J, Guo Y, Wang L, Srinivasula SM, Jacobson MD, Poyet JL, et al. CARD9 is a novel caspase recruitment domain-containing protein that interacts with BCL10/CLAP and activates NF-kappa B. J Biol Chem 2000;275:41082-6.
26. Wang L, Guo Y, Huang WJ, Ke X, Poyet JL, Manji GA, et al. Card10 is a novel caspase recruitment domain/membrane-associated guanylate kinase family member that interacts with BCL10 and activates NF-kappa B. J Biol Chem 2001;276:21405-9.
27. Bertin J, Wang L, Guo Y, Jacobson MD, Poyet JL, Srinivasula SM, et al. CARD11 and CARD14 are novel caspase recruitment domain (CARD)/membrane-associated guanylate kinase (MAGUK) family members that interact with BCL10 and activate NF-kappa B. J Biol Chem 2001;276:11877-82.
28. Gaide O, Martinon F, Micheau O, Bonnet D, Thome M, Tschopp J. Carma1, a CARD-containing binding partner of Bcl10, induces Bcl10 phosphorylation and NF-kappaB activation. FEBS Lett 2001;496:121-7.
29. McAllister-Lucas LM, Inohara N, Lucas PC, Ruland J, Benito A, Li Q, et al. Bimp1, a MAGUK family member linking protein kinase C activation to Bcl10-mediated NF-kappaB induction. J Biol Chem 2001;276:30589-97.
30. Gross O, Gewies A, Finger K, Schafer M, Sparwasser T, Peschel C, et al. Card9 controls a non-TLR signalling pathway for innate anti-fungal immunity. Nature 2006;442:651-6.
31. Grabiner BC, Blonska M, Lin PC, You Y, Wang D, Sun J, et al. CARMA3 deficiency abrogates G protein-coupled receptor-induced NF-{kappa}B activation. Genes Dev 2007;21:984-96.
32. Hara H, Wada T, Bakal C, Kozieradzki I, Suzuki S, Suzuki N, et al. The MAGUK family protein CARD11 is essential for lymphocyte activation. Immunity 2003;18:763-75.
33. Egawa T, Albrecht B, Favier B, Sunshine MJ, Mirchandani K, O'Brien W, et al. Requirement for CARMA1 in antigen receptor-induced NF-kappa B activation and lymphocyte proliferation. Curr Biol 2003;13:1252-8.
34. Wang M, Zhang S, Zheng G, Huang J, Songyang Z, Zhao X, et al. Gain-of-function mutation of Card14 leads to spontaneous psoriasis-like skin inflammation through enhanced keratinocyte response to IL-17A. Immunity 2018;49:66-79.e5.
35. Tanaka M, Kobiyama K, Honda T, Uchio-Yamada K, Natsume-Kitatani Y, Mizuguchi K, et al. Essential role of CARD14 in murine experimental psoriasis. J Immunol 2018;200:71-81.
36. Ruland J, Duncan GS, Elia A, del Barco Barrantes I, Nguyen L, Plyte S, et al. Bcl10 is a positive regulator of antigen receptor-induced activation of NF-kappaB and neural tube closure. Cell 2001;104:33-42.
37. Ruefli-Brasse AA, French DM, Dixit VM. Regulation of NF-kappaB-dependent lymphocyte activation and development by paracaspase. Science 2003;302:1581-4.
38. Ruland J, Duncan GS, Wakeham A, Mak TW. Differential requirement for Malt1 in T and B cell antigen receptor signaling. Immunity 2003;19:749-58.
39. Glocker EO, Hennigs A, Nabavi M, Schaffer AA, Woellner C, Salzer U, et al. A homozygous CARD9 mutation in a family with susceptibility to fungal infections. N Engl J Med 2009;361:1727-35.
40. Stepensky P, Keller B, Buchta M, Kienzler AK, Elpeleg O, Somech R, et al. Deficiency of caspase recruitment domain family, member 11 (CARD11), causes profound combined immunodeficiency in human subjects. J Allergy Clin Immunol 2013;131:477-85.e1.
41. Greil J, Rausch T, Giese T, Bandapalli OR, Daniel V, Bekeredjian-Ding I, et al. Whole-exome sequencing links caspase recruitment domain 11 (CARD11) inactivation to severe combined immunodeficiency. J Allergy Clin Immunol 2013;131:1376-83.e3.
42. Snow AL, Xiao W, Stinson JR, Lu W, Chaigne-Delalande B, Zheng L, et al. Congenital B cell lymphocytosis explained by novel germline CARD11 mutations. J Exp Med 2012;209:2247-61.
43. Ma CA, Stinson JR, Zhang Y, Abbott JK, Weinreich MA, Hauk PJ, et al. Germline hypomorphic CARD11 mutations in severe atopic disease. Nat Genet 2017;49:1192-201.
44. Peled A, Sarig O, Sun G, Samuelov L, Ma CA, Zhang Y, et al. Loss-of-function mutations in caspase recruitment domain-containing protein 14 (CARD14) are associated with a severe variant of atopic dermatitis. J Allergy Clin Immunol 2019;143:173-81.e10.
45. Jordan CT, Cao L, Roberson ED, Duan S, Helms CA, Nair RP, et al. Rare and common variants in CARD14, encoding an epidermal regulator of NF-kappaB, in psoriasis. Am J Hum Genet 2012;90:796-808.
46. Jordan CT, Cao L, Roberson ED, Pierson KC, Yang CF, Joyce CE, et al. PSORS2 is due to mutations in CARD14. Am J Hum Genet 2012;90:784-95.
47. Fuchs-Telem D, Sarig O, van Steensel MA, Isakov O, Israeli S, Nousbeck J, et al. Familial pityriasis rubra pilaris is caused by mutations in CARD14. Am J Hum Genet 2012;91:163-70.
48. Torres JM, Martinez-Barricarte R, Garcia-Gomez S, Mazariegos MS, Itan Y, Boisson B, et al. Inherited BCL10 deficiency impairs hematopoietic and nonhematopoietic immunity. J Clin Invest 2014;124:5239-48.
49. Jabara HH, Ohsumi T, Chou J, Massaad MJ, Benson H, Megarbane A, et al. A homozygous mucosa-associated lymphoid tissue 1 (MALT1) mutation in a family with combined immunodeficiency. J Allergy Clin Immunol 2013;132:151-8.
50. Fuchs S, Rensing-Ehl A, Pannicke U, Lorenz MR, Fisch P, Jeelall Y, et al. Omenn syndrome associated with a functional reversion due to a somatic second-site mutation in CARD11 deficiency. Blood 2015;126:1658-69.
51. Lu HY, Sharma M, Biggs CM, Huang Y-H, Shopsowitz KE, Frosk P, et al. The importance of functional validation after next-generation sequencing: evaluation of a novel CARD11 variant. Pediatr Allergy Immunol 2018;29:663-8.
52. Dorjbal B, Stinson JR, Ma CA, Weinreich MA, Miraghazadeh B, Hartberger JM, et al. Hypomorphic caspase activation and recruitment domain 11 (CARD11) mutations associated with diverse immunologic phenotypes with or without atopic disease. J Allergy Clin Immunol 2019;143:1482-95.
53. Dadi H, Jones TA, Merico D, Sharfe N, Ovadia A, Schejter Y, et al. Combined immunodeficiency and atopy caused by a dominant negative mutation in caspase activation and recruitment domain family member 11 (CARD11). J Allergy Clin Immunol 2018;141:1818-30.e2.
54. Biggs CM, Lu HY, Turvey SE. Monogenic immune disorders and severe atopic disease. Nat Genet 2017;49:1162-3.
55. Jun JE, Wilson LE, Vinuesa CG, Lesage S, Blery M, Miosge LA, et al. Identifying the MAGUK protein Carma-1 as a central regulator of humoral immune responses and atopy by genome-wide mouse mutagenesis. Immunity 2003;18:751-62.
56. Hirota T, Takahashi A, Kubo M, Tsunoda T, Tomita K, Sakashita M, et al. Genome-wide association study identifies eight new susceptibility loci for atopic dermatitis in the Japanese population. Nat Genet 2012;44:1222-6.
57. Desjardins M, Arjunaraja S, Stinson JR, Dorjbal B, Sundaresan J, Niemela J, et al. A unique heterozygous *CARD11* mutation combines pathogenic features of both gain- and loss-of-function patients in a four-generation family. Front Immunol 2018;9:2944.
58. Biggs CM, Keles S, Chatila TA. DOCK8 deficiency: insights into pathophysiology, clinical features and management. Clin Immunol 2017;181:75-82.

59. Freeman AF, Holland SM. The hyper-IgE syndromes. Immunol Allergy Clin North Am 2008;28:277-91.viii.
60. Jeelall YS, Wang JQ, Law HD, Domaschenz H, Fung HK, Kallies A, et al. Human lymphoma mutations reveal CARD11 as the switch between self-antigen-induced B cell death or proliferation and autoantibody production. J Exp Med 2012;209:1907-17.
61. Lenz G, Davis RE, Ngo VN, Lam L, George TC, Wright GW, et al. Oncogenic CARD11 mutations in human diffuse large B cell lymphoma. Science 2008;319:1676-9.
62. Watt SA, Purdie KJ, den Breems NY, Dimon M, Arron ST, McHugh AT, et al. Novel CARD11 mutations in human cutaneous squamous cell carcinoma lead to aberrant NF-κB regulation. Am J Pathol 2015;185:2354-63.
63. Yan Q, Huang Y, Watkins AJ, Kocialkowski S, Zeng N, Hamoudi RA, et al. BCR and TLR signaling pathways are recurrently targeted by genetic changes in splenic marginal zone lymphomas. Haematologica 2012;97:595-8.
64. Wu C, de Miranda NF, Chen L, Wasik AM, Mansouri L, Jurczak W, et al. Genetic heterogeneity in primary and relapsed mantle cell lymphomas: impact of recurrent CARD11 mutations. Oncotarget 2016;7:38180-90.
65. da Silva Almeida AC, Abate F, Khiabanian H, Martinez-Escala E, Guitart J, Tensen CP, et al. The mutational landscape of cutaneous T cell lymphoma and Sézary syndrome. Nat Genet 2015;47:1465-70.
66. Buchbinder D, Stinson JR, Nugent DJ, Heurtier L, Suarez F, Sukumar G, et al. Mild B-cell lymphocytosis in patients with a CARD11 C49Y mutation. J Allergy Clin Immunol 2015;136:819-21.e1.
67. Brohl AS, Stinson JR, Su HC, Badgett T, Jennings CD, Sukumar G, et al. Germline CARD11 mutation in a patient with severe congenital B cell lymphocytosis. J Clin Immunol 2015;35:32-46.
68. Gupta M, Aluri J, Desai M, Lokeshwar M, Taur P, Lenardo M, et al. Clinical, immunological, and molecular findings in four cases of B cell expansion with NF-κB and T cell anergy disease for the first time from India. Front Immunol 2018;9:1049.
69. Outinen T, Syrjanen J, Rounioja S, Saarela J, Kaustio M, Helminen M. Constant B cell lymphocytosis since early age in a patient with CARD11 mutation: a 20-year follow-up. Clin Immunol 2016;165:19-20.
70. Darte JM, McClure PD, Saunders EF, Weber JL, Donohue WL. Congenital lymphoid hyperplasia with persistent hyperlymphocytosis. N Engl J Med 1971;284:431-2.
71. Jattani RP, Tritapoe JM, Pomerantz JL. Intramolecular interactions and regulation of cofactor binding by the four repressive elements in the caspase recruitment domain-containing protein 11 (CARD11) inhibitory domain. J Biol Chem 2016;291:8338-48.
72. Jattani RP, Tritapoe JM, Pomerantz JL. Cooperative control of caspase recruitment domain-containing protein 11 (CARD11) signaling by an unusual array of redundant repressive elements. J Biol Chem 2016;291:8324-36.
73. Arjunaraja S, Angelus P, Su HC, Snow AL. Impaired control of Epstein-Barr virus infection in B-cell expansion with NF-κB and T-cell anergy disease. Front Immunol 2018;9:198.
74. Cohen JI, Jaffe ES, Dale JK, Pittaluga S, Heslop HE, Rooney CM, et al. Characterization and treatment of chronic active Epstein-Barr virus disease: a 28-year experience in the United States. Blood 2011;117:5835-49.
75. Arjunaraja S, Nosé BD, Sukumar G, Lott NM, Dalgard CL, Snow AL. Intrinsic plasma cell differentiation defects in B cell expansion with NF-κB and T cell anergy patient B cells. Front Immunol 2017;8:913.
76. Forbes SA, Beare D, Boutselakis H, Bamford S, Bindal N, Tate J, et al. COSMIC: somatic cancer genetics at high-resolution. Nucleic Acids Res 2017;45:D777-83.
77. Lee CH, Bae SJ, Kim M. Mucosa-associated lymphoid tissue lymphoma translocation 1 as a novel therapeutic target for rheumatoid arthritis. Sci Rep 2017;7:11889.
78. Saba NS, Wong DH, Tanios G, Iyer JR, Lobelle-Rich P, Dadashian EL, et al. MALT1 inhibition is efficacious in both naive and ibrutinib-resistant chronic lymphocytic leukemia. Cancer Res 2017;77:7038-48.
79. Corvilain E, Casanova JL, Puel A. Inherited CARD9 deficiency: invasive disease caused by ascomycete fungi in previously healthy children and adults. J Clin Immunol 2018;38:656-93.
80. Vaezi A, Fakhim H, Abtahian Z, Khodavaisy S, Geramishoar M, Alizadeh A, et al. Frequency and geographic distribution of CARD9 mutations in patients with severe fungal infections. Front Microbiol 2018;9:2434.
81. De Bruyne M, Hoste L, Bogaert DJ, Van den Bossche L, Tavernier SJ, Parthoens E, et al. A CARD9 founder mutation disrupts NF-kappaB signaling by inhibiting BCL10 and MALT1 recruitment and signalosome formation. Front Immunol 2018;9:2366.
82. Lanternier F, Cypowyj S, Picard C, Bustamante J, Lortholary O, Casanova JL, et al. Primary immunodeficiencies underlying fungal infections. Curr Opin Pediatr 2013;25:736-47.
83. Gavino C, Cotter A, Lichtenstein D, Lejtenyi D, Fortin C, Legault C, et al. CARD9 deficiency and spontaneous central nervous system candidiasis: complete clinical remission with GM-CSF therapy. Clin Infect Dis 2014;59:81-4.
84. Drummond RA, Zahra FT, Natarajan M, Swamydas M, Hsu AP, Wheat LJ, et al. GM-CSF therapy in human caspase recruitment domain-containing protein 9 deficiency. J Allergy Clin Immunol 2018;142:1334-8.e5.
85. Rieber N, Gazendam RP, Freeman AF, Hsu AP, Collar AL, Sugui JA, et al. Extrapulmonary Aspergillus infection in patients with CARD9 deficiency. JCI Insight 2016;1:e89890.
86. Lyons JJ, Milner JD. Primary atopic disorders. J Exp Med 2018;215:1009-22.
87. Eichenfield LF, Tom WL, Chamlin SL, Feldman SR, Hanifin JM, Simpson EL, et al. Guidelines of care for the management of atopic dermatitis: section 1. Diagnosis and assessment of atopic dermatitis. J Am Acad Dermatol 2014;70:338-51.
88. Eichenfield LF, Tom WL, Berger TG, Krol A, Paller AS, Schwarzenberger K, et al. Guidelines of care for the management of atopic dermatitis: section 2. Management and treatment of atopic dermatitis with topical therapies. J Am Acad Dermatol 2014;71:116-32.
89. Sidbury R, Davis DM, Cohen DE, Cordoro KM, Berger TG, Bergman JN, et al. Guidelines of care for the management of atopic dermatitis: section 3. Management and treatment with phototherapy and systemic agents. J Am Acad Dermatol 2014;71:327-49.
90. Sidbury R, Tom WL, Bergman JN, Cooper KD, Silverman RA, Berger TG, et al. Guidelines of care for the management of atopic dermatitis: section 4. Prevention of disease flares and use of adjunctive therapies and approaches. J Am Acad Dermatol 2014;71:1218-33.
91. Israel L, Mellett M. Clinical and genetic heterogeneity of CARD14 mutations in psoriatic skin disease. Front Immunol 2018;9:2239.
92. International Psoriasis Genetics Consortium. The International Psoriasis Genetics Study: assessing linkage to 14 candidate susceptibility loci in a cohort of 942 affected sib pairs. Am J Hum Genet 2003;73:430-7.
93. Howes A, O'Sullivan PA, Breyer F, Ghose A, Cao L, Krappmann D, et al. Psoriasis mutations disrupt CARD14 autoinhibition promoting BCL10-MALT1-dependent NF-kappaB activation. Biochem J 2016;473:1759-68.
94. Griffiths CE, Barker JN. Pathogenesis and clinical features of psoriasis. Lancet 2007;370:263-71.
95. Bachelez H. Pustular psoriasis and related pustular skin diseases. Br J Dermatol 2018;178:614-8.
96. Wang D, Chong VC, Chong WS, Oon HH. A review on pityriasis rubra pilaris. Am J Clin Dermatol 2018;19:377-90.
97. Craiglow BG, Boyden LM, Hu R, Virtanen M, Su J, Rodriguez G, et al. CARD14-associated papulosquamous eruption: a spectrum including features of psoriasis and pityriasis rubra pilaris. J Am Acad Dermatol 2018;79:487-94.
98. Kim WB, Jerome D, Yeung J. Diagnosis and management of psoriasis. Can Fam Physician 2017;63:278-85.
99. Moretta G, De Luca EV, Di Stefani A. Management of refractory pityriasis rubra pilaris: challenges and solutions. Clin Cosmet Investig Dermatol 2017;10:451-7.
100. Takeichi T, Sugiura K, Nomura T, Sakamoto T, Ogawa Y, Oiso N, et al. Pityriasis rubra pilaris type V as an autoinflammatory disease by CARD14 mutations. JAMA Dermatol 2017;153:66-70.
101. Lwin SM, Hsu CK, Liu L, Huang HY, Levell NJ, McGrath JA. Beneficial effect of ustekinumab in familial pityriasis rubra pilaris with a new missense mutation in CARD14. Br J Dermatol 2018;178:969-72.
102. Afonina IS, Van Nuffel E, Baudelet G, Driege Y, Kreike M, Staal J, et al. The paracaspase MALT1 mediates CARD14-induced signaling in keratinocytes. EMBO Rep 2016;17:914-27.
103. McKinnon ML, Rozmus J, Fung SY, Hirschfeld AF, Del Bel KL, Thomas L, et al. Combined immunodeficiency associated with homozygous MALT1 mutations. J Allergy Clin Immunol 2014;133:1458-62, e1-7.
104. Punwani D, Wang H, Chan AY, Cowan MJ, Mallott J, Sunderam U, et al. Combined immunodeficiency due to MALT1 mutations, treated by hematopoietic cell transplantation. J Clin Immunol 2015;35:135-46.
105. Charbit-Henrion F, Jeverica AK, Begue B, Markelj G, Parlato M, Avcin SL. Deficiency in mucosa-associated lymphoid tissue lymphoma translocation 1: a novel cause of IPEX-like syndrome. J Pediatr Gastroenterol Nutr 2017;64:378-84.
106. Klein T, Fung SY, Renner F, Blank MA, Dufour A, Kang S, et al. The paracaspase MALT1 cleaves HOIL1 reducing linear ubiquitination by LUBAC to dampen lymphocyte NF-kappaB signalling. Nat Commun 2015;6:8777.
107. Gewies A, Gorka O, Bergmann H, Pechloff K, Petermann F, Jeltsch KM, et al. Uncoupling Malt1 threshold function from paracaspase activity results in destructive autoimmune inflammation. Cell Rep 2014;9:1292-305.
108. Jaworski M, Marsland BJ, Gehrig J, Held W, Favre S, Luther SA, et al. Malt1 protease inactivation efficiently dampens immune responses but causes spontaneous autoimmunity. EMBO J 2014;33:2765-81.
109. Bornancin F, Renner F, Touil R, Sic H, Kolb Y, Touil-Allaoui I, et al. Deficiency of MALT1 paracaspase activity results in unbalanced regulatory and effector T and B cell responses leading to multiorgan inflammation. J Immunol 2015;194:3723-34.
110. Rozmus J, McDonald R, Fung SY, Del Bel KL, Roden J, Senger C, et al. Successful clinical treatment and functional immunological normalization of human MALT1 deficiency following hematopoietic stem cell transplantation. Clin Immunol 2016;168:1-5.