The Laryngoscope
© 2020 The American Laryngological, Rhinological and Otological Society, Inc.

Eosinophilic Sialodochitis: A Type of Chronic Obstructive Sialadenitis Related to Allergy

Wen-Xuan Zhu, DDS; Yan Chen, MD, DDS; Deng-Gao Liu, MD; Guang-Yan Yu, PhD, DDS

Objectives: To investigate the clinical, laboratory, radiological, histopathological, and immunohistochemical features, and the expression of allergy-related cytokines in eosinophilic sialodochitis (ES).

Methods: Thirty-eight patients diagnosed with chronic obstructive sialadenitis (COS) who had undergone glandular excision or incisional biopsy were enrolled. Seventeen patients with comorbid atopic disease and increased ductal tissue eosinophils comprised the ES group, while 21 patients comprised the COS group. The clinicopathological features and allergy-related cytokine expression were compared between groups.

Results: The ES group frequently involved multiple, bilateral major salivary glands, and the number of glands was significantly greater than the COS group (2.8 ± 1.1 vs. 1.2 ± 0.4, $P < .001$). Serum immunoglobulin (Ig) E was elevated in 91% of patients in ES group (419 ± 357 kU/L) and peripheral blood eosinophil was significantly greater compared with the COS group (7.6% ± 4.6% vs. 2.5% ± 1.4%, $P < .001$). Histologically, eosinophil infiltration in ES group was observed around the main and interlobular ducts (50 ± 39/high power field [HPF]). Follicular hyperplasia (76%), epithelial mucous metaplasia (82%), and mucus plugs with eosinophils (41%) were observed. IgE-positive cell count was 20.7 ± 18.3/HPF and tryptase-positive mast cell count was 23.5 ± 15.1/HPF, which was significantly greater than the respective cell counts in COS group, which mainly infiltrated around the ducts. The levels of interleukin-4, interleukin-13, and eotaxin in tissue were significantly greater in ES than the COS group.

Conclusions: The clinicopathological characteristics of ES are significantly different from COS and ES might have an allergy-related pathogenesis.

Key Words: Eosinophilic sialodochitis, chronic obstructive sialadenitis, immunoglobulin E, allergy, salivary gland.

Level of Evidence: 4

***Laryngoscope*, 00:1–7, 2020**

INTRODUCTION

Chronic obstructive sialadenitis (COS) is a relatively common disease of the salivary glands. COS may result from blockage of ducts by mucus plugs, salivary stones, ductal strictures, and anatomic anomalies in the ductal system.[1] Ductal obstructions might result from iodine radiation, autoimmunity, allergies, metabolism, or idiopathic causes.[2] Approximately 10% to 20% of patients with COS are refractory to treatments, such as interventional endoscopy, daily conservative massage, and regular saline or steroid infusion.[3] Although the definite local obstructive causes remain unclear, patients have obvious symptoms of ductal obstruction, accompanied by allergy and increased serum IgE, which indicates that allergy might play an important role in the pathogenesis and development of this disease.

In 1879, Kussmaul reported a disease characterized by recurrent parotid gland (PG) swelling and mucus plugs containing leukocytes and Charcot–Leyden crystals.[4] Since then, a similar recurrent major salivary gland swelling condition (Kussmaul disease) with mucus plugs and/or allergies has been termed allergic parotitis,[5] sialodochitis fibrinosa,[6,7] or eosinophilic sialodochitis (ES).[4] Most reports indicate allergy as an etiology of ES and emphasize eosinophilia in both mucus plugs and peripheral blood, as well as elevated serum IgE. Histopathological studies show eosinophilic infiltration around the large salivary gland ducts.[4,8–10] Treatment for ES includes the abovementioned conventional options as well as anti-anaphylactic treatment.[4,7]

To date, reports on ES with large sample sizes are lacking, and the clinicopathological characteristics of ES are unclear. The purpose of the present study was to comparatively analyze the clinical, laboratory, histopathological, and immunohistochemical features, as well as the expression of allergy-related cytokines between ES and conventional COS on the basis of a relatively large case series, and to clarify the clinicopathological characteristics of ES and the possible role of allergy in the pathogenesis of ES.

From the Department of Oral and Maxillofacial Surgery (W.-X.Z., G.-Y.Y.), Peking University School and Hospital of Stomatology, National Engineering Laboratory for Digital and Material Technology of Stomatology, Beijing Key Laboratory of Digital Stomatology, Beijing, China; Department of Oral Radiology (D.-G.L.), Peking University School and Hospital of Stomatology, National Engineering Laboratory for Digital and Material Technology of Stomatology, Beijing Key Laboratory of Digital Stomatology, Beijing, China; and the Department of Oral Pathology (Y.C.), Peking University School and Hospital of Stomatology, National Engineering Laboratory for Digital and Material Technology of Stomatology, Beijing Key Laboratory of Digital Stomatology, Beijing, China.

Editor's Note: This Manuscript was accepted for publication on May 10, 2020.

This work was supported by the National Natural Science Foundation of China (No. 81671005, 81974151).

The authors have no other funding, financial relationships, or conflicts of interest to disclose.

Send correspondence to Guang-Yan Yu, Department of Oral and Maxillofacial Surgery, Peking University School of Stomatology, 22 Zhongguancun South Street, Beijing 100081, China. E-mail: gyyu@263.net. Deng-Gao Liu, Department of Oral Radiology, Peking University School of Stomatology, 22 Zhongguancun South Street, Beijing, 100081, China. E-mail: kqldg@bjmu.edu.cn

DOI: 10.1002/lary.28772

MATERIALS AND METHODS

The study protocol was approved by the Ethics Committee for Human Experiments of the Peking University School of Stomatology (PKUSSIRB-201947099). Informed consent was obtained from all patients.

Patient Selection and Study Design

Clinical and histopathological records from 60 patients diagnosed with COS who had undergone glandular excision or incisional biopsy from January 1999 through January 2019 were retrospectively acquired from a computer-assisted searching system at Peking University School of Stomatology. Twenty-two patients who underwent surgery to treat sialolithiasis or severe gland trauma were excluded. A total of 38 patients formed the basis of the current study. Tissue samples were acquired by glandular excision in seven cases and from incisional biopsy in 10 cases in the ES group, and acquired by glandular excision in all 21 cases of the COS group. Twenty-eight of the samples were from PGs and 10 of the samples were from submandibular glands (SMGs). The clinical, laboratory, radiological, and histopathological data of patients was reviewed and analyzed. Patients were divided into two groups according to the following ES criteria: 1) the patients had comorbid atopic disease; and 2) histopathology showed obvious eosinophil infiltration around the ducts (≥15/high power field [HPF]).[11] These criteria were fulfilled in 15 cases. Two patients had atopic disease and elevation of peripheral blood eosinophil (PBE) and serum IgE, but their tissue eosinophil count was 2/HPF. They were preliminarily defined as having ES on the basis that they were undergoing glucocorticoid therapy, which may decrease eosinophil infiltration. A total of 17 patients were included in the ES group. The remaining 21 patients did not satisfy these criteria and were defined as the conventional COS group. An elevated PBE count was defined as $>0.5 \times 10^9$ cells/L or >5% of leukocytes. An elevated serum total IgE was defined as >100 kU/L.

Histopathological Examinations

The hematoxylin- and eosin-stained slides from all patients were reviewed and the following histopathological features were recorded: A) atrophy of the gland: 0, no atrophy; 1, occasional atrophic foci; 2, extensive moderate parenchyma atrophy; and 3, extensive serious parenchyma atrophy; B) fibrosis of the gland: 0, a small amount of fibrosis; 1, partial mild fibrosis; 2, extensive moderate fibrosis; and 3, extensive serious fibrosis; and C) infiltration of inflammatory cells: 0, scattered inflammatory cells as seen in normal glands; 1, occasional focal distribution of inflammatory cells; 2, extensive moderate infiltration of inflammatory cells; and 3, extensive serious infiltration of inflammatory cells.[12]

The following histopathological features were recorded as present or absent: fibrin clots with eosinophils, follicular hyperplasia, squamous metaplasia, and goblet cell metaplasia of the ducts.[13] The slides were reviewed when there were differences in the records between the two observers and discussion was occasionally necessary to reach a consensus. Three HPFs with the greatest eosinophil density were selected and quantified (HPF area = 0.2375 mm^2). The proportion of mucous cells in ductal epithelium was determined using the diastase periodic acid-Schiff (D-PAS) stain, and three HPFs with the most serious mucous metaplasia were selected to calculate the ratio of mucous cells to total ductal epithelial cells per HPF.

Immunohistochemical Examinations

Tissue sections (4-μm thickness) were deparaffinized and rehydrated. Endogenous peroxidase activity was blocked using 3% H_2O_2. Antibodies against human IgG4 (prediluted ZA0576, Zhongshan, Beijing, China), IgG (prediluted ZA0448, Zhongshan), IgE (prediluted ab75673, Abcam, Cambridge, UK), mast cell tryptase (diluted 1:1000, ab2378, Abcam), cluster of differentiation 21 (CD21; prediluted ZA0525, Zhongshan), IL-13 (diluted 1:200, ab106732, Abcam), eotaxin (diluted 1:150, ab133604, Abcam), IL-4 (diluted 1:200, ab239508, Abcam), and IL-5 (26677-1-AP, Proteintech, Wuhan, China) were used. Antigen retrieval was achieved by treating sections with boiling citric acid buffer solution (0.01 mol/L, pH 6.0) for 10 minutes in a microwave oven. Negative controls were obtained using normal SMG tissue. Three identical HPFs with the greatest IgE-, tryptase-, IgG-, IgG4-, IL-4-, IL-5-, eotaxin-, and IL-13-positive cell density were selected and quantified using Image-Pro Plus 6.0 (Media Cybernetics, Rockville, MD, USA).

Statistical Analyses

Statistical analyses were performed using SPSS 20.0 (SPSS, Chicago, IL, USA). The mean ± standard deviation or median (Q1–Q3) was used for continuous variables, and compared using an independent *t*-test or Wilcoxon rank test. Categorical variables were expressed as percentages and compared using the chi-squared or Fisher's exact test. The sensitivities, specificities, and receiver operating characteristic (ROC) curves of IgE-positive cells and tryptase-positive cells were statistically analyzed. $P < .05$ was considered statistically significant.

RESULTS

Clinical Features

The male–female ratio in the ES group was 9:8, and no gender differences were observed between the two groups. The median onset age was 33 years in the ES group (range, 16–60 years), which was lower than the median age of 45 years in the COS group, although this difference was non-significant ($P = .251$). In the ES group, the PG was involved in six patients, the SMG was involved in two patients, and both the PG and SMG were involved in the remaining nine patients. The average number of affected glands was 2.8 ± 1.1 in ES, which was significantly greater compared with the COS group (1.2 ± 0.4; $P < .001$; Table I).

TABLE I.
The Clinical and Laboratory Features of ES and COS.

	ES	COS	*P*
Clinical features			
Male:female	9:8	9:12	.745
Onset age (yr), m (Q1–Q3)	33(27–54)	45(29–59)	.251
Duration (mo), m (Q1–Q3)	36(15–120)	48(24–102)	.518
Affected glands			
Number of affected glands	2.8 ± 1.1	1.2 ± 0.4	<.001
Bilateral glands, n (%)	15(88)	4(19)	<.001
Multiple gland enlargement, n (%)	16(94)	4(19)	<.001
Laboratory examinations			
Raised PBE, n (%)	10/17(58.8)	1/11(9)	
Raised serum T-IgE, n (%)	10/11(91)	-	
PBE (%)	7.6 ± 4.6	2.5 ± 1.4	<.001
T-IgE (kU/L)	419 ± 357	-	

COS = chronic obstructive sialadenitis; ES = eosinophilic sialodochitis; Ig = immunoglobulin; PBE = peripheral blood eosinophil; T-IgE = total-IgE.

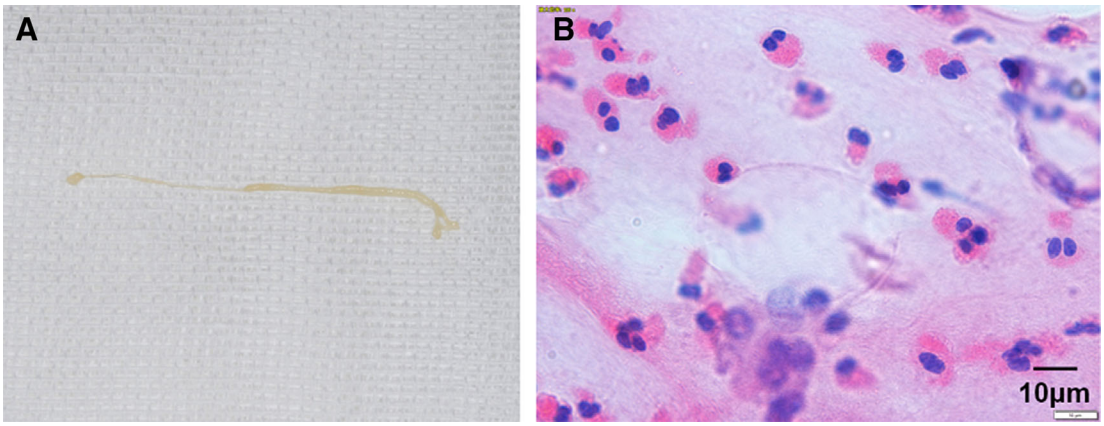

Fig. 1. Mucus plug smear examination. **(A)** Strip-like gelatinous plugs. (**B**) Abundant eosinophils in the mucus plug smear by hematoxylin–eosin staining. [Color figure can be viewed in the online issue, which is available at www.laryngoscope.com.]

Furthermore, bilateral involvement of the major salivary glands was more prevalent in the ES group (88% vs. 19%; $P < .001$). The median symptomatic duration was 36 months and 48 months in the ES group and COS group, respectively ($P = .518$). In ES patients, strip-like gelatinous plugs were frequently discharged from the duct orifice of the gland (Fig. 1A). Moreover, comorbid allergic diseases including allergic rhinitis or asthma (88%), atopic dermatitis or urticaria (41%), and drug or food allergies (29%), were more frequently observed in patients in the ES group (Table I).

Laboratory Findings

In the ES group, elevated total IgE and peripheral blood eosinophilia were evident in 91% and 58.8% of patients, respectively. Furthermore, the percentage of eosinophil counts in peripheral blood was greater in the ES group compared with the COS group (7.6% ± 4.6% vs. 2.5% ± 1.4%; $P < .001$; Table I). Serum IgG4 was elevated in one patient with ES. One patient with ES underwent a mucus plug smear, which showed abundant eosinophils (Fig. 1B).

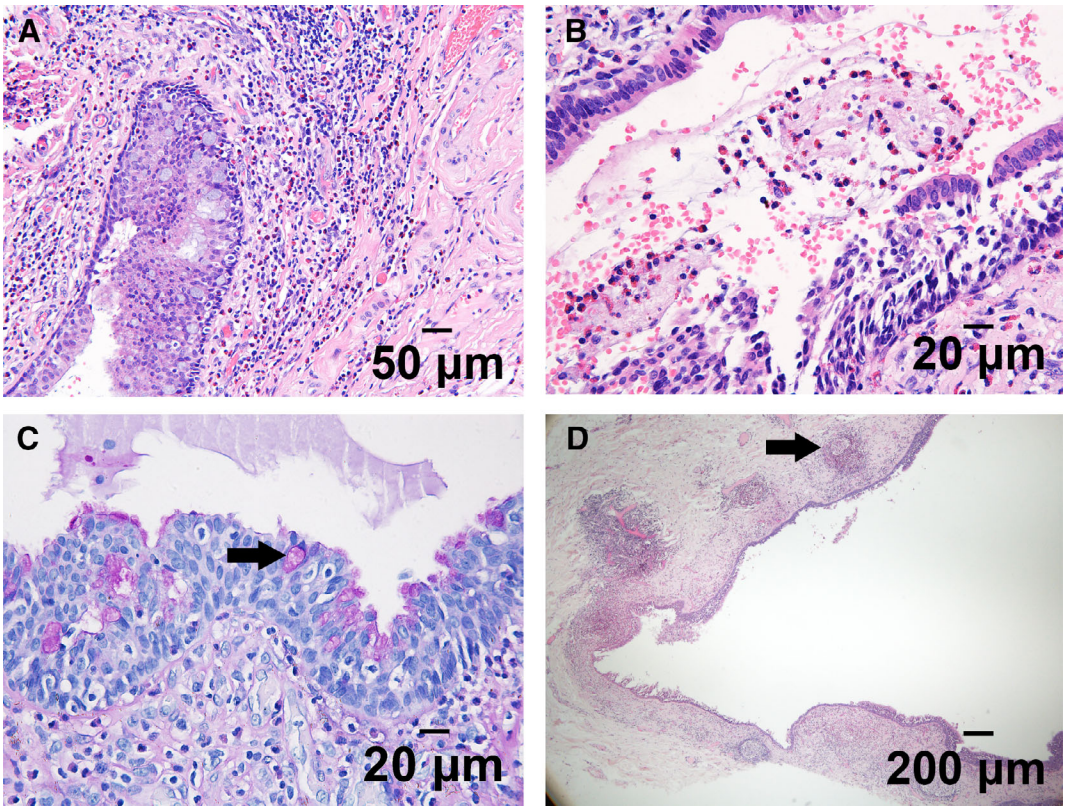

Fig. 2. Histological features of ES. (**A**) Dense eosinophil infiltration around the duct. (**B**) Intraductal mucus plug with eosinophils and fibrin clots. (**C**) Mucous metaplasia of the duct by D-PAS (arrow). (**D**) Follicular hyperplasia around the ducts (arrow). D-PAS = diastase periodic acid-Schiff; ES = eosinophilic sialodochitis. [Color figure can be viewed in the online issue, which is available at www.laryngoscope.com.]

TABLE II.
The Histopathological and Immunochemical Features of ES and COS.

	ES	COS	*P*
Histopathological features			
Eosinophils, cells/HPF (range)	57 ± 39 (2–109)	3 ± 3 (0–13)	<.001
The ratio of goblet cell (%)	32 ± 21	12 ± 17	.003
Grade of acinar atrophy			<.001
0 and 1, n (%)	17 (100)	9 (42.9)	
2 and 3, n (%)	0	12 (57.1)	
Grade of fibrosis			.024
0 and 1, n (%)	17 (100)	15 (71.4)	
2 and 3, n (%)	0	6 (28.6)	
Grade of lymphocyte cells			1
0 and 1, n (%)	7 (41.1)	8 (38.1)	
2 and 3, n (%)	10 (58.5)	13 (61.9)	
Follicular hyperplasia, n (%)	12 (76.4)	3 (14.3)	.001
Intraductal fibrin clots, n (%)	15 (88.2)	12 (57.1)	.07
With eosinophils, n (%)	7 (41.1)	0	.002
Without eosinophils, n (%)	8 (47.1)	12 (57.1)	
Hyperplasia of ductal epithelium, n (%)	16 (94.1)	11 (52.4)	
Mucous metaplasia, n (%)	15 (88.2)	8 (38.1)	.002
Squamous metaplasia, n (%)	7 (41.2)	7 (33.3)	.74
Intraluminal epithelial cell shedding, n (%)	9 (52.9)	7 (33.3)	.324
Immunochemical features			
IgE+, cells/HPF (range)	20.7 ± 18.3 (3–66)	1.7 ± 2.9 (0–10)	.001
IgE+ reticular networks in GCs, n (%)	9 (52.9)	0	.001
IgG4+, cells/HPF	19.7 ± 19.6	3 ± 5.7	.003
Tryptase-positive cells, cells/HPF(range)	23.5 ± 15.1 (9–55)	10.1 ± 4.4 (4–18)	.002
CD21+, n (%)	12 (76.4)	3 (20)	.016
IL-4+ (cells/HPF)	12.5 ± 8.8	4.3 ± 2.4	.001
IL-5+ (cells/HPF)	13.6 ± 20.9	3.2 ± 3.3	.067
IL-13+ (cells/HPF)	2.8 ± 3.5	0.3 ± 0.9	.014
Eotaxin+ (cells/HPF)	11 ± 23	0	.068

CD21 = cluster of differentiation 21; COS = chronic obstructive sialadenitis; ES = eosinophilic sialodochitis; GC = germinal center; HPF = high power field; Ig = immunoglobulin; IL = interleukin.

Imaging Characteristics

In the ES group, 11 patients underwent computed tomography (CT), which showed diffuse enlargement of the involved glands with heterogeneous density and ductal dilation. Sialography was performed in 16 ES patients, which exhibited various degrees of dilatation and stenosis in the main and intraglandular ducts with a "sausage" appearance. The radiological features of patients with ES were not significantly different compared with patients in the COS group.

Histopathological Examination

One of the prominent histopathological features of ES was eosinophil infiltration. There was dense eosinophil infiltration around the dilated main and interlobular ducts, which was rarely observed in the acini or around the small ducts (Fig. 2A). The average eosinophil count was 50 ± 39/HPF (range, 2–109/HPF), which was significantly greater compared with the COS group (3.6 ± 5/HPF; range, 0–13/HPF; $P < .001$). Specifically, the eosinophil count was >17/HPF in 15 ES patients without records of glucocorticoid therapy, and 2/HPF in the remaining two patients with ES who did receive glucocorticoid therapy before surgery.

Another histopathological feature of ES was mucous metaplasia. Mucous metaplasia occurred mainly in the main and interlobular duct, and was rarely seen in small-sized ducts. Ductal mucous metaplasia was observed in 15 patients with ES (Fig. 2C), and the average ratio of mucous cells to ductal epithelial cells was 32% ± 21%, which was significantly greater compared with the COS group ($P = .003$). Intraductal mucus plugs with abundant eosinophils and fibrin clots were observed in seven patients with ES (44%; Fig. 2B). Lymphocyte infiltration was mostly observed around the large- and medium-sized ducts in both groups. Although significant differences were not observed in the degree of inflammatory cell infiltration between the two groups ($P = 1$), follicular hyperplasia around the ducts was observed in 12 out of

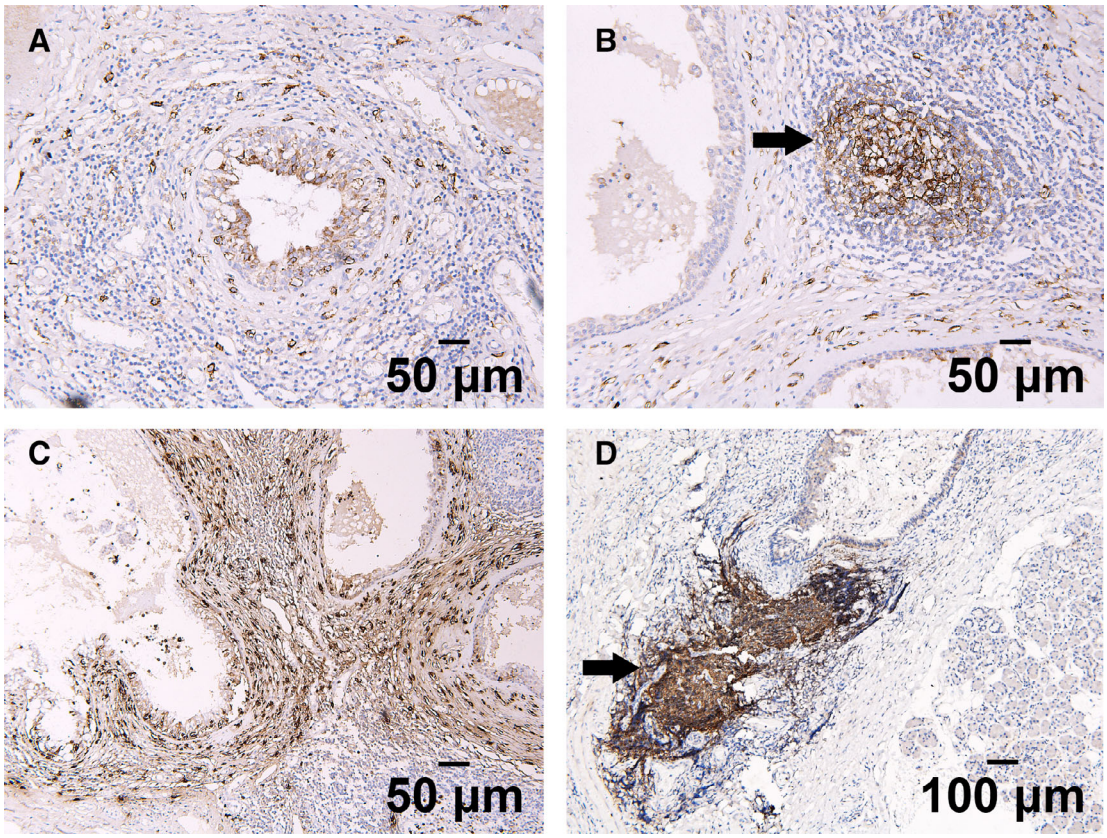

Fig. 3. Immunohistochemical features of ES. **(A)** IgE-positive cells infiltrated around the ducts with surface membrane staining. **(B)** IgE-positive reticular networks in the germinal center (arrow). **(C)** Tryptase-positive mast cell infiltration around the large ducts. **(D)** CD21 positive cell in lymphoid follicle (arrow). CD21 = cluster of differentiation 21; ES = eosinophilic sialodochitis; IgE = immunoglobulin E. [Color figure can be viewed in the online issue, which is available at www.laryngoscope.com.]

17 patients with ES, and was more prevalent than the COS group (P = .001; Fig. 2D). Squamous metaplasia of the ductal epithelium was observed in both groups. The scores for acinar atrophy and fibrosis were significantly smaller in the ES group compared with COS group (P < .001 and P = .024, respectively; Table II).

Immunohistochemical Features and Expression of Allergy-Related Cytokines

High expression of IgE was an obvious immunohistochemical feature in patients in the ES group. The number of IgE-positive cells ranged from three to 66/HPF (mean, 20.7 ± 18.3/HPF) in ES group, which was much greater than that in the COS group (range, 0–10; mean, 1.7 ± 2.9/HPF; P < .001). In the two patients with low levels of tissue eosinophil, the IgE-positive cell counts were as high as 14/HPF and 15/HPF, respectively, which verified the diagnosis of ES in the initial stage of the study. IgE-positive cells were mainly located around the ducts with surface membrane staining (Fig. 3A). Significant tryptase-positive mast cell infiltration could be seen around the large ducts in both groups. The tryptase-positive mast cell counts in ES group ranged from nine to 55/HPF (mean, 23.5 ± 15.1/HPF; Fig. 3C), while this value was much lower in the COS group (range, 4–18/HPF; mean, 10.1 ± 4.4/HPF; P < .001). CD21 staining was positive in 12 ES patients (76.4%) (Fig. 3D). IL-4-, IL-13-, and eotaxin-positive cells were seen around the large ducts, and the numbers were significantly greater in the ES group (Figs 4A–C) compared with the COS group. The number of IL-5-positive cells was also slightly increased (Fig. 4D). IL-4 and IL-5 were strongly expressed around the large duct with mucous metaplasia in the ES group. The expression of these cytokines varied in different cases and in different glandular locations. However, in the COS group, the expression of IL-13 and eotaxin was negative in 86.7% and 100% of cases, respectively. In the ES group, IgG4 and IgG-positive cells were focally distributed in the periductal area with more severe lymphocyte infiltration, and the number of IgG4-positive cells was >50/HPF with a ratio of IgG4+ to IgG+ of >40% in two patients (Table II). However, the histological characteristics of IgG4-related sialadenitis, such as storiform fibrosis, irregular lymphoid follicles with expanded germinal centers, and obliterative phlebitis could not be seen in these two cases.

ROC curve analysis revealed that IgE-positive cell counts had a good area under the curve of 0.929, and an IgE-positive cell count of >12/HPF had a sensitivity of 64.7% and a specificity of 100%. When tryptase-positive mast cell counts were > 16/HPF, a sensitivity of 70.6% and a specificity of 86.7% for the diagnosis of ES were achieved.

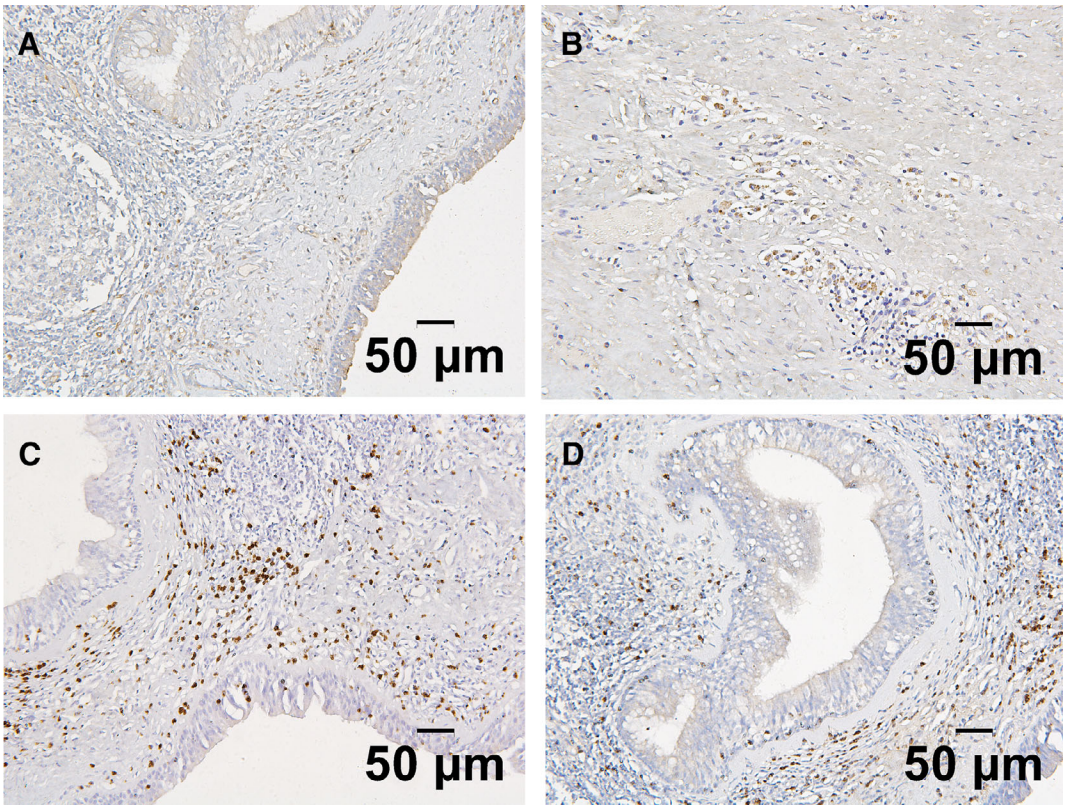

Fig. 4. Immunohistochemical expression of allergy-related cytokines in ES. (**A**) Significant infiltration of IL-4-positive cells around the duct. (**B**) Scattered infiltration of IL-13-positive cells. (**C**) Infiltration of eotaxin-positive cells around the duct. (**D**) Strong expression of IL-5 in the cells around the large duct. ES = eosinophilic sialodochitis; IL = interleukin. [Color figure can be viewed in the online issue, which is available at www.laryngoscope.com.]

DISCUSSION

ES is a new type of chronic inflammatory disease of the salivary gland. As far as we know, few studies have systematically elucidated the clinicopathological features of ES. In the present study, we analyzed clinicopathological data from 17 patients with recurrent swelling of the salivary gland, elevation of IgE, and obvious eosinophil infiltration in the tissue, and compared these results with conventional COS. This was so far the largest sample size used to study ES.[4]

The results showed obvious clinical features of ES. The age at onset in ES patients was lower compared with the age at onset in COS patients, which may be related to the increased incidence of allergic diseases caused by environmental pollution and chemical substance exposure in recent years.[14–16] ES frequently involves multiple and bilateral salivary glands, which is consistent with the results of Baer et al.[4] The proportion of cases with elevated serum IgE was 91%, which was greater than the figure of 72% reported in the literature.[4,7] The clinical features including comorbid atopy, involvement of multiple glands, and increased IgE and PBE indicate that the pathogenesis of the disease is related to allergy, but the underlying mechanisms need further study.

In patients with ES included in this study, sialography and CT images showed irregular dilation and stenosis of the main and intraglandular branch ducts. These radiographic features had also been revealed by magnetic resonance examinations.[4,7,8] This indicated that the morphological changes in the ducts in ES patients were similar to those observed in COS patients, irrespective of their different etiologies and pathological mechanisms.

Histopathologically, the ES lesion was mainly located in the ductal system and was characterized by marked eosinophil infiltration around the large- and medium-sized duct with a lymphocyte background and mucous metaplasia of the ductal epithelium. Furthermore, epithelial cell shedding, eosinophils, and inspissated mucin were frequently observed in the ductal lumen. These findings were consistent with previous reports.[4,8] Compared with conventional COS, eosinophil infiltration, hyperplasia of the lymphoid follicles around the duct, and mucous metaplasia of the ductal epithelium were more severe, while atrophy and fibrosis were milder in ES patients. It is worth noting that ductal epithelial mucous metaplasia might be the pathological basis for thick discharge and eosinophil-rich mucus plugs, which were the main cause of obstructive symptoms.

The clinicopathological features of ES were akin to those of asthma and eosinophilic esophagitis (EoE). First, the symptoms of regional organs were characterized by luminal stenosis comorbid with allergy, which manifested as salivary duct stenosis in ES, airway narrowing in asthma,[17] and esophageal stricture in EoE.[11,18] Second, the lesion mainly involved the ductal system and spared the parenchyma,

characterized histologically by eosinophil-predominant inflammation.[4,11,19] Pathophysiological studies on asthma and EoE show that a defective epithelial barrier in the respiratory and gastrointestinal tracts, promotes invasion of antigens in the epithelium and triggers an allergic reaction.[7,17,19,20] It might suppose that desquamation of ductal epithelial cells in ES impairs the integrity of the epithelial barrier, allowing antigens to penetrate the ductal epithelium and induce a primary immune reaction in the salivary gland. These common clinicopathological features suggest that research into asthma and EoE might be a useful reference for research into ES in the future.

Antigen-specific IgE and mast cells with FceRI receptors are required for initiation and propagation of immediate hypersensitivity reactions,[21] and tissue mast cells and eosinophils coexist in the late and chronic phases of hypersensitivity reactions.[22] Baer et al. found no increase in mast cells (c-kit+) by immunohistochemical staining,[4] while we found dense tryptase-positive mast cells and IgE-positive cells around the duct in ES lesions, which might be attributed to more severe inflammation and fibrosis of the periductal area and primarily subepithelial infiltration of mast cells.[21] Obvious infiltration of IgE-positive cells, mast cells, and eosinophils further indicates that allergic inflammation is essential to the pathogenesis of ES.

In the present study, obvious infiltration of IL-4, IL-13, and eotaxin-positive cells could be observed in ES tissues, and IL-5 was also expressed around the large duct with mucous metaplasia, which are key cytokines in atopic diseases.[21,23] IL-13 acts directly on the epithelium to induce hyperplasia of goblet cells.[23–26] IL-5 and IL-13 are also related to loss of barrier integrity in epithelial cells by reducing the expression of desmoglein-1.[20] It might be speculated that high expression of IL-13 and IL-5 might promote ductal goblet metaplasia in the salivary glands, increase secretion of mucinous protein, and disrupt the barrier function of the ductal epithelium. IL-4/IL-13 pathway inhibitors demonstrate gratifying efficacy in the treatment of EoE and asthma.[18,23] Whether they are suitable as a therapy for ES is worthy of further investigation.

It is suitable to separate ES from COS because of the distinct histopathological features of these two conditions. Briefly, elevated serum IgE is one of the prominent characteristics of ES and infiltration of IgE-positive cells is evident around the duct. Using the designation of IgG4-related sialadenitis for reference,[27,28] ES might also be named as IgE-related sialodochitis. The definite diagnostic criteria are still obscure at present.[4] Here, we suggest the follow diagnostic criteria for ES: 1) recurrent swelling of multiple major salivary glands for more than 3 months; 2) comorbid with atopic disease; 3) elevated serum IgE and PBE; 4) significant eosinophil infiltration around the duct (≥15/HPF); and 5) marked infiltration of IgE+ cells (≥12/HPF) in the tissues.

The present study has certain limitations. Due to the retrospective nature of the study, some clinical data were not sufficient; thus, prospective studies using a larger sample size are needed to validate the results.

CONCLUSIONS

ES is a special type of COS. Its clinical, laboratory, histological, and immunohistochemical characteristics are significantly different from COS. Significant expression of allergy-related cytokines suggests that the pathogenesis of ES is related to allergy.

BIBLIOGRAPHY

1. Lee LI, Pawar RR, Whitley S, Makdissi J. Incidence of different causes of benign obstruction of the salivary glands: retrospective analysis of 493 cases using fluoroscopy and digital subtraction sialography. *Br J Oral Maxillofac Surg* 2015;53:54–57.
2. Vashishta R, Gillespie MB. Salivary endoscopy for idiopathic chronic sialadenitis. *Laryngoscope* 2013;123:3016–3020.
3. Delagnes EA, Aubin-Pouliot A, Zheng M, Chang JL, Ryan WR. Sialadenitis without sialolithiasis: prospective outcomes after sialendoscopy-assisted salivary duct surgery. *Laryngoscope* 2017;127:1073–1079.
4. Baer AN, Okuhama A, Eisele DW, Tversky JR, Gniadek TJ. Eosinophilic sialodochitis: redefinition of 'allergic parotitis' and 'sialodochitis fibrinosa'. *Oral Dis* 2017;23:840–848.
5. Bookman R. Allergic parotitis. *Calif Med* 1950;72:179–180.
6. Ammar-Khodja A. Kussmaul's fibrinous sialodochitis: apropos of an unusual case. *Rev Laryngol Otol Rhinol (Bord)* 1971;92:847–848.
7. Chikamatsu K, Shino M, Fukuda Y, Sakakura K, Furuya N. Recurring bilateral parotid gland swelling: two cases of sialodochitis fibrinosa. *J Laryngol Otol* 2006;120:330–333.
8. Flores RBJ, Brea AB, Sanabria SAA, et al. Sialodochitis fibrinosa (Kussmaul disease): report of 3 cases and literature review. *Medicine (Baltimore)* 2016;95:e5132.
9. Harkness P. Submandibular salivary disease: a proposed allergic etiology. *J Laryngol Otol* 1995;109:66–67.
10. Ray A, Burgin SJ, Spector ME. A rare case of Kussmaul disease (sialodochitis fibrinosa). *J Case Rep Med* 2015;4:235894.
11. Dellon ES, Gonsalves N, Hirano I, Furuta GT, Liacouras CA, Katzka DA. ACG clinical guideline: evidenced based approach to the diagnosis and management of esophageal eosinophilia and eosinophilic esophagitis (EoE). *Am J Gastroenterol* 2013;108:679–692; Quiz 93.
12. Epivatianos A, Zaraboukas T, Poulopoulos A, Harrison JD. Immunohistochemical study of fibroblasts and mast cells in chronic submandibular sialadenitis. *Oral Dis* 2008;14:259–263.
13. Harrison JD, Epivatianos A, Bhatia SN. Role of microliths in the aetiology of chronic submandibular sialadenitis: a clinicopathological investigation of 154 cases. *Histopathology* 1997;31:237–251.
14. Loftus PA, Wise SK. Epidemiology of asthma. *Curr Opin Otolaryngol Head Neck Surg* 2016;24:245–249.
15. Wang XD, Zheng M, Lou HF, et al. An increased prevalence of self-reported allergic rhinitis in major Chinese cities from 2005 to 2011. *Allergy* 2016; 71:1170–1180.
16. Lieberman JA, Greenhawt M, Nowak-Wegrzyn A. The environment and food allergy. *Ann Allergy Asthma Immunol* 2018;120:455–457.
17. Kudo M, Ishigatsubo Y, Aoki I. Pathology of asthma. *Front Microbiol* 2013; 4:263.
18. Capucilli P, Hill DA. Allergic comorbidity in eosinophilic esophagitis: mechanistic relevance and clinical implications. *Clin Rev Allergy Immunol* 2019;57:111–127.
19. McBrien CN, Menzies-Gow A. The biology of eosinophils and their role in asthma. *Front Med (Lausanne)* 2017;4:93.
20. Sato H, Nakajima N, Takahashi K, et al. Proposed criteria to differentiate heterogeneous eosinophilic gastrointestinal disorders of the esophagus, including eosinophilic esophageal myositis. *World J Gastroenterol* 2017; 23:2414–2423.
21. Stone KD, Prussin C, Metcalfe DD. IgE, mast cells, basophils, and eosinophils. *J Allergy Clin Immunol* 2010;125:S73–S80.
22. Gri G, Frossi B, D'Inca F, et al. Mast cell: an emerging partner in immune interaction. *Front Immunol* 2012;3:120.
23. Gandhi NA, Pirozzi G, Graham NMH. Commonality of the IL-4/IL-13 pathway in atopic diseases. *Expert Rev Clin Immunol* 2017;13:425–437.
24. Birchenough GM, Johansson ME, Gustafsson JK, Bergstrom JH, Hansson GC. New developments in goblet cell mucus secretion and function. *Mucosal Immunol* 2015;8:712–719.
25. Burgel PR, Lazarus SC, Tam DC, et al. Human eosinophils induce mucin production in airway epithelial cells via epidermal growth factor receptor activation. *J Immunol* 2001;167:5948–5954.
26. Rosenberg HF, Phipps S, Foster PS. Eosinophil trafficking in allergy and asthma. *J Allergy Clin Immunol* 2007;119:1303–1310.
27. Li W, Chen Y, Sun ZP, et al. Clinicopathological characteristics of immunoglobulin G4-related sialadenitis. *Arthritis Res Ther* 2015;17:186.
28. Kamisawa T, Zen Y, Pillai S, Stone JH. IgG4-related disease. *Lancet* 2015; 385:1460–1471.