CASE REPORT
Iran J Allergy Asthma Immunol
December 2011; 8(4): 299-303

Recurrent Infections and Cows-milk Hypersensitivity in a 2-Year-Old Girl with Hyper Immunoglobulin E Syndrome

Sonja Prcic[1], Jelena Tomić[2], Slobodanka Petrović[3], Anica Radulović [1], Verica Djuran[4], and Zorica Gajinov[4]

[1] Department of Dermatovenereology, Institute for Child and Youth Health Care of Vojvodina, Novi Sad, Serbia
[2] Department of Immunology and Allergology, Institute For Child and Youth Health Care of Vojvodina, Novi Sad, Serbia
[3] Department of Pulmology, Institute for Child and Youth Health Care of Vojvodina, Novi Sad, Serbia
[4] Clinic of Dermatovenereologic Diseases, Clinical Centre of Vojvodina, Novi Sad, Serbia

Received: 5 December 2010 ; Received in revised form: 16 May 2011 ; Accepted: 9 July 2011

ABSTRACT

The hyperimmunoglobulin E syndrome is a rare complex primary immunodeficiency characterized by high serum IgE levels, eczema, and recurrent infections. We present a case of 2-years-old girl with eczema and repeated bacterial skin and lung infections since the period of infancy.

The patient also had eosinophilia, high serum levels of IgE, and cows-milk hypersensitivity. We describe the case, in order to illustrate the difficulty of establishing the diagnosis hyper-immunoglobulin E syndrome in a toddler.

Keywords: Child; Food-allergy; Hyper-IgE syndrome; Infections

INTRODUCTION

The hyperimmunoglobulin E syndrome (HIES) is a rare complex primary immunodeficiency, characterized by recurrent skin, and lung infections associated with extremely high serum IgE level.[1] Two types of inheritance exist: dominant autosomal (AD-HIES) and recessive autosomal (AR-HIES).[1,2] The association between HIES and food allergy is rare, although both of them can result in the early onset of skin rash, eosinophilia, and marked elevation of serum IgE.[3]

Corresponding Author: Sonja Prcic, MD, PhD;
Department Of Dermatovenereology Institute For Child And Youth Health Care Of Vojvodina, Hajduk Veljkova 10, Novi Sad, Serbia. Tel: (+38 121) 4880 444, Fax: (+38 121) 520 436,
E-mail:buki97@eunet.rs

To the best of our knowledge, this is the first case of hyper-IgE syndrome with cows-milk hypersensitivity reported in the Republic of Serbia.

CASE REPORT

Two years old girl has been treated in the Institute of Children and Youth Health Care of Vojvodina, in Novi Sad, on several occasions, due to recurrent bacterial infections. The first hospital admission was when she was only 35 days old, because of pustular and eczematous rash on the face and scalp, and oral candidiasis. When she was 8 months old, prick skin test with cow's milk was positive, and specific IgE levels for cow's milk were high.

Copyright© 2010, IRANIAN JOURNAL OF ALLERGY, ASTHMA AND IMMUNOLOGY. All rights reserved.

Figure 1.

The rash partially improved when patient fed with an extensively hydrolyzed milk formula. Diagnosis of atopic dermatitis was reached. The moderate-to-severe eczema was present to some degree, during whole year. At the age of 9 months necrectomy was performed because of redness, swelling and necrotic changes at the BCG inoculation site. Also, patient suffered recurrent episodes of otitis. At the age of 13 months, patient came to Institute due to cough, impaired breathing and fever. Chest X-ray and computed tomography (CT) revealed left-sided destructive pneumonia with empyema on the left lung (Figure 1). Purulent exudate was evacuated by thoracic drainage, and Staphylococcus aureus was isolated in pure bacteriological culture. Pneumonia resolved after 6 weeks of treatment with different antibiotics combination, according to antibiotic sensitivity testing. Four months after the initial pulmonary infection, control chest CT revealed pneumatocoela in the lower lobe of the left lung (Figure 2).

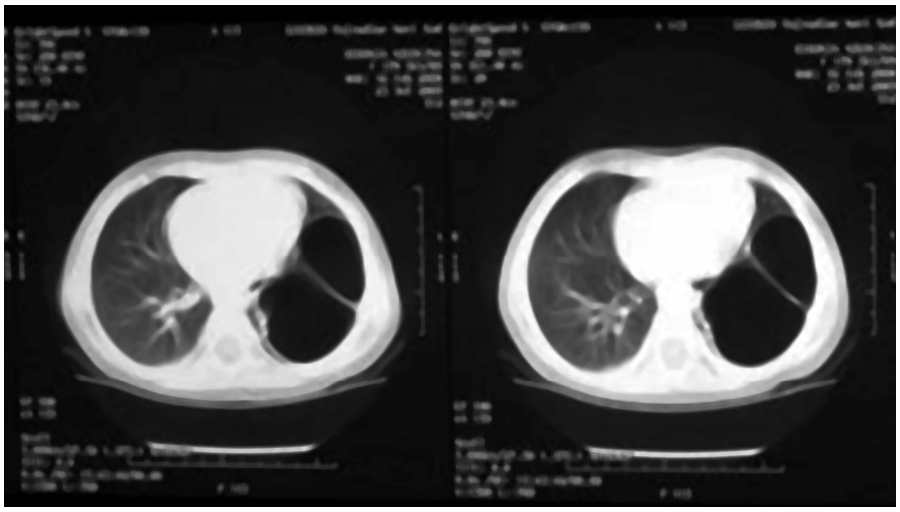

Figure 2.

Figure 3.

At two years old once again was admitted to the Institute with severe skin infection on the head and trunk. Numerous papules and pustules on the erythematous skin of the head and trunk were present, together with formed abscess and furuncle (Figure 3). One centimeter long linear scar was visible on left shoulder (BCG vaccine inoculation site). Numerous minor malformations were present: epicanthus, hypertelorism, broad nasal bridge, fleshy tip of the nose, and increased inter-alary distance. Joints were hyper-extensible. Family history did not reveal any significant data. White blood cells count was 13,4 G/l with eosinophilia (absolute count 1608 /mm3) and increased IgE (1551 IU/ml) plasma level, while the concentration of IgA, IgM and IgG, C_3,C_4 were within normal ranges. C-reactive protein level (48 mg/ml) and erythrocyte sedimentation rate (32 mm/h) were also elevated**.** Nitroblue tetrazolium (NBT) test (21%) and phagocytosis test were normal, but inflammatory response in vivo (Rebuck skin window test) and in vitro was absent (delayed response to purified protein derivate-PPD). Flow cytometry of the peripheral blood lymphocytes subpopulations was normal: CD3, 63.6% (limits of normal, 50%-77%); CD4, 38.7% (normal, 33%-58%); CD8, 16.6% (normal, 13%-26%). The CD4/CD8 ratio was 2.33 (normal, 1.6-3.8); B (CD19) 31.5% (normal 13-55%); NK (CD16+CD56) 7.1% (normal 2-13%). Antineutrophil antibody screen were negative. All other biochemical investigations were within normal limits. Tuberculin skin test result was negative. Her caryotype was normal. Candida species were isolated from the stool culture. Stool analysis was negative for parasite infection (Oxiuris vermicularis, Ascaris lumbricoides and cysts of intestinal protozoa), and Trichinella serology was negative also. Pneumoatocela persisted in left lung on control chest radiograph and CT. Craniogram showed normal bone structure with poorly modulated frontal region of the skull. During hospitalization, skin abscess was treated surgically, and Staphylococcus aureus isolated. The patient received parenteral antibiotic therapy (ceftazidim, amikacin) with oral antifungal drug (nystatin). Eczematous dermatitis was treated with a topical corticosteroid, a moisturizing cream and desloratadine, to decrease pruritus. Three month after hospitalization, on the last check up, she was infection-free, receiving prophylaxis with trimethoprim-sulfamethoxazole, and nystatin as well.

DISCUSSION

HIES is a primary, rare and complex immunodeficiency in which severe bacterial infections, as well as skin changes (pustulous dermatitis) may develop very early, sometimes even in the neonatal period, just like in our patient. A newborn rash is usually the first manifestation of STAT3 deficiency and can be quite significant, especially in childhood.[4] Among the most frequent infections in patients with HIES is staphylococcal pneumonia; sometimes it is complicated with destruction of parenchyma and formation of pneumatocele, such as in our patient.[1,2] Recurrent infections (pneumonia, candidiasis, otitis, BCG-itis and skin abscesses) appeared early in life in our patient, and were associated with elevated IgE levels and eosinophilia. Other causes of eosinophilia were ruled out (parasitic diseases- oxiuriasis, ascariasis, trichinosis), asthma, malignant diseases (Hodgkin and non-Hodgkin lymphoma, acute and chronic eosinophilic leukemia, chronic myelogenous leukemia, acute lymphoblastic leukemia), and idiopathic

hypereosinophylic syndrome. Hereditary and acquired immunological disorders are frequently associated with eosinophylia and eczema (Wiskott-Aldrich syndrome, Ommen syndrome, Hyper-IgM syndrome).[5] These disorders, as well as atopic dermatitis, were ruled out in our patient. All clinical symptoms indicated that she is a patient with hyper-IgE syndrome. The diagnosis of HIES is difficult to be confirmed, considering that both immunologic and somatic features need to be identified prior to genetic testing. Immune system disturbances in patients with HIES are still not completely elucidated. It is known that impairment of granulocyte chemotaxis in these patients is evident as well as decreased production of interferon-4 on stimulation with IL-12.[6] One can suppose that increased expression of IL-13 receptors on CD4- lymphocytes in these patients causes extreme elevation of IgE antibodies.[7] Elevated IgE level greater than 2 standard deviations, higher than age-appropriate normal limits, is the hallmark of HIES, although even lower IgE values do not exclude completely diagnosis of HIES. Sometimes, in patients with atopic dermatitis serum concentrations of IgE can be elevated, but atopic dermatitis is clinically characterized by a somewhat different appearance - with frequent weeping and superinfected lesions. Patients with atopic dermatitis also lack distinctive facial and skeletal anomalies associated with HIES.[1,2] Our patient had skin changes resembling atopic dermatitis and proven hypersensitivity to cow's milk. According to our knowledge so far, several cases of HIES with the proven nutritional allergy have been described.[3,5,8] In HIES numerous skeletal and dental abnormalities were described. Some of them are demonstrated in our case, and these features tend to become more pronounced with age.[1,2] Genetic basis of HIES is still under investigation. Recent studies have demonstrated that dominant-negative mutations in the signal transducer and activator of transcription 3 (STAT3) gene results in the classical multisystem form of AD-HIES, whereas a null mutation in the tyrosine kinas 2 (TYK2) gene causes an AR-HIES**.** STAT3 plays a critical role in responses to many cytokines, in which, IL-17 produced by T_H17 cell is protective in the host defence against Staphylococcus aureus and Candida. Therefore, a deficiency in STAT3 is a major cause of sporadic and familial HIES. Our opinion is that our patient possibly had *de novo* mutation, as a literature data suggest in a most cases of sporadic AD-HIES.[1] The diagnosis HIES is done with clinical scoring system was devised by the National Institutes of Health (NIH).[1,9,10] Her NIH score was 44 and suggest AD-HIES. Medical history, careful physical examination and determination of serum IgE levels are essential in screening for HIES, and detection of STAT3 mutations is helpful for diagnosis and genotyping of HIES. According to the recent guideline of Woellner C. at al, for the diagnosis of STAT-3 defficient HIES score of our patient was 29,97, and for possible diagnosis: IgE 1000 IU/ml plus a weighted score of clinical features greater than 30, based on recurrent pneumonia, newborn rash, pathologic bone fractures, characteristic face, and high palate. Albeit, as authors emphasizes, HIES scoring cannot replace thorough clinical examination, because patients with HIES accrue findings over time.[11] Moreover, BCG-itis, severe skin infection and abscess of the skin in our patient have not been captured by score, but increased our clinical suspicion for HIES. Regarding the lack of genetic investigation, the definite diagnosis is not possible. Molecular genetic testing of STAT3 are planned to confirm our clinical suspicion.

CONCLUSION

In this report, patient represents a case with HIES and cows-milk hypersensitivity. To diagnose HIES not all features need to be present, and because diagnostic characteristics can appear during longer time interval, clinical diagnosis in young children can be uncertain. Life threatening bacterial infections can appear early in the course of HIES, therefore for their adequate prevention and treatment it is important to diagnose the disorder as soon as possible. Occasionally, it can be difficult to distinguish hyper-IgE syndrome and atopic dermatitis. We suggest that food hypersensitivity should be investigated in patients with hypereosinophilia, hyper-IgE syndrome, and atopic dermatitis.

REFERENCES

1. Freeman AF, Holland SM. Clinical manifestations, etiology and pathogenesis of the hyper-IgE syndromes. Pediatr Res 2009; 65(5 Pt 2):32R-37R.
2. Orozco CV, Velásquez LH, Méndez NH, Augusto B, Salazar T. Hyper IgE syndrome. Opportune diagnosis and management. Rev Alerg Mex 2008; 55(1):38-45.

3. Hernandez-Trujillo VP, Nguyen WT, Belleau JT, Jeng M, Conley ME, Lew DB. Cow's milk allergy in a patient with hyper-IgE syndrome. Ann Allergy Asthma Immunol 2004; 92(4):469-74.
4. Chamlin SI, McCalmont TH, Cunningham BB, Esterly NB, Lai CH, Mallory SB, at al. Cutaneous manifestations of hyper-IgE syndrome in infants and children. J Pediatr 2002; 141(4):572-5.
5. Estrada-Reyes E, Hernnández-Román MP, Gamboa-Marrufo JD, Valencia-Herrera A, Nava-Ocampo AA. Hypereosinophilia, hyper-IgE syndrome, and atopic dermatitis in a toddler with food hypersensitivity. J Investig Allergol Clin Immunol 2008; 18(2):131-5.
6. Borges WG, Augustine NH, Hill HR. Defective interleukin-12 interferon-gamma pathway in patients with hyperimmunoglobulinemia E syndrome. J Pediatr 2000; 136(2):176-80.
7. Gudmundsson KO, Sigurjonsson OE, Gudmundsson S, Goldblatt D, Weemaes CM, Haraldsson A. Increased expression of interleukin-13 but not interleukin-4 in CD4+ cells from patients with the hyper-IgE syndrome. Clin Exp Immunol 2002; 128(3):532-7.
8. Neves AM, Cunha PA, Montanherc AG, Lima SS, Mallozi MC, Sole D, et al. Food allergy in an exclusively breast-fed infant with Hyper-IgE syndrome. Allergol Immunopathol (Madr) 2008; 36(4):238-41.
9. Grimbacher B, Holland SM, Gallin JI, Greenberg F, Hill SC, Malech HL, et al. Hyper-IgE syndrome with recurrent infection- an autosomal dominant multisystem disorder. N Engl J Med 1999; 340:692-702.
10. Minegishi Y. Hyper IgE syndrome. Curr Opin Immunol 2009; 21(5):487-92.
11. Woellner C, Gertz EM, Schäffer AA, Lagos M, Perro M, Glocker EO, et al. Mutations in STAT-3 and diagnostic guidelines for hyper-IgE syndrome. J Allergy Clin Immunol 2010; 125(2):424-32.