Mod Rheumatol
DOI 10.1007/s10165-012-0695-9

CASE REPORT

A case of Epstein–Barr virus-related lymphadenopathy mimicking the clinical features of IgG4-related disease

Yoko Wada · Masaru Kojima · Kazuhiro Yoshita · Mihoko Yamazaki · Daisuke Kobayashi · Shuichi Murakami · Shinichi Nishi · Masaaki Nakano · Ichiei Narita

Received: 14 March 2012 / Accepted: 30 May 2012
© Japan College of Rheumatology 2012

Abstract We report an intriguing case of Epstein–Barr virus (EBV)-related multiple lymphadenopathy that clinically mimics immunoglobulin G4-related disease (IgG4-RD). A 72-year-old woman presented with a history of asthma attacks, systemic lymphadenopathy, hypergammaglobulinemia, proteinuria, and an elevated level of serum IgG4, leading to a possible diagnosis of IgG4-RD based on current comprehensive diagnostic criteria. However, a percutaneous kidney biopsy specimen showed mild mesangial proliferative glomerulonephritis with focal membranous transformation, and there was no interstitial lesion or lymphocyte infiltration. Cervical lymph node biopsy demonstrated follicular hyperplasia associated with prominent lymphoplasmacytic infiltration in the interfollicular area. However, only a few IgG4-positive plasma cells were present. An in situ hybridization study demonstrated many EBV-infected lymphocytes in the germinal center as well as in the interfollicular area. This case illustrates the diversity of conditions associated with elevated levels of serum IgG4 and the necessity for tissue biopsy when diagnosing IgG4-RD.

Keywords Epstein–Barr virus · Systemic lymphadenopathy · Bronchial asthma · Membranous nephropathy · IgG4-related disease

Y. Wada (✉) · K. Yoshita · M. Yamazaki · D. Kobayashi · S. Murakami · I. Narita
Division of Clinical Nephrology and Rheumatology, Department of Medicine II, Niigata University Graduate School of Medical and Dental Sciences, 1-757 Asahimachi-dori, Chuo-ku, Niigata, Niigata 951-8510, Japan
e-mail: yoko.wada@gmail.com

M. Kojima
Anatomic and Diagnostic Pathology, Dokkyo Medical University, Tochigi, Japan

S. Nishi
Division of Nephrology and Kidney Center, Kobe University Graduate School of Medicine, Kobe, Japan

M. Nakano
Department of Medical Technology, School of Health Sciences, Faculty of Medicine, Niigata University, Niigata, Japan

Introduction

IgG4-related disease (IgG4-RD) has been recently established as a clinical entity characterized by an elevated level of serum IgG4 and mass-forming fibrotic lesions in exocrine glands and systemic organs with numerous infiltrating IgG4-positive plasma cells, and a generally good response to glucocorticoid therapy [1, 2]. Originally, it was recognized as an autoimmune disorder with features similar to those of autoimmune pancreatitis (AIP), retroperitoneal fibrosis, or Mikulicz's disease [3–5]. However, very little is known about the underlying cause of IgG4-RD.

Here, we report a case of Epstein–Barr virus (EBV)-related systemic lymphadenopathy in which the clinical symptoms and laboratory findings resembled those of IgG4-RD.

Case report

A 72-year-old Japanese woman was admitted to our hospital in January 2009 because of systemic lymphadenopathy, polyclonal hypergammaglobulinemia, and proteinuria. She had no history of smoking, dust exposure, or significant medical care. Initially she had been suffering repeated asthma attacks since August 2008, and chest

Published online: 28 July 2012

Table 1 Laboratory data on the patient upon admission to our hospital

	Values
Blood count	
White blood cells (WBCs)	4,120/μl
Neutrophils	56.8 %
Basophils	0.5 %
Eosinophils	7.5 %
Lymphocytes	28.4 %
Monocytes	6.8 %
Red blood cells (RBCs)	392 × 10^4/μl
Hemoglobin	11.2 g/dl
Hematocrit	35.4 %
Platelets	10.8 × 10^4/μl
Urinalysis	
Protein	4+
Occult blood	1+
Sugar	–
Urinary sediment	
RBCs	1–4/hpf
WBCs	1–4/hpf
Serum chemistry	
TP	7.3 g/dl
Alb	3.2 g/dl
BUN	20 mg/dl
Cr	0.63 mg/dl
UA	3.7 mg/dl
Na	139 mEq/l
K	3.9 mEq/l
Cl	106 mEq/l
AST	49 IU/l
ALT	21 IU/l
LDH	215 IU/l
ALP	198 IU/l
ChE	112 IU/l
TB	1.0 mg/dl
DB	0.0 mg/dl
Immunological findings	
CRP	0. 85 mg/dL
IgG	2155 mg/dL
IgG1	1330 mg/dL
IgG2	630 mg/dL
IgG3	32.6 mg/dL
IgG4	415 mg/dL
IgM	89 mg/dL
IgE	2235 IU/mL
CH50	34 U/mL
C3	66.7 mg/dL
C4	13.7 mg/dL
s-IL2R	3779 U/mL
ANA	17.7 index
RF	25.1 IU/ml
HBs-Ag	–
HCV-Ab	–
HIV-Ab	–
CMV-IgM	< ×10
CMV-IgG	×160
EBVCA-IgG	×160
EBVCA-IgM	< ×10
EBEA-IgG	< ×10
EBEA-IgM	< ×10
EBEBNA	×40

HBs-Ag surface antigen of the hepatitis B virus, *HCV Ab* hepatitis C virus antibody, *HIV* human immunosufficiency virus, *CMV* cytomegalovirus, *Ig* immunoglobulin, *EBVCA* Epstein–Barr virus capsid antigen

X-ray examination at the referring hospital had revealed incidental bilateral hilar lymph node swelling. Systemic lymphadenopathy was identified on the computed tomography (CT) scan, and a subaxillar lymph node biopsy was performed. Reactive lymphadenopathy was diagnosed in the specimen. The asthmatic symptoms were improved after inhaled glucocorticoid therapy, but additional laboratory studies revealed hypergammaglobulinemia, proteinuria, and positivity for anti-nuclear antibody (ANA), indicating some form of autoimmune disorder.

Upon admission, physical examination revealed bilateral axillar lymph node swelling and pretibial edema. No fever or particular rash was observed. Table 1 shows the results of the initial laboratory examinations performed on admission to our hospital, revealing mild thrombocytopenia, elevated levels of C-reactive protein (0.85 mg/dl), immunoglobulin G (IgG) (2,155 IU/ml), and IgA (663 mg/dl), and a marked elevation of the IgE level (2,235 IU/ml). The serum level of IgG4 was elevated at 415 mg/dl (17.2 %). The patient tested weakly positive for rheumatoid factor (25.1 IU/ml), but negative for ANA. Positivity for antibodies against cytomegalovirus and Epstein–Barr virus (EBV) indicated a history of these infections. Urinary protein excretion was 2.69 g/day, and the 24-h creatinine clearance was normal at 112.7 ml/min. Pulmonary function studies demonstrated a moderate obstructive but normal, restrictive lung. The CT scan revealed systemic multiple lymph node swellings in the bilateral cervical, interstitial, hilar, abdominal, and intrapelvic areas. Small trabecular shadows with ground-glass opacities were also found in the right upper and left lower lobes (Fig. 1a, b). No significant abnormality was observed in the bilateral kidneys. The

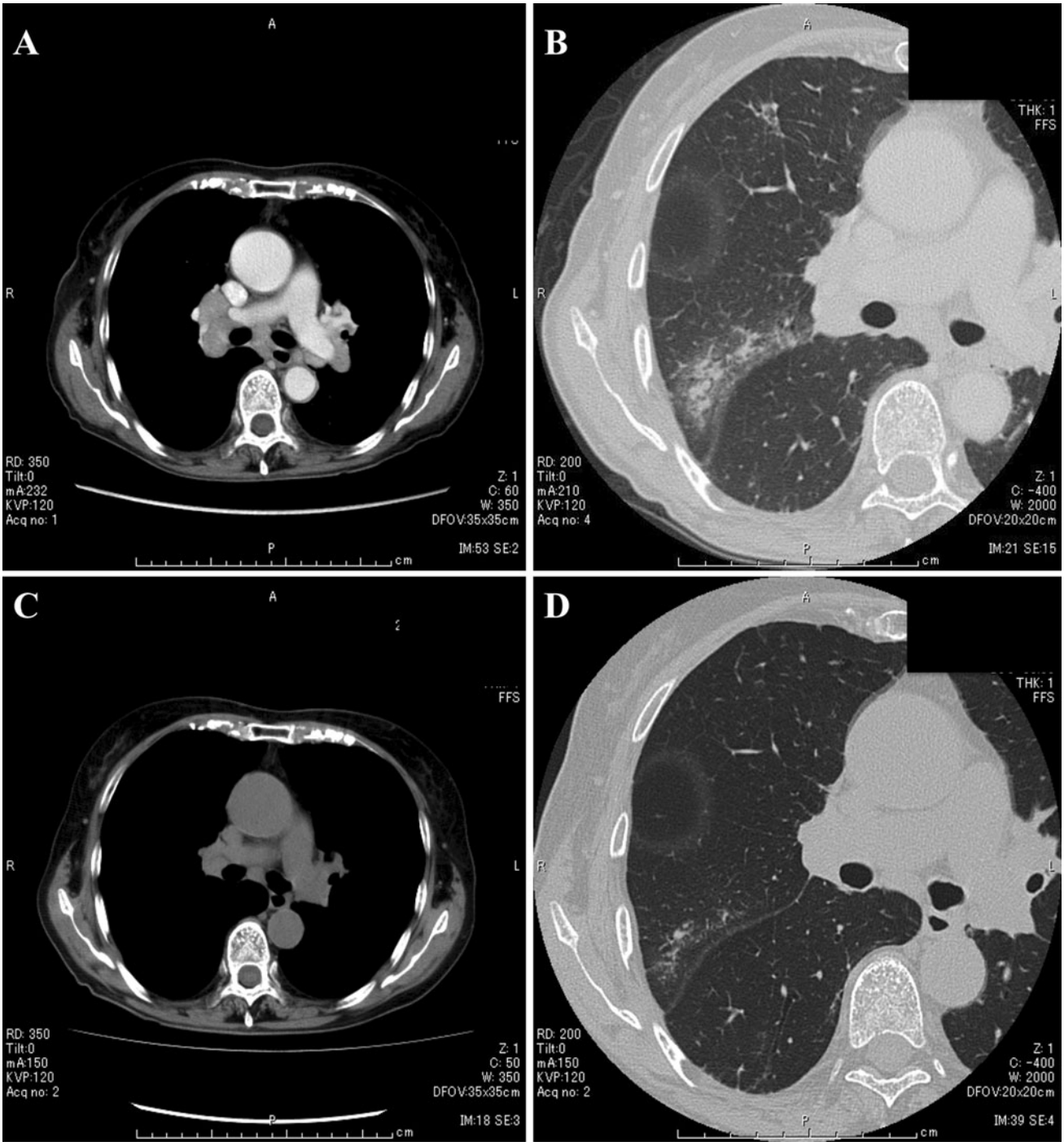

Fig. 1 Computed tomography scan on admission (**a**, **b**) and 1 year after admission (**c**, **d**). **a** Bilateral hilar lymphadenopathy is evident, **b** small trabecular shadows with ground-glass opacities in the right lobe, visible on the high-resolution computed tomography scan, **c** lymphadenopathy is significantly improved, **d** ground-glass opacities are also improved

whole-body gallium scan showed abnormal uptake in the bilateral hilar regions. These clinical, laboratory, and imaging findings fulfilled a possible diagnosis of IgG4-related disease (IgG4-RD) involving the lymph nodes, kidneys, and lung, according to the comprehensive diagnostic criteria for IgG4-related disease [6]. A percutaneous kidney biopsy was performed for confirmation. However, light microscopy observation of the specimen showed only minor glomerular abnormalities without any interstitial lesion or lymphocyte infiltration. An immunofluorescence study showed scattered deposition of IgG, IgM, and C3c in the mesangial space, and focal, fine granular staining of

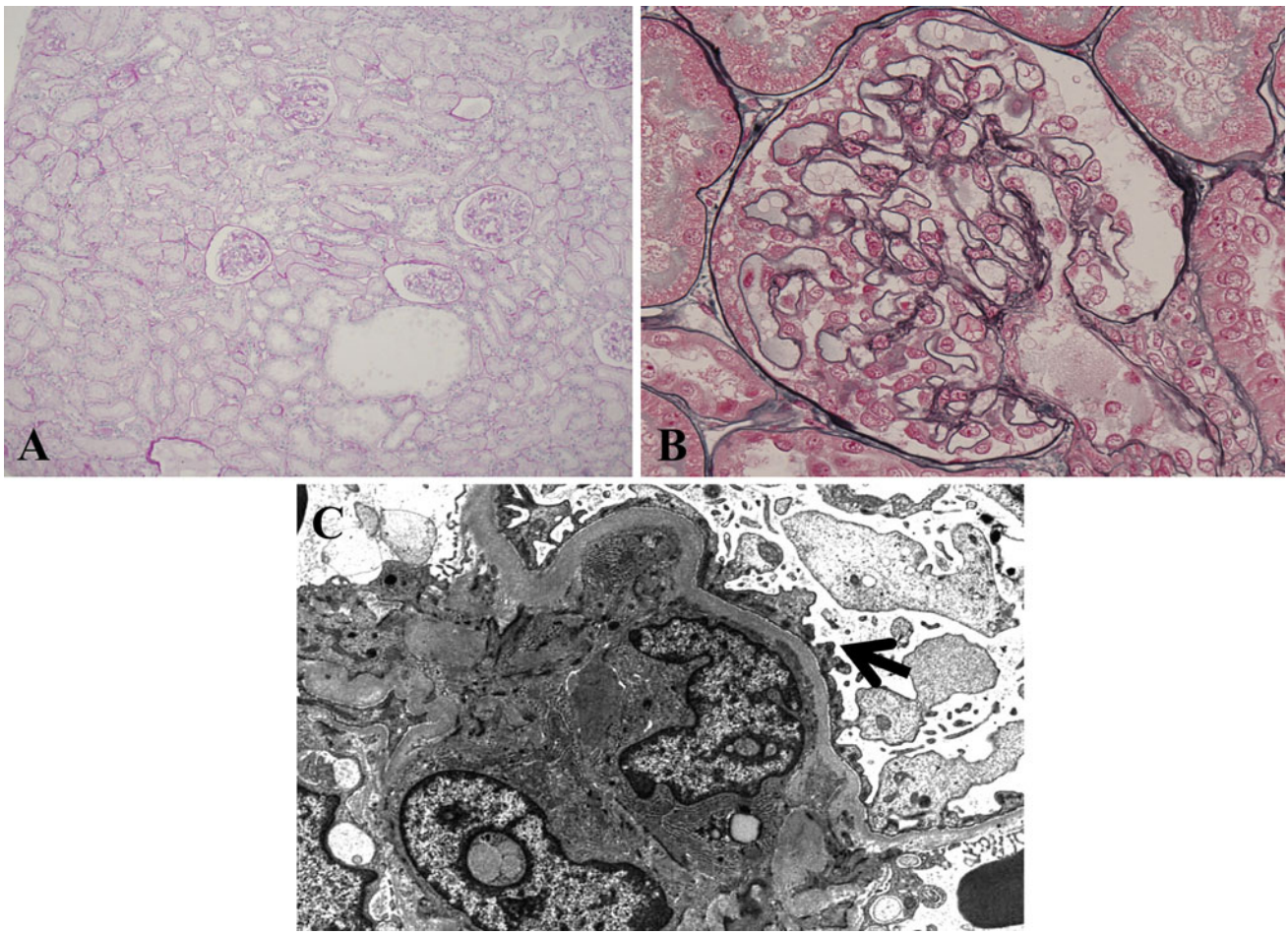

Fig. 2 Histopathological features of kidney biopsy specimens. **a** No significant interstitial lesion is evident by light microscopy examination (periodic acid–Schiff stain, magnification ×100), **b** Glomeruli in the biopsy specimen are found to have minor abnormalities upon light microscopy examination (periodic acid–methenamine/Masson trichrome stain, ×600), **c** scattered membranous transformation of the glomerular basement membrane is evident (*black arrow*) upon electron microscopy examination (×1,500)

IgG, IgA, and IgM in the glomerular capillary loops. Electron microscopic examination revealed mild mesangial matrix proliferation and focal, small electron-dense deposits in the mesangial space and subepithelial aspects of the glomerular basement membrane with focal foot process effacement (Fig. 2a–c). No significant lymphocyte infiltration or interstitial lesion was observed. Together with these results, the pathological diagnosis of this case was mild mesangial proliferative glomerulonephritis with focal mesangial and subepithelial deposits, indicating no significant evidence of IgG4-related kidney disease.

Cervical lymph node biopsy specimens taken at the previous hospital showed reactive follicular hyperplasia with enlarged germinal centers, as well as prominent lymphoplasmacytic infiltration in the interfollicular areas (Fig. 3a, b). Immunohistochemical studies of light-chain determinants for interfollicular plasma cells and plasmacytoid cells revealed a polyclonal pattern. There were numerous IgG-positive plasma cells, but only a few IgG4-positive cells (Fig. 3c). An in situ hybridization study demonstrated many EBV-encoded small RNA (EBER)-positive lymphocytes in the germinal centers as well as in the interfollicular areas (Fig. 3d). Tests for EBV nuclear antigen-2 and latent membrane protein-1 were negative, suggesting that the EBV latency pattern was I in this case.

The patient's proteinuria gradually decreased after admission and then completely disappeared after administration of a low dose of the angiotensin II receptor antagonist losartan. The serum levels of IgG and IgG4 became almost normalized (Table 2), and the systemic lymph node swellings and lung lesions evident on the CT scan also ameliorated without any medication during the follow-up period (Fig. 1c, d).

Discussion

Although the case described here has many characteristic features in common with IgG4-RD and the patient could even be diagnosed as possibly having IgG4-RD on the basis

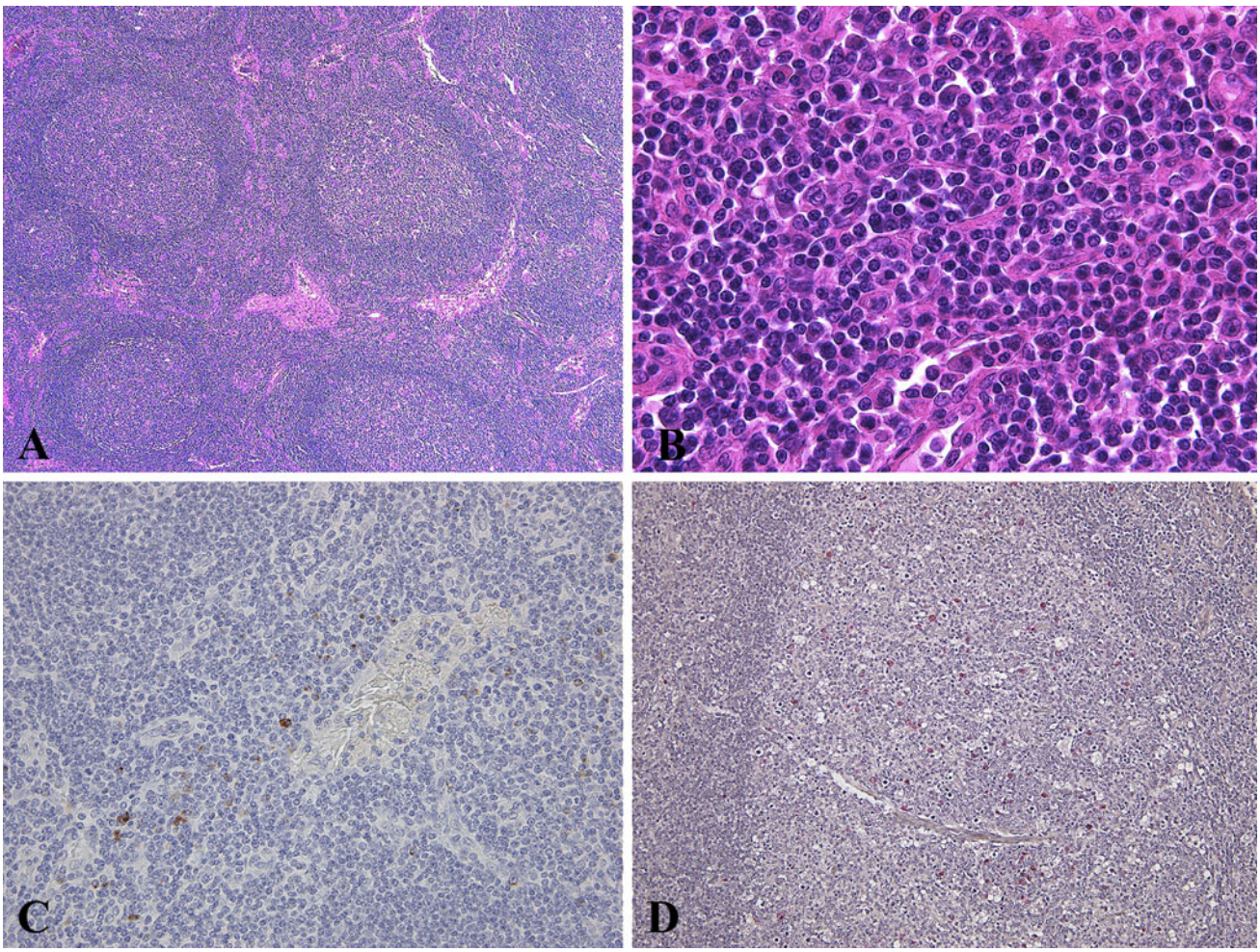

Fig. 3 Histopathological features of lymph node biopsy specimens. **a** Follicular hyperplasia with an enlarged germinal center is evident [hematoxylin and eosin (H&E) stain, ×4], **b** numerous infiltrating lymphocytes and plasma cells are evident in interfollicular areas (H&E stain, ×40), **c** scattered positive cells are evident by IgG4 immunostaining (×20), **d** many Epstein–Barr virus-encoded small nuclear RNA (EBER)-positive cells are evident in germinal centers and interfollicular areas (×20)

Table 2 Clinical course and laboratory findings in this case

Clinical parameters	August 2008[a]	January 2009[b]	March 2009	January 2010
IgG (mg/dl)	2,821	2,155	1,608	1,120
IgG4 (mg/dl)	–	415	–	106
IgE (mg/dl)	7,385	2,235	–	–
C3 (mg/dl)	–	66.3	93.6	102.2
C4 (mg/dl)	–	13.7	20.3	25.6
Urinary protein	–	(4+), 2.69 g/day	(1+)	(−)

[a] Initial visit to the previous hospital

[b] Admission to our hospital

of the comprehensive diagnostic criteria [6], the pathological findings from kidney and lymph node specimens were quite different. Indeed, the serum IgG4 level is known to be elevated in many other disorders, such as granulomatosis with polyangiitis (Wegener's granulomatosis), Churg–Strauss syndrome, multicentric Castleman's disease, and even bronchial asthma, at a low frequency [7, 8]. It is unclear whether the serum IgG4 level is elevated in patients with chronic or re-activated EBV infections, but it has been reported to be transiently elevated during the course of acute EBV infection [9].

Autoimmunity is thought to be involved in the pathogenesis of IgG4-RD. In patients with autoimmune pancreatitis (AIP), for example, autoantibodies against lactoferrin and carbonic anhydrase II are known to be detectable together with increased serum levels of IgG4 [10]. Several studies have also demonstrated molecular mimicry between *Helicobacter pylori* and constituents of pancreatic epithelial cells, indicating that certain kinds of infections may trigger the onset of AIP [11].

The most striking feature in our case was the numerous EBV-infected lymphocytes in the germinal centers and interfollicular areas. Kurth et al. [12] reported that the

presence of numerous EBER-positive cells in germinal centers as well as in interfollicular areas appeared to be a characteristic of recent EBV infection. EBV is well recognized as a possible pathogen involved in the development of autoimmune disorders, such as systemic lupus erythematosus, rheumatoid arthritis, and Sjögren's syndrome [13–15]. Although there is no significant evidence for the involvement of acute or chronic EBV infection in IgG4-RD, Kashiwagi et al. [16] reported the presence of EBV-encoded small RNA-expressed myofibroblasts and the infiltration of IgG4-positive plasma cells in sclerosing angiomatoid nodular transformation of the spleen, suggesting that this disorder is part of the organ involvement of IgG4-RD associated with EBV infection.

Kojima et al. [17] have reported elderly patients with EBV-related systemic lymph node lesions resembling those clinicopathologically evident in autoimmune disease. Indeed, these patients shared many characteristic findings with our present patient, including an advanced age at onset, transient hypergammaglobulinemia with positivity for autoantibodies, a self-limiting clinical course, and no significant degree of immunocompromise.

The other characteristic feature of the present case was systemic organ involvement, including the lung and kidney. With regard to EBV infection, lung lesions are evident in patients with EBV-associated lymphoproliferative disorders, and secondary membranous nephropathy is known to be one of the rare complications of EBV infection, albeit mainly in children [18, 19]. Indeed, membranous nephropathy is also reported to be one of the rare kidney complications associated with tubulointerstitial nephritis in patients with IgG4-RD [20, 21]. Interestingly, an increase in Th2 cytokines, a regulatory immune reaction, and IgG4 production have been reported to be involved in both IgG4-RD [22] and idiopathic membranous nephropathy [23]. Although the Th1/Th2 balance in EBV infection has not yet been fully investigated [24], it is possible that some kind of re-activation or chronic active EBV infection may alter the functions of T cells to produce Th2 cytokines, leading to increased production of IgG4 by B cells.

In conclusion, we have described a case of EBV-related lymphadenopathy that mimics the clinical features of IgG4-RD. This case illustrates the diversity of conditions associated with an elevated level of serum IgG4 and the need for tissue biopsy when diagnosing IgG4-RD. Further studies and additional cases will be needed to examine the possible involvement of EBV re-activation in the development of IgG4-RD-like symptoms and to clarify some of the mechanisms potentially underlying the development of IgG4-RD.

Acknowledgments The authors are grateful to Dr. Yasuharu Sato, MD, PhD, Department of Pathology, Okayama University Graduate School of Medicine, Dentistry and Pharmaceutical Sciences, Okayama, Japan, for his valuable suggestions concerning the manuscript.

Conflict of interest None.

References

1. Masaki Y, Dong L, Kurose N, Kitagawa K, Morikawa Y, Yamamoto H, et al. Proposal for a new clinical entity, IgG4-positive multi-organ lymphoproliferative syndrome: analysis of 64 cases of IgG4-related disorders. Ann Rheum Dis. 2009;68:1310–5.
2. Umehara H, Kazuichi O, Masaki Y, Kawano M, Yamamoto M, Saeki T, et al. A novel clinical entity, IgG4-related disease (IgG4RD): general concept and details. Mod Rheumatol. 2012; 22:1–14.
3. Hamano H, Kawa S, Horiuchi A, Unno H, Furuya N, Akamatsu T, et al. High serum IgG4 concentrations in patients with sclerosing pancreatitis. N Engl J Med. 2001;344:732–8.
4. Zen Y, Sawazaki A, Miyayama S, Notsumata K, Tanaka N, Nakanuma Y. A case of retroperitoneal and mediastinal fibrosis exhibiting elevated levels of IgG4 in the absence of sclerosing pancreatitis (autoimmune pancreatitis). Hum Pathol. 2006;37: 239–43.
5. Yamamoto M, Takahashi H, Ohara M, Suzuki C, Naishiro Y, Yamamoto H, et al. A new conceptualization for Mikulicz's disease as an IgG4-related plasmacytic disease. Mod Rheumatol. 2006;16:335–40.
6. Umehara H, Okazaki K, Masaki Y, Kawano M, Yamamoto M, Saeki T, et al. Comprehensive diagnostic criteria for IgG4-related disease (IgG4-RD), 2011. Mod Rheumatol. 2012;22:21–30.
7. Yamamoto M, Tabeya T, Naishiro Y, Yajima H, Ishigami K, Shimizu Y, et al. Value of serum IgG4 in the diagnosis of IgG4-related disease and in differentiation from rheumatic diseases and other diseases. Mod Rheumatol. 2011 (Epub ahead of print).
8. Iguchi A, Wada Y, Kobayashi D, Sato H, Oyama T, Nakatsue T, et al. A case of MPO and PR3-ANCA-positive hypertrophic cranial pachymeningitis with elevated serum IgG4. Mod Rheumatol. 2012 (in press).
9. Shacks SJ, Heiner DC, Bahna SL, Horwitz CA. Increased serum IgG4 levels in acute Epstein–Barr viral mononucleosis. Ann Allergy. 1985;54:284–8.
10. Okazaki K, Uchida K, Fukui T. Recent advances in autoimmune pancreatitis: concept, diagnosis, and pathogenesis. J Gastroenterol. 2008;43:409–18.
11. Kountouras J, Zavos C, Chatzopoulos D. A concept on the role of *Helicobacter pylori* infection in autoimmune pancreatitis. J Cell Mol Med. 2005;9:196–207.
12. Kurth J, Hansmann M-L, Rajewsky K, Küppers R. Epstein–Barr virus infected B cells expanding in germinal centers of infectious mononucleosis patients do not participate in germinal center reaction. Proc Natl Acad Sci USA. 2003;100:4730–5.
13. Poole BD, Scofield RH, Harley JB, James JA. Epstein–Barr virus and molecular mimicry in systemic lupus erythematosus. Autoimmunity. 2006;39:63–70.
14. Toussirot E, Roudier J. Epstein–Barr virus in autoimmune diseases. Best Pract Res Clin Rheumatol. 2008;22:883–96.
15. Niller HH, Wolf H, Minarovits J. Regulation and dysregulation of Epstein–Barr virus latency: implications for the development of autoimmune diseases. Autoimmunity. 2008;41:298–328.
16. Kashiwagi S, Kumasaka T, Bunsei N, Fukumura Y, Yamasaki S, Abe K, et al. Detection of Epstein–Barr virus-encoded small RNA-expressed myofibroblasts and IgG4-producing plasma cells

in sclerosing angiomatoid nodular transformation of the spleen. Virchows Arch. 2008;453:275–82.
17. Kojima M, Sugiura I, Itoh H, Shimizu K, Murayama K, Motoori T, et al. Histological varieties of Epstein–Barr virus related lymph node lesion resembling autoimmune disease-like clinicopathological findings in middle-aged and elderly patients—a study of six cases. Pathol Res Pract. 2006;203:609–15.
18. Blowey DL. Nephrotic syndrome associated with an Epstein–Barr virus infection. Pediatr Nephrol. 1996;10:507–8.
19. Araya CE, Gonzalez-Peralta RP, Skoda-Smith S, Dharnidharka VR. Systemic Epstein–Barr virus infection associated with membranous nephropathy in children. Clin Nephrol. 2006;65:160–4.
20. Saeki T, Imai N, Ito T, Yamazaki H, Nishi S. Membranous nephropathy associated with IgG4-related systemic disease and without autoimmune pancreatitis. Clin Nephrol. 2009;71:173–8.
21. Nishi S, Imai N, Yoshita K, Ito Y, Saeki T. Clinicopathological findings of immunoglobulin G4-related kidney disease. Clin Exp Nephrol. 2011;15:810–9.
22. Stone JH, Zen Y, Deshpande V. IgG4-related disease. N Engl J Med. 2012;366:539–51.
23. Kuroki A, Iyoda M, Shibata T, Sugisaki T. Th2 cytokines increase and stimulate B cells to produce IgG4 in idiopathic membranous nephropathy. Kidney Int. 2005;68:302–10.
24. Ohshima K, Karube K, Hamasaki M, Tutiya T, Yamaguchi T, Suefuji H, et al. Differential chemokine, chemokine receptor and cytokine expression in Epstein–Barr virus-associated lymphoproliferative diseases. Leuk Lymphoma. 2003;44:1367–78.