Clinical Reviews in Allergy & Immunology
https://doi.org/10.1007/s12016-019-08732-1

Eosinophilic Gastrointestinal Disorders

Nirmala Gonsalves [1]

© Springer Science+Business Media, LLC, part of Springer Nature 2019

Abstract
Eosinophilic gastrointestinal disorders (EGID) are a group of disorders characterized by pathologic eosinophilic infiltration of the esophagus, stomach, small intestine, or colon leading to organ dysfunction and clinical symptoms (*J Pediatr Gastroenterol Nutr*; Spergel et al., 52: 300–306, 2011). These disorders include eosinophilic esophagitis (EoE), eosinophilic gastritis (EG), eosinophilic gastroenteritis (EGE), eosinophilic enteritis (EE), and eosinophilic colitis (EC). Symptoms are dependent not only on the location (organ) as well as extent (layer invasion of the bowel wall). Common symptoms of EoE include dysphagia and food impaction in adults and heartburn, abdominal pain, and vomiting in children. Common symptoms of the other EGIDs include abdominal pain, nausea, vomiting, early satiety, diarrhea, and weight loss. These disorders are considered immune-mediated chronic inflammatory disorders with strong links to food allergen triggers. Treatment strategies focus on either medical or dietary therapy. These options include not only controlling symptoms and bowel inflammation but also on identifying potential food triggers. This chapter will focus on the clinical presentation, pathophysiology, and treatment of these increasingly recognized disorders.

Keywords Eosinophilic gastroenteritis · Eosinophilic gastritis · Eosinophilic esophagitis · Dysphagia · Food impaction · Food allergy

Introduction

Eosinophilic gastrointestinal disorders (EGID) are a group of disorders characterized by pathologic eosinophilic infiltration of the esophagus, stomach, small intestine, or colon leading to organ dysfunction and clinical symptoms [1]. Nomenclature and the specific presentation of EGID depend on the location (organ) and extent (layer invasion) of eosinophilic infiltration. In eosinophilic esophagitis (EoE), the most common of these disorders, eosinophils are isolated to the esophagus. Other less common disorders include eosinophilic gastritis (EG) where eosinophils are isolated to the stomach. If eosinophils are located more diffusely (esophagus, stomach, and/or small intestine), we label the illness, eosinophilic gastroenteritis (EGE). Eosinophilic involvement isolated solely to the intestine or colon is labeled eosinophilic enteritis and colitis (EC) respectively. Eosinophils may infiltrate the mucosal layer, the muscular layer, or the subserosal layer of the GI tract [2]. For the purpose of this chapter, we will discuss these disorders separately and focus on the available data on the clinical presentation, pathophysiology, and treatment.

✉ Nirmala Gonsalves
n-gonsalves@northwestern.edu

[1] Feinberg School of Medicine, Northwestern University, 676 N St. Claire St, Suite 1400, Chicago, IL 60614, USA

Eosinophilic Esophagitis

Background and Epidemiology and Pathophysiology

Eosinophilic esophagitis (EoE) is an immune-mediated antigen-driven disease characterized by pathologic eosinophilic inflammation of the esophagus as well as esophageal dysfunction leading to clinical symptoms [3]. Over the last decade, EoE has become increasingly recognized as an important disease by allergists, internists, pediatricians, pathologists, and gastroenterologists caring for both pediatric and adult patients. Previously considered a rare condition, there has been a dramatic increase in reports of EoE from many continents including North and South America, Europe, Asia, Australia, and the Middle East. The cause for this rise is thought to be multifactorial including a true increasing incidence of EoE in addition to a growing awareness of the condition among clinicians [4, 5]. Prior studies have suggested an incidence in children to be 10.4 in 10,000 and 3 per 10,000 in adults [6–8].

Published online: 22 March 2019

These numbers are likely to underestimate the true incidence and prevalence of EoE in the general population since these studies evaluated patients with symptoms warranting upper endoscopy. Esophageal eosinophilia may be more prevalent than this as demonstrated by a population-based study in Sweden which randomly surveyed 3000 adults, 1000 of whom underwent endoscopy with esophageal biopsies. This group found that histologic eosinophilia meeting their criteria for definite and probable EoE was present in 1% of the population [9]. These numbers suggest that incidence of EoE may one day approximate that of other immunologically driven disorders such as inflammatory bowel disease. This increase also reflects the rising trends in other immunologically driven disorders such as asthma, atopy, and food allergies [10].

Eosinophilic esophagitis has a male predilection. Results from 323 adult patients from 13 studies observed that 76% were males with a mean age of 38 years (range 14 to 89 years). Results from 754 pediatric patients from 16 studies found that 66% were male with a mean age of 8.6 years (range 0.5 to 21.1 years) [3, 11]. While most studies show a Caucasian predilection, EoE has been described in patients with varied ethnicities including those African American, Latin-American, and Asian descent [11]. In a case-control study that included 115 patients with EoE and 225 controls, patients with EoE were significantly less likely to have smoked cigarettes or actively use NSAIDs (OR 0.36 and 0.47, respectively) [12]. However, there was no significant difference in rates of smoking or NSAID exposure between cases with or without fibrostenosing disease or among patients with a post-treatment histologic response. More recent studies have suggested that early-life factors, including maternal fever, preterm labor, cesarean delivery, and antibiotic or acid suppressant use in infancy, were associated with risk of pediatric EoE. Interestingly, having a pet in the home was protective. These results implicate early-life exposures in EoE pathogenesis and are being further investigated [13].

Genetics

A familial pattern has been recognized in both the adult and pediatric population. In a case series of 381 children with EoE, 5% of patients had siblings with EoE and 7% had a parent with either an esophageal stricture or a known diagnosis of EoE [14–16]. Therefore, a workup of patients should include a thorough family history [12].

A genetic predisposition to EoE is supported by evidence of familial clustering and twin studies, which have revealed a 58% concordance in monozygotic twins and a 36% concordance in dizygotic twins compared with regular fraternal siblings [17]. In addition, several genetic variants that may predispose to EoE have been identified, especially at 5q22 (*TSLP* gene) and 2p23 (*CAPN14* gene) as well as a genome-wide association study identifying links between EoE and a gene called eotaxin-3, a gene encoding an eosinophil-specific chemoattractant [18]. Pathophysiology of these interesting disorders is thought to be multifactorial including involvement of food and environmental allergens, acid interplay, and genetic factors described above.

Clinical Features

As with other diseases, some age-related differences in clinical presentation are noted between children and adults [19, 20]. The most common presenting symptoms in adults include dysphagia, food impaction, heartburn, and chest pain with one study showing as many as 50% of adult patients with food impaction were diagnosed with EoE [3].

Children present differently however with the most common complaints being vomiting, heartburn, regurgitation, emesis, and abdominal pain [14, 21]. While younger children rarely present with dysphagia and food impaction typical of adult complaints, these presentations were more often seen in older children and adolescents [6]. In adults, there has been a delay of diagnosis with prior misdiagnosis of alternate diagnoses, including Schatzki rings or gastroesophageal reflux disease (GERD) [22]. In many cases, these patients had undergone repeated endoscopies, esophageal dilations, and a delay in the institution of appropriate medical therapy. One reason for the delay of diagnosis could be that prior literature in the pathology community equated the presence of eosinophils in esophageal mucosal biopsies with GERD and therefore some specimens may have been classified as reflux. Due to this potential overlap, gastroenterologists who suspect a diagnosis of EoE should specifically request tissue eosinophil counts as well as description of other inflammatory features to help differentiate this diagnosis from GERD. Recent investigations by prominent eosinophil pathologists are now looking at a newer histologic scoring system which takes into account additional inflammatory features rather than focusing solely on the eosinophil number [23].

Endoscopic Findings

Patients with eosinophilic esophagitis have characteristic features on endoscopy suggestive of the diagnosis. The most common endoscopic features in adults with EoE include linear or longitudinal furrows (80%), mucosal rings (64%), small caliber esophagus (28%), white plaques and/or exudates (16%), and strictures (12%) [24] (Fig. 1). In a large clinical series of 381 children, the most common endoscopic features were linear furrows (41%), normal appearance (32%), esophageal rings (12%), and white plaques (15%) [14, 21]. While these are the characteristic features, they can often be subtle and missed on endoscopy, so it is advised to take esophageal biopsies in all patients suspected of having EoE irrespective of

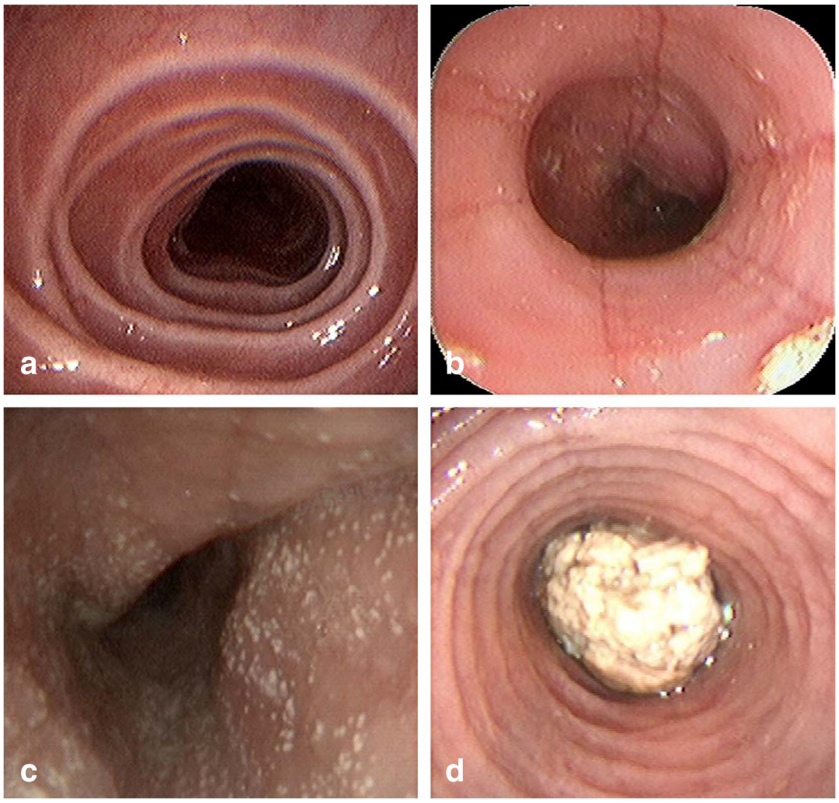

Fig. 1 Endoscopic images showing common features of EoE in adults. **a** Concentric mucosal rings. **b** Linear furrowing. **c** White exudates/plaques. **d** Food impaction in a patient with underlying EoE [22]

endoscopic appearance [3]. A new endoscopic reference scoring tool called (EREFS) has been developed and validated and is a helpful tool to objectively characterize endoscopic abnormalities [25].

Histologic Features

While certain endoscopic features are characteristic of EoE, the gold standard for diagnosis remains biopsy findings demonstrating histologic changes of increased intramucosal eosinophils in the esophagus without concomitant eosinophilic infiltration in the stomach or duodenum [11]. Other histologic features of this condition include superficial layering of the eosinophils, eosinophilic microabscesses (clusters of ≥ 4 eosinophils), epithelial hyperplasia intercellular edema or spongiosis, and degranulation of eosinophils (see Fig. 2). Other inflammatory cells such as lymphocytes, polymorphonuclear leukocytes, and mast cells may be present in the epithelium [26].

Subepithelial fibrosis has been demonstrated in biopsies of both children and adults with EoE suggesting involvement of deeper layers of the esophagus which also likely contribute to esophageal dysfunction [27]. Thickening of the deeper layers of the esophagus has also been demonstrated in studies using endoscopic ultrasound to investigate the esophagus [28]. It is speculated that this mucosal and submucosal fibrosis may lead to esophageal remodeling and decreased compliance of the esophagus thus contributing to the symptoms of dysphagia even in the absence of an identifiable stricture. A newer technique called the functional luminal imaging probe has also shown changes in compliance of the esophageal wall in adults further supporting the concern for esophageal fibrosis. This technique has shown improvement in esophageal compliance after treatment with either diet or medication [29].

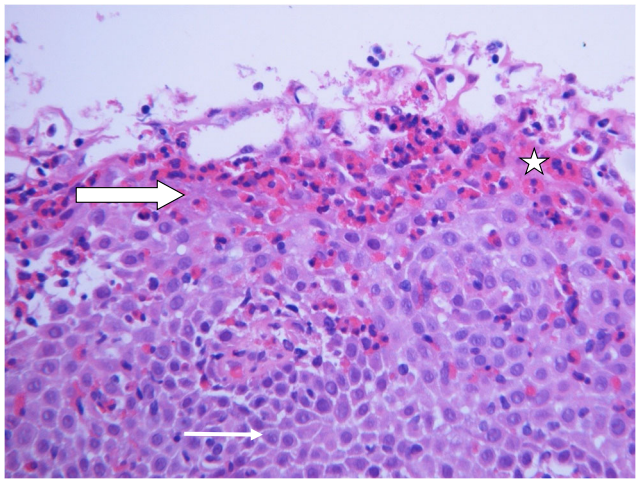

Fig. 2 Histologic findings in patients with EoE showing numerous eosinophils with superficial layering in the esophageal epithelium (large arrow), spongiosis or intercellular edema (small arrow), and microabscesses or clusters of > 4 eosinophils in a group (star). Image courtesy of Dr. Gonsalves

Although a single diagnostic threshold of eosinophil density has not been determined, prior consensus statements suggest using a threshold value of ≥ 15 eosinophils per high power field to diagnose EoE [3, 11, 30]. It has also been demonstrated that the eosinophilic infiltration of the esophagus may not be evenly distributed within the esophagus [22]. Therefore, it is suggested that biopsies be obtained from both the proximal and distal esophagus to obtain a higher diagnostic yield and perhaps increase the specificity of the diagnosis. At least five biopsies need to be obtained at multiple regions of the esophagus to help maximize the sensitivity based on a diagnostic threshold of ≥ 15 eosinophils per high power field in the adult population [22]. While current guidelines are using an absolute threshold of 15 eosinophils/hpf to determine active inflammation, development of newer histologic scoring tools may have better accuracy in assessing disease activity [23].

Diagnostic Criteria

Recent consensus recommendations based on a systematic review of the literature and expert opinion have led to the following diagnostic criteria. EoE is a clinicopathological disease characterized by (a) the presence of symptoms including but not limited to dysphagia and food impaction in adults and feeding intolerance and GERD symptoms in children, (b) eosinophil predominant inflammation of ≥ 15 eosinophils per high power field in the esophageal tissue, and (c) eosinophilia isolated to the esophagus after an adequate high dose PPI trial, as well as (d) exclusion of other disorders associated with similar clinical, histologic, or endoscopic features [3].

PPI-Responsive Esophageal Eosinophilia (PPI-REE)

Patients with clinical and histologic features compatible with eosinophilic esophagitis but who respond histologically to a PPI have been described as having PPI-responsive esophageal eosinophilia. At this present time, there is considerable controversy over this group of patients and whether they represent a subset of patients with EoE who happen to respond to PPI therapy given the strong overlap of some clinical, endoscopic, and even genotypic features [31–33]. In a study that evaluated differences in major basic protein, tryptase, and eotaxin-3 levels in patients with PPI-responsive esophageal eosinophilia, eosinophilic esophagitis, and controls, there were significant differences in protein levels when patients with eosinophilic esophagitis were compared with controls but not with patients with PPI-responsive esophageal eosinophilia [34]. In another study, clinical and endoscopic features of patients with PPI-REE were indistinguishable from patients with EoE [35].The mechanisms by which PPIs improve esophageal eosinophilia have been shown to be independent of acid suppression and rather on effect of blocking eotaxin-3 and its effect on esophageal eosinophil recruitment [36]. Given that there is strong evidence that PPI therapy can improve histologic, endoscopic, and symptomatic features in patients with presumed EoE/esophageal eosinophilia, PPI therapy is a helpful first step in the treatment of these disorders.

Mucosal involvement classically presents with abdominal pain, nausea, vomiting, diarrhea, anemia, protein-losing enteropathy, and weight loss [2]. In contrast, muscular involvement typically presents with pyloric or intestinal obstruction, stricturing or perforation. Subserosal infiltration causes eosinophilic ascites [2]. There can be significant overlap as multiple layers may be involved in individual patients [2].

Treatment

The goal of therapy of EoE is not only improving the clinical symptoms but also prevention of disease progression and complications. In this regard, understanding the natural history of EoE is of great importance. Prior studies by Dr. Schoepfer and Straumann suggest this is a chronic inflammatory condition and untreated disease can lead to an increased risk of stricture formation over time [37, 38]. These studies suggest that earlier identification and treatment of EoE may prevent progression to fibrostenosis and also advocates for pursuing maintenance therapy to prevent ongoing fibrosis. Practical endpoints of treatment are to improve histologic eosinophilia to below the diagnostic threshold (< 15 eos/hpf), improve the symptoms of dysphagia, achieve endoscopic improvement, and target for esophageal diameter of 16–17 mm [3, 39].

Medical Therapy

Proton Pump Inhibitors

Recent studies have demonstrated that 25–50% of pediatric and adult patients with symptomatic, endoscopic, and histologic findings of EoE that resolved with proton pump inhibitor (PPI) therapy [40]. Further studies have shown that these patients more closely resemble EoE patients than GERD. The benefits of PPI therapy in EoE are likely multifactorial including repair of esophageal epithelial barrier as well as possible direct anti-inflammatory effects on the certain cytokines [33, 36]. PPI therapy has been shown to be an effective, safe and practical initial step in the management of patients with esophageal eosinophilia. Ongoing studies are being undertaken to delineate the mechanism behind this PPI response and understanding this role in EoE.

Topical Corticosteroids

Swallowed, aerosolized fluticasone propionate was first reported to be a successful treatment for EoE in 1998 by Faubion in a series of 4 children [41]. Subsequently, prospective adult

studies extending these early reports and documented symptomatic, endoscopic, and histologic improvement in EoE with swallowed fluticasone [42, 43] and there have been many additional randomized placebo-controlled studies investigating these agents and showing effectiveness [44, 45]. Fluticasone has continued to be a desirable option in both children and adults because of the low systemic bioavailability owing to first-pass hepatic metabolism.

Another topical steroid that has been described is budesonide suspension with the argument that this allows for better esophageal delivery. This was first described by Aceves and Dohil using liquid budesonide mixed with sucralose to create a viscous suspension in a retrospective series of 20 children with EoE [46]. In a subsequent randomized controlled trial of 24 children with EoE, the same authors demonstrated an 87% histologic response (≤ 6 eos/hpf) following 12 weeks of oral viscous budesonide (1–2 mg QD) [47]. These findings have been replicated in adult studies suggesting effectiveness of the oral viscous solution and improvement over inhaled formulations [48]. A recent European study used a novel budesonide effervescent tablet versus placebo showed dramatic results and has led to the approval of this medication for EoE in Europe [49].

Overall, the use of swallowed topical corticosteroids is well tolerated. In terms of adverse effects, esophageal candidiasis occurs in a small proportion and is usually asymptomatic and found at the time of the endoscopy. Prospective studies have demonstrated evidence of adrenal insufficiency in 0–15% of patients treated with long-term topical steroids [50, 51]. This has led to some experts suggesting checking ACTH and serum cortisol to check for adrenal suppression in patients on long-term topical corticosteroids.

Systemic Corticosteroids

One of the first treatment options reported for EoE was systemic corticosteroids. Liacouras et al. who showed 65% symptom resolution and 30% symptom improvement with 100% histologic resolution. However, the eosinophilic inflammation recurred after cessation of the medication as expected [52]. A second pediatric study randomized 80 patients to therapy with either topical fluticasone 220–440 μg PO QID or prednisone 1 mg/kg BID (max 30 mg BID) for 4 weeks [53]. The important findings of this study were that there was no significant improvement in histologic eosinophilia or symptom improvement between the two medications. Due to the plethora of concerning side effects with oral corticosteroids, these medications have fallen out of favor and topical corticosteroids have taken over as the mainstay in medical therapy for EoE.

Montelukast

Montelukast, a leukotriene D4 receptor antagonist, has been studied in small adult cohorts with EoE without overwhelming results. The first study was by Attwood and colleagues who used montelukast in 8 adult patients with an initial dose of 10 mg daily with dose escalation in some up to 100 mg/day. While some patients showed symptomatic improvement, histologic improvement was not observed and significant side effects were noted. Recently, a randomized controlled trial evaluated the efficacy of montelukast for symptom recurrence among 41 patients who responded to induction therapy with topical fluticasone [54]. The study endpoint was symptom remission at week 26. Although a greater proportion of patients on montelukast had sustained symptom response (40%) compared with placebo (24%), this difference was not statistically significant. As a result of these two studies, montelukast is not advised as a primary therapy for EoE.

Cromolyn Sodium

Cromolyn sodium (100 mg QID) was used in a small pediatric case series of EoE. While the study showed a small reduction of esophageal eosinophilia, symptoms did not improve.

Immunomodulators

Azathioprine and 6-mercaptopurine were used in 3 adult EoE patients who were dependent on systemic steroids [55]. One patient had muscular involvement of the esophagus and another had concomitant eosinophilic gastroenteritis. In this small series, tissue eosinophilia normalized with the immunomodulators, however, recurred after discontinuation of the immunomodulator. Another recent study used an antagonist of the chemoattractant receptor-homologous molecule on TH2 cells (CRTH2) which is a prostaglandin D2 receptor. A selective, orally administered CRTH2 antagonist, OC000459 was studied in a randomized controlled trial of 26 adults with EoE treated for 8 weeks [56]. Eosinophil load (mean of 40 hpf from 8 biopsies) significantly but modestly decreased with active treatment from 115 to 73 eos/hpf) but not placebo and there was a modest reduction in physician global assessment of disease activity. Due to the modest reduction in tissue eosinophils, enthusiasm for this agent to replace topical corticosteroids is not present.

Biologic Therapy

Specific mediators involved in the pathogenesis of EoE have been identified in translational studies as well as murine models, most of these are directed against the TH2-mediated inflammatory response. These agents are currently under investigation in the form of clinical trials. Interleukin (IL)-5 is a cytokine produced by TH2 lymphocytes that regulates the proliferation, bone marrow release, activation, and survival of eosinophils. Mepolizumab is a fully humanized monoclonal IgG antibody that binds and

inactivates IL-5 and has demonstrated efficacy in a randomized, double-blind, and placebo-controlled trial in patients with hypereosinophilic syndrome [57]. Less positive results were reported in a randomized, controlled trial of 11 adults with EoE who were either unresponsive or dependent on corticosteroids [58]. While a statistically significant decrease was noted in peripheral blood and esophageal eosinophilia, remission was not achieved in any patient.

Two additional randomized controlled trials of anti-IL-5 therapy were completed in pediatric EoE. Fifty-nine children with EoE were randomized to three doses of mepolizumab (0.55, 2.5, and 10 mg/kg) administered intravenously every 4 weeks over 12 weeks [59]. The primary endpoint defined by the proportion of patients with reduction in eosinophil levels to < 5 eos/hpf was achieved in 8.8%. In one of the largest trials in EoE, three doses of rezlizumab were compared to placebo in 226 children with EoE [60]. Active therapy led to a 59–67% reduction in esophageal eosinophilia compared with 24% with placebo. No difference, however, was seen in the co-primary outcome of physician global assessment with active drug when compared to placebo.

Tumor necrosis factor (TNF) expression has increased expression in EoE; however, in an open label trial in 3 patients, treatment with two doses of infliximab 5 mg/kg did not result in improvement in symptoms, esophageal eosinophilia, or tissue expression of TNF alpha [61].

IL-13 is over-expressed in the esophageal mucosa in EoE patients and induces a substantial number of genes that overlap with the EoE transcriptome. A monoclonal antibody targeting IL-13, QAX576, was examined in a small randomized, placebo-controlled trial of 23 adults with EoE given every 4 weeks for 8 weeks [62]. The study did not meet the primary endpoint based on a 75% reduction in eosinophil density; however, mean eosinophil counts decreased by 60% compared to an increase of 23% seen I the placebo group. A second, humanized monoclonal IgG antibody selective for IL-13, RPC4046, was examined in a randomized, double-blind, and placebo-controlled trial of 99 adults with EoE with weekly subcutaneous administration (180 mg, 360 mg, placebo) for 16 weeks. RPC4046 demonstrated an overall 79% decrease in eosinophil density with both 180 and 360 mg doses, without change with placebo (Hirano UEGW 2016 abstract). In this study, significant improvement in endoscopic features was also evident with RPC4046 but not placebo. Additional biologic studies focusing on a combined anti-IL-13/IL-4R agent are undergoing investigation currently. There is much interest in the development of biologic therapy for EoE due to the lack of currently available FDA-approved medications for these disorders.

Dietary Therapy

Diet Therapies

Diet therapy was first identified as an effective therapeutic approach in children with EoE thereby implicating dietary antigens in the pathogenesis of EoE. Studies have subsequently identified three distinct diet approaches in both children and adults: elemental formula, allergy testing-directed, and empiric elimination diets. Diet therapy has emerged as a non-pharmacologic, first-line approach to disease management in both adults and children with EoE.

Elemental Diet

The first study to show improvement in EoE after treatment with an elemental or amino acid-based diet in EoE was a small study in 10 children with suspected GERD and esophageal eosinophilia [63]. In this landmark study, administration of an elemental diet led to substantial improvement of both symptoms and esophageal eosinophilic inflammation. This effect of a diet devoid of dietary protein implicated that food allergy was responsible for this eosinophilic inflammation. Subsequently, uncontrolled pediatric series from several institutions have confirmed an overall 90% histologic remission in EoE. Two prospective adult studies of elemental diet reported a lower histologic response in approximately 75%, suggesting that non-food allergens may be playing a role in adults with EoE [64]. However, the adult trials were both limited by a 4-week treatment period, a high patient drop out due to palatability of the elemental formula, and non-adherence to the diet protocol.

Retrospective cohort studies as well as a meta-analysis have reported superiority of the elemental diet over either the empiric elimination or allergy testing-directed diet approaches discussed below [65]. Limitations of this approach include the palatability of the formula and the lack of meal variety. While the goal of diet therapy is the elimination of specific food triggers, another major shortcoming of the elemental diet approach is the length of time and number of endoscopies required to identify specific triggers during food reintroduction. This formula can also be costly for many patients and currently most insurance companies do not cover the cost of this intervention.

Allergy Testing-Directed Elimination Diet

Allergy testing-directed dietary therapy has the conceptual appeal of identification of trigger foods, thereby streamlining the empiric elimination and reintroduction process. A large, retrospective study in children utilized a combination of skin prick and atopy patch testing of 23 different foods to formulate an elimination diet and demonstrated a 72% histologic remission. Subsequent pediatric series have reported response rates

of 53–65% using allergy testing-directed diets but adult series have demonstrated substantially lower response rates. A prospective trial utilizing a combination of prick and patch testing in 22 adults with EoE achieved only a 26% remission [66]. Another prospective study of 50 adults with EoE found a predictive value of 13% for skin prick testing, suffering from both false positive and false negative test results [67].

Current studies do not support the widespread utilization of IgE-based allergy testing in EoE for the intent of identification of causative foods as current studies have failed to identify a major role for IgE in the immune pathogenesis of EoE. Novel immunologic assays to accurately identify food triggers in EoE are needed.

Empiric Elimination Diet

Given the difficulties with following an elemental diet and the variable response rates to skin testing to detect specific foods triggers in EoE, a number of studies have used an empiric elimination diet. The foods eliminated in this approach exclude the most common food allergens. The six-food elimination diet (SFED) eliminates cow's milk, egg, soy, wheat, peanuts/tree nuts, and fish/shellfish. First studied in children, the SFED has shown consistent effectiveness in the treatment of EoE. Kagalwalla et al. first demonstrated histologic remission in 74% of children treated with SFED [68]. Similar histologic response rates were found in prospective adult EoE studies from the USA and Spain [67, 69]. In the Spanish study, patients were followed for up to 3 years and remained in remission while avoiding their specific trigger foods. In both adult and pediatric populations, milk, wheat, egg, and soy have been identified as the most common food triggers for EoE. Empiric elimination of single (milk), two (milk and wheat), or four food groups are being actively investigated as alternatives to the SFED [66].

The empiric elimination diet has demonstrated a consistently high degree of effectiveness while allowing for continued consumption of a restricted number table foods that include fruits, vegetables, meat, poultry, rice, beans, and alternative grains such as quinoa. In patients demonstrating histologic response, eliminated food groups are sequentially reintroduced while monitoring for disease recurrence using endoscopic biopsies. The current requirement for repeated endoscopies during the reintroduction is a considerable drawback to this approach. Practically, the elimination diet can be onerous due to concerns with dietary contamination, psychosocial impact of restricted diets, and costs of allergen-free food products [70]. Incorporation of a dietician or allergist in patient education and dietary monitoring likely improves the success of the elimination diet approach. A number of non-invasive methods to sample the esophagus to detect disease activity without endoscopy are actively being investigated [71].

Practical Implementation of Diet Therapy in the Management of EoE

As there are no controlled studies comparing dietary with steroid therapy in EoE, the choice of treatment approach is currently individualized, based on a discussion with the patient. The dietary approach does require a highly motivated patient and physician as well as available dietary resources. Studies across medical disciplines have demonstrated the widespread patient acceptance for the use of diet interventions to manage medical conditions. Many patients find the concept of treating their disease by eliminating an inciting food allergen more appealing than taking a drug to counteract the downstream inflammatory response. Furthermore, when discussing the dietary approach, it is important to emphasize that the strict elimination of multiple foods is for a limited time and the goal is to ultimately reintroduce food to help liberalize the foods being eliminated. The long-term goal is the identification and continued elimination of one or two food groups. Once a food trigger has been identified, occasional dietary "indiscretion" is likely acceptable, in distinction to patients with food associated anaphylaxis. Small case series have described tolerance to baked milk in patients with cow's milk-mediated EoE [72]. Dietary therapy has been shown to be an effective long-term treatment in EoE.

Endoscopic Therapy

Esophageal Dilation

Esophageal dilation is a therapy which has primarily been used in adult EoE patients with strictures. This approach when done conservatively is safe with a low rate of complications [73, 74]. While diet and topical corticosteroids can treat the inflammatory nature of this disease, dilation treats the fibrostenotic and structural alterations. Several case series suggest esophageal dilation is well tolerated by patients and provides long-lasting symptomatic relief despite having no effect on mucosal eosinophilia [75]. Esophageal dilation offers an important adjunct to topical corticosteroids and/or dietary therapy and may be considered in patients unresponsive to initial medical or diet therapy. Attempts are made to target for an esophageal diameter of 16–17 mm to help avoid food impactions. This may need to be accomplished over several dilations sessions depending on the patients' initial starting diameter. Although effective at relieving dysphagia, esophageal dilation can carry a risk of post procedural chest pain and uncommon but significant complications that should be discussed with patients prior to undergoing dilation.

Conclusion

EoE is an emerging clinical problem and treatment is effective at reducing symptoms as well as tissue eosinophilia. Although

the risk of not treating an asymptomatic or minimally symptomatic patient is currently unknown, sequelae including fibrosis, narrow caliber esophagus, and stricture formation are well described. Furthermore, symptoms that impair quality of life as well as complications of malnutrition, food impaction, and esophageal perforation have been reported. The degree to which the structural alterations are reversible with medical or dietary therapy is uncertain. Spontaneous remission appears to occur infrequently.

Summary of Approach to the Care of Patients with EoE

A clinical approach to EoE begins with an increased awareness of the disease and its manifestations. The diagnosis should be considered in a child presenting with vomiting, food refusal, and abdominal pain, especially if the symptoms have not improved with empiric therapeutic trials of acid suppression. The diagnosis should be strongly entertained in both children and adults with dysphagia and food impactions, regardless of the presence or absence of heartburn. Other presentations include atypical chest pain and heartburn that do not respond to empiric PPI therapy.

- Once the presence of increased esophageal eosinophilia (generally greater than 15 eos/hpf) has been demonstrated, patients should undergo an 8-week trial of acid suppression therapy to see if this results in clinical and histologic improvement. This recommendation is based on observations that some patients with esophageal eosinophilia respond both symptomatically and histologically to PPI therapy. If symptoms and eosinophilia persist despite adequate acid suppression, the various targeted treatment options for EoE are discussed with patients. The most common treatment approaches are medical therapy with swallowed topical corticosteroids or dietary therapy with empiric elimination diet or in severe cases, elemental diet. Allergy consultation has been useful to help treat patients with other allergic diathesis and in some cases, monitored for allergic symptoms during food reintroduction. The role of treatment of aeroallergens (e.g., allergen avoidance, nasal steroids, and immunotherapy) in EoE patients remains speculative at this time. Esophageal dilation is performed cautiously for strictures that do not respond to medical or dietary treatment. Patients may benefit from maintenance therapy given the high rates of symptomatic recurrence of EoE in both children and adults.

Eosinophilic Gastroenteritis

Eosinophilic gastroenteritis belongs to a group of diseases that includes esophagitis (EoE), gastritis (EG), esophagitis/gastritis/enteritis (EGE), enteritis (EE), and colitis (EC). These are collectively referred to as "eosinophilic gastrointestinal disorders." Nomenclature and the specific presentation of EGID depend on the location (organ) and extent (layer invasion) of eosinophilic infiltration. Eosinophilic esophagitis has been discussed above. Less common disorders include eosinophilic gastritis (EG) where eosinophils are isolated to the stomach. If eosinophils are located more diffusely (esophagus, stomach, and/or small intestine), we label the illness, eosinophilic gastroenteritis (EGE). Eosinophils isolated solely to the intestine are called eosinophilic enteritis and the rarest of these disorders is eosinophilic colitis (EC) where eosinophils are isolated to the colon. Eosinophils may infiltrate the mucosal layer, the muscular layer, or the subserosal layer of the GI tract [2]. Symptoms vary based on the layer of bowel wall affected.

Epidemiology There are limited data on the prevalence of eosinophilic gastroenteritis (EGE). Based on recent insurance database review, the prevalence of EG in the USA is estimated to be 6.3/100.000, EGE 8.4/100,000, and EC 3.3/100,000. Compared to estimates of EoE ranging from 4.5–10.4/10,000, non-EoE EGIDs are quite rare [76]. EGE can affect patients of any age, but typically presents in the third through fifth decade and has a peak age of onset in the third decade [77–79]. A slight male predominance has previously been reported.

Pathogenesis The pathogenesis of eosinophilic gastroenteritis (EGE) is not well understood. Multiple epidemiologic and clinical features suggest an allergic component. In addition, patients with EGE have elevated serum immunoglobulin E (IgE) levels [80]. Although the role of food allergy in EGE has not been as clearly defined as with eosinophilic esophagitis, several reports have described an improvement in EGE disease activity with an elemental or elimination diet [81, 82]. In allergic EGE patients, a population of interleukin-5 (IL-5) expressing food allergen-specific T helper 2 (Th2) cells have been identified suggesting that food exposure may activate and drive the differentiation of IL-5 + Th2 cells in EGE resulting in eosinophilic infiltration into the gut [83]. More recent studies investigating the gene expression and cytokine profile in EG have shown that gastric tissue from patients with EG exhibits a conserved pattern of cytokine gene expression revealing an increased expression of IL-4, IL-5, IL-17, IL-33, IL-13, and ccl26 similar to that seen in EoE [84].

Clinical Manifestations The entire gastrointestinal tract from esophagus to colon can be affected in patients with eosinophilic gastroenteritis (EGE). While studies have suggested that EGE has a predilection for the distal antrum and proximal small bowel, this may reflect the fact that these areas are more easily sampled during conventional endoscopy rather than distal small bowel. As many as 50% of patients with EGE have a history of atopy including asthma, defined food

sensitivities, eczema, or rhinitis [77, 80, 85]. The clinical features of EGE are related to the location, extent, and layer(s) of bowel with eosinophilic infiltration.

Mucosal Variant This is the most common variant of eosinophilic gastroenteritis where infiltration is limited to the mucosa of the gut. This can produce a variety of symptoms that depend upon the area of the gastrointestinal tract that is involved. In a retrospective study of 40 patients with mucosal EGE, the most common symptoms were abdominal pain, nausea, vomiting, early satiety, and diarrhea [77]. Only one third of patients had a weight loss of 2.4 kg or more. Patients with diffuse small bowel disease can develop malabsorption, protein-losing enteropathy, and failure to thrive [86, 87].

Muscular Layer Variant Eosinophilic infiltration of the muscle layer of the gastrointestinal tract results in wall thickening and impaired motility and often rigidity of this portion of the GI tract. Patients may present with symptoms of intestinal obstruction, including nausea, vomiting, abdominal distention, and gastric outlet obstruction. Patients with pseudo-achalasia from submucosal involvement or an esophageal stricture may present with dysphagia and regurgitation of undigested food. Eosinophilic infiltration may result in perforation or obstruction of the gastric outlet, small bowel, or rarely the colon [77, 86, 87].

Subserosal Disease This is the rarest form of eosinophilic gastroenteritis. Patients with subserosal EGE present with isolated ascites or ascites in combination with symptoms characteristic of mucosal or muscular EGE [77]. An eosinophilic pleural effusion may also be present [87]. Typically eosinophilia in the ascetic or pleural fluid is markedly elevated.

Laboratory Findings Various laboratory tests may be abnormal in patients with eosinophilic gastroenteritis (EGE). Peripheral eosinophil counts are usually elevated in 80% of patients with EGE [77]. Peripheral eosinophil counts range from 5 to 35% with an average absolute eosinophil count of 1000 cells/μL [88]. Mucosal and subserosal EGE are characterized by higher eosinophil counts as compared with EGE that involves the muscular layer. Patients with malabsorption due to mucosal EGE may have impaired mucosal permeability resulting in protein-losing enteropathy and hypoalbuminemia. Impaired iron absorption in combination with occult gastric bleeding from erosions/ulcerations can be present [86, 87, 89]. In some cases, an abnormal D-xylose test due to carbohydrate malabsorption and increased fecal fat excretion with prolonged prothrombin time can also be seen. Increased mucosal permeability may result in protein-losing enteropathy and resultant hypoalbuminemia [86, 87, 89]. In 25% of cases, an elevated erythrocyte sedimentation rate may be seen [77]. Serum immunoglobulin E (IgE) levels in these patients are typically markedly elevated.

Imaging Findings Various abnormalities may be seen on dedicated GI imaging depending on the severity of the disease. Barium studies, dedicated, abdominal computed tomography (CT) scan, or magnetic resonance imaging (MRI) of the gastrointestinal tract may reveal thickening or nodularity in the antrum and thickened or "saw-tooth" mucosa in the small bowel [90]. Imaging in patients with muscular involvement may reveal bowel stricturing and decreased luminal diameter most often seen in the distal antrum or proximal small bowel. Despite these abnormalities, these findings are neither sensitive nor specific for eosinophilic gastroenteritis (EGE) and a normal imaging scan does not necessarily rule out these disorders.

Evaluation Eosinophilic gastroenteritis (EGE) should be suspected in a patient with abdominal pain, nausea, vomiting, early satiety, diarrhea, weight loss, or ascites associated with peripheral eosinophilia (eosinophil count > 500 eosinophils/μL in the peripheral blood), and/or a history of food allergy or intolerance. Evaluation of a patient with suspected EGE serves to exclude other causes of eosinophilia and establish the diagnosis of EGE. The diagnosis is made during endoscopy and numerous biopsies should be taken in the area most heavily involved and the pathologist should be notified of the clinical suspicion of this diagnosis. The diagnosis of EGE is based on the presence of eosinophilic infiltration of the gastrointestinal tract on biopsy and/or eosinophilic ascitic fluid, lack of involvement of other organs, and absence of other causes of intestinal eosinophilia particularly infection. While consensus guidelines on the histologic criteria for non-EoE EGID are not as well defined, currently accepted criteria include > 30 eosinophils in the stomach and/or duodenum [26].

Laboratory evaluation: Laboratory evaluation should include a complete blood count with differential to determine the absolute eosinophil count. In addition, we also obtain serum electrolytes, albumin, serum iron, iron-binding capacity, ferritin, and markers of inflammation, erythrocyte sedimentation rate, or C-reactive protein. As eosinophilia can be caused by a number of conditions other than EGE, in patients with peripheral eosinophilia, additional testing and investigation may be helpful. These may include some or all of the following tests depending on the suspicion for other etiologies: peripheral smear review to r/o dysplastic features, serum chemistries for adrenal dysfunction, serum b12, serum immunoglobulin subsets, as evidence of immune deficiency (immunoglobulin E [IgE], immunoglobulin M [IgM], immunoglobulin G [IgG]), human immunodeficiency virus (HIV) serology, serum tryptase (elevated in systemic mastocytosis and some neoplastic hypereosinophilic syndromes), and flow cytometry for lymphocyte subsets (may show clonality in lymphoid lymphoma or leukemia. Stool studies and serologic studies should be performed to exclude a parasitic infection including microscopy for ova and parasites and serologies for *Strongyloides* and *Toxocara* species. In patients with ascites,

ascitic fluid analysis should include cell count with differential, Gram stain, culture, acid fast bacillus (AFB) stain, fungal and mycobacterial cultures, and cytology. Although there are no established criteria for ascitic fluid eosinophilia, studies have reported markedly elevated eosinophil counts (up to 88% eosinophilia) in patients with EGE [86].

Endoscopy and Biopsy Endoscopic findings of mucosal disease are nonspecific and include nodular or polypoid gastric mucosa, erythema, or erosions (see Fig. 3). The diagnosis of mucosal EGE is established by the presence of more than the number of expected eosinophils on microscopic examination of biopsies of the gastrointestinal tract. As there is no defined cut-off for the number of eosinophils/high power field to diagnose EGE, the diagnosis should be confirmed by an experienced gastrointestinal pathologist to assess if the number of eosinophils is more than expected for a particular area. Because the stomach and duodenum are the most commonly affected sites, endoscopic evaluation is typically limited to the upper gastrointestinal tract. In patients with significant diarrhea, a colonoscopy with investigation of the terminal ileum is undertaken. Since EGE can be patchy in patients with mucosal disease, multiple biopsies should be taken in both normal and abnormal mucosa to help increase sensitivity. However, it is important to note that mucosal biopsies are normal in patients with muscular or subserosal disease and sometimes if these variants are suspected, full thickness biopsies are necessary to establish this diagnosis.

Disease Course The natural history of eosinophilic gastroenteritis (EGE) is not well understood as studies are limited to case reports and small series. While some untreated patients with EGE have been reported to remit spontaneously, other patients may progress to severe malabsorption and malnutrition and it is not clear which patients fall into which category. With treatment, in a small percentage of patients, EGE may remit while others patients have periodic flares months to years after initial presentation requiring maintenance therapy. Long-term studies are desperately needed to better understand the natural history of these disorders.

Management Treatment of eosinophilic gastroenteritis (EGE) is based on limited evidence and varies based upon the severity of symptoms and the presence of malabsorption. Similar to EoE, both medication and diet therapy have been investigated.

Medical Therapy

Glucocorticoids A trial of prednisone (typically 20 to 40 mg/day) has been previously used as initial therapy for EGID. However, evidence to support the use of glucocorticoids is limited to small series of patients [91, 92]. Improvement in symptoms usually occurs within 2 weeks regardless of the layer of bowel involved. Prednisone should then be tapered rapidly over the next 2 weeks. The goal of glucocorticoid therapy is to use the minimum dose needed to ameliorate severe EGE symptoms, rather than use high doses to control tissue eosinophilia, as fibrosis is much less common in EGE as compared with eosinophilic esophagitis, and high doses of glucocorticoids are associated with systemic side effects. Similar to inflammatory bowel disease, some patients require more prolonged therapy with gradual tapering (up to several months) to produce complete resolution of symptoms. Patients not responding to oral prednisone should be treated with equivalent intravenous glucocorticoids. Patients who fail to respond to intravenous glucocorticoids should undergo careful reevaluation to rule out the presence of an underlying infection or alternate diagnoses including Crohn's disease. Successful transition from oral, conventional glucocorticoids to budesonide (nonenterically coated) has been reported in patients with EGE involving the gastric antrum and small intestine [93–95]. It should be noted that the formulation of budesonide available for gastrointestinal use is in controlled ileal release capsules, so case reports suggest that such budesonide formulations have been used off-label to target the upper gastrointestinal tract by dissolving the controlled release capsules in water or crushing them and mixing them with applesauce.

Other Therapies Several other approaches have been described in case reports or small series to treat recurrent or

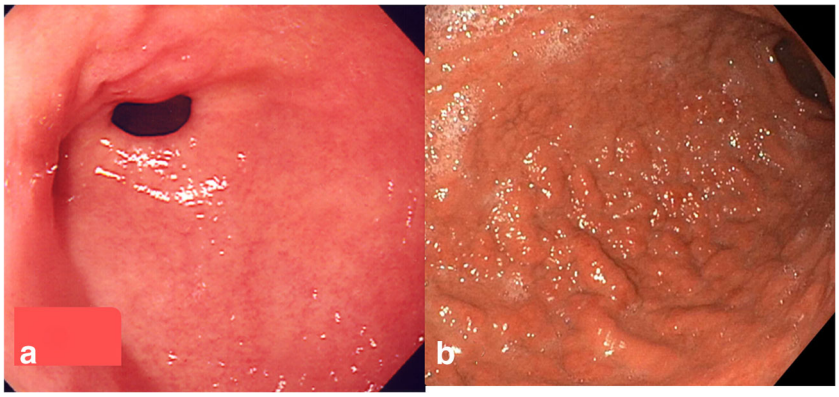

Fig. 3 Endoscopic image of eosinophilic gastroenteritis. **a** Normal appearance of the antrum. **b**. Endoscopic image of patient with mucosal variant of eosinophilic gastroenteritis demonstrating erythema, nodularity, and thickened folds. Image courtesy of Dr. Gonsalves

refractory symptoms. However, none of these agents can be recommended for routine use based on limited available data. Cromolyn (800 mg/day in four divided doses) has been effective for short- and long-term management of EGE in some case reports, but conflicting results have also been reported [96]. Cromolyn works by preventing the release of mast cell mediators, including histamine, platelet-activating factor, and leukotrienes, and is also thought to reduce absorption of antigens by the small intestine. Ketotifen is an H1-antihistamine and mast cell stabilizer that has been associated with an improvement in clinical symptoms and tissue eosinophilia in small series of patients [97]. In adults, it is administered at a starting dose of 1 mg at night and increased to 2 to 4 mg/day for 1 to 4 months. Although ketotifen is available in some countries, it is not available in the USA. Humanized anti-IL-5 antibody treatment was associated with reduced peripheral and tissue eosinophil counts in a preliminary report of four patients, but had no effect on symptoms [98]. In addition, rebound eosinophilia has been observed after treatment is discontinued. Omalizumab is an anti-IgE monoclonal antibody that has been associated with a significant improvement in symptoms and measures of IgE-mediated allergy in a case series that included nine patients [78]. Tissue eosinophilia was reduced, but the reduction was not statistically significant.

Dietary Therapy Dietary therapy has been shown to be effective in small case series [99]. In patients who are symptomatic or have evidence of malabsorption, attempt at an empiric elimination diet, a six-food elimination diet, or an elemental diet can be undertaken in a similar approach to that of EoE. Based on studies in eosinophilic esophagitis, such diets should be undertaken for a minimum of 4 to 6 weeks. Whether this approach will yield similar results in EGE is yet to be determined as there are no prospective studies using this approach. Similar to the approach in EoE, patients on an elemental diet are placed on an elemental formula, which eliminates all potential food allergens. The empiric elimination diet consists of avoidance of foods that most commonly cause immediate hypersensitivity in a population. The six-food elimination diet is the most commonly used empiric elimination diet. Specific foods that are avoided in the six-food elimination diet include soy, wheat, egg, milk, peanut/tree nuts, and fish/shellfish [67, 68]. Similar to EoE, the main limitation of dietary therapy is patient compliance and therefore it should be used after an extensive discussion with motivated patients and under the guidance of a dietitian trained in eosinophilic gastrointestinal disorders. A repeat endoscopy with biopsies when there is uncertainty regarding the response to treatment and/or degree of ongoing disease activity is typically undertaken. If the dietary changes are successful at reducing symptoms and either peripheral eosinophilia or tissue eosinophilia, foods can be added back slowly in a systematic fashion from least allergenic to most allergenic. Preliminary results of a trial in adults with EGE demonstrated clinical remission with a 6-week course of dietary elimination. In this study, three of seven adults undergoing an empiric six-food elimination diet and all six adults undergoing elemental diet had significant reduction in symptoms, complete histologic remission, endoscopic improvement, and normalization of peripheral eosinophilia within six weeks [82]. Similar to EoE, at present, there is no evidence to support routine food allergy testing of EGE patients for use in clinical decision-making.

Summary

Eosinophilic gastrointestinal disorders are a group of inflammatory disorders characterized by eosinophilic infiltration of the gut leading to clinical symptoms and organ dysfunction. These disorders include eosinophilic esophagitis, eosinophilic gastritis, eosinophilic gastroenteritis, eosinophilic enteritis, and eosinophilic colitis. The pathophysiology of these disorders is thought to be immune-mediated food antigen-driven disorders characterized by a strong th2-linked genetic signature. These disorders are chronic inflammatory conditions which respond to both medical and dietary therapy and maintenance therapy is advocated to prevent chronic complications. Natural history studies of eosinophilic esophagitis suggest that untreated disease leads to increased risk of stricture formation. Natural history studies are needed in non-EoE EGIDs to better understand disease progression and pathogenesis.

Compliance with Ethical Standards

Conflict of Interest The author declares that she is an author for Up-to-Date, Advisory Board for Allakos.

Ethical Approval This article does not contain any studies with human participants or animals performed by the author.

Reference

1. Spergel JM, Book WM, Mays E, Song L, Shah SS, Talley NJ, Bonis PA (2011) Variation in prevalence, diagnostic criteria, and initial management options for eosinophilic gastrointestinal diseases in the United States. J Pediatr Gastroenterol Nutr 52:300–306
2. Zhang L, Duan L, Ding S, Lu J, Jin Z, Cui R, McNutt M, Wang A (2011) Eosinophilic gastroenteritis: clinical manifestations and morphological characteristics, a retrospective study of 42 patients. Scand J Gastroenterol 46:1074–1080
3. Dellon ES, Gonsalves N, Hirano I, Furuta GT, Liacouras CA, Katzka DA, American College of Gastroenterology (2013) ACG clinical guideline: evidenced based approach to the diagnosis and management of esophageal eosinophilia and eosinophilic esophagitis (EoE). Am J Gastroenterol 108:679–692 quiz 693

4. Erwin EA, Asti L, Hemming T, Kelleher KJ (2012) A decade of hospital discharges related to eosinophilic esophagitis. J Pediatr Gastroenterol Nutr 54:427–429
5. Soon IS, Butzner JD, Kaplan GG, deBruyn JCC (2013) Incidence and prevalence of eosinophilic esophagitis in children. J Pediatr Gastroenterol Nutr 57:72–80
6. Noel RJ, Putnam PE, Rothenberg ME (2004) Eosinophilic esophagitis. N Engl J Med 351:940–941
7. Hruz P, Straumann A, Bussmann C, Heer P, Simon HU, Zwahlen M, Beglinger C, Schoepfer AM, Swiss EoE study group (2011) Escalating incidence of eosinophilic esophagitis: a 20-year prospective, population-based study in Olten County, Switzerland. J Allergy Clin Immunol 128:1349–1350 e5
8. Giriens B, Yan P, Safroneeva E, Zwahlen M, Reinhard A, Nydegger A, Vavricka S, Sempoux C, Straumann A, Schoepfer AM (2015) Escalating incidence of eosinophilic esophagitis in Canton of Vaud, Switzerland, 1993-2013: a population-based study. Allergy 70: 1633–1639
9. Ronkainen J, Talley NJ, Aro P, Storskrubb T, Johansson SE, Lind T, Bolling-Sternevald E, Vieth M, Stolte M, Walker MM, Agreus L (2007) Prevalence of oesophageal eosinophils and eosinophilic oesophagitis in adults: the population-based Kalixanda study. Gut 56:615–620
10. Bach J-F (2001) Protective role of infections and vaccinations on autoimmune disease. J Autoimmun 3:347–353
11. Furuta GT, Liacouras CA, Collins MH, Gupta SK, Justinich C, Putnam PE, Bonis P, Hassall E, Straumann A, Rothenberg ME, First International Gastrointestinal Eosinophil Research Symposium (FIGERS) Subcommittees (2007) Eosinophilic esophagitis in children and adults: a systematic review and consensus recommendations for diagnosis and treatment. Gastroenterology 133:1342–1363
12. Koutlas NTES, Rusin S, Perjar I, Hollyfield J, Woosley JT, Shaheen NJ, Dellon S (2018) Impact of smoking, alcohol consumption, and NSAID use on risk for and phenotypes of eosinophilic esophagitis. Dis Esophagus 31:1–7
13. Jensen ETKJ, Martin LJ, Rothenberg ME, Dellon ES (2018) Prenatal, intrapartum, and postnatal factors are associated with pediatric eosinophilic esophagitis. J Allergy Clin Immunol 141:214–222
14. Liacouras CA, Spergel JM, Ruchelli E, Verma R, Mascarenhas M, Semeao E, Flick J, Kelly J, Brown–Whitehorn T, Mamula P, Markowitz JE (2005) Eosinophilic esophagitis: a 10-year experience in 381 children. Clin Gastroenterol Hepatol 3:1198–1206
15. Patel SM, Falchuk KR (2005) Three brothers with dysphagia caused by eosinophilic esophagitis. Gastrointest Endosc 61:165–167
16. Meyer GW (2005) Eosinophilic esophagitis in a father and a daughter. Gastrointest Endosc 61:932
17. Alexander ES, Martin LJ, Collins MH, Kottyan LC, Sucharew H, He H, Mukkada VA, Succop PA, Abonia JP, Foote H, Eby MD, Grotjan TM, Greenler AJ, Dellon ES, Demain JG, Furuta GT, Gurian LE, Harley JB, Hopp RJ, Kagalwalla A, Kaul A, Nadeau KC, Noel RJ, Putnam PE, von Tiehl KF, Rothenberg ME (2014) Twin and family studies reveal strong environmental and weaker genetic cues explaining heritability of eosinophilic esophagitis. J Allergy Clin Immunol 134:1084–1092 e1
18. Blanchard C, Wang N, Stringer KF, Mishra A, Fulkerson PC, Abonia JP, Jameson SC, Kirby C, Konikoff MR, Collins MH, Cohen MB, Akers R, Hogan SP, Assa'ad AH, Putnam PE, Aronow BJ, Rothenberg ME (2006) Eotaxin-3 and a uniquely conserved gene-expression profile in eosinophilic esophagitis. J Clin Invest 116:536–547
19. Gonsalves N (2014) Distinct features in the clinical presentations of eosinophilic esophagitis in children and adults: is this the same disease? Dig Dis 32:89–92
20. Straumann A, Aceves SS, Blanchard C, Collins MH, Furuta GT, Hirano I, Schoepfer AM, Simon D, Simon HU (2012) Pediatric and adult eosinophilic esophagitis: similarities and differences. Allergy 67:477–490
21. Assa'ad AH, Putnam PE, Collins MH et al (2007) Pediatric patients with eosinophilic esophagitis: an 8-year follow-up. J Allergy Clin Immunol 119:731–738
22. Gonsalves N, Policarpio-Nicolas M, Zhang Q, Rao MS, Hirano I (2006) Histopathologic variability and endoscopic correlates in adults with eosinophilic esophagitis. Gastrointest Endosc 64:313–319
23. Collins MH, Martin LJ, Alexander ES et al (2016) Newly developed and validated eosinophilic esophagitis histology scoring system and evidence that it outperforms peak eosinophil count for disease diagnosis and monitoring. Dis Esophagus
24. Sgouros SN, Bergele C, Mantides A (2006) Eosinophilic esophagitis in adults: a systematic review. Eur J Gastroenterol Hepatol 18: 211–217
25. Hirano I, Moy N, Heckman MG, Thomas CS, Gonsalves N, Achem SR (2013) Endoscopic assessment of the oesophageal features of eosinophilic oesophagitis: validation of a novel classification and grading system. Gut 62:489–495
26. Collins MH (2014) Histopathologic features of eosinophilic esophagitis and eosinophilic gastrointestinal diseases. Gastroenterol Clin N Am 43:257–268
27. Aceves SS (2011) Tissue remodeling in patients with eosinophilic esophagitis: what lies beneath the surface? J Allergy Clin Immunol 128:1047–1049
28. Fox VL, Nurko S, Teitelbaum JE, Badizadegan K, Furuta GT (2003) High-resolution EUS in children with eosinophilic “allergic” esophagitis. Gastrointest Endosc 57:30–36
29. Carlson DA, Hirano I, Zalewski A, Gonsalves N, Lin Z, Pandolfino JE (2017) Improvement in esophageal distensibility in response to medical and diet therapy in eosinophilic esophagitis. Clin Transl Gastroenterol 8:119
30. Liacouras CA, Furuta GT, Hirano I, Atkins D, Attwood SE, Bonis PA, Burks AW, Chehade M, Collins MH, Dellon ES, Dohil R, Falk GW, Gonsalves N, Gupta SK, Katzka DA, Lucendo AJ, Markowitz JE, Noel RJ, Odze RD, Putnam PE, Richter JE, Romero Y, Ruchelli E, Sampson HA, Schoepfer A, Shaheen NJ, Sicherer SH, Spechler S, Spergel JM, Straumann A, Wershil BK, Rothenberg ME, Aceves SS (2011) Eosinophilic esophagitis: updated consensus recommendations for children and adults. J Allergy Clin Immunol 128:3–20 e6 quiz 21-2
31. Fujiwara Y, Sugawa T, Tanaka F, Tatsuwaki H, Okuyama M, Hayakawa T, Yamamori K, Wada R, Ohtani K, Uno H, Tanigawa T, Watanabe Y, Tominaga K, Watanabe T, Takaishi O, Saeki Y, Nebiki H, Oshitani N, Sato H, Arakawa T (2012) A multicenter study on the prevalence of eosinophilic esophagitis and PPI-responsive esophageal eosinophilic infiltration. Intern Med 51: 3235–3239
32. Gomez Torrijos E, Rodriguez Sanchez J, Castro Jimenez A, Garcia Rodriguez R, Feo-Brito F, Molina-Infante J (2015) Proton pump inhibitor-responsive oesophageal eosinophilia (PPI-REE): characteristics of a Spanish population in Central Spain. Clin Exp Allergy 45:1367–1369
33. Molina-Infante J, Ferrando-Lamana L, Ripoll C et al (2011) Esophageal eosinophilic infiltration responds to proton pump inhibition in most adults. Clin Gastroenterol Hepatol 9:110–117
34. Dellon ES, Speck O, Woodward K, Covey S, Rusin S, Gebhart JH, Chen X, Woosley JT, Shaheen NJ (2014) Markers of eosinophilic inflammation for diagnosis of eosinophilic esophagitis and proton pump inhibitor-responsive esophageal eosinophilia: a prospective study. Clin Gastroenterol Hepatol 12:2015–2022

35. Eluri S, Dellon ES (2015) Proton pump inhibitor-responsive oesophageal eosinophilia and eosinophilic oesophagitis: more similarities than differences. Curr Opin Gastroenterol 31:309–315
36. Cheng E, Zhang X, Huo X, Yu C, Zhang Q, Wang DH, Spechler SJ, Souza RF (2013) Omeprazole blocks eotaxin-3 expression by oesophageal squamous cells from patients with eosinophilic oesophagitis and GORD. Gut 62:824–832
37. Schoepfer AM, Safroneeva E, Bussmann C et al (2013) Delay in diagnosis of eosinophilic esophagitis increases risk for stricture formation in a time-dependent manner. Gastroenterology 145:1230–1236 e1–2
38. Straumann A, Spichtin HP, Grize L, Bucher KA, Beglinger C, Simon HU (2003) Natural history of primary eosinophilic esophagitis: a follow-up of 30 adult patients for up to 11.5 years. Gastroenterology 125:1660–1669
39. Kwiatek MA, Hirano I, Kahrilas PJ, Rothe J, Luger D, Pandolfino JE (2011) Mechanical properties of the esophagus in eosinophilic esophagitis. Gastroenterology 140:82–90
40. Kia L, Hirano I (2015) Distinguishing GERD from eosinophilic oesophagitis: concepts and controversies. Nat Rev Gastroenterol Hepatol 12:379–386
41. Faubion WA Jr, Perrault J, Burgart LJ, Zein NN, Clawson ML, Freese DK (1998) Treatment of eosinophilic esophagitis with inhaled corticosteroids. J Pediatr Gastroenterol Nutr 27:90–93
42. Remedios M, Campbell C, Jones DM, Kerlin P (2006) Eosinophilic esophagitis in adults: clinical, endoscopic, histologic findings, and response to treatment with fluticasone propionate. Gastrointest Endosc 63:3–12
43. Lucendo AJ, Pascual-Turrion JM, Navarro M et al (2007) Endoscopic, bioptic, and manometric findings in eosinophilic esophagitis before and after steroid therapy: a case series. Endoscopy 39:765–771
44. Konikoff MR, Noel RJ, Blanchard C, Kirby C, Jameson SC, Buckmeier BK, Akers R, Cohen MB, Collins MH, Assa'ad AH, Aceves SS, Putnam PE, Rothenberg ME (2006) A randomized, double-blind, placebo-controlled trial of fluticasone propionate for pediatric eosinophilic esophagitis. Gastroenterology 131:1381–1391
45. Alexander JA, Jung KW, Arora AS, Enders F, Katzka DA, Kephardt GM, Kita H, Kryzer LA, Romero Y, Smyrk TC, Talley NJ (2012) Swallowed fluticasone improves histologic but not symptomatic response of adults with eosinophilic esophagitis. Clin Gastroenterol Hepatol 10:742–749 e1
46. Aceves SS, Bastian JF, Newbury RO, Dohil R (2007) Oral viscous budesonide: a potential new therapy for eosinophilic esophagitis in children. Am J Gastroenterol 102:2271–2279 quiz 2280
47. Dohil R, Newbury R, Fox L, Bastian J, Aceves S (2010) Oral viscous budesonide is effective in children with eosinophilic esophagitis in a randomized, placebo-controlled trial. Gastroenterology 139:418–429
48. Straumann A, Conus S, Degen L et al (2010) Budesonide is effective in adolescent and adult patients with active eosinophilic esophagitis. Gastroenterology 139:1526–1537 1537 e1
49. Miehlke S, Hruz P, Vieth M, Bussmann C, von Arnim U, Bajbouj M, Schlag C, Madisch A, Fibbe C, Wittenburg H, Allescher HD, Reinshagen M, Schubert S, Tack J, Müller M, Krummenerl P, Arts J, Mueller R, Dilger K, Greinwald R, Straumann A (2016) A randomised, double-blind trial comparing budesonide formulations and dosages for short-term treatment of eosinophilic oesophagitis. Gut 65:390–399
50. Golekoh MC, Hornung LN, Mukkada VA, Khoury JC, Putnam PE, Backeljauw PF (2016) Adrenal insufficiency after chronic swallowed glucocorticoid therapy for eosinophilic esophagitis. J Pediatr 170:240–245
51. Butz BK, Wen T, Gleich GJ, Furuta GT, Spergel J, King E, Kramer RE, Collins MH, Stucke E, Mangeot C, Jackson WD, O'Gorman M, Abonia JP, Pentiuk S, Putnam PE, Rothenberg ME (2014) Efficacy, dose reduction, and resistance to high-dose fluticasone in patients with eosinophilic esophagitis. Gastroenterology 147:324–333 e5
52. Liacouras CA, Wenner WJ, Brown K, Ruchelli E (1998) Primary eosinophilic esophagitis in children: successful treatment with oral corticosteroids. J Pediatr Gastroenterol Nutr 26:380–385
53. Schaefer ET, Fitzgerald JF, Molleston JP, Croffie JM, Pfefferkorn MD, Corkins MR, Lim JD, Steiner SJ, Gupta SK (2008) Comparison of oral prednisone and topical fluticasone in the treatment of eosinophilic esophagitis: a randomized trial in children. Clin Gastroenterol Hepatol 6:165–173
54. Alexander JA, Ravi K, Enders FT et al (2016) Montelukast does not maintain symptom reductions following topical steroid therapy for eosinophilic esophagitis. Clin Gastroenterol Hepatol
55. Netzer P, Gschossmann JM, Straumann A, Sendensky A, Weimann R, Schoepfer AM (2007) Corticosteroid-dependent eosinophilic oesophagitis: azathioprine and 6-mercaptopurine can induce and maintain long-term remission. Eur J Gastroenterol Hepatol 19:865–869
56. Straumann A, Hoesli S, Bussmann C, Stuck M, Perkins M, Collins LP, Payton M, Pettipher R, Hunter M, Steiner J, Simon HU (2013) Anti-eosinophil activity and clinical efficacy of the CRTH2 antagonist OC000459 in eosinophilic esophagitis. Allergy 68:375–385
57. Stein ML, Collins MH, Villanueva JM et al (2006) Anti-IL-5 (mepolizumab) therapy for eosinophilic esophagitis. J Allergy Clin Immunol 118:1312–1319
58. Straumann A, Conus S, Grzonka P, Kita H, Kephart G, Bussmann C, Beglinger C, Smith DA, Patel J, Byrne M, Simon HU (2010) Anti-interleukin-5 antibody treatment (mepolizumab) in active eosinophilic oesophagitis: a randomised, placebo-controlled, double-blind trial. Gut 59:21–30
59. Assa'ad AH, Gupta SK, Collins MH, Thomson M, Heath AT, Smith DA, Perschy TL, Jurgensen CH, Ortega HG, Aceves SS (2011) An antibody against IL-5 reduces numbers of esophageal intraepithelial eosinophils in children with eosinophilic esophagitis. Gastroenterology 141:1593–1604
60. Spergel JM, Rothenberg ME, Collins MH et al (2012) Reslizumab in children and adolescents with eosinophilic esophagitis: results of a double-blind, randomized, placebo-controlled trial. J Allergy Clin Immunol 129:456–463 463 e1–3
61. Straumann A, Bussmann C, Conus S, Beglinger C, Simon HU (2008) Anti-TNF-alpha (infliximab) therapy for severe adult eosinophilic esophagitis. J Allergy Clin Immunol 122:425–427
62. Rothenberg ME, Wen T, Greenberg A, Alpan O, Enav B, Hirano I, Nadeau K, Kaiser S, Peters T, Perez A, Jones I, Arm JP, Strieter RM, Sabo R, Gunawardena KA (2015) Intravenous anti-IL-13 mAb QAX576 for the treatment of eosinophilic esophagitis. J Allergy Clin Immunol 135:500–507
63. Kelly KJ, Lazenby AJ, Rowe PC, Yardley JH, Perman JA, Sampson HA (1995) Eosinophilic esophagitis attributed to gastroesophageal reflux: improvement with an amino acid-based formula. Gastroenterology 109:1503–1512
64. Peterson KA, Byrne KR, Vinson LA, Ying J, Boynton KK, Fang JC, Gleich GJ, Adler DG, Clayton F (2013) Elemental diet induces histologic response in adult eosinophilic esophagitis. Am J Gastroenterol 108:759–766
65. Arias A, Gonzalez-Cervera J, Tenias JM et al (2014) Efficacy of dietary interventions for inducing histologic remission in patients with eosinophilic esophagitis: a systematic review and meta-analysis. Gastroenterology 146:1639–1648
66. Molina-Infante J, Arias A, Barrio J, Rodríguez-Sánchez J, Sanchez-Cazalilla M, Lucendo AJ (2014) Four-food group elimination diet for adult eosinophilic esophagitis: a prospective multicenter study. J Allergy Clin Immunol 134:1093–1099 e1

67. Gonsalves N, Yang GY, Doerfler B et al (2012) Elimination diet effectively treats eosinophilic esophagitis in adults; food reintroduction identifies causative factors. Gastroenterology 142:1451–1459 e1; quiz e14–5
68. Kagalwalla AF, Sentongo TA, Ritz S, Hess T, Nelson SP, Emerick KM, Melin–Aldana H, Li BUK (2006) Effect of six-food elimination diet on clinical and histologic outcomes in eosinophilic esophagitis. Clin Gastroenterol Hepatol 4:1097–1102
69. Lucendo AJ, Arias A, Gonzalez-Cervera J et al (2013) Empiric 6-food elimination diet induced and maintained prolonged remission in patients with adult eosinophilic esophagitis: a prospective study on the food cause of the disease. J Allergy Clin Immunol 131:797–804
70. Doerfler B, Bryce P, Hirano I, Gonsalves N (2015) Practical approach to implementing dietary therapy in adults with eosinophilic esophagitis: the Chicago experience. Dis Esophagus 28:42–58
71. Furuta GT, Kagalwalla AF, Lee JJ, Alumkal P, Maybruck BT, Fillon S, Masterson JC, Ochkur S, Protheroe C, Moore W, Pan Z, Amsden K, Robinson Z, Capocelli K, Mukkada V, Atkins D, Fleischer D, Hosford L, Kwatia MA, Schroeder S, Kelly C, Lovell M, Melin-Aldana H, Ackerman SJ (2013) The oesophageal string test: a novel, minimally invasive method measures mucosal inflammation in eosinophilic oesophagitis. Gut 62:1395–1405
72. Leung J, Hundal NV, Katz AJ, Shreffler WG, Yuan Q, Butterworth CA, Hesterberg PE (2013) Tolerance of baked milk in patients with cow's milk-mediated eosinophilic esophagitis. J Allergy Clin Immunol 132:1215–1216 e1
73. Hirano I (2010) Dilation in eosinophilic esophagitis: to do or not to do? Gastrointest Endosc 71:713–714
74. Cohen MS, Kaufman AB, Palazzo JP et al (2007) An audit of endoscopic complications in adult eosinophilic esophagitis. Clin Gastroenterol Hepatol 5:1149–1153
75. Schoepfer AM, Gonsalves N, Bussmann C, Conus S, Simon HU, Straumann A, Hirano I (2010) Esophageal dilation in eosinophilic esophagitis: effectiveness, safety, and impact on the underlying inflammation. Am J Gastroenterol 105:1062–1070
76. Jensen ETMC, Kappelman MD, Dellon ES (2016) Prevalence of eosinophilic gastritis, gastroenteritis, and colitis: estimates from a national administrative database. J Pediatr Gastroenterol Nutr 62: 36–42
77. Talley NJSR, Phillips SF, Zinsmeister AR (1990) Eosinophilic gastroenteritis: a clinicopathological study of patients with disease of the mucosa, muscle layer, and subserosal tissues. Gut 31:53
78. Fouroughi SFB, Kim N (2007) Anti-IgE treatment of eosinophil-associated gastrointestinal disorders. J Allergy Clin Immunol 120: 594–601
79. Min KUMD (1991) Eosinophilic gastroenteritis. Immunol Allergy Clin N Am 11:799
80. Caldwell JHTJ, Bronstein HA (1975) Serum IgE in eosinophilic gastroenteritis. Response to intestinal challenge in two cases. N Engl J Med 292:1388
81. Ko MHMR, Yershov O, Chehade M (2014) Eosinophilic gastritis in children: clinicopathologic correlation, disease course and response to therapy. Am J Gastroenterol 109:1277–1285
82. Gonsalves NDB, Yang G, Hirano I (2009) A prospective clinical trial of six food elimination diet or elemental diet in the treatment of adults with eosinophilic gastroenteritis (abstract). Gastroenterology 136:S1861
83. Prussin CLJ, Foster B (2009) Eosinophilic gastrointestinal disease and peanut allergy are alternatively associated with IL-5+ and IL-5(-) T(H)2 responses. J Allergy Clin Immunol 124:1326
84. Caldwell JMCM, Stucke EM, Putnam PE, Franciosi JP, Kushner JP, Abonia JP, Rothenberg ME (2014) Histologic eosinophilic gastritis is a systemic disorder associated with blood and extragastric eosinophilia, Th2immunity and a unique gastric transcriptome. J Allergy Clin Immunol 134:1114–1124
85. Yun MYCY, Park IS (2007) Eosinophilic gastroenteritis presenting as small bowel obstruction: a case report and review of the literature. World J Gastroenterol 13:1758–1760
86. Klein NCHR, Sleisenger MH, Jeffries GH (1970) Eosinophilic gastroenteritis. Medicine 49:299–320
87. Cello JP (1979) Eosinophilic gastroenteritis—a complex disease entity. Am J Med 67:1097–1104
88. Chang JYCR, Lee RM, Lock GR, Schleck CD, Zinsmeister AR, Smyrk TC, Talley NJ (2010) A shift in the clinical spectrum of eosinophilic gastroenteritis toward the mucosal disease type. Clin Gastroenterol Hepatol 8:669–675
89. Katz AJGH, Grand RJ (1977) Gastric mucosal biopsy in eosinophilic (allergic) gastroenteritis. Gastroenterology 73
90. MacCarty RLTN (1990) Barium studies in diffuse eosinophilic gastroenteritis. Gastrointest Radiol 15:183–187
91. Chen MJCC, Lin SC (2003) Eosinophilic gastroenteritis: clinical experience with 15 patients. World J Gastroenterol 9:2813–2816
92. Lee CMCC, Chen PC, Lin DY, Sheen IS, Wang CS, Tai DI, Sheen-Chen SM, Chen WJ, Wu CS (1993) Eosinophilic gastroenteritis: 10 years experience. Am J Gastroenterol 88:70–74
93. Tan ACKJ, Naber TH (2001) Eosinophilic gastroenteritis treated with non-enteric-coated budesonide tablets. Eur J Gastroenterol Hepatol 13:425–427
94. Siewert ELF, Koppitz P (2006) Eosinophilic gastroenteritis with severe protein-losing enteropathy: successful treatment with budesonide. Dig Liver Dis 38:55–59
95. Elsing CPJ, Gross-Weege W (2007) Budesonide for the treatment of obstructive eosinophilic jejunitis. Z Gastroenterol 45:187–189
96. Van Dellen RGLJ (1994) Oral administration of cromolyn in a patient with protein-losing enteropathy, food allergy, and eosinophilic gastroenteritis. Mayo Clin Proc 69:441–444
97. Melamed IFS, Sherman PM, Roifman CM (1991) Benefit of ketotifen in patients with eosinophilic gastroenteritis. Am J Med 90:310–314
98. Prussin CJS, Huber MM (2003) Pilot study of anti-IL-5 in eosinophilic gastroenteritis (abstract). J Allergy Clin Immunol 11:a
99. Chehade MMM, Mofidi S (2006) Allergic eosinophilic gastroenteritis with protein-losing enteropathy: intestinal pathology, clinical course, and long-term follow-up. J Pediatr Gastroenterol Nutr 42: 516

Publisher's Note Springer Nature remains neutral with regard to jurisdictional claims in published maps and institutional affiliations.