Acta Derm Venereol 2011 Epub ahead of print

CLINICAL REPORT

Atopic Dermatitis-like Pre-Sézary Syndrome: Role of Immunosuppression

Małgorzata SOKOŁOWSKA-WOJDYŁO[1], Wioletta BARAŃSKA-RYBAK[1], Agnieszka CEGIELSKA[1], Magdalena TRZECIAK[1], Hanna ŁUGOWSKA-UMER[1] and Robert GNIADECKI[2]

[1]Department of Dermatology, Venereology and Allergology, Medical University of Gdansk, Gdansk, Poland, and [2]Department of Dermatology, University of Copenhagen, Bispebjerg Hospital, Copenhagen, Denmark

We describe here 4 patients with Sézary syndrome masquerading as adult-onset atopic dermatitis. The patients presented with a clinical picture compatible with widespread atopic dermatitis and did not fulfil the criteria for Sézary syndrome (lack of lymphoadenopathy and blood involvement, skin histology without presence of atypical cells). In our patients, overt Sézary syndrome developed after immunosuppressive treatment (including cyclosporine). These cases support the validity of the concept of pre-Sézary syndrome, which is a long-lasting, pre-malignant condition, and which may develop to true malignancy in a state of immunosuppression. ***Key words: Sézary syndrome; atopic dermatitis; pre-Sézary stage.***

(Accepted February 9, 2011.)

Acta Derm Venereol 2011; 91: XX–XX.

Małgorzata Sokołowska-Wojdyło, Department of Dermatology, Venereology and Allergology, Medical University of Gdansk, 7th Debinki Str., PL-80 210 Gdansk, Poland. E-mail: mwojd@gumed.edu.pl

Atopic dermatitis (AD) is a chronic, pruritic inflammatory disease with an estimated prevalence in the general population of 17–40% (1). There are conflicting data suggesting that AD may be associated with a reduced or increased risk of developing cutaneous T-cell lymphoma (2, 3). AD usually starts in childhood and, in most patients, wanes at puberty (4, 5). However, in a minority of patients the disease continues or reappears in adulthood with characteristic features of head and neck dermatitis. In some instances adult-type AD may cause erythroderma (3.3–17% of all erythrodermas) (6, 7).

Sézary syndrome (SS) is a T-cell lymphoma-leukaemia syndrome involving the skin, blood and lymph nodes. This malignancy is considered to have a progressive course and an unfavourable prognosis. However, in 1983 to 1984 Winkelman et al. (8) suggested that SS may evolve through a relatively benign, pre-malignant condition named pre-Sézary syndrome (pre-SS). Conceptually, pre-SS resembles well-established entities, such as monoclonal gammapathy of undetermined significance (9), monoclonal B-cell lymphocytosis (10), or monoclonal T-cell dyscrasia of undetermined significance (11), which consist of persistent, expanded pre-malignant hematopoietic cell clones of benign behaviour, but which, in some instances, may progress into clinically malignant disease. Despite this, the concept of pre-SS has never gained wider support, and this term has not been included in the recent classification of the primary cutaneous lymphomas (12). We present here 4 cases that fulfil the criteria of pre-SS and presented clinically as adult-type AD.

CASE REPORTS

Case 1 (Gdańsk)

A 26-year-old woman presented with a 4-year history of widespread eczematous skin involvement. A diagnosis of late-onset AD was made; the patient fulfilled 3 out of 4 major criteria of Hanifin (13) and Rajka & Winkelmann (14) (typical localization of eczematous symptoms and relapsing course; pruritus had appeared one year after the onset of the eczema) and 10 out of the 23 minor criteria: xerosis, palmar hyperlinearity, immediate (type I) skin test reactivity (positive prick-tests for grass, trees and grains), elevated serum IgE blood level (2500 kU/l), cheilitis, Dennie-Morgan folds, orbital darkening, itch when sweating, and a course influenced by environmental and emotional factors. The patient had positive epicutaneous tests for nickel and balsam of Peru. The initial treatment consisted of oral prednisone and cyclosporine (5 mg/kg/day) in combination with topical emollients and corticosteroids. Only short remissions were achieved and the condition became refractory to the treatment. A biopsy was performed after 3 months and showed perivascular lymphocytic infiltrates without the presence of atypical cells. The patient was further referred to the Department of Dermatology Medical University of Gdańsk, where she presented with erythroderma and axillary and inguinal lymphadenopathy (Figs 1 and 2). A new biopsy showed epidermotropic infiltrate of $CD3^+$, $CD4^+$, $CD8^-$ and $CD25^+$ lymphocytes, microabscesses of Pautrier and perivascular lymphoid infiltration diagnosed as mycosis fungoides or SS (Fig. 3). Flow cytometry analysis of peripheral blood revealed the presence of an increased proportion of CD4 cells (CD4/CD8 ratio of 6/1), which

© 2011 The Authors. doi: 10.2340/00015555-1149
Journal Compilation © 2011 Acta Dermato-Venereologica. ISSN 0001-5555

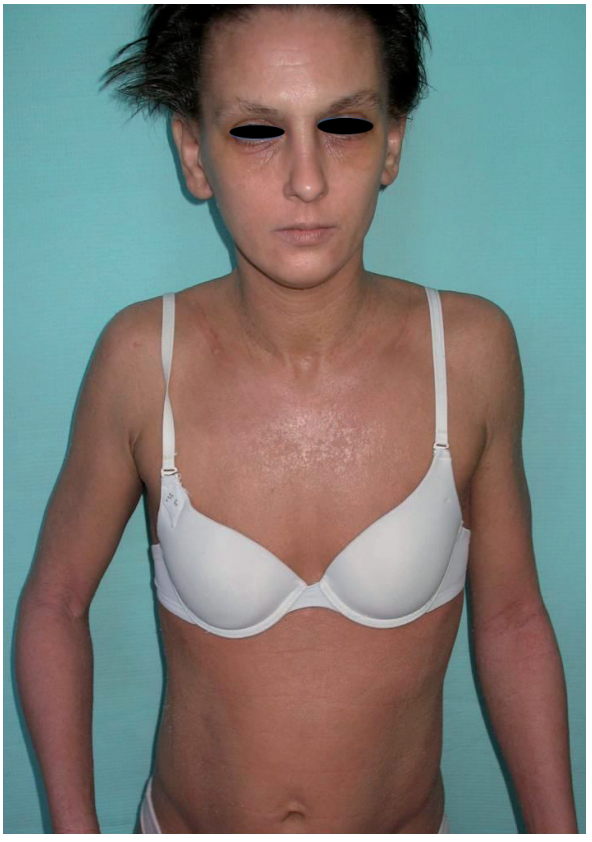

Fig. 1. Clinical features of patient 1, a 26-year-old woman with atopic dermatitis-like Sézary syndrome. Note the lichenification of the neck skin, infraorbital folds and thinning of the lateral aspects of the eyebrows (Hertoghe's sign) resembling atopic dermatitis. Photo published with permission from the patient.

had a pathological phenotype with reduced expression of CD26 (36% of $CD4^+$ cells). The number of Sézary cells was 1120/mm^3. Analysis of clonality in the skin and peripheral blood was attempted, but the isolated DNA degraded and no results were obtained. The peripheral blood showed slightly elevated lactate dehydrogenase (LDH) (626 U/l), but was otherwise normal. Histopathological analysis of the lymph nodes revealed the presence of atypical lymphocytes ($CD3^+$, $CD4^+$, $CD8^-$, $CD20^-$) impairing the architecture, suggesting nodal involvement by mycosis fungoides/SS. A computer tomography (CT) scan revealed hepatomegaly (8 cm below the right costal margin) and the aforementioned lymphadenopathy. A diagnosis of SS was made and the patient was treated with 2-chlordeoxyadenosine (2CdA) (6 mg/day (0.12mg/kg) for 5 days), acyclovir, co-trimoxazole and allopurinol. Because of low efficacy the patient received four pulses of combination chemotherapy: 2CdA (0.12 mg/kg) and cyclophosphamide (250 mg/m2), which resulted in a significant improvement in skin changes, reduction in lymphadenopathy and hepatomegaly, and decrease in LDH to 292 U/l. The $CD4^+CD7^-CD26$-lymphocyte population also decreased from 21.1% to 0.45%. At the 6-month follow-up the patient was clinically stable with low LDH (87 U/l). She had moderate pruritic and erythematous skin lesions in the flexural and periorbicular location.

Fig. 2. Palmar hyperlinearity and lichenification of the infiltrated skin (patient 1).

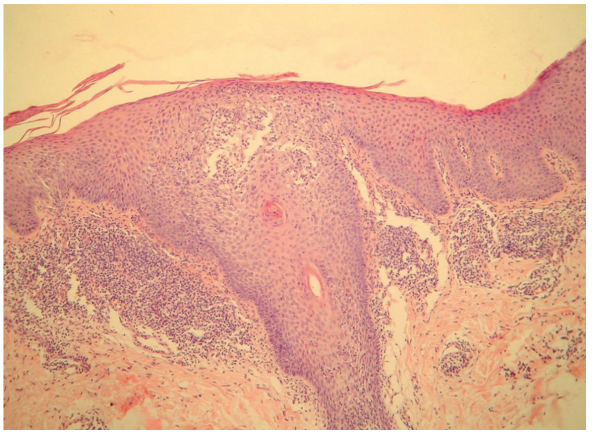

Fig. 3. Biopsy of the lesional skin from the chest (patient 1) showing acanthotic, hyperplastic epidermis and lymphocytic infiltrate in the upper dermis with epidermotropism and single Pautrier's microabscess.

Case 2 (Copenhagen)

A 53-year-old man with a known history of asthma developed an itchy, dermatitis-like skin disease at the age of 40 years. The skin changes consisted of erythema and superficial scaling. Initially, the lesions were confined to the chest, but progressed to erythroderma within several years. No lymphadenopathy was observed and histopathological analysis indicated dermatitis. Blood tests revealed mild neutrophilia ($8–11 \times 10^9$/l), moderately elevated LDH (370–400 U/l), total IgE (295 kU/l) and specific IgE against common antigens, *Dermatophagoides pteronyssinus* and *D. farinae*. Epicutaneous tests were negative. A tentative diagnosis of late-onset AD, based on the presence of idiopathic dermatitis with elevated total IgE specific to common antigens, was made. The patient was treated with topical steroids and ultraviolet B (UVB), followed by systemic methotrexate, azathioprine and mycophenolate mofetil. This regimen

had only a marginal effect on the lesions. Cyclosporine (3 mg/kg) was added and resulted in an excellent clinical response. However, 8 months later, the lesions reappeared and the patient developed severe erythroderma, inguinal lymphadenopathy and peripheral lymphocytosis: reaching 9.5×10^9/l. A new biopsy performed after one year confirmed the diagnosis of dermatitis, but flow cytometry of the peripheral blood revealed a CD4/CD8 ratio of 19, as well as an increased amount of CD4 lymphocytes in bone marrow. T-cell receptor (TCR) gene rearrangement showed a monoclonal population containing TCR-gamma-V2/V4-J1/J2 in the peripheral blood and in the bone marrow, but not in the skin. Positron emission tomography–CT (PET-CT) scanning confirmed the existence of moderately hypermetabolic pathological lymph nodes in the groin and the neck. Based on these findings, the diagnosis of SS was made. The patient has now been treated with extracorporeal photopheresis for 4 months and achieved partial remission.

Case 3 (Copenhagen)

A 64-year-old man developed an itchy eczematous skin condition on the face neck and upper chest at the age of 44 years. There was no history of AD in his childhood. The condition deteriorated over a few years and the patient progressed into erythroderma. No lymphoadenopathy was present, and several skin biopsies revealed dermatitis without the presence of malignant cells. Patch testing performed before the erythrodermic stage showed positive reactions to chromate, colophonium and nickel, but elimination of contact with the antigens did not have any clinical effect. The patient had positive specific IgE to *D. pteronyssinus* and *D. farinae*. Blood tests were normal, except for a mild thrombocytosis, ranging from $400–573 \times 10^9$/l and elevated IgE (825 kU/l). A tentative diagnosis of late-onset AD was made, based on the features of head and neck dermatitis, elevated IgE and presence of several specific IgE species against the common antigens. The patient was treated with topical and systemic steroids, UVB phototherapy, systemic methotrexate, acitretin (Neotigason®), azathioprine (although this was stopped because of gastrointestinal intolerance) and mycophenolate mofetil, without any marked effect. Partial remission of erythroderma was achieved by cyclosporine (2.5 mg/kg, increased to 3.5 mg/kg after 2 months). Six months after the introduction of cyclosporine the patient deteriorated again and a new biopsy showed features of mycosis fungoides. Peripheral blood showed mild lymphocytosis (5.12×10^9/l), thrombocytosis (664×10^9/l); flow cytometry revealed a CD4/CD8 ratio of 23 and an aberrant (lowered) expression of TCRαβ on 46% of $CD4^+$ cells. These cells were also negative for CD2 and CD26, but positive for CD3 and CD7. Bone marrow aspiration did not reveal any atypical cells. PET-CT scan showed diffuse fluorodeoxyglucose (^{18}F-FDG) absorption in the axillary glands. TCR rearrangement was clonal in the blood and the skin (identical clonality), but not in the marrow. A diagnosis of SS was made, cyclosporine was stopped, and the patient was treated with systemic steroids and extracorporeal photopheresis, without response.

Case 4 (Copenhagen)

A 75-year-old woman with a long history of AD and atopic rhinitis and conjunctivitis since early childhood. She had been treated in our institution for the last 12 years, initially with topical steroids and calcineurin inhibitors, UVB and UVA phototherapy, and 1–2 month courses of systemic steroids at the periods of exacerbation. Because of a poor disease control she was treated for the last 8 years with low-dose cyclosporine (1.5–2.5 mg/kg/day) on which she achieved partial remission. On several occasions cyclosporine was combined with mycophenolate mofetil or azathioprine, but further dose reduction was not possible. Clinical symptoms comprised head and neck dermatitis, hand eczema and, in the periods of disease exacerbations, widespread itchy dermatitis. Laboratory tests revealed increased IgE (1130 kU/l) and mild leukocytosis ($11.4–15.9 \times 10^9$/l) with neutrophilia ($7.08–10.8 \times 10^9$/l), but were otherwise normal. Creatinine clearance was within normal range. For the last 12 months we observed a progressively poorer control of eczema, which required higher doses of cyclosporine (2–3 mg/kg). The patient developed erythroderma with palpable axillary lymph nodes, accompanied by a steady increase in lymphocyte count ($7.9–9.9 \times 10^9$/l, CD4/CD8 ratio 31.8). The lymphocytes had an abnormal phenotype $CD4^+CD7^-CD26^-CD2^-$ $TCR\alpha\beta^-$. Bone marrow biopsy showed the presence of 34% pathological T cells of the same phenotype. TCR rearrangement revealed monoclonality in the skin, blood and the marrow (identical clone). PET-CT scan showed slightly increased ^{18}F-FDG uptake in axillary glands and 2 intrathoracic glands. Biopsy showed the presence of atypical lymphocytes in the bone marrow and skin. A diagnosis of SS was made, cyclosporine was discontinued and the patient started treatment with extracorporeal photopheresis, without response.

DISCUSSION

Coexistence of the symptoms of AD and SS have been reported previously. Rajka & Winkelmann (14) and van Haselen et al. (15) described adult patients with AD, family history of atopy and elevated IgE blood level who developed SS. Arellano et al. (3) provided evidence that AD increases the risk of lymphoma. However, it can be argued that our cases represent pre-SS rather than evolution of AD to SS. Three cases (patients

1–3) lack the essential major criteria of the childhood AD preceding the adult symptomatic disease. Pruritus, an essential feature of AD, was absent in patient 1. In this regard, patient 4 is an exception, since she had the diagnosis of AD confirmed since childhood. It is of note that typical SS may resemble severe erythrodermic AD. Serum IgE is often increased in SS, skin is scaly and itchy and patients with SS often present with staphylococcal skin infections and multiple cutaneous allergies, as seen in AD (8, 14, 15).

We put forward the hypothesis that pre-SS may resemble adult-onset AD. The correct diagnosis may be difficult, since skin infiltration at this stage is usually unspecific and it is not established whether clonal T-cell population can be captured in peripheral blood by molecular techniques or by flow cytometry. It was not possible to investigate whether TCR monoclonality was present at the Atopic dermatitis syndrome-like stage (ADS-like) stage, due to DNA degradation in archival skin and blood samples.

The theory that some haematological malignancies are preceded by a long phase of pre-malignant disease has been postulated previously (9–11, 16). It is probable that, in the majority of cases, this phase will never evolve to true malignancy, unless the patient becomes immunosuppressed. All our patients were treated with immunosuppressive treatment before the onset of SS. Cyclosporin A appears to be the most likely trigger in view of the previously reported lymphomas associated with this drug (17–19), but a combination of steroids and mycophenolate mofetil might further aggravate the state of immunosuppression.

The authors declare no conflict of interest.

REFERENCES

1. Mehrany K, El-Azhary RA, Biuwhuis SA, Pittelkow MR. Cutaneous T-cell lymphoma and atopy: is there an association? Br J Dermatol 2003; 149: 1013–1017.
2. Wang H, Diepgen L. Is atopy a protective or risk factor for cancer? A review of epidemiological studies. Allergy 2005; 60: 1098–1111.
3. Arellano FM, Wentworth CE, Arana A, Fernández C, Paul CF. Risk of lymphoma following exposure to calcineurin inhibitors and topical steroids in patients with atopic dermatitis. J Invest Dermatol 2007; 127: 808–816.
4. Bieber T. Atopic dermatitis. N Engl J Med 2008; 358: 1483–1484.
5. Mohrenschlager M, Darsow U, Schnopp C, Ring J. Atopic eczema: what's new? J Eur Acad Dermatol Venereol 2006; 20: 503–513.
6. Pal S, Haroon TS. Erythroderma: a clinico-etiologic study of 90 cases. Int J Dermatol 1998; 37: 104–107.
7. Sigurdsson V, Toonstra J, Hezemans-Boer M, van Vloten WA. A clinical and follow-up study of 102 patients, with special emphasis on survival. J Am Acad Dermatol 1996; 35: 53–57.
8. Winkelmann RK, Buechner SA, Diaz-Perez JL. Pre-Sèzary syndrome. J Am Acad Dermatol 1984; 10: 992–999.
9. Bladé J, Rosiñol L, Cibeira MT, de Larrea CF. Pathogenesis and progression of monoclonal gammopathy of undetermined significance. Leukemia 2008; 22: 1651–1657.
10. Shanafelt TD, Ghia P, Lanasa MC, Landgren O, Rawstron AC. Monoclonal B-cell lymphocytosis (MBL): biology, natural history and clinical management. Leukemia 2010; 24: 512–520.
11. Gniadecki R, Lukowsky A. Monoclonal T-cell dyscrasia of undetermined significance associated with recalcitrant erythroderma. Arch Dermatol 2005; 141: 361–367.
12. Willemze R, Kerl H, Sterry W, Berti E, Cerroni L, Chimenti S, et al. EORTC classification for primary cutaneous lymphomas: a proposal from the cutaneous lymphoma Study Group of the European Organization for Research and Treatment of Cancer. Blood 1997; 80: 354–371.
13. Hanifin JM. Atopic dermatitis. J Allergy Clin Immunol 1984; 73: 211–222.
14. Rajka G, Winkelmann RK. Atopic dermatitis and Sézary syndrome. Arch Dermatol 1984; 120: 83–84.
15. van Haselen CW, Toonstra J, Preesman AH, Van Der Putte SC, Bruijnzeel-Koomen CA, Van Vloten WA. Sézary syndrome in a young man with severe atopic dermatitis. Br J Dermatol 1999; 140: 704–707.
16. Magro CM, Crowson AN, Kovatich AJ, Burns F. Lupus profundus, indeterminate lymphocytic lobular panniculitis and subcutaneous T-cell lymphoma: a spectrum of subcuticular T-cell lymphoid dyscrasia. J Cutan Pathol 2001; 28: 235–247.
17. Mougel F, Dalle S, Balme B, Houot R, Thomas L. Aggressive CD30 large cell lymphoma after cyclosporine given for putative atopic dermatitis. Dermatology 2006; 213: 239–241.
18. Ravat FE, Spittle MF, Russell-Jones R. Primary cutaneous T-cell lymphoma occurring after organ transplantation. J Am Acad Dermatol 2006; 54: 668–675.
19. Kirby B, Owen CM, Blewitt RW, Yates VM. Cutaneous T-cell lymphoma developing in a patient on cyclosporin therapy. J Am Acad Dermatol 2002; 47: 165–167.