Clinical pearls

Does short bowel syndrome increase the risk of food allergy and eosinophilic gastrointestinal disease? Observations in Shah-Waardenburg syndrome

Evelyn Leechawengwongs, MD,[a,f] Brian E. Tison, MD,[b,f] G. S. Gopalakrishna, MD,[c] Barbara S. Reid, MD,[c] Carlos A. Bacino, MD,[d] Andrea L. Haws, MD, MS,[e,g] Milton J. Finegold, MD,[e,g] and William T. Shearer, MD, PhD[b,f] *Houston, Tex*

Key words: *Shah-Waardenburg syndrome, short bowel syndrome, food allergy, eosinophilic esophagitis, eosinophilic gastrointestinal disease*

Abbreviations used

EDNRB:	Endothelin receptor type B gene
hpf:	High-power field
SBS:	Short bowel syndrome
SWS:	Shah-Waardenburg syndrome
TPN:	Total parenteral nutrition
WS:	Waardenburg syndrome

Waardenburg syndrome (WS) is a congenital disorder characterized by sensorineural hearing loss and pigmentation abnormalities of the skin, hair, and irides. There are 4 different clinical types of WS, type I through IV, and their molecular basis is heterogeneous. WS type 4 (Shah-Waardenburg syndrome [SWS]) is characterized by association of the clinical features of classical WS and Hirschsprung disease. SWS is caused by homozygous mutations in the endothelin receptor type B *(EDNRB)* gene for type 4A, homozygous mutations of the endothelin 3 gene *(EDN3)* for type 4B, and heterozygous mutations of *SOX10* encoding an SRY box 10 transcription factor and leading to defects in neural crest development for type 4C.[1] Although the incidence of WS is 1:40,000, the incidence of SWS is unknown. Patients with SWS who have long-segment Hirschsprung disease have short bowel syndrome (SBS) after surgery. We report 2 cases of SWS and SBS with suspected food allergy and eosinophilic gastrointestinal disease. We have not been able to find reports of this constellation in the medical literature.

PATIENT 1

A 10-year-old Pakistani girl with SWS and SBS presented to the Allergy and Immunology Clinic at Texas Children's Hospital for evaluation of possible food allergy. The patient was given a diagnosis of long-segment Hirschsprung disease on the third day of life and started on long-term total parenteral nutrition (TPN) immediately. TPN was administered along with breast milk for 2 to 3 weeks, followed by Peptamen (Nestlé S.A., Vevey, Switzerland), an enzymatically hydrolyzed whey protein formula. Total colectomy and jejunostomy were performed at 1 year of age. She had other features of SWS, including severe bilateral sensorineural hearing loss that necessitated cochlear implants.

She presented with a 7-month history of abdominal pain, nausea, vomiting, and high ostomy output of 1500 to 2000 mL per night, which began immediately after long-term TPN was stopped at 9 years of age. She required multiple hospitalizations for dehydration. At that time, she was on a regular diet with EO28 Splash (SHS, Liverpool, United Kingdom), an amino acid–based formula. She had no history of food allergy and did not react to cow's milk when introduced at 2 years of age. Although her symptoms did not always correlate with specific foods, they worsened after eating corn chips and foods fried in peanut oil. The patient also had longstanding symptoms of perennial allergic rhinitis but did not have a history of eczema. She was not taking any medications. The family history showed that the parents were first cousins. A maternal uncle was apparently affected with SWS, and a maternal aunt was deaf and blind by report. There was also a family history of allergic rhinitis.

Physical examination revealed an active and alert girl with weight at the 13th percentile and height at the 33rd percentile. She had characteristic features consistent with WS, including large patches of white hair, white eyelashes, extensive hypopigmentation of the skin over the face and arms, and pale blue irides (Fig 1, *A*). She had hypoplastic teeth. The rest of her physical examination was unremarkable, except for bilateral inferior turbinate swelling.

Laboratory data revealed a white blood cell count of 6300 cells/μL with peripheral eosinophilia (10.2%, 643 cells/μL). Blood chemistry values were within normal limits, except for increased alkaline phosphatase (486 U/L; normal, 104-471 U/L), aspartate aminotransferase (81 U/L; normal, 12-32 U/L), and alanine aminotransferase (249 U/L; normal, 8-24 U/L) levels. The total bilirubin level was 0.5 mg/dL (normal, 0.2-1.1 mg/dL).

From [a]the Immunology, Allergy, and Rheumatology Section, Department of Medicine; the [b]Allergy and Immunology and [c]Pediatric Gastroenterology Sections, Department of Pediatrics; [d]the Department of Molecular and Human Genetics; and [e]the Department of Pathology and Immunology, Baylor College of Medicine, and the Departments of [f]Allergy and Immunology and [g]Pediatric Pathology, Texas Children's Hospital.

Disclosure of potential conflicts of interest: The authors declare that they have no relevant conflicts of interest.

Received for publication September 2, 2011; revised August 14, 2012; accepted for publication August 24, 2012.

Corresponding author: Evelyn Leechawengwongs, MD, 1 Baylor Plaza, MS:BCM 285, Houston, TX 77030. E-mail: eleecha@gmail.com.

J Allergy Clin Immunol 2012;■■■;■■■-■■■.
0091-6749/$36.00
© 2012 American Academy of Allergy, Asthma & Immunology
http://dx.doi.org/10.1016/j.jaci.2012.08.053

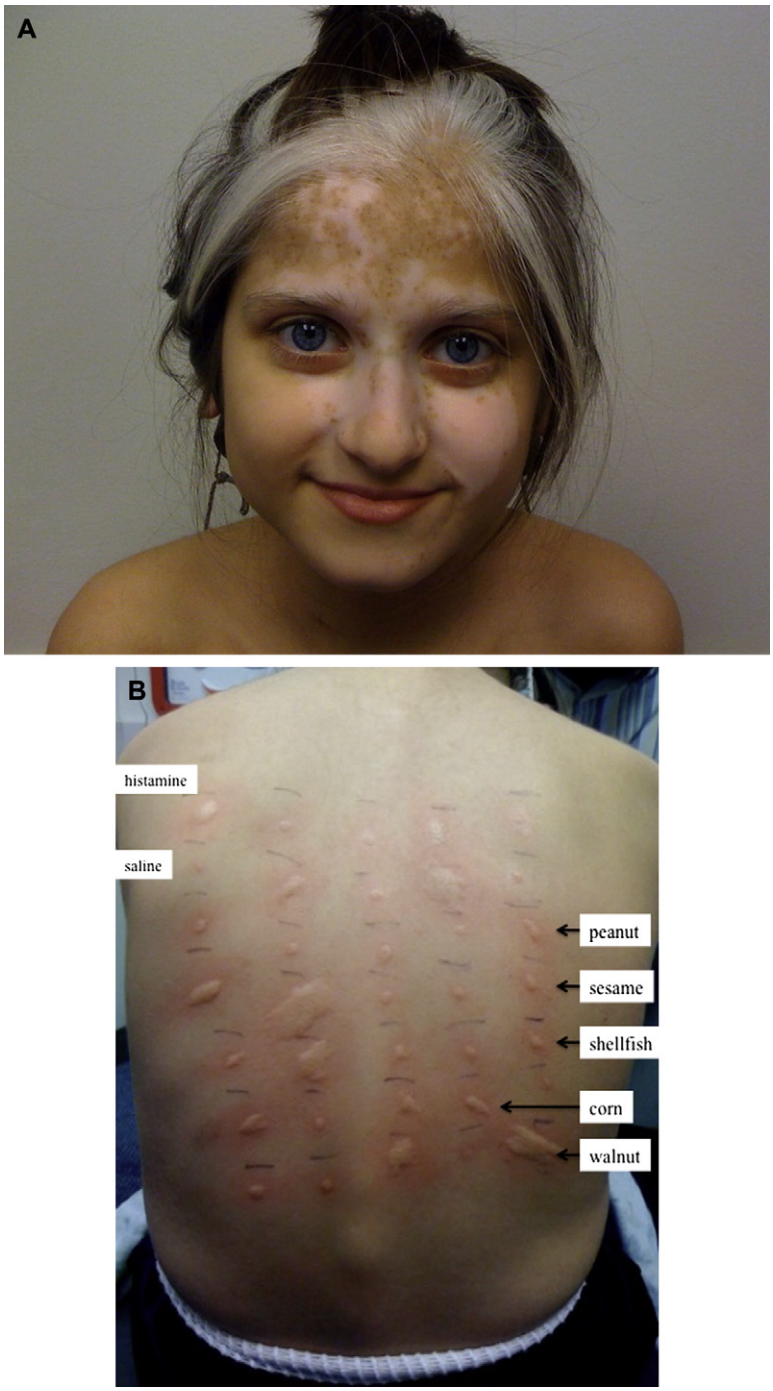

FIG 1. Patient 1: 10-year-old girl with SWS and SBS. **A,** Extensive hypopigmentation of the skin throughout the face and scalp, areas of white hair, and light blue irides. **B,** Back of torso displaying placement of environmental and food allergens (15 minutes after inoculation). **C,** Hematoxylin and eosin–stained section of esophageal mucosa showing eosinophilic infiltrates (original magnification ×10).

The patient's total IgE level was increased at 1741 kU/L, and specific serum IgE test results (ImmunoCAP; Phadia AB, Uppsala, Sweden) were positive for egg white, milk, peanut, wheat, walnut, soybean, corn, and sesame seed (Table I). Percutaneous skin test results were markedly positive for both environmental and food allergens (Fig 1, *B*). Positive food allergen skin test results included corn, peanut, sesame, shellfish, and walnut, with wheals of 12, 15, 9, 10, and 35 mm, respectively (Table II).

The patient underwent gastroduodenoscopy and small bowel endoscopy through her jejunostomy at 10 years of age to evaluate for eosinophilic gastrointestinal disease. Biopsy specimens revealed esophageal basal cell hyperplasia, intraepithelial infiltration of lymphocytes and eosinophils (greater than 60 cells/high-power field [hpf]) in the proximal esophagus, and up to 40 cells/hpf in the distal esophagus (Fig 1, *C*). The stomach lamina propria showed a mild increase in plasma cell and eosinophil

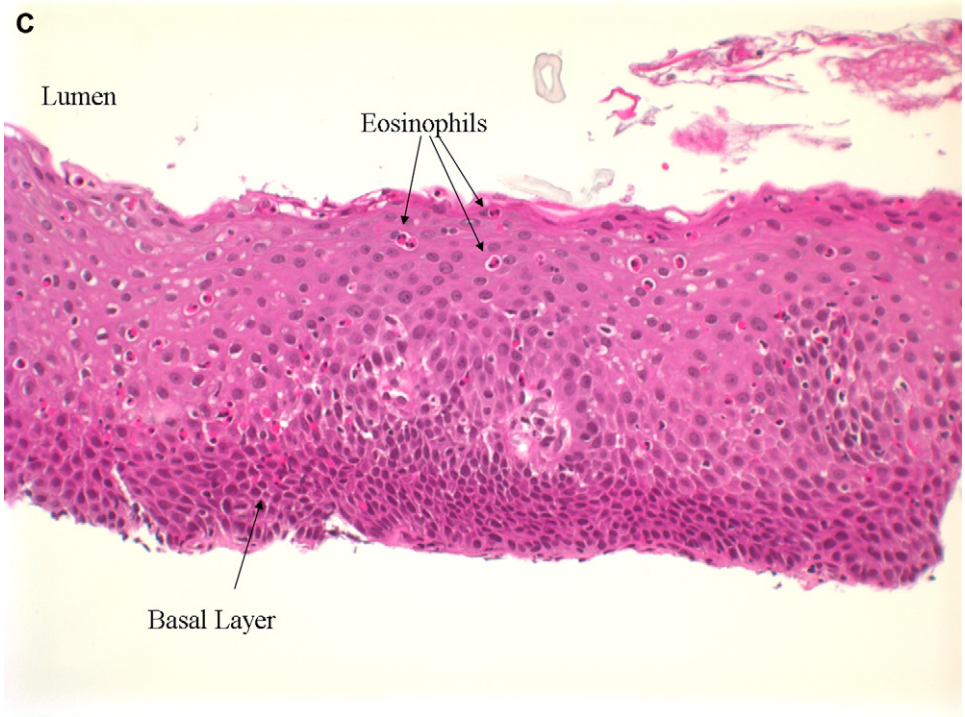

FIG 1. *(Continued)*

TABLE I. Food-specific serum IgE results

	Patient 1 (kU/L)	Patient 2 (kU/L)	Normal range (kU/L)
Total IgE	1741	53.2	0-200
Egg white	2.61	<0.35	<0.35
Milk	1.51	<0.35	<0.35
Soybean	3.53	Not done	<0.35
Peanut	1	Not done	<0.35
Walnut	7.02	Not done	<0.35
Wheat	6.27	Not done	<0.35
Codfish	<0.35	Not done	<0.35
Shellfish	<0.35	Not done	<0.35
Corn	7.7	Not done	<0.35
Sesame seed	32.5	Not done	<0.35
Latex	Not done	0.86	<0.35

TABLE II. Food percutaneous skin test results

	Patient 1		Patient 2	
	Wheal (mm)	Flare (mm)	Wheal (mm)	Flare (mm)
Histamine control	15	32	12	50
Saline control	2	4	4	8
Beef	5	10	4	6
Chicken	4	7	2	5
Codfish	6	12	2	5
Corn	12	28	3	5
Egg white	3	6	7	13
Egg yolk	4	12	6	9
Milk	3	4	8	20
Peanut	15	30	6	13
Sesame seed	9	22	3	8
Shellfish	10	20	5	9
Soybean	4	7	4	8
Walnut	35 × 15	51	4	11
Wheat	1	3	6	10

numbers, with some degranulation (≤25 cells/hpf). Eosinophil numbers were not increased in the duodenum but were increased (≤45 cells/hpf) and showed degranulation in the jejunum. These findings were consistent with eosinophilic esophagitis, eosinophilic infiltrate, and reactive epithelial changes in the stomach and eosinophilic infiltrate in the jejunum. She was also found to have lactase deficiency of 2.3 μM/min/g protein (normal >15 μM/min/g protein) with normal α-glucosidase activities.

She was instructed to avoid corn, peanut, sesame, shellfish, and walnut for her eosinophilic gastrointestinal disease and took lactase supplements as needed. Symptoms of abdominal pain, nausea, and vomiting improved after strict dietary avoidance, and ostomy output decreased to 350 to 500 mL per night. She was started on lansoprazole, cetirizine, and fluticasone nasal spray. After 4 months, the peripheral blood eosinophil count normalized (5.3%, 329 cells/μL) and serum IgE levels decreased from 1741 kU/L to 1454 kU/L. She gained 6 kg and was at the 39th percentile for weight. She then avoided all dairy products because of lactase deficiency. At the 12-month follow-up, she had gained an additional 11 kg (77th percentile). She confessed to sneaking corn chips at school and had abdominal pain and increased ostomy output. Follow-up biopsies revealed decreased numbers of eosinophils in the midesophagus (<1 cell/hpf) and distal esophagus (≤22 cells/hpf). Eosinophils were no longer seen in the stomach, and the number of eosinophils in the jejunum remained unchanged (35-50 cells/hpf).

PATIENT 2

A 14-year-old Pakistani boy with SWS was referred to the Allergy and Immunology Clinic at Texas Children's Hospital for

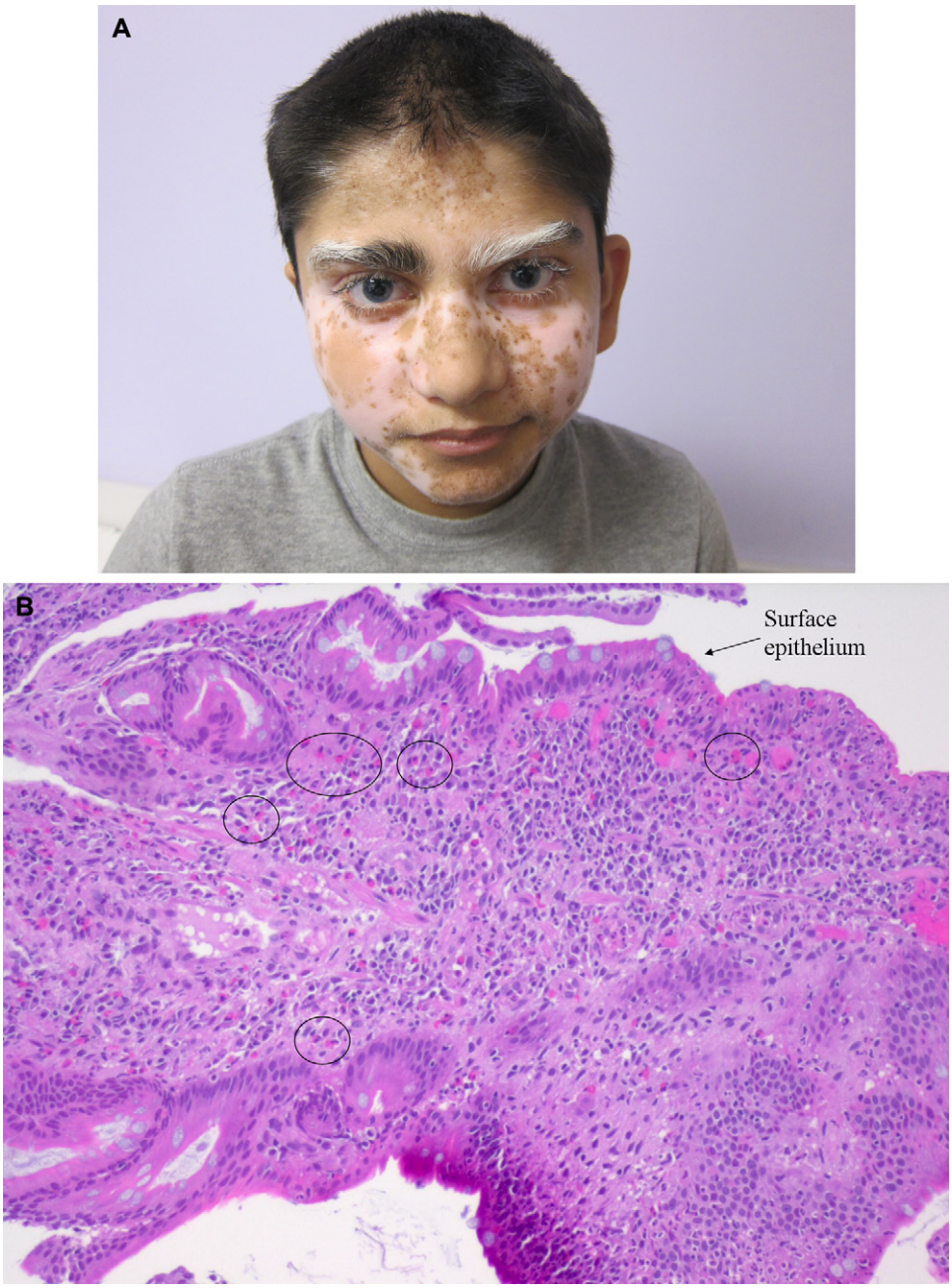

FIG 2. Patient 2: 14-year-old boy with SWS and SBS. **A,** Striking generalized hypopigmentation of the skin, white eyebrows, a couple of small white forelocks, and blue irides. **B,** Small bowel with 75 eosinophils/hpf *(circled)* and focal acute inflammation in the surface epithelium (original magnification ×10).

evaluation of possible food allergy. He was given a diagnosis of long-segment Hirschsprung disease at birth and at 2 weeks of age underwent total colectomy and partial small bowel resection resulting in SBS. He had allergic reactions to milk at 1 month of age, with hives, facial swelling, and shortness of breath. Shortly thereafter, a similar reaction occurred with Pregestimil (Mead Johnson, Evansville, Ind), an extensively hydrolyzed casein formula. He was started on a cow's milk avoidance diet and did not have any subsequent reactions to milk. He also reported latex allergy with sneezing. He remained partially TPN dependent, occasionally had abdominal cramping after eating, and had chronic diarrhea 6 times per day that gradually improved with age. His symptoms did not correlate with specific foods. Of note, he also had perennial allergic rhinitis and was not receiving any medications.

Physical examination revealed a young man with short stature and height and weight of less than the third percentile. He had white eyebrows and eyelashes, extensive hypopigmented skin on the face and arms, blue irides, and cochlear implants (Fig 2, *A*). Laboratory data revealed a normal peripheral eosinophil level, and the IgE level was 53.2 kU/mL. Specific IgE levels were positive for latex and negative for milk and egg (Table I). Percutaneous skin test results were positive for dust mites, milk, and egg white, with wheals of 19, 8, and 7 mm, respectively (Table II).

He did not have a history of egg allergy and tolerated small amounts of yogurt.

Esophagogastroduodenoscopy was done at 14 years of age, and similar to our first patient, the distal small bowel showed mild chronic inflammation with increased eosinophil numbers, ranging from 60 to 75 cells/hpf with degranulation, and focal neutrophils in the surface epithelium. The duodenal lamina propria showed increased eosinophil numbers (≤45 cells/hpf) with degranulation (Fig 2, *B*). Biopsy results of the esophagus were normal, whereas those of the stomach showed mild chronic inflammation without increased eosinophil numbers. He was also found to have lactase deficiency (2.9 μM/min/g protein; normal, >15 μM/min/g protein) with normal α-glucosidase activities.

DISCUSSION

The common symptom complex of these 2 preadolescent children with SWS with SBS consists of abdominal pain, diarrhea, and food intolerance. Patient 1 had current food allergy, and patient 2 had a history of food allergy. Both patients had skin reactivity to specific foods and eosinophilic infiltration of parts of the gastrointestinal system.

Malabsorption occurs after massive intestinal resections (SBS) because the decrease in intestinal absorptive area leads to diarrhea, weight loss, and malnutrition. SBS frequently occurs after surgical resection of the bowel because of intestinal atresias, necrotizing enterocolitis, gastroschisis, pseudoobstruction, trauma, chylous ascites, segmental volvulus, intestinal congenital malformation, intestinal perforation, and meconium peritonitis in which food allergy has been reported.[2-4] Other functions of the bowel are affected, including increased intestinal permeability to luminal contents and immune dysfunction from loss of gut-associated lymphoid tissue.[5,6] Small bowel bacterial overgrowth seen in patients with SBS can lead to mucosal inflammation, increased permeability to dietary antigens, and sensitization to food.[7] Food hypersensitivity has been reported in patients with SBS, particularly to cow's milk and egg.[2,3] In one study of children with SBS,[7] 8 (57.1%) of 14 children were sensitized to cow's milk, and 5 (41.7%) of 12 were sensitized to egg.

Although there have not been any case reports of eosinophilic esophagitis or eosinophilic gastrointestinal disease in patients with SBS, there has been mention of eosinophilic infiltration. In a study of children with intestinal failure,[4] 27 patients underwent endoscopies, and 15% (n = 9) were found to have allergic disease diagnosed based on histopathologic evidence of greater than 15 eosinophils/hpf, the presence of eosinophils in the intramuscular layers, or clusters of eosinophils in the esophageal mucosa. Five patients were switched to a hypoallergenic diet, and 1 patient was started on sulfasalazine. In another study,[8] 9 of 13 patients with SBS and noninfectious bloody diarrhea displayed mild-to-marked eosinophilic infiltration on colorectal biopsy. At that time, they were given a diagnosis of "short gut colitis" not thought to be from allergy and were treated with sulfasalazine, with resolution of bloody stools and increased feeding tolerance.

In our 2 patients we suspect that the underlying SWS with SBS were predisposing factors for food allergy and eosinophilic gastrointestinal disease, given the gut barrier impairment and increased intestinal permeability found in patients with SBS. There is evidence that in adult asthmatic patients, polymorphisms of *EDNRB*, one of the genes mutated in patients with SWS, are strongly associated with airway obstruction, as assessed based on low FEV_1.[9] By investigating the patients' genetic mutations in the future, we might be able to hypothesize whether *EDNRB* is linked to other atopic diseases. Of note, both patients have the atopic feature of allergic rhinitis, which can also be associated with eosinophilic esophagitis.[10] We speculate that similar to the observation of an endothelin receptor mutation/polymorphism being associated with airway obstruction (a form of hypersensitivity), it is possible that *EDNRB* gene polymorphisms/mutations might alter these other forms of hypersensitivity disease (eg, food allergy and eosinophilia gastrointestinal disease).

In summary, food allergy and eosinophilic gastrointestinal diseases can lead to abdominal pain, nausea, vomiting, and chronic diarrhea. These symptoms can be found in patients with SBS and might be related to malabsorption or bacterial overgrowth from SBS itself or complicated by anatomic defects, infection, peptic disease, and allergy (including eosinophilic gastrointestinal diseases).[7] Lactose intolerance might have been part of these patients' complexes as well. Therefore although there might not be known food triggers, patients with evidence of food sensitization might benefit from a trial of strict dietary avoidance of suspect allergic foods.

We thank Dr Naila Siddiqi, who referred the patient; the families who participated; and the Pediatric Allergy and Immunology Research and Education Fund, Baylor College of Medicine.

REFERENCES

1. Pingault V, Ente D, Dastot-Le Moal F, Goossens M, Marlin S, Bondurand N. Review and update of mutations causing Waardenburg Syndrome. Hum Mutat 2010; 31:391-406.
2. Mazon A, Solera E, Alentado N, Oliver F, Pamies R, Caballero L, et al. Frequent IgE sensitization to latex, cow's milk, and egg in children with short bowel syndrome. Pediatr Allergy Immunol 2008;19:180-3.
3. Masumoto K, Esumi G, Teshiba R, Nagata K, Hayashida M, Nakatsuji T, et al. Cow's milk allergy in extremely short bowel syndrome: Report of two infants. European e-Journal of Clinical Nutrition and Metabolism 2008;3:e217-9.
4. Ching YA, Modi BP, Jaksic T, Duggan C. High diagnostic yield of gastrointestinal endoscopy in children with intestinal failure. J Pediatr Surg 2008;43:906-10.
5. Welters CF, Dejong CH, Deutz NE, Heineman E. Intestinal adaptation in short bowel syndrome. ANZ J Surg 2002;72:229-32.
6. Stoidis CN, Misiakos EP, Patapis P, Fotiadis CI, Spyropoulos BG. Potential benefits of pro- and prebiotics on intestinal mucosal immunity and intestinal barrier in short bowel syndrome. Nutr Res Rev 2011;24:21-30.
7. Vanderhoof JA, Young RJ. Hydrolyzed versus nonhydrolyzed protein diet in short bowel syndrome in children. J Pediatr Gastroenterol Nutr 2004;38:107.
8. Taylor SF, Sondheimer JM, Sokol RJ, Silverman A, Wilson HL. Noninfectious colitis associated with short gut syndrome in infants. J Pediatr 1991;119:24-8.
9. Taillé C, Guénégou A, Almolki A, Piperaud M, Leynaert B, Vuillaumier S, et al. ETB receptor polymorphism is associated with airway obstruction. BMC Pulm Med 2007;7:5.
10. Jyonouchi S, Brown-Whitehorn TA, Spergel JM. Association of eosinophilic gastrointestinal disorders with other atopic disorders. Immunol Allergy Clin North Am 2009;29:85-97.