Journal of Clinical Immunology
https://doi.org/10.1007/s10875-018-0588-6

LETTER TO EDITOR

# Two Prenatal Cases of Hyper-IgE Syndrome

Makiko Egawa[1] · Kohsuke Imai[1] · Yoko Taketani[2] · Tomohiro Morio[3] · Naoyuki Miyasaka[2]

Received: 27 September 2018 / Accepted: 27 December 2018
© Springer Science+Business Media, LLC, part of Springer Nature 2019

To the Editor:

## Background

Autosomal dominant hyper-IgE syndrome (AD-HIES), a rare primary immunodeficiency disorder caused by mutations in *STAT3* (signal transducer and activator of transcription factor 3), is characterized by recurrent staphylococcal skin abscesses, pulmonary infections, and high serum IgE concentrations [1]. There are few reports on pregnancy and childbirth in women with AD-HIES. Here, we report the pregnancies of two women with AD-HIES whose infants had the same *STAT3* mutation.

## Case Reports

Patient 1 was a 37-year-old Japanese woman in her first pregnancy. She had had recurrent pulmonary infections, sinusitis, and severe atopic dermatitis from soon after birth. At age 16, she was diagnosed with HIES on the basis of high serum IgE concentrations and typical clinical findings, after which she was started on prophylactic antibiotics (trimethoprim/sulfamethoxazole [TMP/SMX], fluconazole, and clarithromycin). At age 36, she consulted our Obstetrics Department about having a child. She was switched to amoxicillin/clavulanate (AMPC/CVA) because TMP/SMX has teratogenic potential and advised to take folic acid supplementation. Although a possible teratogenic effect of azoles has been reported, an association between azole fungicide use and risk of birth defects has not been established; thus, fluconazole was continued. Cerebral artery abnormalities were excluded by brain magnetic resonance angiography and genetic counseling provided. Her HIES was diagnosed via confirmation of a heterozygous mutation of *STAT3* (c. 1970 A>G, p. Tyr 657 Cys). Five months later, she became pregnant. Fetal growth was normal; however, from gestation weeks 10–15 she developed upper respiratory tract infection and pneumonia and required hospitalization. She was treated with intravenous antibiotics (cefozopran hydrochloride) and intravenous immunoglobulin (IVIG) (Fig. 1a). She continued to have repeated upper and lower respiratory tract infections, so cefditoren pivoxil (CDTR-PI) was added to her treatment regimen. At gestational week 41, she gave birth to a 3084-g boy by emergency cesarean delivery because of arrested labor. His Apgar scores at 1 and 5 min were 8 and 9, respectively. No morphological abnormalities or evidence of infection was observed. The cord blood IgE concentration was < 3 IU/mL (Supplemental Figure 1); however, the infant had the same *STAT3* mutation as assessed by cord and neonatal blood sample tests and was diagnosed as having HIES. He developed serious omphalitis caused by *Staphylococcus aureus* infection on day 9 after birth and required a 1-week course of intravenous antibiotics (meropenem hydrate), after which he commenced daily prophylactic TMP/SMX (TMP 48 mg/day SMX 240 mg/day). One month after birth, he exhibited hypocarnitinemia and began carnitine supplementation. Although administration of TMP/SMX can cause jaundice in neonates, this did not occur. His immunophenotyping showed increased levels of Th1 cells and decreased levels of Th2 and Th17 cells, as previously reported [P67 in reference 2].

**Electronic supplementary material** The online version of this article (https://doi.org/10.1007/s10875-018-0588-6) contains supplementary material, which is available to authorized users.

✉ Makiko Egawa
mak-per@tmd.ac.jp

[1] Department of Pediatrics, Perinatal and Maternal Medicine, Graduate School of Medical and Dental Sciences, Tokyo Medical and Dental University, 1-5-45 Yushima, Bunkyo-ku, Tokyo 113-8510, Japan

[2] Comprehensive Reproductive Medicine, Graduate School of Medical and Dental Sciences, Tokyo Medical and Dental University, 1-5-45 Yushima, Bunkyo-ku, Tokyo 113-8510, Japan

[3] Department of Pediatrics and Developmental Biology, Graduate School of Medical and Dental Sciences, Tokyo Medical and Dental University, 1-5-45 Yushima, Bunkyo-ku, Tokyo 113-8510, Japan

Published online: 07 January 2019

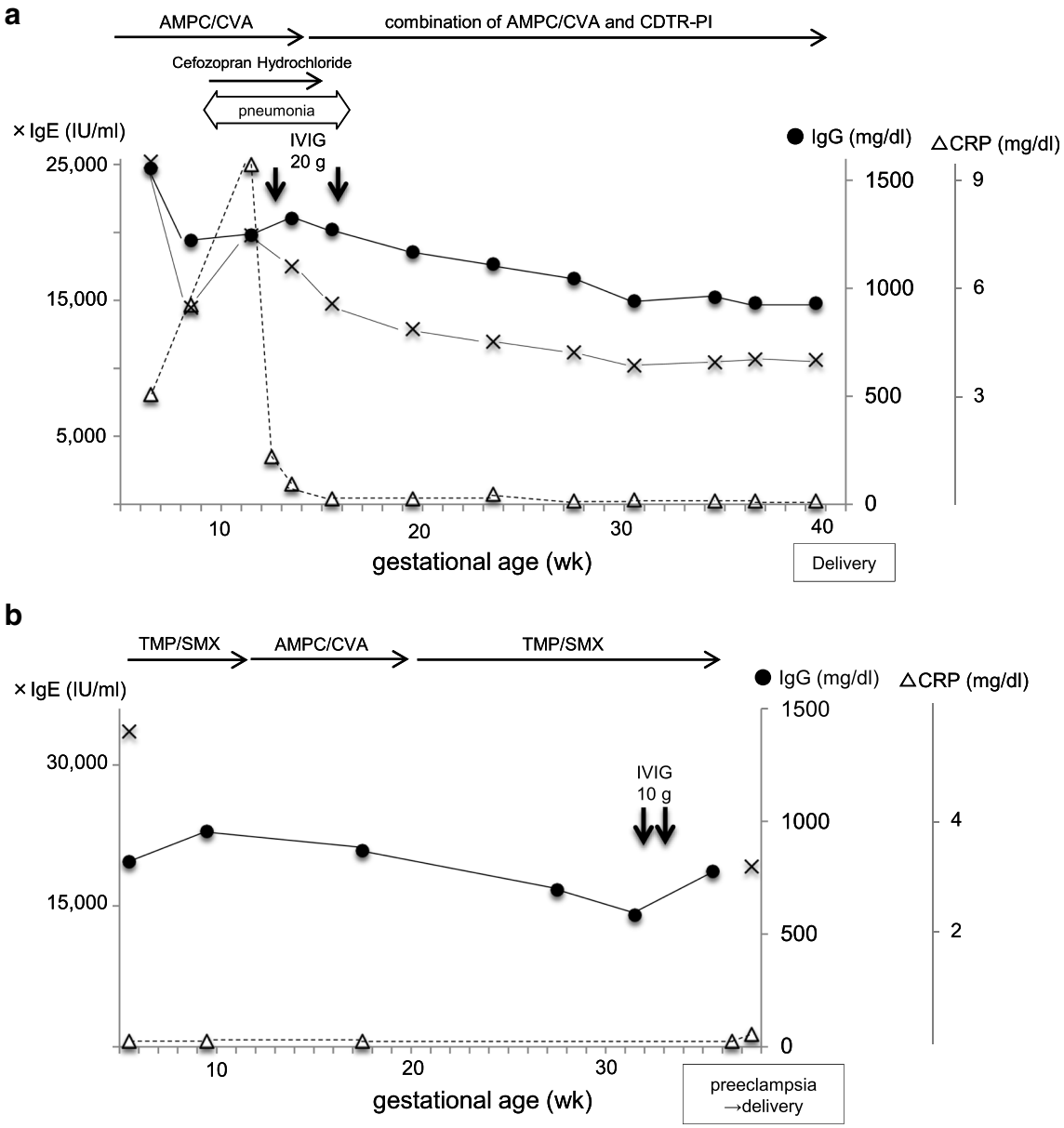
a
AMPC/CVA
combination of AMPC/CVA and CDTR-PI
Cefozopran Hydrochloride
pneumonia
× IgE (IU/ml)
IVIG
20 g
● IgG (mg/dl)
△CRP (mg/dl)
25,000
15,000
5,000
1500
1000
500
0
9
6
3
10
20
30
40
gestational age (wk)
Delivery
b
TMP/SMX
AMPC/CVA
TMP/SMX
× IgE (IU/ml)
● IgG (mg/dl)
△CRP (mg/dl)
30,000
15,000
1500
1000
500
0
4
2
IVIG
10 g
10
20
30
gestational age (wk)
preeclampsia
→delivery

c

d

◀ **Fig. 1** Clinical courses and findings in patients with HIES. **a**, **b** Clinical courses of patients 1 (**a**) and 2 (**b**). In healthy adults, the normal range of IgG is 861–1747 mg/dL and of IgE 0–295 IU/mL. **c** Skin findings in patient 2's infant on day 20 after birth. **d** Skin findings in Patient 2's infant at 1 month of age

Patient 2 was a 30-year-old Japanese woman in her first pregnancy. She had developed eczema and skin abscesses at age 1 month. At age 3 months, she was diagnosed as having HIES and had repeated bouts of severe pneumonia, bronchitis, sinusitis, and lung abscesses despite being started on prophylactic antibiotics (TMP/SMX, fluconazole, and clarithromycin). Her medical history included two fractures (a rib and left hand), eosinophilic hepatitis, and malignant lymphoma (sphenoid sinus neoplasm detected at age 23 years), for which she had received six cycles of a rituximab, cyclophosphamide, hydroxydaunorubicin, vincristine, and prednisolone regimen. At age 24 years, she was genetically diagnosed with AD-HIES via confirmation of a heterozygous mutation of *STAT3* (c. 2126 ins CCA, p. 709 ins Thr). Five years later, she became pregnant. At 12 weeks of gestation, her TMP/SMX was switched to AMPC/CVA. On the basis of our experience with case 1, her TMP/SMX treatment was resumed after gestation week 20. Her serum IgG concentration started to decrease after she became pregnant, so she received IVIG (20 g) twice (Fig. 1b).

Labor was induced with oxytocin at gestation week 36 for preeclampsia. She gave birth to a 2262-g boy by emergency cesarean delivery because of fetal distress. His Apgar scores at 1 and 5 min were 5 and 7, respectively. No morphological abnormalities were observed. Although the operation was uneventful, she required reoperation on day 2 following delivery to remove a huge subcutaneous wound hematoma. Her hemoglobin concentration had dropped to 4.6 g/dl, necessitating an additional 12 days in hospital.

The infant's serum IgE concentration was < 3 IU/mL (Supplemental Figure 1); however, he had the same *STAT3* mutation as his mother. He commenced daily prophylactic TMP/SMX (TMP 24 mg/day SMX 120 mg/day) on day 15 after birth, but developed severe dermatitis on day 20 (Fig. 1c). On day 28 after birth, he required hospitalization for intravenous antibiotics (cefmetazole sodium) for severe dermatitis, skin abscesses, and a urinary tract infection (Fig. 1d).

## Discussion and Conclusion

We made two important clinical observations in these cases. First, prophylaxis and treatment of infections during pregnancy is important in patients with AD-HIES. Second, early diagnosis is very useful in neonate management. The main cause of susceptibility to infection in AD-HIES patients is disordered Th17 cell differentiation. Th17 cells secrete interleukin (IL)-17 and IL-22, which help defend against skin and lung infections by *Candida* species or extracellular bacteria by enabling antibacterial peptide and chemokine production. Lifelong prophylactic antibiotics are needed, and TMP/SMX is a key drug for treating HIES patients [3]. However, trimethoprim is associated with fetal cardiovascular and neural tube defects [4], so we substituted AMPC/CVA for TMP/SMX during pregnancy in both patients. This regimen was insufficient to prevent pneumonia in patient 1, prompting administration of prophylactic CDTR-PI. Unfortunately, the long-term administration of CDTR-PI caused hypocarnitinemia in the infant at age 1 month. Accordingly, TMP/SMX administration was resumed in patient 2 after the fetal organogenesis phase. Chandesris et al. reported that a combination of antibiotic prophylaxis and IgG injections is beneficial [5], so IVIG was administered prophylactically.

Maternal serum IgG concentrations are known to decrease during gestation because of placental transfer to the fetus; IgG is essential for not only pregnant women but also their fetuses [6]. Thus, regular maternal serum IgG checks are important, and IVIG replacement therapy may be useful in pregnant women with HIES. Changes in IgE during pregnancy are unknown. In our patients, maternal serum IgE concentrations also decreased with gestational progression. However, the mechanism and significance of this decline remain unclear.

Early diagnosis of HIES greatly facilitates appropriate neonate management. Both infants had the same *STAT3* mutation as their mothers. Knowing this enabled us to respond promptly when they developed symptoms and guided our advice to the parents concerning care for their babies' skin conditions, especially at the umbilical stump.

Patient 2 developed preeclampsia and a huge subcutaneous hematoma. Because hypertension and vascular abnormalities often occur in HIES patients [7], their obstetricians must monitor blood pressure and renal function, especially in late pregnancy, and be vigilant for postoperative complications caused by vessel wall vulnerability after cesarean delivery.

The selection of suitable prophylactic antibiotics during pregnancy and the early diagnosis of neonates is very important in managing pregnant women with HIES. Prepregnancy provision of information about the justification and safety of drug use during pregnancy is important, as is early diagnosis to ensure timely therapeutic interventions for their infants. Prophylactic antibiotics did not prevent deterioration of dermatitis; the timing of antibiotic prophylaxis and treatment in affected neonates requires further clarification.

**Acknowledgments** We thank the patients who participated in this study.

**Authors' Contributions** ME wrote the manuscript and managed the pregnancies. KI and TM orchestrated the patients' care. KI and YT reviewed the manuscript. All authors reviewed the manuscript and approved the final version.

**Funding Information** This work was partially supported by the Japan Ministry of Health, Labor, and Welfare (201711064A) and the AMED under Grant Number JP18ek0109218.

## Compliance with Ethical Standards

**Conflict of Interest** The authors declare that they have no conflicts of interest.

**Research Involving Human Participants** All procedures performed in the study were in accordance with the Helsinki principles.

**Informed Consent** Written informed consent was obtained from both patients here presented.

**Publisher's Note** Springer Nature remains neutral with regard to jurisdictional claims in published maps and institutional affiliations.

## References

1. Minegishi Y, Saito M, Tsuchiya S, Tsuge I, Takada H, Hara T, et al. Dominant-negative mutations in the DNA-binding domain of STAT3 cause hyper-IgE syndrome. Nature. 2007;448:1058–62.
2. Takashima T, Okamura M, Yeh TW, Okano T, Yamashita M, Tanaka K, et al. Multicolor flow cytometry for the diagnosis of primary immunodeficiency diseases. J Clin Immunol. 2017;37:486–95.
3. Milner JD, Brenchley JM, Laurence A, Freeman AF, Hill BJ, Elias KM, et al. Impaired T(H)17 cell differentiation in subjects with autosomal dominant hyper-IgE syndrome. Nature. 2008;452:773–6.
4. Czeizel AE, Rockenbauer M, Sorensen HT, Olsen J. The teratogenic risk of trimethoprim-sulfonamides: a population based case-control study. Reprod Toxicol. 2006;15:637–46.
5. Chandesris MO, Melki I, Natividad A, Puel A, Fieschi C, Yun L, et al. Autosomal dominant STAT3 deficiency and hyper-IgE syndrome: molecular, cellular, and clinical features from a French national survey. Medicine (Baltimore). 2012;91:e1–19.
6. Malek A, Sager R, Kuhn P, Nicolaides KH, Schneider H. Evolution of maternofetal transport of immunoglobulins during human pregnancy. Am J Reprod Immunol. 1996;36:248–55.
7. Freeman AF, Avila EM, Shaw PA, Davis J, Hsu AP, Welch P, et al. Coronary artery abnormalities in hyper-IgE syndrome. J Clin Immunol. 2011;31:338–45.

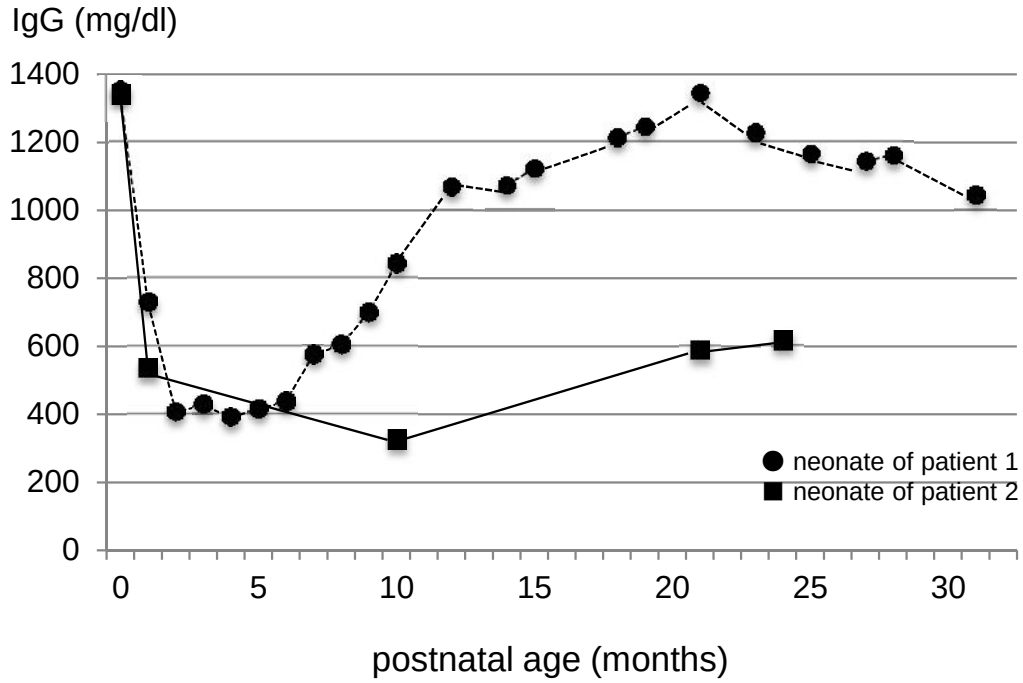


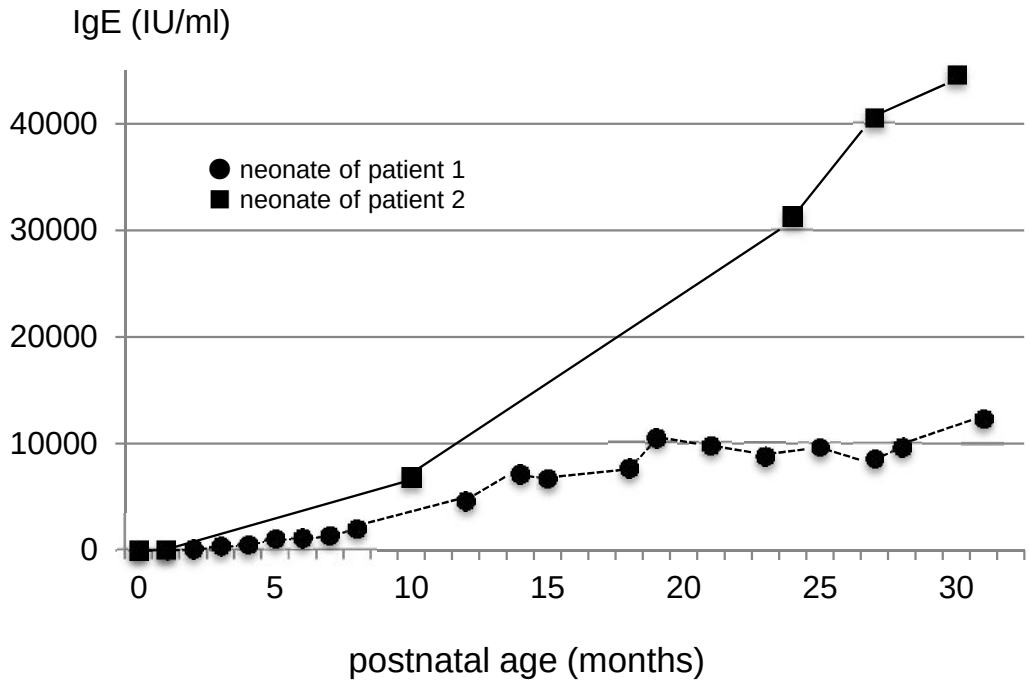


Supplemental Figure 1