American Journal of Case Reports

e-ISSN 1941-5923
© Am J Case Rep, 2021; 22: e934190
DOI: 10.12659/AJCR.934190

Received: 2021.07.27
Accepted: 2021.10.15
Available online: 2021.10.21
Published: 2021.11.22

# A Case of Kounis Syndrome Presenting as Coronary Artery Spasm Associated with Acetaminophen Infusion

Authors' Contribution:
Study Design A
Data Collection B
Statistical Analysis C
Data Interpretation D
Manuscript Preparation E
Literature Search F
Funds Collection G

ABCDEF 1 Vu Hoang Vu
ABCDEF 1 Khang Duong Nguyen
EF 1 Chinh Duc Nguyen
EF 2 Binh Quang Truong

1 Department of Interventional Cardiology, University Medical Center Ho Chi Minh City, Ho Chi Minh City, Vietnam
2 Cardiovascular Center, University Medical Center Ho Chi Minh City, Ho Chi Minh City, Vietnam

**Corresponding Author:** Khang Duong Nguyen, e-mail: doctorduongkhang@gmail.com
**Financial support:** None declared
**Conflict of interest:** None declared

**Patient:** Male, 38-year-old
**Final Diagnosis:** Myocardial Infarction
**Symptoms:** Chest discomfort • dyspnea • hypotension
**Medication:** —
**Clinical Procedure:** —
**Specialty:** Allergology • Cardiology

**Objective:** Unusual clinical course

**Background:** Kounis syndrome is a hypersensitive coronary disorder triggered by drugs, food, and environmental factors. A 38-year-old male patient with acetaminophen-induced type 1 Kounis syndrome is described. The purpose of this paper is to show that Kounis syndrome is a serious condition that may be linked to a common medication and that it should be recognized earlier in clinical practice.

**Case Report:** We report a case of a 38-year-old male patient with chest discomfort, dyspnea, and hypotension following a paracetamol continuous infusion, as well as ST elevation on numerous leads during the episode. The diagnosis of drug-induced Kounis syndrome was made when the patient no longer had angina and the EKG returned to normal after the infusion was discontinued; the coronary angiography also showed no remarkable stenosis.

**Conclusions:** Kounis syndrome is a hypersensitive coronary disease that involves eosinophil and/or mast cell infiltrated coronary stent thrombosis, vasospastic angina, and allergic myocardial infarction. Although acetaminophen is widely used, acetaminophen-induced Kounis syndrome is uncommon and seldom documented. The necessity of detecting the distinct appearance earlier to give more suitable therapy is highlighted in this report.

**Keywords:** Acetaminophen • Coronary Vasospasm • Kounis Syndrome

**Full-text PDF:** https://www.amjcaserep.com/abstract/index/idArt/934190

1997 — 4 20

This work is licensed under Creative Common Attribution-NonCommercial-NoDerivatives 4.0 International (CC BY-NC-ND 4.0)



Indexed in: [PMC] [PubMed] [Emerging Sources Citation Index (ESCI)] [Web of Science by Clarivate]

## Background

Kounis syndrome is an acute coronary syndrome characterized by coronary artery vasospasm, acute myocardial infarction, and coronary stent thrombosis, all of which are linked to mast cell and platelet activation in the context of allergies or anaphylaxis [1-4]. Inflammation mediators such as histamine, platelet activation factors, arachidonic acid derivatives, proteases, and numerous types of cytokines and chemokines released during the allergic process activate Kounis syndrome [5].

The syndrome is not uncommon, with one study reporting that 3.4% of allergy patients (27/793) brought to the emergency room had the syndrome [6]. Kounis syndrome patients have longer hospital stays (mean, 5.8±6.0 vs 3.0±3.9 days, $P<0.001$) and higher rates of all-cause in-hospital death (7.0% vs 0.4%, $P<0.001$), according to a national registry in the United States [7] compared with patients without Kounis syndrome. Nevertheless, it is rarely recognized and reported in clinical practice due to incorrect diagnosis. Therefore, doctors must keep it in mind to diagnose and manage these patients correctly.

## Case Report

This is the case of a 38-year-old man who was admitted to a rural hospital with diarrhea. He had stomachache, lightheadedness, and diarrhea with blood stains 3 days before admission, after consuming raw foods. He was diagnosed with infectious diarrhea and then admitted. He had no previous history of allergic reaction to food, drugs, or environmental elements. The next day at the hospital, shortly after receiving the paracetamol infusion, he felt chest discomfort, dyspnea, and hypotension. There was neither urticaria nor angioedema on the record. This was also the first time since his admission that he had been given paracetamol. The exams of the other organs were unremarkable. On electrocardiogram (recorded in the rural hospital) (**Figure 1**), there were anterolateral and posterior ST elevation along with depressed ST segments in leads aVR, V1, V2, V3, V3R, V4R; no q waves were observed. The blood test revealed an increased level of hs-Troponin T of 1580 ng/L (reference range: <24.9 ng/L). There was no record of the baseline ECG or troponin concentration at the time of admission. Acute myocardial infarction was diagnosed, and the patient was sent to the secondary hospital.

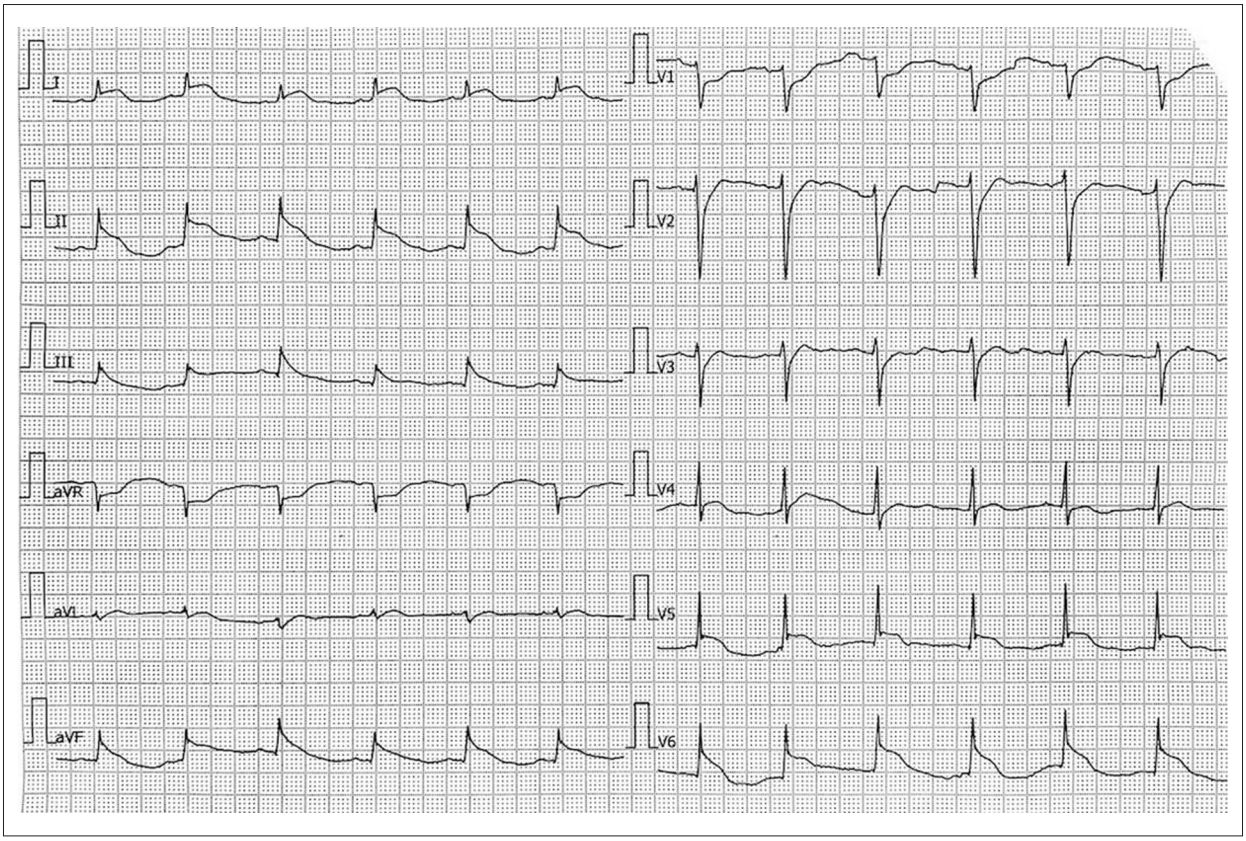


**Figure 1.** Electrocardiogram recorded during angina episode at the rural hospital. Sinus rhythm, D1, D2, aVF, V4, V5, V6 leads had elevated ST segments.

This work is licensed under Creative Common Attribution-NonCommercial-NoDerivatives 4.0 International (CC BY-NC-ND 4.0)

Indexed in: [PMC] [PubMed] [Emerging Sources Citation Index (ESCI)] [Web of Science by Clarivate]

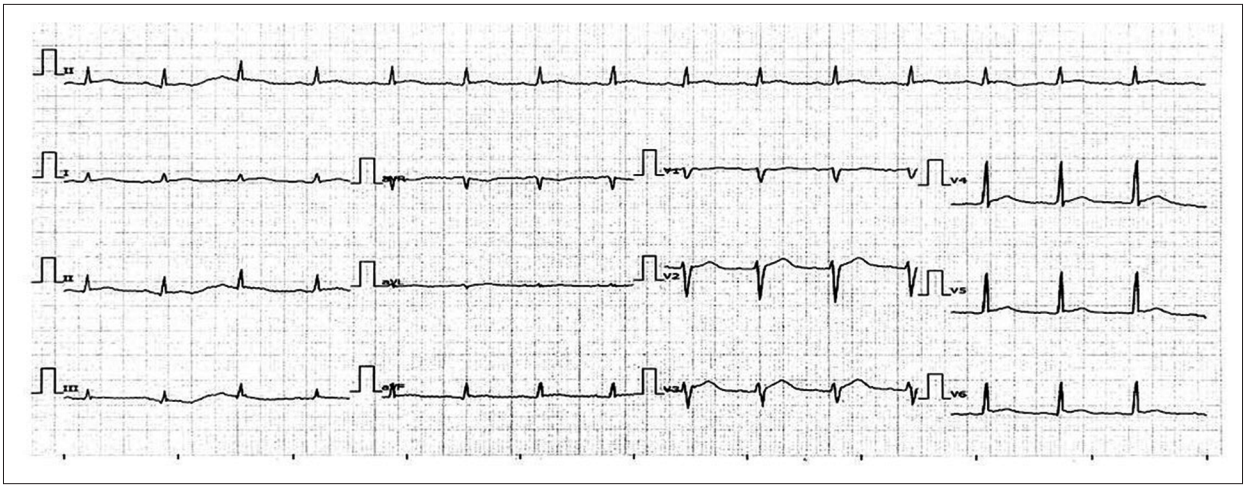

**Figure 2.** Electrocardiogram 6 h after the angina, recorded at the secondary hospital. Sinus rhythm, no ST-T changes, no q wave detected.

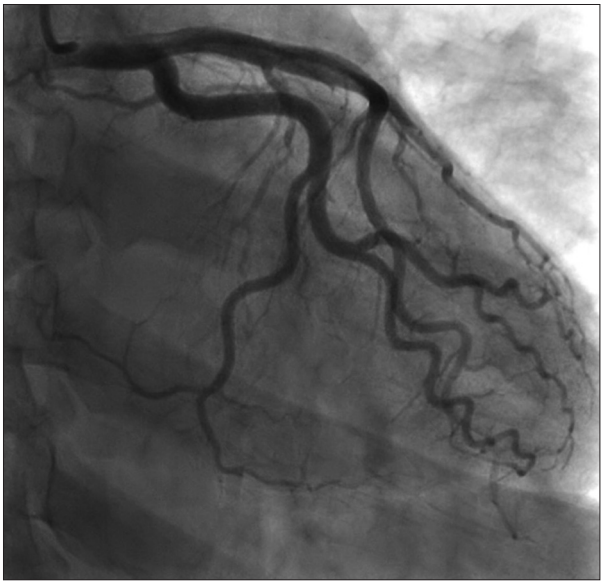

**Figure 3.** Coronary angiography showed no remarkable findings on the left coronary artery.

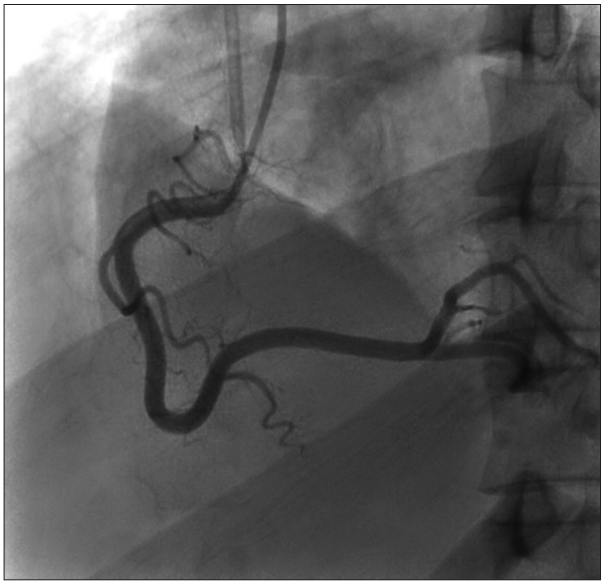

**Figure 4.** Coronary angiography showed no remarkable findings on the right coronary artery.

The patient had a second electrocardiogram (recorded at the secondary hospital 6 h after the angina attack) (**Figure 2**), which revealed sinus rhythm, no ST-T alterations, and no q waves at any of the leads. At that time, the blood concentrations of hs-Troponin T and D-dimer were 2716 ng/L (reference range: <14.0 ng/L) and 5.21 mcg/mL (reference range: <0.5 mcg/mL). He stated that he had no chest pain or trouble breathing, and his vital signs were normal. The diagnosis of Kounis syndrome was made, and he was sent to another cardiology center that had a catheterization lab. He arrived at our hospital more than 12 h after the angina attack, at which time the EKG was negative, and the transthoracic echocardiography was normal; hence, he was hospitalized for planned coronary angiography.

A transthoracic echocardiogram 1 day before the angina episode, 1 day after the event, and 3 days later, were normal. There was no evidence of dyskinesis, the left ventricular function was 71%, and no pericardial effusion was noted. His blood IgE concentration was 380.2 IU/mL (<158 IU/mL). The results of the coronary angiography (**Figures 3, 4**) revealed right coronary dominance, no stenosis, and no wall motion abnormalities in left ventriculography. He had uneventful hospital course and then was discharged with the diagnosis of lateral, posterior, and inferior acute ST-elevated myocardial infarction due to coronary spasm/Kounis syndrome, triggered by acetaminophen.

This work is licensed under Creative Common Attribution-NonCommercial-NoDerivatives 4.0 International (CC BY-NC-ND 4.0)



Indexed in: [PMC] [PubMed] [Emerging Sources Citation Index (ESCI)] [Web of Science by Clarivate]

## Discussion

The signs and symptoms of allergy, hypersensitivity, and anaphylaxis-related cardiovascular problems have been documented in the literature for 7 decades, starting in England, Germany, and Austria [2,3,8]. The first case report was of a 49-year-old man with urticaria-related acute myocardial infarction [1], effectively controlled with 300 000 UI/day of penicillin. However, it was not until 1991 that the term „allergic angina syndrome" was introduced to describe a type of coronary spasm characterized by endocardial dysfunction or microvascular angina, which progressed to allergic myocardial infarction. Since then, allergy-related coronary problems have been described in a wide range of patients [9], affecting people of all ages, with more and more triggering variables being discovered. Mast cells, which interact with macrophages and T-lymphocytes via multidirectional stimulation, are the major inflammatory cells implicated in the development of Kounis syndrome. When allergens cross-bridge their matching, receptor-bound immunoglobulin E antibodies on the mast cell or basophil cell surface, an allergic, hypersensitive, or anaphylactic response occurs. Degranulation of mast cells occurs during allergy, hypersensitivity, or anaphylaxis, then a range of stored and subsequently produced inflammatory mediators are released locally and in the systemic circulation. These include histamine, chemokines, neutral proteases chymase, tryptase, cathepsin-D, peptides, proteoglycanes, cytokines, growth factors, leukotrienes, thromboxane, prostacyclin, and tumor necrosis factor. Almost all of these mediators have significant cardiovascular effects [12]. Other authors identified allergic angina as a subgroup of dynamic coronary occlusion lesions in which the reaction effects histamine or leukotrienes exerted on coronary vascular smooth muscle cells can cause vasospastic angina, implying that even common allergic responses can cause plaque disruption [10].

Mast cell activation, or the so-called Kounis syndrome, manifests itself in a variety of clinical manifestations. In the only prospective trial to date [6], 793 allergic patients were detected among 138 911 patients hospitalized in the emergency department over the course of 1 year. The incidence of Kounis syndrome was 19.4/100 000 (27/138 911) and 3.4% (27/793), respectively, among all emergency department patients and allergy patients. Nevertheless, while Kounis syndrome is not uncommon, it is rarely documented or recognized in clinical practice, owing to misdiagnosis. As a result, there are not enough trials to reliably define the incidence of Kounis syndrome. A meta-analysis [11] found 173 Kounis syndrome cases, with 74.3% of patients being male; the most common age was 51-60 years, but it can occur at any age; and the most common medical histories were allergies, hypertension, smoking, diabetes, and hyperlipidemia. Antibiotics, anticoagulants, non-steroid anti-inflammatory drugs, and others were identified as triggers [12]. There has recently been a report of Kounis syndrome in a patient receiving epirubicin injections for bladder cancer [13], as well as a case of type 1 Kounis syndrome caused by SARS-CoV-2 vaccination [14]. Many medications can cause allergic responses, which can lead to catastrophic consequences. Our patient was a 38-year-old man who smoked heavily, had diabetes and hyperlipidemia, but had no history of allergic responses. This was also consistent with previous research, with allergy history being found in just 25.1% of individuals [11]. Acute coronary syndrome, Takotsubo syndrome, and aortic artery dissection were some of the alternatives for our situation. Regarding the first option, we expected a much older patient with several cardiac risk factors, such as hypertension, physical inactivity, or a family history of cardiovascular disease. Despite this, a history of persistent chest discomfort, dyspnea, ST segments changes on ECG, and elevated troponin necessitates further testing, including coronary angiography. Takotsubo syndrome, on the other hand, is more common in postmenopausal women who have been exposed to emotional or physical stress, either from the environment or from medications, and who have ventricular apical akinesia, which we did not see during the left ventriculography phase of our patient. The latter diagnosis is most commonly made when a patient experiences significant chest or upper back discomfort, which is typically characterized as a tearing or ripping sensation, as well as a weak pulse in one arm or thigh relative to the other and uncontrolled hypertension. This did not apply to our case; therefore, we returned to Kounis syndrome.

Kounis syndrome is classified into 3 types: type 1 (72.6%) occurs when release of inflammation mediators causes coronary spasm with/without elevated cardiac enzymes; type 2 (22.3%) occurs when release of inflammation mediators causes coronary spasm along with plaque erosion or dissection, and presents as myocardial infarction; and type 3 (5.1%) is defined as coronary stent thrombosis after allergic reactions [12]. Kounis syndrome is mostly diagnosed based on clinical signs, along with laboratory findings, electrocardiogram signs, echocardiogram results, and evidence from coronary angiography. A thorough medical history-taking, including drug and allergy exposure, is essential. The cardiovascular system manifestations and allergic reactions are the most common clinical findings. The most prevalent cardiovascular symptoms are chest pain (86.9%), palpitation, and dyspnea. Acute myocardial infarction or severe anaphylactic reactions can cause pulmonary edema, which can lead to hypotension and shock. Allergic symptoms include rash, urticaria, and wheezing. Increased CK-MB (60.6%) and Troponin I or T indicate myocardial injury as a result of allergic responses. During an angina attack, an electrocardiogram often exhibits ST-T changes that are specific to ischemia, which are mostly elevated ST-segment (76%) or depressed ST-segment (17.1%). Measurement of IgE, histamine, chymase, tryptase, interferon, and interleukin-6 concentrations are other

This work is licensed under Creative Common Attribution-NonCommercial-NoDerivatives 4.0 International (CC BY-NC-ND 4.0)

Indexed in: [PMC] [PubMed] [Emerging Sources Citation Index (ESCI)] [Web of Science by Clarivate]

recommended laboratory tests. These tests, together with clinical findings, may help clinicians make more accurate diagnosis. Our patient exhibited angina and dyspnea, and an EKG obtained during the angina episode revealed ST-T alterations in multiple leads, as well as significant elevations in cardiac enzymes. As a result, the diagnosis of acute ST-elevated myocardial infarction was prioritized. We also discovered an elevated IgE level of 380.2 IU/mL (reference range: < 158 IU/mL). Along with no angina or apnea episodes, the electrocardiogram returned to normal after the drug infusion was stopped. Most importantly, the coronary angiography revealed unremarkable findings, leading us to conclude that this was a type 1 Kounis syndrome caused by a drug, specifically acetaminophen. There were a few acetaminophen hypersensitivity cases reported in the literature, including a case series [12] that reported 13 cases from 01/1999 to 12/2012, with clinical presentations ranging from urticaria, angioedema, to type 2 anaphylaxis and wheezing. Despite this, only 1 case of paracetamol/propyphenazone-related Kounis syndrome has been reported [16], which was a male patient with type 2 Kounis syndrome who was treated with a paclitaxel-eluting stent placed in the culprit artery. Our patient is the second paracetamol-related Kounis syndrome to be documented, as well as the first case of type 1 paracetamol-related Kounis syndrome.

Managing a Kounis syndrome patient can be difficult because the goals are to consider revascularization while also treating allergic/anaphylactic reactions. Patients with type 1 Kounis syndrome may benefit from allergy treatment because it also heals cardiac damage. Corticosteroids and antihistamine medications can also be used to reduce inflammation and alleviate allergic reactions [16,18]. Epinephrine should be used with caution in Kounis syndrome because it can aggravate ischemia, prolong the QT interval, and cause coronary spasms or arrhythmias [19]. Calcium channel blockers and nitrate have been shown to reduce vascular vasospasm [20]. Overall, the prognosis for Kounis syndrome is generally favorable, with almost all patients fully recovering, as early recognition of this clinical entity also comes with appropriate uses of corticosteroids, anti-histamines, epinephrine, and nitrates. This can be explained by the fact that the majority of Kounis syndrome cases are type 1 with vascular spasm that is effectively handled with vasodilation drugs. The prognosis of Kounis syndrome is correlated with previous reports of coronary vasospasm, which is also favorable.

## Conclusions

Kounis syndrome is not uncommon, but it is complicated and rarely recognized clinically. Treatment of allergic responses in type 1 Kounis syndrome can also help decrease cardiac symptoms, with a good prognosis as long as physicians detect the condition. The fundamental task to distinguishing other types of acute coronary syndromes is a through medical history-taking, and a patient who presents with allergic responses and clinical symptoms, ECG findings, and laboratory data consistent with acute ischemia should be examined for Kounis syndrome.

### Statement

The publication of this case was approved by the Ethics Committee for Biomedical Research at University Medical Center Ho Chi Minh City, and a consent form was signed by the patient.

### Acknowledgements

We are grateful to our colleagues at the Cardiovascular Center, University Medical Center Ho Chi Minh City for their great assistance.

### Declaration of Figures' Authenticity

All figures submitted have been created by the authors who confirm that the images are original with no duplication and have not been previously published in whole or in part.

## References:

1. Pfister CW, Plice SG. Acute myocardial infarction during a prolonged allergic reaction to penicillin. Am Heart J. 1950;40(6):945-47
2. Czickeli H. [Contribution to the problem of the allergic etiology of angina pectoris and myocardial infarct]. Klin Med Osterr Z Wiss Prakt Med. 1950;5(8): 364-67 [in German]
3. Schultheiss E. [Clinical aspects of allergic heart diseases]. Dtsch Med J. 1964;15:15-18 [in German]
4. Kovanen PT, Kaartinen M, Paavonen T. Infiltrates of activated mast cells at the site of coronary atheromatous erosion or rupture in myocardial infarction. Circulation. 1995;92(5):1084-88
5. Kounis NG. Coronary hypersensitivity disorder: The Kounis syndrome. Clin Ther. 2013;35(5):563-71
6. Akoz A, Tanboga H, Emet M, et al. A prospective study of kounis syndrome: Clinical experience and cardiac magnetic resonance imaging findings for 21 patients. Acta Medica Mediterranea. 2013;29:811-16
7. Desai R, Parekh T, Patel U, et al. Epidemiology of acute coronary syndrome co-existent with allergic/hypersensitivity/anaphylactic reactions (Kounis syndrome) in the United States: A nationwide inpatient analysis. Int J Cardiol. 2019;292:35-38
8. Clark E. Serum carditis: The morphologic cardiac alterations in man associated with serum disease. JAMA. 1938;110(14):1098-100
9. Fassio F, Almerigogna F. Kounis syndrome (allergic acute coronary syndrome): Different views in allergologic and cardiologic literature. Intern Emerg Med. 2012;7(6):489-95
10. Kounis NG, Koniari I, Velissaris D, et al. Kounis syndrome – not a single-organ arterial disorder but a multisystem and multidisciplinary disease. Balkan Med J. 2019;36(4):212-21
11. Abdelghany M, Subedi R, Shah S, et al. Kounis syndrome: A review article on epidemiology, diagnostic findings, management and complications of allergic acute coronary syndrome. Int J Cardiol. 2017;232:1-4

This work is licensed under Creative Common Attribution-NonCommercial-NoDerivatives 4.0 International (CC BY-NC-ND 4.0)



Indexed in: [PMC] [PubMed] [Emerging Sources Citation Index (ESCI)] [Web of Science by Clarivate]

12. Kounis NG. Kounis syndrome: An update on epidemiology, pathogenesis, diagnosis and therapeutic management. Clin Chem Lab Med. 2016;54(10):1545-59
13. Liang HZ, Zhao H, Gao J, et al. Epirubicin-induced Kounis syndrome. BMC Cardiovasc Disord. 2021;21(1):133
14. Özdemir İH, Özlek B, Özen MB, et al. Type 1 Kounis syndrome induced by inactivated SARS-COV-2 vaccine. J Emerg Med. 2021 [Online ahead of print]
15. Rojas-Pérez-Ezquerra P, Sánchez-Morillas L, Gómez-Traseira C, et al. Selective hypersensitivity reactions to acetaminophen: A 13-case series. J Allergy Clin Immunol Pract. 2014;2(3):343-45
16. Terzioğlu K, Ediger D, Tülümen Öztürk R, et al. Kounis syndrome not induced but prevented by the implantation of a drug-eluting stent: A case report. Anatol J Cardiol. 2017;17(5):412-13
17. Takagi S, Goto Y, Hirose E, et al. Successful treatment of refractory vasospastic angina with corticosteroids: Coronary arterial hyperactivity caused by local inflammation? Circ J. 2004;68(1):17-22
18. Ioannidis TI, Mazarakis A, Notaras SP, et al. Hymenoptera sting-induced Kounis syndrome: Effects of aspirin and beta-blocker administration. Int J Cardiol. 2007;121(1):105-8
19. Fassio F, Losappio L, Antolin-Amerigo D, et al. Kounis syndrome: A concise review with focus on management. Eur J Intern Med. 2016;30:7-10
20. Terlemez S, Eryılmaz U, Tokgöz Y, et al. Kounis syndrome caused by metronidazole – a case of 14 year-old boy. Int J Cardiol. 2015;179:222-24

This work is licensed under Creative Common Attribution-NonCommercial-NoDerivatives 4.0 International (CC BY-NC-ND 4.0)



Indexed in: [PMC] [PubMed] [Emerging Sources Citation Index (ESCI)] [Web of Science by Clarivate]