Ciliary beat pattern is associated with specific ultrastructural defects in primary ciliary dyskinesia

Mark A. Chilvers, MRCPCH, Andrew Rutman, and Christopher O'Callaghan, FRCPCH, PhD *Leicester, United Kingdom*

Background: The main symptoms of primary ciliary dyskinesia (PCD) are nasal rhinorrhea or blockage and moist-sounding cough. Diagnosis can be difficult and is based on an abnormal ciliary beat frequency, accompanied by specific abnormalities of the ciliary axoneme. It is unknown whether determining ciliary beat pattern related to specific ultrastructural ciliary defects might help in the diagnosis of PCD.
Objective: We sought to determine ciliary beat pattern and beat frequency (CBF) associated with the 5 common ultrastructural defects responsible for PCD.
Methods: Nasal brushings were performed on 56 children with PCD. Ciliary movement was recorded using digital high-speed video imaging to assess beat frequency and pattern. Electron microscopy was performed.
Results: In patients with an isolated outer dynein arm or with an outer and inner dynein arm defect, 55% and 80% of cilia were immotile, respectively. Cilia that moved were only flickering. Mean CBF (± 95% CI) was 2.3 Hz (± 1.2) and 0.8 Hz (± 0.8), respectively. Cilia with an isolated inner dynein arm or a radial spoke defect had similar beat patterns. Cilia appeared stiff, had a reduced amplitude, and failed to bend along their length. Immotile cilia were present in 10% of cilia with an inner dynein arm defect and in 30% of radial spoke defects. Mean CBF was 9.3 Hz (± 2.6) and 6.0 Hz (± 3.1), respectively. The ciliary transposition defect produced a large circular beat pattern (mean CBF, 10.7 Hz [± 1.1]). No cilia were immotile.
Conclusions: Different ultrastructural defects responsible for PCD result in predictable beat patterns. Recognition of these might help in the diagnostic evaluation of patients suspected of having PCD. (J Allergy Clin Immunol 2003;112:518-24.)

Key words: *Cilia, ultrastructure, dyskinesia, beat frequency, beat pattern*

The main clinical symptoms of patients with primary ciliary dyskinesia (PCD) are nasal rhinorrhea or blockage, a moist-sounding cough, and, in approximately 50%, hearing problems in early life. Despite persistent symptoms, and often attendance at ear, nose, and throat and respiratory clinics, many patients with PCD are not diagnosed until later in life,[1] by which time permanent lung damage has occurred.[2] Approximately 50% of patients with PCD have situs inversus.[3-5] Early and accurate diagnosis is important, because once made, lung function can be maintained with specialist respiratory care.[2,6] Failure to recognize the condition might also lead to inappropriate ear, nose, and throat surgery, leaving persistent aural discharge with little improvement in hearing loss.[3,7,8]

Abbreviations used
CBF: Ciliary beat frequency
DHSV: Digital high-speed video
PCD: Primary ciliary dyskinesia
TEM: Transmission electron microscopy

The diagnosis of PCD is traditionally made on the basis of a supportive clinical history and an abnormal ciliary beat frequency (CBF), accompanied in most cases by specific abnormalities of the ciliary axoneme on transmission electron microscopy (TEM).[3-5]

The most commonly used techniques (the modified photodiode[9] or photomultiplier method[10]) to measure CBF use an indirect method and do not provide information on ciliary beat pattern.

New high-resolution digital high speed video (DHSV) imaging has allowed the precise beat pattern of cilia to be viewed in 3 different planes in slow motion or frame by frame.[11] This shows that the widely held belief that respiratory cilia beat with a classical forward power stroke and then a recovery stroke that sweeps to the side[12] is incorrect. Cilia simply beat in a forward and backward planar motion without a sideways recovery sweep.[11]

DHSV analysis has also proved useful in determining the effect of viral infection on the movement of respiratory cilia. After a coronavirus infection, CBF of nasal respiratory cilia was found to remain within the normal range. However, slow-motion analysis revealed a large number of dyskinetic cilia.[13] This would have been missed by the conventional methods that rely solely on CBF measurement.

It has been suggested that evaluation of ciliary beat pattern, in addition to CBF, might be helpful in the diagnosis of PCD.[14,15] Indeed, one report suggested that some of the different ultrastructural defects found to cause PCD might have different beat patterns.[16] If specific beat patterns could be associated with each of the ultrastructural defects responsible for PCD, diagnostic testing might be improved.

From the Department of Child Health, University of Leicester School of Medicine.
Supported by the Cystic Fibrosis Trust (UK), Masons Medical Foundation.
Received for publication February 17, 2003; revised April 29, 2003; accepted for publication June 12, 2003.
Reprint requests: Christopher O'Callaghan, FRCPCH, PhD, Department of Child Health and Institute of Lung Health, University of Leicester School of Medicine, Robert Kilpatrick Clinical Sciences Building, Leicester Royal Infirmary, PO Box 65, Leicester, LE2 7LX England.
© 2003 Mosby, Inc. All rights reserved.
0091-6749/2003 $30.00 + 0
doi:10.1067/mai.2003.1701

TABLE I. Ciliary ultrastructural defects and clinical demographics of patients diagnosed with primary ciliary dyskinesia. The number of patients with the same structural defect is shown with mean age at diagnosis (range) and clinical symptoms and signs (n [%])

Ultrastructural defect	No. of patients (female)	Age (range) (y)	Chest (%)	Nasal (%)	Ear (%)	Situs inversus (%)
Inner and outer dynein arm defect	20 (9)	2.9 (0.1-10.0)	20 (100.0)	17 (85.0)	9 (45.0)	9 (45.0)
Outer dynein arm defect	16 (6)	4.5 (0.2–13.0)	16 (100.0)	15 (93.8)	11 (68.8)	9 (56.2)
Inner dynein arm defect	8 (3)	6.9 (0.1-11.0)	7 (87.5)	7 (87.5)	6 (75.0)	2 (25.0)
Radial spoke defect	4 (2)	3.6 (1.5-5.0)	4 (100.0)	4 (100.0)	1 (25.0)	3 (75.0)
Transposition defect	8 (4)	8.3 (0.4-14.0)	8 (100.0)	8 (100.0)	3 (37.5)	0 (0.0)
Total	56 (24)	4.7 (0.1-14)	55 (98.2)	51 (91.0)	30 (54.5)	23 (41.0)

The aim of this study was, therefore, to use high-resolution, DHSV photography to determine the precise ciliary beat pattern and CBF associated with the 5 common ultrastructural abnormalities responsible for PCD.

Our secondary aim was to define in detail, by use of TEM, the ultrastructural findings and ciliary orientation of cilia obtained by nasal brush biopsy from patients with the 5 most common ultrastructural defects responsible for PCD

METHODS

This study reports 56 children (5 weeks to 14 years [32 males]) who were diagnosed as having PCD at the Leicestershire PCD diagnostic clinic.

Information was collected evaluating chest, nasal, and ear symptoms. The presence of situs inversus was noted. Each subject had been free from upper respiratory tract infections or nasal and chest exacerbation in the previous 6 weeks. Medication was discontinued 48 hours before nasal brush biopsy.

Ciliated samples were obtained by brushing the inferior nasal turbinate without local anesthetic.[11] Nasal brushings were placed in medium 199 (pH 7.3) that contained antibiotic solution (streptomycin, 50 μg/mL, penicillin, 50 μg/mL, Gibco, Leicester, United Kingdom). Approval was obtained from the Leicestershire ethics committee. Written consent was obtained before sampling.

TEM

Tissue obtained by nasal brushing was processed for TEM by the standard techniques.[13]

Ciliary ultrastructure was examined without knowledge of ciliary beat pattern and beat frequency readings. Individual cilia were examined for microtubular and dynein arm defects. The total number of inner and outer dynein arms for each cilium were counted. Alignment of individual cilia within a cell was assessed by measuring ciliary orientation as previously described.[17] Percentages were calculated for the number of cilia with microtubular or dynein arm defects.

CBF and beat pattern

This was evaluated as previously described.[11,13] Ciliated epithelium of greater than 50 μm long was observed at 37°C using a ×100 interference contrast lens.

Beating ciliated edges were recorded using a DHSV camera (Kodak Motioncorder Analyser, Model 1000) at 400 frames per second. Video sequences could be recorded and played back at reduced frame rates or frame by frame.

The ciliated edge, projected onto a high-resolution monitor, was divided into 5 adjacent areas measuring 10 μm. A total of 10 measurements of CBF was made along each ciliated strip. At least 3 edges up to a maximum of 10 edges were analyzed per subject. CBF was determined directly. Groups of beating cilia were identified, and the number of frames required to complete 10 cycles was recorded. This was converted to CBF by a simple calculation.[11]

An immotility index was calculated as previously described.[18] If immotile cilia were observed, a CBF of 0 Hz was recorded. The immotility index was calculated as the percentage of immotile cilia within the sample (number of immotile readings/total number of readings for sample ×100).

The experimental system allowed the ciliary beat pattern to be evaluated in 3 different planes: a sideways profile, beating directly toward the observer, and from directly above.[11] The path taken by a cilium during the beat cycle was analyzed frame by frame. This was characterized and compared with the normal beat pattern seen on DHSV analysis.[11]

Statistics

The mean ciliary beat frequency, 95% CIs, and range were calculated. The mean percentage of immotile cilia and 95% CIs were calculated. For all ultrastructural parameters the mean and 95% CIs were calculated.

RESULTS

Patients could be categorized into 1 of 5 recognized ultrastructural defects.[3,4,19] This formed the following groups: isolated outer dynein arm defects, a combined defect of both outer and inner dynein arms, isolated inner dynein arm defects, radial spoke defect with an associated inner dynein arm defect (radial spoke defect), and transposition defect.

The clinical pictures of patients with PCD caused by different ultrastructural defects are shown (Table I). The mean age at diagnosis was 4.7 years (range, 0.1-14 years). More than 98% of patients had chronic chest symptoms, and 90% had chronic nasal symptoms. Ear symptoms were reported in half the subjects. Situs inversus was found in 41% of patients. None of the 8 (100%) patients with a transposition defect had situs inversus.

Nearly two thirds of the patients had either a combined inner and outer dynein arm defect (36%) or an isolated outer dynein arm defect (29%). The remaining ultrastructural defects were less common, with an isolated inner dynein arm defect responsible for 14%, a transposition defect 14%, and radial spoke defect 7%.

Each patient had an average of 15 ciliated cells (range, 5-36) and 310 individual cilia (range, 28-1067) examined by TEM. Detailed ciliary ultrastructural evaluation for each defect is shown (Tables II and III). In patients with isolated outer dynein arm defects, a combined defect of both outer and inner dynein arms, or an isolated inner

TABLE II. Assessment of microtubular abnormalities and ciliary orientation by transmission electron microscopy. Results displayed are for ultrastructural defect and expressed as the mean percentage (95% CIs)

Ultrastructural defect	Total microtubular defects (%)	Disarranged microtubules (%)	Extraperipheral microtubules (%)	Central microtubule defects (%)	Ciliary orientation (°)
Inner and outer dynein arm defect	3.4 (2.9-4.0)	0.8 (0.5-1.0)	0.8 (0.5-1.2)	1.8 (1.4-2.3)	21.6 (20.6-22.5)
Outer dynein arm defect	2.9 (1.9-4.1)	0.9 (0.4-1.5)	1.2 (0.3-2.2)	0.8 (0.5-1.2)	13.6 (12.7-14.5)
Inner dynein arm defect	5.7 (3.6-7.8)	2.4 (0.9-4.0)	0.4 (0.0-0.8)	2.9 (1.8-4.1)	17.8 (15.3-20.4)
Radial spoke defect	26.4 (23.7-29.1)	25.2 (22.5-27.9)	0.0 (0.0-0.0)	1.2 (0.6-1.8)	21.9 (20.1-23.8)
Transposition defect	22.8 (14.3-31.3)	7.8 (4.0-11.5)	0.8 (0.0-1.6)	14.2 (6.8-21.6)	21.1 (19.6-22.5)

TABLE III. Analysis of ciliary dynein arms by transmission electron microscopy. Results for individual ultrastructural defects are for individual dynein arm counts and the percentage of cilia with dynein arm defects. Results are expressed as the mean (95% CIs)

Ultrastructural defect	Dynein arm counts		Cilia with dynein arm defects (%)	Inner and outer dynein arm defect (%)	Outer dynein arm defect (%)	Inner dynein arm defect (%)
	Outer	Inner				
Inner and outer dynein arm defect	0.6 (0.5-0.7)	0.6 (0.4-0.7)	96.4 (94.5-98.2)	85.5 (74.3-96.7)	2.1 (0.5-3.6)	8.8 (0.0-19.5)
Outer dynein arm defect	1.3 (1.0-1.7)	6.3 (6.0-6.7)	96.0 (92.9-99.2)	5.1 (3.1-7.1)	90.9 (87.4-94.4)	0.0 (0.0-0.0)
Inner dynein arm defect	7.2 (7.0-7.4)	1.9 (1.4-2.3)	93.6 (92.5-96.2)	5.3 (2.2-8.5)	0.0 (0.0-0.0)	88.3 (85.0-91.6)
Radial spoke defect	7.1 (6.7-7.5)	0.9 (0.4-1.3)	96.0 (93.1-98.9)	4.3 (1.4-7.1)	0.0 (0.0-0.0)	91.7 (87.9-95.6)
Transposition defect	7.4 (7.1-7.6)	6.2 (5.9-6.5)	1.1 (0.2-2.0)	1.1 (0.2-2.0)	0.0 (0.0-0.0)	0.0 (0.0-0.0)

dynein arm defect, less than 5% of cilia had microtubular abnormalities; 25% of cilia with a radial spoke defect exhibited peripheral microtubular defects. Patients with ciliary transposition defect had a similar percentage of cilia with microtubular defects, but this predominantly involved the central microtubular pair. It is of interest that in all patients except those with an isolated outer dynein arm defect, ciliary orientation is markedly increased compared with the normal range[20] of <11°.

In patients with the following abnormalities: isolated outer dynein arm defect, combined defect of both outer and inner dynein arms, isolated inner dynein arm defect, and radial spoke defect with an associated inner dynein arm defect, 95% of cilia were found to exhibit the defect (Table III). Although referred to as absence of dynein arms, it was possible to identify at least 1 dynein arm. The dynein arms that were identified appeared abnormal (Table III).

Approximately 5% of cilia exhibited defects of both inner and outer dynein arms in the following ultrastructural groups: isolated outer dynein arm defect, isolated inner dynein arm defects, and radial spoke defect. Less than 1% of cilia with a transposition defect had associated defects of the outer and inner dynein arms (Table III).

No patients with PCD had cilia with a normal beat pattern (Fig 1, *A*; Table IV).[20] It was possible to categorize the patients into 3 groups on the basis of distinct dyskinetic beat patterns observed (Table IV).

Virtually immotile cilia (Fig 1, *b*, Table IV)

Cilia with either a combined inner and outer dynein arm defect or an isolated outer dynein arm defect were observed to have large areas of immotile cilia. Ciliary movement, when present, was restricted to a slow, short, stiff flickering motion (Fig 1, *B*). In the combined inner and outer dynein arm defect group, an average of 80% of cilia were immotile. The mean (± SD) CBF was 0.8 (± 1.7) Hz. In the outer dynein arm defect group, an average 55% of cilia were immotile. Cilia that were moving had a stiff flickering motion with a mean (± SD) beat frequency of 2.3 (± 2.6) Hz.

Stiff ciliary beat pattern (Fig 1, *c*, Table IV)

Cilia with an isolated inner dynein arm defect or a radial spoke with an isolated inner dynein arm defect were observed to have a very abnormal stiff forward power stroke with a markedly reduced amplitude. Cilia failed to bend along their axoneme (Fig 1, *C*). Ten percent of the cilia in patients with an isolated inner dynein arm defect were immotile. The remainder had a mean (± SD) CBF of 9.3 (± 4.0) Hz.

Cilia with a radial spoke defect associated with an inner dynein arm defect were found to beat in a similar manner to cilia from patients with an isolated inner dynein arm defect. Thirty percent of the cilia were immotile, and the remainder beat at a lower mean (± SD) CBF of 6.0 (± 3.3) Hz.







FIG 1. A, Diagram of the normal ciliary beat pattern. Cilia move in a planar motion with a forward power stroke and a backward recovery stroke that does not sweep to the side. **B,** Diagram of the dyskinetic beat pattern observed for cilia with either a combined inner and outer dynein arm defect or an isolated outer dynein arm defect. Cilia were virtually immotile, with the occasional slow, low-amplitude, stiff flickering motion. **C,** Diagram of the dyskinetic beat pattern observed for cilia with either an isolated inner dynein arm defect or a radial spoke defect. Cilia had a stiff planar forward-backward motion with markedly reduced amplitude. (Figure continued on next page.)

Circular beating cilia (Fig 1, *D*, Fig 2; Table IV)

This beat pattern was observed only in patients with a ciliary transposition defect. A forward and backward planar whiplike motion was seen when cilia were viewed from a side profile. However, when viewed from above, a large, circular, gyrating motion about the base of the cilium was apparent (Fig 1, *D*). None of the cilia were immotile, and they had a mean (± SD) CBF of 10.7 (± 1.6) Hz.

DISCUSSION

The advent of DHSV imaging has allowed us to define the ciliary beat pattern and beat frequency associated with 5 of the most common ultrastructural abnormalities responsible for PCD. The literature in this area is very sparse, and our results differ in a number of aspects from previous reports.[16,21] Three distinct beat patterns associated with underlying ultrastructural defects were seen.

The most common ultrastructural defect responsible for PCD are defects of the inner or outer dynein arms. In the isolated outer dynein arm defect and those patients with both an inner and outer dynein arm defect, most cilia were immotile. The few cilia that actually moved had a very stiff flickering motion. The frequency of these flickering cilia was slightly slower in those with a combined inner and outer dynein arm defect than in those with an isolated outer dynein arm defect. In addition, patients with a combined defect had a higher percentage of totally immotile cilia.

In previous studies, patients with inner and outer dynein arm defects[21,22] were noted to have a higher proportion of immotile cilia, although the actual percentage was not defined, and 2 different beat patterns were described, one as "vibrational" and the other as a "rotational egg beater."[16] In an article by Rossman et al,[16] the 5 patients with dynein arm defects were not split into those with isolated outer dynein arm defects or combined inner dynein and outer dynein arm defects. They reported the beat frequency of the cilia in this combined group to be 6 Hz, considerably higher than the frequency in our 20 patients with combined inner and outer dynein arm defects (0.8 Hz) and the 16 patients with outer dynein arm defects (2.3 Hz). In our study, the number of immotile cilia was shown to vary, depending on whether there was an isolated dynein arm defect (55% immotile) or a combined inner and outer dynein arm defect (80% immotile). The article by Rossman et al[16] suggested that 60% from their combined group were immotile.

The second beat pattern observed was that of a stiff forward stroke with a markedly reduced amplitude. This pattern was common to patients with an isolated inner dynein arm defect and also to those with a radial spoke defect associated with an inner dynein arm defect. The beat frequency of these 2 groups, however, was different. Patients with an isolated inner dynein arm defect had a mean beat frequency of 8.1 Hz compared with a beat frequency of 6 Hz in those with a radial spoke defect and an inner dynein arm defect. The number of immotile cilia also varied, depending on the defect with 10% of cilia immotile in those with an isolated inner dynein arm defect compared with more than 30% of cilia in patients with a radial spoke defect in association with an inner dynein defect. Rossman et al[16] did not consider inner



FIG 1. (continued) **D,** Diagram of the dyskinetic beat pattern observed for cilia with a transposition defect. Cilia beat in a large circular gyrating motion about the base of the cilium.

dynein arm defects separately, and the report of a single patient by Pederson[21] suggested that an asynchronized beat pattern was observed. The study by Pederson involved cilia observed at a room temperature of 22°C, so comparison of beat frequency is not possible. De Iongh and Rutland[23] observed the beat frequency in 2 patients with PCD caused by an inner dynein arm to be within the normal range.

Two patients with radial spoke defects described in the Rossman et al[16] study were found to have no immotile cilia. The beat frequency measured in these 2 patients was 9.6 Hz, which is higher than the frequency of 6 Hz in our 4 patients. The beat pattern they described for this defect was a biphasic rotational pattern that differs significantly from our findings of a stiff beat pattern with reduced amplitude.

The third beat pattern was that of an oval gyrating pattern in which cilia had a mean beat frequency of 10.7 Hz. We have previously investigated the normal CBF of healthy children and found the mean to be 12 Hz (range, 9.7-18.8 Hz).[20] In some cases, patients suspected of having PCD are screened using beat frequency measurement alone. The implication of these findings is that a number of patients with ciliary transposition will have a beat frequency within the normal range, and these patients will be missed unless beat pattern analysis and electron microscopy are undertaken. Two patients described by Rossman et al[16] with a ciliary transposition defect were found to have a CBF of 10 Hz and no immotile cilia. The pattern they described is one of a grabbing motion.

By use of DHSV, we have now shown that respiratory cilia simply beat forward and backward in the same plane without a sideways sweep.[11] All 3 beat patterns associated with PCD differ from the normal ciliary beat pattern. In fact, no cilia were seen in any of the patients to have a normal beat pattern.

The major benefit of the new video technology is that of high resolution and the ability to play back the movement of individual cilia frame by frame after their being recorded at a frequency of 400 to 600 Hz. This is a considerable advantage over previous methods such as that used by Rossman et al[16] in 1981 that allowed 60 frames per second. This, for example, only allows 5 or 6 frames per ciliary beat cycle compared with the high resolution 40 to 50 frames per cycle with the newer technology. Our method also allows visualization of the beat pattern in 3 distinct planes.[11] In addition, video records might be compiled and archived for audit.

Results of our study are in keeping with the postulated role of the various ultrastructural components of the ciliary axoneme. In the ciliary beat cycle, outer dynein arms are thought to generate the force to cause sliding of the peripheral microtubules[19,24,25] and to largely control CBF.[24,26]

The stiff beat pattern that we observed with inner dynein arm defects alone or those accompanied by radial spoke defects would support the evidence that the inner dynein arms assist in the bending of the ciliary axoneme.[24,26,27] Although the beat frequency of patients with inner arm defects is reduced, the reduction is only moderate compared with outer dynein arm defects. Radial spokes are thought to resist the sliding of the microtubules and cause the cilium to bend.[19,28] Although the cilium failed to bend in the combined radial spoke and

inner dynein arm defect, it was also observed in the inner dynein arm defect alone.

Little information is available on the action of the central microtubular pair. It has been postulated that the central pair might rotate during active ciliary bending.[28] It would seem that the central pair allows the cilium to beat in a forward and backward planar motion. Absence of the central pair for the short distance seen in patients with ciliary transposition seems to allow the cilia to rotate around this section.

The main aim was to look at the association between ciliary beat pattern and beat frequency with ultrastructural defect in patients with PCD. Our secondary aim was to perform quantitative ciliary ultrastructural analysis on this group of patients. We are aware of only 4 studies that have performed such analysis.[23,29-31] The data from these articles are somewhat limited. Only 1 study involved samples obtained by nasal brush biopsy,[23] 1 study solely analyzed microtubular defects,[31] and just 1 study placed patients into groups according to ultrastructural defect.[30]

In healthy tissue, it is possible to identify between 7 and 9 outer dynein arms and 4 and 7 inner dynein arms per ciliary cross-section.[32] Even with a dynein arm defect, we found it possible to identify 1 or 2 of the dynein arms. We found patients with an inner dynein arm, radial spoke, or transposition defects to have a normal number of outer dynein arms present. Similarly, normal numbers of inner dynein arms were observed in subjects with an outer dynein arm or transposition defect. This is in agreement with other published data for dynein arm defects.[30,32]

Five percent of cilia were observed to have microtubular defects in patients with dynein arm defects. This agrees with work by De Iongh and Rutland,[23] who found similar numbers of cilia to exhibit microtubular defects.

Ciliary orientation evaluates how individual cilia are aligned within a cell. This is uniform between cells and is <11° in healthy individuals.[20] Measurement of ciliary orientation in patients with PCD is limited, although it has been suggested to be increased.[23,29,30] No reports exist for ciliary orientation of individual ultrastructural defects. We found ciliary disorientation to be increased in all groups.

Two thirds of patients with PCD were found to have abnormalities of the dynein arms. This is a similar proportion of patients to previous studies.[18,23,33] However, we found a greater proportion of patients to have a ciliary transposition defect (14%). This is higher than in previous series, which have suggested a prevalence between 3% and 10%.[18,23,30,33,34] Because patients with a transposition defect have cilia that have a beat frequency within the normal range, it is likely that this group of patients is underdiagnosed.

Our results suggest that specific ultrastructural defects responsible for PCD result in specific abnormalities in beat pattern and beat frequency. It is clear that simply relying on beat frequency analysis alone, as measured by indirect measures such as the photodiode or photomultiplier systems, will not differentiate a proportion of patients with PCD from normals. The combination of beat frequency and beat pattern analysis with DHSV should improve the recognition of patients with underlying PCD.

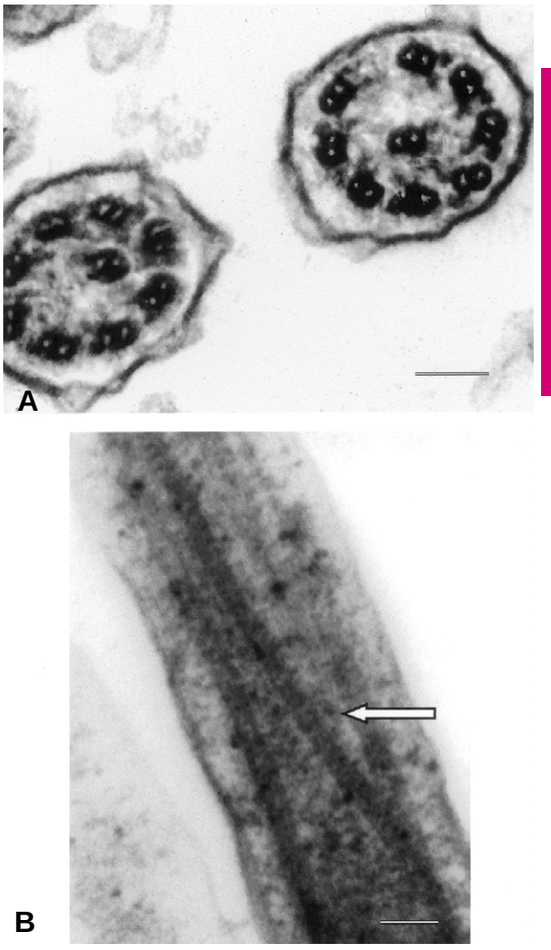

FIG 2. A, Electron micrograph of ciliary cross-section illustrating transposition defect. **B,** Electron micrograph of longitudinal section of ciliary axoneme illustrating the crossover of the peripheral microtubular doublet into the central position seen in the ciliary transposition defect.

In summary, we have been able to quantify CBF, beat pattern, and ultrastructural defects in patients with PCD. The CBF and beat pattern have been correlated with ultrastructural defects to form 3 distinct groups of dyskinetic beat patterns.

REFERENCES

1. Turner JA, Corkey CW, Lee JY, Levison H, Surgess J. Clinical expression of immotile cilia syndrome. Pediatrics 1981;67:805-10.
2. Ellerman A, Bisgaard H. Longitudinal study of lung function in a cohort of primary ciliary dyskinesia. Eur Resp J 1997;10:2376-9.
3. Bush A, Cole PJ, Hariri M, Mackay I, Phillips G, O'Callaghan C, et al. Primary ciliary dyskinesia: diagnosis and standards of care. Eur Respir J 1998;12:982-8.
4. Schidlow DV. Primary ciliary dyskinesia (the immotile cilia syndrome). Ann Allergy 1994;73:457-68.

TABLE IV. Summary of ciliary function. The 3 groups of beat pattern and corresponding ultrastructural defect, ciliary beat frequency, and immotility index are displayed. The mean (95% CIs) and range for ciliary beat frequency and mean (95% CIs) for the percentage of immotile cilia (immotility index) are shown. Normal ciliary beat frequency data are taken from reference 20.

		Ciliary beat frequency (Hz)			
Beat pattern	**Ultrastructural defect**	**Mean**	**95% CI**	**Range**	**Immotility index (%)**
Immotile cilia, flickering	Inner and outer dynein arm defect	0.8	0.0-1.6	0-7.2	79.8 (66.4-93.1)
	Outer dynein arm defect	2.3	1.1-3.5	0.0-8.1	55.0 (37.2-73.0)
Stiff planar motion	Inner dynein arm defect	8.1	6.7-9.5	5.6-10.6	9.1 (3.8-15.0)
	Radial spoke defect	6.0	2.8-9.1	3.8-10.8	31.4 (9.3-53.6)
Rotational motion	Transposition defect	10.7	9.6-11.8	8.6-13.9	0.0 (0.0-0.0)
Normal planar motion[20]	Normal	12.8	12.3-13.3	9.7-18.3	0.0 (0.0-0.0)

5. Meeks M, Bush A. Primary ciliary dyskinesia. Pediatr Pulmonol 2000;29:307-16.
6. Corkey CW, Levison H, Turner JAP. The immotile cilia syndrome. A longitudinal survey. Am Rev Respir Dis 1981;124:544-89.
7. Greenstone MA, Stanley P, Cole P, Mackay I. Upper airway manifestations of primary ciliary dyskinesia. J Laryngol Otol 1985;99:985-91.
8. Hadfield PJ, Rowes-Jones JM, Bush A, Mackay I. Treatment of otitis media with effusion in children with primary ciliary dyskinesia. Clin Otolaryngol 1997;22:302-6.
9. Teichtahl H, Wright PL, Kirsner RL. Measurement of in vitro ciliary beat frequency: a television-video modification of the transmitted light technique. Med Biol Eng Comp 1986;24:193-6.
10. Dalhamn T, Rylander R. Frequency of ciliary beat measured with a photosensitive cell. Nature 1962;196:592-3.
11. Chilvers M, O'Callaghan C. Analysis of ciliary beat pattern and beat frequency using digital high-speed imaging: comparison with the photomultiplier and photodiode methods. Thorax 2000;55:314-7.
12. Sanderson MJ, Sleigh MA. Ciliary activity of cultured rabbit tracheal epithelium: beat pattern and metachrony. J Cell Sci 1981;47:331-7.
13. Chilvers MA, McKean M, Rutman Myint S, Silverman M, O'Callaghan C. The effects of coronavirus on human nasal ciliated respiratory epithelium. Eur Respir J 2001;18:965-70.
14. Rossman CM, Newhous MT. Primary ciliary dyskinesia: evaluation and management. Pediatr Pulmonol 1988;5:36-50.
15. Santa Maria F, de Santi MM, Grillo G, Sarnelli P, Caterino M, Greco L. Ciliary motility at light microscopy: a screening test for ciliary defects? Acta Paediatr 1999;88:853-7.
16. Rossman CM, Forrest JB, Lee RMKW, Newhouse AF, Newhouse MT. The dyskinetic cilia syndrome: abnormal ciliary motility in association with abnormal ciliary ultrastructure. Chest 1981;80:860-4.
17. Rayner CFJ, Rutman A, Dewar A, Cole PJ, Wilson R. Ciliary disorientation alone as a cause of primary ciliary dyskinesia syndrome. Am J Respir Crit Care Med 1996;153:1123-9.
18. Greenstone MA, Rutman A, Dewar I, Mackay, Cole PJ. Primary ciliary dyskinesia: cytological and clinical features. Q J Med 1988;67:405-23.
19. Sturgess JM, Turner JAP. Ultrastructural pathology in the immotile cilia syndrome. Perspect Pediatr Pathol 1984;8:133-61.
20. Chilvers MA, Rutman A, O'Callaghan C. Functional analysis of cilia and ciliated epithelial ultrastructure in healthy children and young adults. Thorax 2003;58:333-8.
21. Pedersen M. Specific types of abnormal ciliary motility in Kartageners syndrome and analogous respiratory disorders. Eur J Respir Dis 1983;64 (Suppl 127):78-90.
22. Afzelius BA. A human syndrome caused by immotile cilia. Science 1976;193:317-9.
23. De Iongh RU, Rutland J. Ciliary defect in healthy subjects, bronchiectasis, and primary ciliary dyskinesia. Am J Respir Crit Care Med 1995;151:1559-67.
24. Wanner A, Salathe M, O'Riordan TG. Mucociliary clearance in the airways. Am J Respir Crit Care Med 1996;154:1868-902.
25. Sleigh MA, Blake JR, Liron N. The propulsion of mucous by cilia. Am Rev Respir Dis 1988;137:726-41.
26. Taylor HC, Satir P, Holwill MEJ. Assessment of inner dynein arm structure and possible function in ciliary and flagellar axonemes. Cell Motil Cytoskeleton 1999;43:167-77.
27. Brokaw CJ, Kamiya R. Bending patterns of Chlamydomonas flagella: IV. Mutants with defects in inner and outer dynein arms indicate differences in dynein arm function. Cell Motil Cytoskeleton 1987;8:68-75.
28. Omoto CK, Kung C. The pair of central tubules rotates during ciliary beat in *Paramecium*. Nature 1979;279:532-4.
29. Van der Baan S, Veerman AJP, Bezemer, PD, Feenstra L. Primary ciliary dyskinesia: quantitative investigation of the ciliary ultrastructure with statistical analysis. Ann Otol Rhinol Laryngol 1987:96;264-72.
30. Jorissen M, Willems T, Van der Schueren B, Verbeken E, De Boeck K. Ultrastructural expression of primary ciliary dyskinesia after ciliogenesis in culture. Acta Otorhinolaryngol Belg 2000;54:343-56.
31. Rossman CM, Lee RMKW, Forrest JB, Newhouse MT. Nasal ciliary ultrastructure and function in patients with primary ciliary dyskinesia compared with that in normal subjects and in subjects with various respiratory diseases. Am Rev Respir Dis 1984;129:161-7.
32. Jorissen M, Willems T, Van der Schueren, Verbeken E. Dynein arms and spokes after ciliogenesis in cultured respiratory epithelial cells from non-PCD individuals. Acta Otorhinolaryngol Belg 2000;54:325-32.
33. Sturgess JM, Thompson MW, Czegledy-Nagy E, Turner JAP. Genetic aspects of immotile cilia syndrome. Am J Med Genet 1986;25:149-60.
34. Min YG, Shin JS, Choi SH, Chi JG, Yoon CJ. Primary ciliary dyskinesia: ultrastructural defects and clinical features. Rhinol 1995;33:189-93.