Rethinking neutrophils and eosinophils in chronic rhinosinusitis

Tim Delemarre, MSc,[a] Bruce S. Bochner, MD,[b] Hans-Uwe Simon, MD, PhD,[c,d,e] and Claus Bachert, MD, PhD[a,f,g] *Ghent, Belgium; Chicago, Ill; Bern, Switzerland; Moscow and Kazan, Russia; Stockholm, Sweden; and Guangzhou, China*

Chronic rhinosinusitis (CRS) often is characterized by an eosinophilic inflammatory pattern, nowadays referred to as type 2 inflammation, although the mucosal inflammation is dominated by neutrophils in about a third of the patients. Neutrophils are typically predominant in 50% of patients with CRS without nasal polyps, but also are found to play a role in patients with severe type 2 CRS with nasal polyp disease. This review aims at summarizing the current understanding of the eosinophilic and neutrophilic inflammation in CRS pathophysiology, and provides a discussion of their reciprocal interactions and the clinical impact of the mixed presentation in patients with severe type 2 CRS with nasal polyps. A solid understanding of these interactions is of utmost importance when treating uncontrolled severe CRS with nasal polyps with biologicals that are preferentially directed toward type 2 inflammation. We here focus on recent findings on both eosinophilic and neutrophilic granulocytes, their subgroups and the activation status, and their interactions in CRS. (J Allergy Clin Immunol 2021;■■■:■■■-■■■.)

Key words: *Chronic rhinosinusitis, type 2 inflammation, eosinophils, neutrophils, activation, extracellular traps, Charcot-Leyden crystals, IL-17, biologicals*

HETEROGENEITY OF CHRONIC RHINOSINUSITIS

Chronic rhinosinusitis (CRS) is an increasing health problem affecting up to 15% of the population in western countries. Patients with CRS are phenotypically classified as CRS with nasal polyps (CRSwNP) and CRS without nasal polyps (CRSsNP).[1,2] Although phenotyping of CRS is well established, it has been demonstrated that both CRS phenotypes can be further differentiated into endotypes, on the basis of underlying immune responses and cellular differentiation.[3-5] CRSwNP is in general the most severe phenotype with high rates of recurrence and comorbid asthma, and is traditionally characterized by a strong type 2 biased eosinophilic inflammation and *Staphylococcus aureus* colonization rates of 67%.[5-8] CRSsNP, However, has long been considered a type 1-type 17 inflammation, with increased levels of IFN-γ, TNF-α, IL-17, and IL-21, and a predominant presence of neutrophils.[9-11] Although this dichotomous type 1-type 2 classification is still valid in general, CRS endotyping has stressed the complexity of CRS with a frequent presentation of mixed inflammatory patterns and cellular diversity, making it obvious that type 1-type 2 differentiation alone is not sufficient to explain the pathophysiology.[3,5,12-15]

Eosinophilic-neutrophilic inflammation has long been presented as black and white, almost implying mutual exclusion in CRS. Recent endotype-focused studies have challenged this traditional image, showing a more versatile picture than was anticipated on the basis of cytokine profiles in both patients with CRSsNP and patients with CRSwNP.[12,13] The most severe patients with CRSsNP have a predominant eosinophilic inflammation, and most patients with severe CRSwNP display a mixed pattern of eosinophilic-neutrophilic inflammation.

Despite the heterogeneity of CRS, there is a clear association between type 2 immune responses and the severity of clinical features in both CRSsNP and CRSwNP. Patients with CRS with a type 2 immune response have higher rates of recurrence and comorbid asthma, and a more frequent and severe presentation of clinical symptoms, whereas the presence of a type 1 or type 17 inflammation is inversely correlated with recurrence and associated with a milder clinical picture.[5,12,16-18] Interestingly, the fraction of patients with CRS with a type 2 inflammation is significantly increasing in both white and Asian populations.[15,19,20] Because type 2 inflammation is the decisive factor for disease severity in both CRSsNP and CRSwNP, this review will be focused on eosinophilic and neutrophilic inflammation, their interplay, and the clinical relevance in CRS with a type 2 immune response.

From [a]the Upper Airways Research Laboratory, Faculty of Medicine, Ghent University, Ghent; [b]the Division of Allergy and Immunology, Department of Medicine, Northwestern University Feinberg School of Medicine, Chicago; [c]the Institute of Pharmacology, University of Bern, Bern; [d]the Department of Clinical Immunology and Allergology, Sechenov University, Moscow; [e]the Laboratory of Molecular Immunology, Institute of Fundamental Medicine and Biology, Kazan Federal University, Kazan; [f]the Division of ENT Diseases, CLINTEC, Karolinska Institute, Stockholm; and [g]the First Affiliated Hospital, Sun Yat-Sen University, International Airway Research Center, Guangzhou.

C.B. was supported by grants from Flams wetenschappelijk Onderzeok (FWO) Flanders (grant no. 1515516N, Excellence of Science [EOS] project no. GOG2318N), the Interuniversity Attraction Poles Grant P7/30, and Sanofi (grant nos. A17/TT/1942 and A19/TT/0828). B.S.B. is supported in part by a grant from the National Institute of Allergy and Infectious Diseases (grant no. U19AI136443). H.-U.S. is supported by grants from the Swiss National Science Foundation (grant no. 310030_184816). H.-U.S. also acknowledges financial support by the Russian Government Program "Recruitment of the Leading Scientists into the Russian Institutions of Higher Education."

Disclosure of potential conflicts of interest: B. S. Bochner has received research funding from Acerta Pharma/AstraZeneca, as well as consulting fees from Regeneron, Sanofi, and GlaxoSmithkline (GSK); receives remuneration for serving on the Scientific Advisory Board of Third Harmonic Bio and Allakos, Inc; owns stock in Allakos; is a coinventor on existing Siglec-8–related patents and thus may be entitled to a share of royalties received by Johns Hopkins University during development and potential sales of such products; and is also a cofounder of Allakos; the terms of this arrangement are being managed by Johns Hopkins University and Northwestern University in accordance with their conflict of interest policies. H.-U. Simon is a consultant for AstraZeneca, GSK, and Esocap. C. Bachert has received research funding and/or is a consultant for Sanofi, Regeneron, Genzyme, Novartis, and GSK.

Received for publication January 27, 2021; revised March 15, 2021; accepted for publication March 18, 2021.

Corresponding author: Claus Bachert, MD, PhD, Upper Airways Research Laboratory, Department Head & Skin, Ghent University, UZ Ghent, C. Heymanslaan 10, 9000 Ghent, Belgium. E-mail: Claus.Bachert@ugent.be.

0091-6749/$36.00

© 2021 American Academy of Allergy, Asthma & Immunology

https://doi.org/10.1016/j.jaci.2021.03.024

Abbreviations used

CD:	Cluster of differentiation
CLC:	Charcot-Leyden crystal
CRS:	Chronic rhinosinusitis
CRSsNP:	CRS without nasal polyps
CRSwNP:	CRS with nasal polyps
DMBT1:	Deleted in malignant brain tumor 1
EET:	Eosinophil extracellular trap
GCS:	Glucocorticosteroid
NET:	Neutrophil extracellular trap

Type 2 CRSsNP

About 50% of the white patients with CRSsNP show a mild to moderate—in some cases mixed—type 2 inflammation, similar but less pronounced compared with those with severe CRSwNP.[5,12,16] Type 2 immune responses in CRSsNP are—just like their CRSwNP counterparts—characterized by increased levels of IL-4, IL-5, total IgE, *Staphylococcus aureus* enterotoxin-specific IgE, and eosinophil cationic protein, and elevated numbers of eosinophils in both the blood and nasal mucosa.[12] In addition, eosinophil extracellular traps (EETs) and Charcot-Leyden crystal (CLC, the crystalized form of galectin-10) deposition are also present in CRSsNP, and strongly associated with the underlying type 2 inflammation.[12] The number of neutrophils, however, are unaltered in the blood and mucosa of patients with type 2 CRSsNP.[12]

Interestingly, the presentation of an eosinophilic type 2 inflammation in patients with CRSsNP is associated with a worse clinical outcome, indicated by increased ratios of comorbid asthma, headache, and nasal polyp recurrence over 12 years, and reduced smell/taste.[12,16] In addition, tissue eosinophilia in CRSsNP is associated with disease severity, defined by computed tomography, endoscopy, and Smell Identification Test scores, and reduced improvement in disease-specific and general quality of life after surgery.[21,22]

Type 2 CRSwNP

The patients with most severe CRSwNP display a type 2 inflammatory pattern—a phenomenon observed internationally in Europe, the United States, and Asia—, associated with profound eosinophilic inflammation.[5,16,20] This eosinophilic inflammation is characterized by increased eosinophil infiltration and the presence of EETs in association with *S aureus* colonization and CLCs, mainly subepithelially at sites where the epithelial barrier is damaged.[7,12,20,23-25]

Interestingly, several studies over the last decade report the existence of a mixed eosinophilic-neutrophilic inflammation in patients with CRSwNP.[4,26] Chinese studies found that 35.8% of the patients with CRSwNP displayed a mixed phenotype, associated with type 2 inflammation.[27,28] In the western population, 26% of patients with CRSwNP have been reported to display a mixed inflammation pattern.[29] Indeed, a substantial neutrophilic inflammation co-occurring with—and affected by—eosinophilia was recently demonstrated in most patients with severe type 2 CRSwNP (Fig 1).[13,23] In addition, a CRS cluster analysis demonstrated elevated levels of neutrophil-related proteins, such as IL-6, IL-8, and myeloperoxidase, in patients with highly type 2 eosinophilic CRSwNP, with a severe clinical outcome.[5]

For asthma it is well known that the presentation of a mixed type 2-type 17 inflammatory pattern is associated with a mixed eosinophilic-neutrophilic picture, as observed in the more severe and difficult to control asthma phenotype.[30,31] In contrast, in CRS, the most severe patient group shows a predominant type 2 inflammation with high levels of neutrophil-related proteins, but low IL-17 levels, not linking type 17 to neutrophilia and disease severity.[5,32] This indicates that although there is more of a predominant type 2 inflammation than a mixed type 2-type 17 inflammation, the patients with most severe CRSwNP do have a mixed eosinophilic-neutrophilic inflammation. Despite the fact that IL-17 is traditionally considered a major driving force of neutrophilia, these findings show that IL-17 levels are not a good indicator for the presence of neutrophils in the tissue of patients with severe type 2 CRSwNP.[5,13] However, this seems to be the case specifically for patients with CRSwNP with a severe type 2 inflammation, because some nonendotype-based studies still observed a regulatory role for IL-17 on neutrophils in CRSwNP.[33] Interestingly, CLCs could be functional to orchestrate neutrophilia specifically in this severe CRSwNP group, as we will discuss later in this review.[13,23,24]

EOSINOPHILIC INFLAMMATION

Increased eosinophilic inflammation is a hallmark of severe CRSwNP in white patients, whereas patients with CRSsNP with a type 2 immune response also display a certain degree of eosinophilic inflammation—albeit far less severe compared with CRSwNP.[7,12,13] Recruitment of eosinophils in the tissue of CRS is well known to be mediated by IL-5, RANTES, and eotaxins, but recent studies also demonstrated increased eosinophil migration toward *S aureus* at subepithelial regions in CRSwNP tissue.[4,7,34-37] Interestingly, eosinophils have increased potential to affect the CRS pathophysiology due to their prolonged survival in CRS tissue, supported by elevated levels of IL-5, IL-33, and thymic stromal lymphopoietin, protecting the eosinophils from apoptosis.[36-42] IL-33 and thymic stromal lymphopoietin could also stimulate eosinophils and their recruitment toward impaired epithelium indirectly, by inducing IL-5 secretion of group 2 innate lymphoid cells.[7,43]

Increased cluster of differentiation (CD)69 expression—a marker for eosinophil activation—was observed in eosinophils present in the nasal polyps compared with those in the blood of patients with CRSwNP.[44-46] Interestingly, eosinophils are already in a priming state in the blood of patients with CRSwNP, which indicate that while eosinophils are in an increased state of preparedness in the blood of patients with CRSwNP, they are locally activated in the nasal polyp tissue.[47]

Once activated, eosinophils are known to secrete cytotoxic granule proteins with a primary role in protective immunity, but are very toxic at high concentrations, contributing to tissue damage and remodeling.[48-52] Besides protein mediators, eosinophils produce proinflammatory lipids as cysteinyl leukotrienes that can further promote eosinophil recruitment, mucus secretion, and increased vascular permeability in CRSwNP.[53-55] Eosinophils have also been reported to produce anti-inflammatory prostaglandin E_2 and proinflammatory prostaglandin D_2, but levels of prostaglandin E_2 are decreased, whereas levels of prostaglandin D_2 are increased in CRSwNP.[53,56]

Another way by which eosinophils can cause tissue damage is through formation of EETs, as observed in the tissue of both

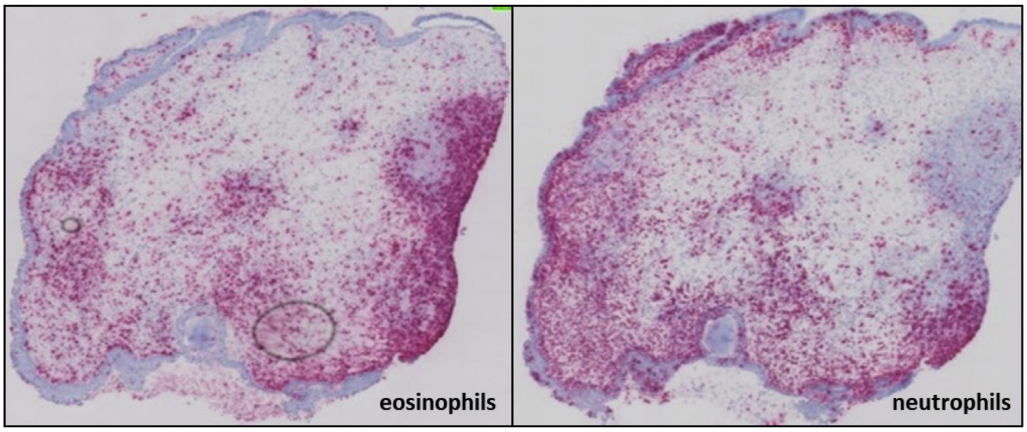

FIG 1. Mixed presence of eosinophils and neutrophils in CRSwNP. Eosinophils (*left*) and neutrophils (*right*) in the mucosa of CRSwNP *via* IHC staining of major basic protein (MBP) and elastase, respectively.

patients with CRSsNP and patients with CRSwNP with a type 2 inflammation.[7,12] These EETs consist of extracellular DNA and contain large amounts of granule proteins, which can facilitate capturing and killing of pathogens.[57] In CRSwNP, EETs are mainly observed in subepithelial regions with epithelial barrier defects, leading to the entrapment of *S aureus*.[7,25] EETs are also highly present in mucus from patients with eosinophilic CRS, increasing the mucus viscosity.[58] Interestingly, EET formation is closely associated with disease severity in CRS, regardless of the presence of NP.[59]

EET formation lays at the basis of CLC deposition, the crystalized form of galectin-10.[24,60] CLCs are abundantly present in the mucosa and mucus of both patients with CRSsNP and CRSwNP, and are associated with type 2 inflammation.[12,23,24] Recent discoveries have demonstrated that CLCs are more than a degradation product of eosinophils, because they affect the epithelial barrier and sustain a neutrophilic inflammation in CRSwNP.[23] An enhanced neutrophil migration caused by CLCs was observed both *in vitro* and in mouse models, and their association was confirmed in the tissue of patients with severe type 2 CRSwNP.[13,23,24] CLCs also contribute to inflammation by inducing neutrophilic inflammation and activate the NLR family pyrin domain containing 3 inflammasome after uptake by macrophages, causing IL-1β–driven inflammation.[23,61] However, only the crystalized form of galectin-10 elicits those proinflammatory effects in CRSwNP, whereas soluble galectin-10 displayed anti-inflammatory effects.[23] Recently developed CLC-dissolving antibodies suppressed airway inflammation, goblet-cell metaplasia, bronchial hyperreactivity, and IgE synthesis, induced by CLC or by house dust mite inhalation in a humanized mouse model.[24]

Type 2 CRSsNP, characterized by tissue eosinophilia with EET formation and CLC deposition, had significantly higher rates of asthma and recurrence, and reduced improvement in quality of life (based on Rhinosinusitis Disability Index and Chronic Sinusitis Survey scores), compared with CRSsNP without an eosinophilic type 2 response.[22,62] However, recurrence among patients with type 2 CRSsNP was still remarkably lower than that described in patients with CRSwNP (19% vs 79% after 12 years).[6,63] Also, in patients with CRSwNP, elevated numbers of activated eosinophils in the mucosa, and increased galectin 10 mRNA expression in the mucus, are associated with higher rates of recurrence.[64-66] Moreover, the presentation of an eosinophilic inflammation in CRSwNP was reflected by disease severity, defined by comorbid asthma, olfactory dysfunction, nasal polyp size, and degree of sinonasal inflammation on computed tomography scan.[5,44,55,65,67-69]

Interestingly, increased CLC mRNA expression was the only eosinophil-related mediator that correlates with olfactory loss in patients with CRSsNP and CRSwNP.[70] This matches the observation that the presence of EETs in the tissue of patients with CRS was associated with reduced olfactory function and higher Lund-Mackay scores, regardless of the presence of nasal polyps.[59] These data indicated that the activation of eosinophils, more than the presence alone, is decisive for the clinical outcome in both CRSsNP and CRSwNP. Identification of reliable eosinophil activation markers is thus essential for appropriate therapy assignment.

There are additional studies that may shed some light on how eosinophilic inflammation might be locally regulated within the nasal mucosa *via* production of endogenous factors. For example, the highly glycosylated protein DMBT1 (deleted in malignant brain tumor 1, also known as gp-340 and salivary agglutinin), produced within nasal mucosal glands and secreted into the nasal passage, is highly overexpressed in CRSwNP.[71] This has taken on greater significance with the recent discovery that a subset of nasal DBMT1 is decorated with unique and specific sialylated and sulfated glycan ligands for Siglec-8, a receptor selectively expressed on eosinophils and whose engagement causes eosinophils to die (so-called DMBT1[S8]). Whether the levels of DMBT1[S8] are altered in various forms of CRS is currently being investigated.[72,73]

Finally, it is important to recognize that there are some reports, such as those using antieosinophil pharmacologic approaches, that raise some interesting conundrums regarding the role of eosinophils in CRS. In a sizable study, an oral agent called dexpramipexole, which causes a gradual but marked reduction in eosinophils, was administered to explore its impact on signs and symptoms of CRSwNP. As expected, use of the drug resulted in an approximately 95% reduction in blood and NP eosinophils, but unexpectedly this resulted in no clinical improvement, and in fact an increase in tissue mast cells was observed.[74] A similar pattern was observed in a case report during treatment with reslizumab,

an anti–IL-5 antibody.[75] This is confusing because of favorable results in phase 2 trials of anti–IL-5 and anti–IL-5R antibody treatments (see below).

NEUTROPHILIC INFLAMMATION

Neutrophil infiltration has been found to be elevated in patients with severe type 2 CRSwNP.[13] As discussed above, neutrophilia can occur independent from IL-17 in several CRS endotypes, especially in severe type 2 immune responses. Interestingly, CLCs can orchestrate a neutrophilic inflammation and increased neutrophil infiltration correlated significantly with markers of severe eosinophilia as EETs and CLCs in patients with severe type 2 CRSwNP.[13] These findings imply that CLCs overrule IL-17 in the regulation of the increased neutrophil infiltration in severe type 2 immune responses. However, increased IL-8 production caused by CLCs indicate a potential indirect role for CLCs in the regulation of neutrophil recruitment, like demonstrated earlier for neutrophil elastase.[23,76] *S aureus* colonization is also linked to increased neutrophil migration in CRSwNP and could therefore have a prominent role *in vivo* triggering neutrophilia in CRSwNP.[8,77-79]

Increased neutrophil survival has been described in patients with severe asthma.[80-84] Interestingly, neutrophil survival was associated with tissue levels of IL-17 only in CRSsNP, but not in type 2 CRSwNP, underlining the IL-17 independency of neutrophilic inflammation in severe type 2 CRSwNP.[13] GM-CSF, G-CSF, TNF-α, and IL-4 stimulate the generation of long-living populations of neutrophils; however, the involvement of these cytokines in neutrophil survival, nor increased neutrophil survival, is yet to be described in type 2 CRSwNP.[13,84,85]

Although mature neutrophils are dominant in the blood of patients with CRSwNP, a significant shift of activated neutrophils is observed in the tissue of CRSwNP, indicating that neutrophils get activated once they enter the CRSwNP microenvironment.[13,86,87] Activated neutrophils contribute to the antibacterial cascade *via* phagocytosis of *S aureus* and oxidative burst, and are involved in the development of airway hyperreactivity.[88,89] Multiple studies reported increased proteolytic activity of both elastase and cathepsin G—granule proteins secreted by activated neutrophils—in the tissue of patients with type 2 CRSwNP.[13,26,87] Once secreted, elastase and cathepsin G are less effective in microbial killing, but are able to enhance secretion and activation of IL-1 family cytokines such as IL-1β, IL-33, and IL-36γ in an extremely efficient manner.[90] IL-1β and IL-33 are key players in the induction of type 2 responses in eosinophilic nasal polyps. In contrast, IL-36γ promotes the secretion of IL-8 and IL-17 from tissue neutrophils, reinforcing a positive feedback loop on their own recruitment.[26,91-93] Substrates for neutrophil proteases as elastin, collagen, and fibronectin are major components of the extracellular matrix, and their degradation is linked to tissue remodeling.[94] In addition, neutrophil serine proteases have a direct negative effect on the nasal epithelial barrier integrity and elastase can initiate goblet-cell metaplasia and increased mucus production.[83,95,96] These findings indicate that neutrophils are not only more frequent in a severe type 2 environment but they also affect the local inflammation *via* increased (proteolytic) activity.

Neutrophil extracellular traps (NETs), generally consisting of neutrophil DNA associated with granule proteins, are present in secretions of CRSwNP and at subepithelial regions in tissue of both patients with CRSsNP and patients with CRSwNP.[13,97-99] The pathway of NET formation is highly dependent on the individual micro-organism identity, pathogen size, and additional stimuli.[99-101] CLCs evoke neutrophil death *in vitro*, making it likely that CLCs in tissue and secretions might contribute to tissue damage in patients with CRS.[23,99] It should be noted that neutrophil cytolysis and NET formation are different phenomena with different underlying molecular mechanisms.[102] Moreover, *S aureus*—present in most patients with CRSwNP—has been found to degrade NETs, which then promotes its own survival.[103] This could explain the increased presence of NETs in patients with CRSsNP where NETs were shown to be associated with bacterial colonization, whereas CLC deposition is more pronounced in patients with CRSwNP.[12] In secretions of patients with eosinophilic CRSwNP, NETs were found to increase the mucus viscosity, leading to plug formation, hampering mucociliary clearance, and eventually airway damage.[104] Moreover, NETs could have proinflammatory effects on macrophages and stimulate tissue remodeling of the extracellular matrix.[99,101,105]

Interestingly, research over the last decade demonstrated the involvement of neutrophils in the establishment of a type 2 response, because double-stranded DNA associated with NETs may directly contribute to the pathogenesis by inducing a type 2 immune response.[106] IL-33 treatment of neutrophils resulted in a polarization of the cells and also in the elective production of type 2 cytokines, such as IL-4, IL-5, IL-9, and IL-13.[107] The expression of IL-9 in a subgroup of neutrophils was recently described in the tissue of patients with CRSwNP.[108] Understanding the heterogeneity of neutrophils in CRS, caused by microenvironment- or tissue-specific stimuli, could help in understanding their contribution across endotypes. So far, subsetting of neutrophils in CRS resulted in the identification of an activated subset ($CD16^{high}$ $CD62L^{dim}$) and IL-9–expressing neutrophils.[13,86,108] In asthma, in which NETs have been identified under *in vivo* conditions, it has been postulated that C-X-C chemokine receptor 4^{high} neutrophils are more prone to form NETs; however, no evidence on that has been found in the tissue of CRS so far.[109,110]

Markers of severe or moderate neutrophilic inflammation are elevated in patients with difficult to treat CRS, and increased presence of neutrophils in subepithelial regions of nasal polyps is associated with severe refractoriness of CRS.[111-113] Neutrophils produce high amounts of matrix metalloproteinase 9 in CRSwNP tissue, which is linked to poor wound healing quality and regeneration of tissue after functional endoscopic sinus surgery.[114-116] In spite of these insights, the contribution of neutrophils in the pathophysiology and persistence of CRS, especially in a type 2 context, remains largely unknown and needs attention to enable further improvement of treatments and endotyping of patients.

MIXED EOSINOPHILIC-NEUTROPHILIC INFLAMMATION

Based on the mixed presence described above, eosinophilic and neutrophilic inflammation cannot be seen as separate processes. Neutrophil infiltration was associated with EET formation and CLC deposition—hallmarks of eosinophilic inflammation—in patients with severe type 2 CRSwNP, and an increased neutrophil migration toward epithelial cells was observed on CLC stimulation *in vitro*.[13,23] In addition, it is known that activated neutrophils can enhance eosinophil transmigration, and that IL-8–mediated neutrophil recruitment induces an accumulation of eosinophils.[88,117,118] Interestingly, recent studies reported the

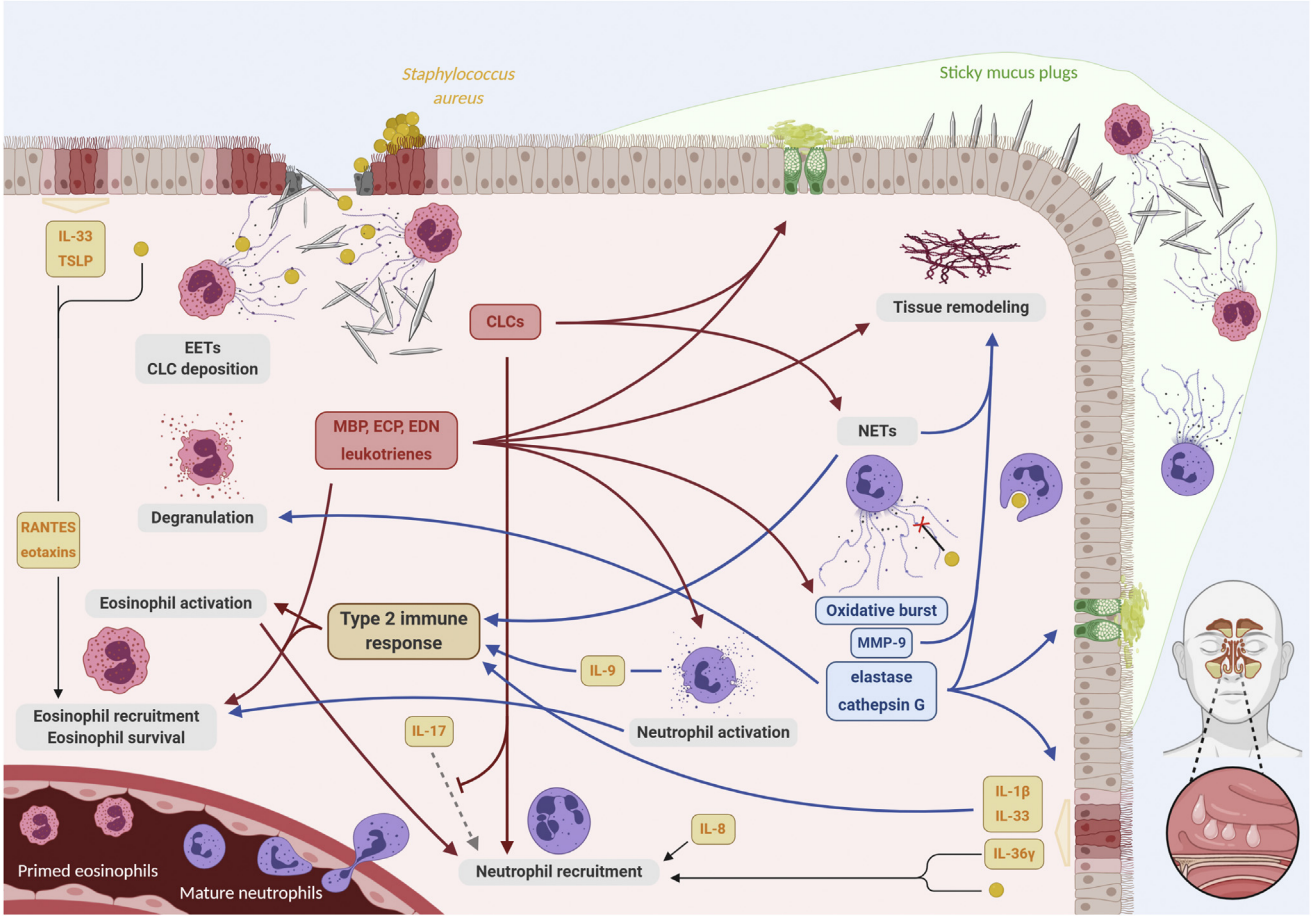

FIG 2. Pathophysiology of a mixed eosinophilic-neutrophilic inflammation in severe type 2 CRSwNP. Both an eosinophilic inflammation (*left side*) and a neutrophilic inflammation (*right side*) contribute to the pathophysiology in the mucosa of severe type 2 CRSwNP. Both responses impact the course of the disease, and reciprocal interactions between eosinophils and neutrophils contribute to the persistency and severity of the disease. *ECP*, Eosinophil cationic protein; *EDN*, eosinophil-derived neurotoxin; *MBP*, major basic protein; *MMP-9*, matrix metalloproteinase 9; *TSLP*, thymic stromal lymphopoietin.

expression of IL-5R and IL-9 on tissue neutrophils in asthmatic patients with CRSwNP and the potential of neutrophils to initiate a type 2 response that could lay the basis for eosinophil infiltration.[96,108,110,119] Also, in mice models, neutrophil proteases elastase and cathepsin G have been reported to induce eosinophil degranulation in a Ca^{+2}-dependent manner *in vitro*.[120] However, prostaglandin D_2 released by activated eosinophils can—in synergy with leukotriene E_4—enhance T_H2 responses and induce the production of nonclassical T_H2 inflammatory mediators, including IL-8 and GM-CSF at concentrations that would be sufficient to affect neutrophil migration, survival, and activation.[121] Moreover, eosinophil-derived major basic protein has the potential to activate neutrophils and stimulate its O_2^- production.[122,123] These findings indicate that, especially in patients with severe type 2 CRSwNP, interplay between eosinophils and neutrophils could be essential in the maintenance of the chronicity of the disease—even after targeting the eosinophilic inflammation—by stimulating each other's influx (Fig 2).

In severe asthma, it is well known that the mixed presence of eosinophils and neutrophils is associated with disease severity and a harder-to-treat phenotype, defined by glucocorticoid resistance and more pronounced airway obstruction and hyperreactivity compared with predominantly eosinophilic inflammation.[124-126] Recently, the same observations were made in white patients with CRSwNP, where an increased neutrophilic inflammation in association with eosinophilia was demonstrated in the patients with most severe, difficult to treat high type 2 CRSwNP who suffer reduction or loss of smell, severe nasal obstruction, and increased prevalence of asthma.[5,13] Patients with CRSwNP with a mixed granulocytic phenotype have increased severity of tissue inflammation with a greater overall inflammatory burden, reflected by worse computed tomography scores, olfactory function, disease-specific quality of life, and higher symptom burden, compared with patients with predominantly eosinophilic or neutrophilic CRSwNP.[29,68] The same observation was made in Asian patients with CRS regarding recurrence.[112] A mixed granulocytic presence in the sputum of patients with asthma was associated with severe comorbid CRS, as evaluated by the Lund-Mackay score.[127] Eosinophils and neutrophils can thus stimulate each other's influx in CRSwNP, which results in a mixed inflammation and the establishment of a more persistent and severe pathogenesis of CRSwNP.

TREATMENT STRATEGIES FOR EOSINOPHILIC-NEUTROPHILIC INFLAMMATION IN CRS

Glucocorticosteroids (GCSs) do target type 2 inflammatory responses better than non–type 2 responses; however, GCS resistance has been observed even in patients with type 2 CRSwNP.[27,128] This nonresponsiveness could be partially explained by the presence of a neutrophilic inflammation in CRSwNP because neutrophil-low polyps had significantly greater reductions in bilateral polyp scores, nasal congestion scores, and total symptom scores, compared with neutrophil-high patients.[27] Indeed, corticosteroid treatment decreases the eosinophilic inflammation, whereas the neutrophilic inflammation remains unaltered or even increases.[27,86,98,129-132]

Because of the predominant type 2 inflammatory pattern in patients with severe CRS, current therapies target the eosinophilic/type 2 inflammation via anti–IL-4Rα, anti-IgE, anti–IL-5, or IL-5Rα approaches.[3,133,134] Phase 3 trials have recently been reported with mepolizumab (anti–IL-5) and benralizumab (anti–IL-5Rα); dupilumab (anti–IL-4R) and xolair (anti-IgE) are already approved for CRSwNP in the United States and Europe. However, these innovative drugs reduce the polyp score only in about 30% to 70% of patients.[133,135-140] Recent studies demonstrated the presence of functional IL-5Rα on a number of other cells relevant in CRS, including neutrophils, plasma cells, and epithelial cells.[119,141,142] However, it is still unknown whether nonresponders are more neutrophilic than responders, but we do have evidence that neutrophils remain present in the tissue and keep affecting the pathogenesis in patients with a mixed eosinophilic-neutrophilic inflammation.[143] In fact, we recently observed the disappearance of eosinophils, EETs, and CLCs in subjects with CRSwNP, who were treated for asthma with mepolizumab and benralizumab for more than 6 months, but underwent surgery for resistant nasal polyps, whereas neutrophils were abundant in these nasal polyp tissues (personal observation). Interestingly, treatment of patients with bronchiectasis with brensocatib —an oral inhibitor of dipeptidyl peptidase 1 that is responsible for neutrophil serine protease activation—was associated with improvements in clinical outcomes in a 24-week trial.[144]

Patients with asthma diagnosed with predominant eosinophilic inflammation can be well controlled with GCSs or anti–IL-5 biologics. Patients with neutrophilic asthma, however, are often steroid insensitive, and to date the most effective treatment for this group is macrolides because there are currently no biologics approved for neutrophilic asthma. However, like CRSwNP, the most severe asthmatic patients have a mixed granulocytic inflammation and are difficult to control because they show a poor response to GCSs.[30,126,145] Moreover, gene signatures of neutrophils did not show any significant change after treatment with benralizumab (anti–IL-5Rα) in asthmatic patients.[146] These associations between CRSwNP and asthma indicate that these diseases are driven by comparable mechanisms; therefore, future insights into the mixed inflammation of patients with severe CRSwNP can be extrapolated to get a better understanding of asthma as well.

CONCLUSIONS AND FUTURE CLINICAL IMPLICATIONS

Although CRS is a complex disease with heterogeneous inflammatory patterns, there is a clear link between the presence of type 2 immunity and severity and persistency in both CRSsNP and CRSwNP. Severe type 2 CRSsNP is characterized by a predominant eosinophilic inflammation, whereas patients with severe type 2 CRSwNP display a mixed eosinophilic-neutrophilic inflammation. In the latter, the mixed inflammation is established by—among others —a wide range of reciprocal interactions between eosinophils and neutrophils themselves, establishing a difficult-to-manage disease. Treatments of predominant eosinophilic or neutrophilic inflammations are well established in airway disease and still in development, whereas patients with a mixed inflammation may be less responsive to these specific treatments. Therefore, new treatment options, targeting the mixed inflammation by a combination of biologics, may be helpful in certain patients with refractory severe and uncontrolled CRSwNP. Because this phenomenon is also observed in patients with severe asthma, new insights in the treatment of mixed inflammations in CRSwNP could be extrapolated for the treatment of patients with severe asthma, and *vice versa*.

REFERENCES

1. Khan A, Vandeplas G, Huynh TMT, Joish VN, Mannent L, Tomassen P, et al. The Global Allergy and Asthma European Network (GALEN rhinosinusitis cohort: a large European cross-sectional study of chronic rhinosinusitis patients with and without nasal polyps. Rhinology 2019;57:32-42.
2. Bachert C, Han JK, Wagenmann M, Hosemann W, Lee SE, Backer V, et al. EUFOREA expert board meeting on uncontrolled severe chronic rhinosinusitis with nasal polyps (CRSwNP) and biologics: definitions and management. J Allergy Clin Immunol 2021;147:29-36.
3. Bachert C, Zhang N, Hellings PW, Bousquet J. Endotype-driven care pathways in patients with chronic rhinosinusitis. J Allergy Clin Immunol 2018;141:1543-51.
4. Van Zele T, Claeys S, Gevaert P, Van Maele G, Holtappels G, Van Cauwenberge P, et al. Differentiation of chronic sinus diseases by measurement of inflammatory mediators. Allergy 2006;61:1280-9.
5. Tomassen P, Vandeplas G, Van Zele T, Cardell LO, Arebro J, Olze H, et al. Inflammatory endotypes of chronic rhinosinusitis based on cluster analysis of biomarkers. J Allergy Clin Immunol 2016;137:1449-56.e4.
6. Calus L, Van Bruaene N, Bosteels C, Dejonckheere S, Van Zele T, Holtappels G, et al. Twelve-year follow-up study after endoscopic sinus surgery in patients with chronic rhinosinusitis with nasal polyposis. Clin Transl Allergy 2019;9:30.
7. Gevaert E, Zhang N, Krysko O, Lan F, Holtappels G, De Ruyck N, et al. Extracellular eosinophilic traps in association with *Staphylococcus aureus* at the site of epithelial barrier defects in patients with severe airway inflammation. J Allergy Clin Immunol 2017;139:1849-60.e6.
8. Van Zele T, Gevaert P, Watelet JB, Claeys G, Holtappels G, Claeys C, et al. *Staphylococcus aureus* colonization and IgE antibody formation to enterotoxins is increased in nasal polyposis. J Allergy Clin Immunol 2004;114:981-3.
9. Cho SH, Kim DW, Gevaert P. Chronic rhinosinusitis without nasal polyps. J Allergy Clin Immunol Pract 2016;4:575-82.
10. Ahern S, Cervin A. Inflammation and endotyping in chronic rhinosinusitis—a paradigm shift. Medicina (Kaunas) 2019;55:95.
11. De Greve G, Hellings PW, Fokkens WJ, Pugin B, Steelant B, Seys SF. Endotype-driven treatment in chronic upper airway diseases. Clin Transl Allergy 2017;7:22.
12. Delemarre T, Holtappels G, De Ruyck N, Zhang N, Nauwynck H, Bachert C, et al. Type 2 inflammation in chronic rhinosinusitis without nasal polyps: another relevant endotype. J Allergy Clin Immunol 2020;146:337-43.e6.
13. Delemarre T, Holtappels G, De Ruyck N, Zhang N, Nauwynck H, Bachert C, et al. A substantial neutrophilic inflammation as regular part of severe type 2 chronic rhinosinusitis with nasal polyps. J Allergy Clin Immunol 2021;147:179-88.e2.
14. König K, Klemens C, Haack M, Nicoló MS, Becker S, Kramer MF, et al. Cytokine patterns in nasal secretion of non-atopic patients distinguish between chronic rhinosinusitis with or without nasal polys. Allergy Asthma Clin Immunol 2016;12:19.
15. Wang X, Zhang N, Bo M, Holtappels G, Zheng M, Lou H, et al. Diversity of T(H) cytokine profiles in patients with chronic rhinosinusitis: a multicenter study in Europe, Asia, and Oceania. J Allergy Clin Immunol 2016;138:1344-53.
16. Stevens WW, Peters AT, Tan BK, Klingler AI, Poposki JA, Hulse KE, et al. Associations between inflammatory endotypes and clinical presentations in chronic rhinosinusitis. J Allergy Clin Immunol Pract 2019;7:2812-20.e3.

17. Tan BK, Klingler AI, Poposki JA, Stevens WW, Peters AT, Suh LA, et al. Heterogeneous inflammatory patterns in chronic rhinosinusitis without nasal polyps in Chicago, Illinois. J Allergy Clin Immunol 2017;139:699-703.e7.
18. Van Zele T, Holtappels G, Gevaert P, Bachert C. Differences in initial immunoprofiles between recurrent and nonrecurrent chronic rhinosinusitis with nasal polyps. Am J Rhinol Allergy 2014;28:192-8.
19. Karin J, Tim D, Gabriele H, Cardell LO, Marit W, Claus B. Type 2 inflammatory shift in chronic rhinosinusitis during 2007-2018 in Belgium [published online ahead of print September 23, 2020]. Laryngoscope. https://doi.org/10.1002/lary.29128.
20. Zhang Y, Gevaert E, Lou H, Wang X, Zhang L, Bachert C, et al. Chronic rhinosinusitis in Asia. J Allergy Clin Immunol 2017;140:1230-9.
21. Soler ZM, Sauer DA, Mace J, Smith TL. Relationship between clinical measures and histopathologic findings in chronic rhinosinusitis. Otolaryngol Head Neck Surg 2009;141:454-61.
22. Soler ZM, Sauer D, Mace J, Smith TL. Impact of mucosal eosinophilia and nasal polyposis on quality-of-life outcomes after sinus surgery. Otolaryngol Head Neck Surg 2010;142:64-71.
23. Gevaert E, Delemarre T, De Volder J, Zhang N, Holtappels G, De Ruyck N, et al. Charcot-Leyden crystals promote neutrophilic inflammation in patients with nasal polyposis. J Allergy Clin Immunol 2020;145:427-30.e4.
24. Persson EK, Verstraete K, Heyndrickx I, Gevaert E, Aegerter H, Percier J-M, et al. Protein crystallization promotes type 2 immunity and is reversible by antibody treatment. Science 2019;364:eaaw4295.
25. Morshed M, Yousefi S, Stöckle C, Simon HU, Simon D. Thymic stromal lymphopoietin stimulates the formation of eosinophil extracellular traps. Allergy 2012;67:1127-37.
26. Wang H, Li ZY, Jiang WX, Liao B, Zhai GT, Wang N, et al. The activation and function of IL-36γ in neutrophilic inflammation in chronic rhinosinusitis. J Allergy Clin Immunol 2018;141:1646-58.
27. Wen W, Liu W, Zhang L, Bai J, Fan Y, Xia W, et al. Increased neutrophilia in nasal polyps reduces the response to oral corticosteroid therapy. J Allergy Clin Immunol 2012;129:1522-8.e5.
28. Wei Y, Zhang J, Wu X, Sun W, Wei F, Liu W, et al. Activated pyrin domain containing 3 (NLRP3) inflammasome in neutrophilic chronic rhinosinusitis with nasal polyps (CRSwNP). J Allergy Clin Immunol 2020;145:1002-5.e16.
29. Succar EF, Li P, Ely KA, Chowdhury NI, Chandra RK, Turner JH. Neutrophils are underrecognized contributors to inflammatory burden and quality of life in chronic rhinosinusitis. Allergy 2020;75:713-6.
30. Ray A, Kolls JK. Neutrophilic inflammation in asthma and association with disease severity. Trends Immunol 2017;38:942-54.
31. De Volder J, Vereecke L, Joos G, Maes T. Targeting neutrophils in asthma: a therapeutic opportunity? Biochem Pharmacol 2020;182:114292.
32. Derycke L, Eyerich S, Van Crombruggen K, Pérez-Novo C, Holtappels G, Deruyck N, et al. Mixed T helper cell signatures in chronic rhinosinusitis with and without polyps. PLoS One 2014;9:e97581.
33. Derycke L, Zhang N, Holtappels G, Dutre T, Bachert C. IL-17A as a regulator of neutrophil survival in nasal polyp disease of patients with and without cystic fibrosis. J Cyst Fibros 2012;11:193-200.
34. Hulse KE, Stevens WW, Tan BK, Schleimer RP. Pathogenesis of nasal polyposis. Clin Exp Allergy 2015;45:328-46.
35. Bachert C, Gevaert P, Holtappels G, Johansson SGO, van Cauwenberge P. Total and specific IgE in nasal polyps is related to local eosinophilic inflammation. J Allergy Clin Immunol 2001;107:607-14.
36. Simon HU, Yousefi S, Schranz C, Schapowal A, Bachert C, Blaser K. Direct demonstration of delayed eosinophil apoptosis as a mechanism causing tissue eosinophilia. J Immunol 1997;158:3902-8.
37. Nonaka M, Pawankar R, Saji F, Yagi T. Distinct expression of RANTES and GM-CSF by lipopolysaccharide in human nasal fibroblasts but not in other airway fibroblasts. Int Arch Allergy Immunol 1999;119:314-21.
38. Bagley CJ, Lopez AF, Vadas MA. New frontiers for IL-5. J Allergy Clin Immunol 1997;99:725-8.
39. Geering B, Stoeckle C, Conus S, Simon HU. Living and dying for inflammation: neutrophils, eosinophils, basophils. Trends Immunol 2013;34:398-409.
40. Ohno I, Lea R, Finotto S, Marshall J, Denburg J, Dolovich J, et al. Granulocyte/macrophage colony-stimulating factor (GM-CSF) gene expression by eosinophils in nasal polyposis. Am J Respir Cell Mol Biol 1991;5:505-10.
41. Wong CK, Hu S, Cheung PF, Lam CW. Thymic stromal lymphopoietin induces chemotactic and prosurvival effects in eosinophils: implications in allergic inflammation. Am J Respir Cell Mol Biol 2010;43:305-15.
42. Cherry WB, Yoon J, Bartemes KR, Iijima K, Kita H. A novel IL-1 family cytokine, IL-33, potently activates human eosinophils. J Allergy Clin Immunol 2008;121:1484-90.
43. Zhang N, Van Crombruggen K, Gevaert E, Bachert C. Barrier function of the nasal mucosa in health and type-2 biased airway diseases. Allergy 2016;71:295-307.
44. Yun Y, Kanda A, Kobayashi Y, Van Bui D, Suzuki K, Sawada S, et al. Increased CD69 expression on activated eosinophils in eosinophilic chronic rhinosinusitis correlates with clinical findings. Allergol Int 2020;69:232-8.
45. Matsumoto K, Appiah-Pippim J, Schleimer RP, Bickel CA, Beck LA, Bochner BS. CD44 and CD69 represent different types of cell-surface activation markers for human eosinophils. Am J Respir Cell Mol Biol 1998;18:860-6.
46. Julius P, Luttmann W, Knoechel B, Kroegel C, Matthys H, Virchow JC Jr. CD69 surface expression on human lung eosinophils after segmental allergen provocation. Eur Respir J 1999;13:1253-9.
47. Dupuch V, Tridon A, Ughetto S, Walrand S, Bonnet B, Dubray C, et al. Activation state of circulating eosinophils in nasal polyposis. Int Forum Allergy Rhinol 2018;8:584-91.
48. Yousefi S, Simon D, Simon HU. Eosinophil extracellular DNA traps: molecular mechanisms and potential roles in disease. Curr Opin Immunol 2012;24:736-9.
49. Frigas E, Motojima S, Gleich GJ. The eosinophilic injury to the mucosa of the airways in the pathogenesis of bronchial asthma. Eur Respir J Suppl 1991;13:123s-35s.
50. Soragni A, Yousefi S, Stoeckle C, Soriaga AB, Sawaya MR, Kozlowski E, et al. Toxicity of eosinophil MBP is repressed by intracellular crystallization and promoted by extracellular aggregation. Mol Cell 2015;57:1011-21.
51. Watelet JB, Bachert C, Claeys C, Van Cauwenberge P. Matrix metalloproteinases MMP-7, MMP-9 and their tissue inhibitor TIMP-1: expression in chronic sinusitis vs nasal polyposis. Allergy 2004;59:54-60.
52. Shimizu S, Ogawa T, Takezawa K, Tojima I, Kouzaki H, Shimizu T. Tissue factor and tissue factor pathway inhibitor in nasal mucosa and nasal secretions of chronic rhinosinusitis with nasal polyp. Am J Rhinol Allergy 2015;29:235-42.
53. Pérez-Novo CA, Watelet JB, Claeys C, Van Cauwenberge P, Bachert C. Prostaglandin, leukotriene, and lipoxin balance in chronic rhinosinusitis with and without nasal polyposis. J Allergy Clin Immunol 2005;115:1189-96.
54. Pérez-Novo CA, Claeys C, Van Zele T, Holtapples G, Van Cauwenberge P, Bachert C. Eicosanoid metabolism and eosinophilic inflammation in nasal polyp patients with immune response to *Staphylococcus aureus* enterotoxins. Am J Rhinol 2006;20:456-60.
55. Bochner BS, Stevens WW. Biology and function of eosinophils in chronic rhinosinusitis with or without nasal polyps. Allergy Asthma Immunol Res 2021;13:8-22.
56. Yoshimura T, Yoshikawa M, Otori N, Haruna S, Moriyama H. Correlation between the prostaglandin D(2)/E(2) ratio in nasal polyps and the recalcitrant pathophysiology of chronic rhinosinusitis associated with bronchial asthma. Allergol Int 2008;57:429-36.
57. Yousefi S, Gold JA, Andina N, Lee JJ, Kelly AM, Kozlowski E, et al. Catapult-like release of mitochondrial DNA by eosinophils contributes to antibacterial defense. Nat Med 2008;14:949-53.
58. Ueki S, Konno Y, Takeda M, Moritoki Y, Hirokawa M, Matsuwaki Y, et al. Eosinophil extracellular trap cell death-derived DNA traps: their presence in secretions and functional attributes. J Allergy Clin Immunol 2016;137:258-67.
59. Hwang CS, Park SC, Cho HJ, Park DJ, Yoon JH, Kim CH. Eosinophil extracellular trap formation is closely associated with disease severity in chronic rhinosinusitis regardless of nasal polyp status. Sci Rep 2019;9:8061.
60. Ueki S, Tokunaga T, Melo RCN, Saito H, Honda K, Fukuchi M, et al. Charcot-Leyden crystal formation is closely associated with eosinophil extracellular trap cell death. Blood 2018;132:2183-7.
61. Rodríguez-Alcázar JF, Ataide MA, Engels G, Schmitt-Mabmunyo C, Garbi N, Kastenmüller W, et al. Charcot-Leyden crystals activate the NLRP3 inflammasome and cause IL-1β inflammation in human macrophages. J Immunol 2019;202:550-8.
62. Smith TL, Litvack JR, Hwang PH, Loehrl TA, Mace JC, Fong KJ, et al. Determinants of outcomes of sinus surgery: a multi-institutional prospective cohort study. Otolaryngol Head Neck Surg 2010;142:55-63.
63. DeConde AS, Mace JC, Levy JM, Rudmik L, Alt JA, Smith TL. Prevalence of polyp recurrence after endoscopic sinus surgery for chronic rhinosinusitis with nasal polyposis. Laryngoscope 2017;127:550-5.
64. Vlaminck S, Vauterin T, Hellings P, Jorissen M, Acke F, Van Cauwenberge P, et al. The importance of local eosinophilia in the surgical outcome of chronic rhinosinusitis: a 3-year prospective observational study. Am J Rhinol Allergy 2014;28:260-4.
65. Vlaminck S, Acke F, Prokopakis E, Speleman K, Kawauchi H, van Cutsem JC, et al. Surgery in nasal polyp patients: outcome after a minimum observation of 10 years [published online ahead of print October 5, 2020]. Am J Rhinol Allergy. https://doi.org/10.1177/1945892420961964.

66. Qi S, Yan B, Liu C, Wang C, Zhang L. Predictive significance of Charcot-Leyden crystal mRNA levels in nasal brushing for nasal polyp recurrence. Rhinology 2020;58:166-74.
67. Hauser LJ, Chandra RK, Li P, Turner JH. Role of tissue eosinophils in chronic rhinosinusitis-associated olfactory loss. Int Forum Allergy Rhinol 2017;7:957-62.
68. Lou H, Meng Y, Piao Y, Zhang N, Bachert C, Wang C, et al. Cellular phenotyping of chronic rhinosinusitis with nasal polyps. Rhinology 2016;54:150-9.
69. Ikeda K, Shiozawa A, Ono N, Kusunoki T, Hirotsu M, Homma H, et al. Subclassification of chronic rhinosinusitis with nasal polyp based on eosinophil and neutrophil. Laryngoscope 2013;123:E1-9.
70. Lavin J, Min JY, Lidder AK, Huang JH, Kato A, Lam K, et al. Superior turbinate eosinophilia correlates with olfactory deficit in chronic rhinosinusitis patients. Laryngoscope 2017;127:2210-8.
71. Liu Z, Kim J, Sypek JP, Wang IM, Horton H, Oppenheim FG, et al. Gene expression profiles in human nasal polyp tissues studied by means of DNA microarray. J Allergy Clin Immunol 2004;114:783-90.
72. Gonzalez-Gil A, Li TA, Porell RN, Fernandes SM, Tarbox HE, Lee HS, et al. Isolation, identification, and characterization of the human airway ligand for the eosinophil and mast cell immunoinhibitory receptor Siglec-8 [published online ahead of print August 11, 2020]. J Allergy Clin Immunol. https://doi.org/10.1016/j.jaci.2020.08.001.
73. Bochner BS. "Siglec"ting the allergic response for therapeutic targeting. Glycobiology 2016;26:546-52.
74. Laidlaw TM, Prussin C, Panettieri RA, Lee S, Ferguson BJ, Adappa ND, et al. Dexpramipexole depletes blood and tissue eosinophils in nasal polyps with no change in polyp size. Laryngoscope 2019;129:E61-6.
75. Staudacher AG, Peters AT, Carter RG, Welch KC, Stevens WW. Decreased nasal polyp eosinophils but increased mast cells in a patient with aspirin-exacerbated respiratory disease treated with reslizumab. Ann Allergy Asthma Immunol 2020;125:490-3.e2.
76. Nakamura H, Yoshimura K, McElvaney NG, Crystal RG. Neutrophil elastase in respiratory epithelial lining fluid of individuals with cystic fibrosis induces interleukin-8 gene expression in a human bronchial epithelial cell line. J Clin Investig 1992;89:1478-84.
77. Suh JD, Ramakrishnan V, Palmer JN. Biofilms. Otolaryngol Clin North Am 2010;43, 521-530, viii.
78. Wang X, Du J, Zhao C. Bacterial biofilms are associated with inflammatory cells infiltration and the innate immunity in chronic rhinosinusitis with or without nasal polyps. Inflammation 2014;37:871-9.
79. Huvenne W, Callebaut I, Reekmans K, Hens G, Bobic S, Jorissen M, et al. *Staphylococcus aureus* enterotoxin B augments granulocyte migration and survival via airway epithelial cell activation. Allergy 2010;65:1013-20.
80. Grunwell JR, Stephenson ST, Tirouvanziam R, Brown LAS, Brown MR, Fitzpatrick AM. Children with neutrophil-predominant severe asthma have proinflammatory neutrophils with enhanced survival and impaired clearance. J Allergy Clin Immunol Pract 2019;7:516-25.e6.
81. Uddin M, Nong G, Ward J, Seumois G, Prince LR, Wilson SJ, et al. Prosurvival activity for airway neutrophils in severe asthma. Thorax 2010;65:684-9.
82. Sigua JA, Buelow B, Cheung DS, Buell E, Hunter D, Klancnik M, et al. CD49d-expressing neutrophils differentiate atopic from nonatopic individuals. J Allergy Clin Immunol 2014;133:901-4.e5.
83. Silvestre-Roig C, Hidalgo A, Soehnlein O. Neutrophil heterogeneity: implications for homeostasis and pathogenesis. Blood 2016;127:2173-81.
84. Chakravarti A, Rusu D, Flamand N, Borgeat P, Poubelle PE. Reprogramming of a subpopulation of human blood neutrophils by prolonged exposure to cytokines. Lab Invest 2009;89:1084-99.
85. Garley M, Jabłońska E. Heterogeneity among neutrophils. Arch Immunol Ther Exp (Warsz) 2018;66:21-30.
86. Arebro J, Drakskog C, Winqvist O, Bachert C, Kumlien Georén S, Cardell L-O. Subsetting reveals CD16high CD62Ldim neutrophils in chronic rhinosinusitis with nasal polyps. Allergy 2019;74:2499-501.
87. Kim YS, Han D, Kim J, Kim DW, Kim YM, Mo JH, et al. In-depth, proteomic analysis of nasal secretions from patients with chronic rhinosinusitis and nasal polyps. Allergy Asthma Immunol Res 2019;11:691-708.
88. Arebro J, Ekstedt S, Hjalmarsson E, Winqvist O, Kumlien Georen S, Cardell LO. A possible role for neutrophils in allergic rhinitis revealed after cellular subclassification. Sci Rep 2017;7:43568.
89. Ekstedt S, Säfholm J, Stenberg H, Tufvesson ET, Diamant Z, Bjermer L, et al. Dividing neutrophils in subsets, reveals a significant role for CD16highCD62L-dim neutrophils in the development of airway hyperreactivity. Eur Respir J 2019;54:PA4092.
90. Clancy DM, Henry CM, Sullivan GP, Martin SJ. Neutrophil extracellular traps can serve as platforms for processing and activation of IL-1 family cytokines. Febs J 2017;284:1712-25.
91. Schmitz J, Owyang A, Oldham E, Song Y, Murphy E, McClanahan TK, et al. IL-33, an interleukin-1-like cytokine that signals via the IL-1 receptor-related protein ST2 and induces T helper type 2-associated cytokines. Immunity 2005;23:479-90.
92. Teufelberger AR, Nordengrun M, Braun H, Maes T, De Grove K, Holtappels G, et al. The IL-33/ST2 axis is crucial in type 2 airway responses induced by *Staphylococcus aureus*-derived serine protease-like protein D. J Allergy Clin Immunol 2018;141:549-59.e7.
93. Kato A. Immunopathology of chronic rhinosinusitis. Allergol Int 2015;64:121-30.
94. Jasper AE, McIver WJ, Sapey E, Walton GM. Understanding the role of neutrophils in chronic inflammatory airway disease. F1000Research 2019;8:F1000, Faculty Rev-557.
95. Kao SS, Ramezanpour M, Bassiouni A, Wormald PJ, Psaltis AJ, Vreugde S. The effect of neutrophil serine proteases on human nasal epithelial cell barrier function. Int Forum Allergy Rhinol 2019;9:1220-6.
96. Voynow JA, Fischer BM, Malarkey DE, Burch LH, Wong T, Longphre M, et al. Neutrophil elastase induces mucus cell metaplasia in mouse lung. Am J Physiol Lung Cell Mol Physiol 2004;287:L1293-302.
97. Hwang JW, Kim JH, Kim HJ, Choi IH, Han HM, Lee KJ, et al. Neutrophil extracellular traps in nasal secretions of patients with stable and exacerbated chronic rhinosinusitis and their contribution to induce chemokine secretion and strengthen the epithelial barrier. Clin Exp Allergy 2019;49:1306-20.
98. Cao Y, Chen F, Sun Y, Hong H, Wen Y, Lai Y, et al. LL-37 promotes neutrophil extracellular trap formation in chronic rhinosinusitis with nasal polyps. Clin Exp Allergy 2019;49:990-9.
99. Delgado-Rizo V, Martínez-Guzmán MA, Iñiguez-Gutierrez L, García-Orozco A, Alvarado-Navarro A, Fafutis-Morris M. Neutrophil extracellular traps and its implications in inflammation: an overview. Front Immunol 2017;8:81.
100. Warnatsch A, Tsourouktsoglou TD, Branzk N, Wang Q, Reincke S, Herbst S, et al. Reactive oxygen species localization programs inflammation to clear microbes of different size. Immunity 2017;46:421-32.
101. Dicker AJ, Crichton ML, Pumphrey EG, Cassidy AJ, Suarez-Cuartin G, Sibila O, et al. Neutrophil extracellular traps are associated with disease severity and microbiota diversity in patients with chronic obstructive pulmonary disease. J Allergy Clin Immunol 2018;141:117-27.
102. Yousefi S, Stojkov D, Germic N, Simon D, Wang X, Benarafa C, et al. Untangling "NETosis" from NETs. Eur J Immunol 2019;49:221-7.
103. Thammavongsa V, Missiakas DM, Schneewind O. *Staphylococcus aureus* degrades neutrophil extracellular traps to promote immune cell death. Science 2013;342:863-6.
104. Ueki S, Melo RC, Ghiran I, Spencer LA, Dvorak AM, Weller PF. Eosinophil extracellular DNA trap cell death mediates lytic release of free secretion-competent eosinophil granules in humans. Blood 2013;121:2074-83.
105. Grabcanovic-Musija F, Obermayer A, Stoiber W, Krautgartner W-D, Steinbacher P, Winterberg N, et al. Neutrophil extracellular trap (NET) formation characterises stable and exacerbated COPD and correlates with airflow limitation. Respir Res 2015;16:59.
106. Toussaint M, Jackson DJ, Swieboda D, Guedan A, Tsourouktsoglou TD, Ching YM, et al. Host DNA released by NETosis promotes rhinovirus-induced type-2 allergic asthma exacerbation. Nat Med 2017;23:681-91.
107. Sun B, Zhu L, Tao Y, Sun H-X, Li Y, Wang P, et al. Characterization and allergic role of IL-33-induced neutrophil polarization. Cell Mol Immunol 2018;15:782-93.
108. Delemarre T, De Ruyck N, Holtappels G, Bachert C, Gevaert E. Unravelling the expression of interleukin-9 in chronic rhinosinusitis: a possible role for *Staphylococcus aureus*. Clin Transl Allergy 2020;10:41.
109. Dworski R, Simon HU, Hoskins A, Yousefi S. Eosinophil and neutrophil extracellular DNA traps in human allergic asthmatic airways. J Allergy Clin Immunol 2011;127:1260-6.
110. Radermecker C, Sabatel C, Vanwinge C, Ruscitti C, Maréchal P, Perin F, et al. Locally instructed CXCR4(hi) neutrophils trigger environment-driven allergic asthma through the release of neutrophil extracellular traps. Nat Immunol 2019;20:1444-55.
111. Liao B, Liu JX, Li ZY, Zhen Z, Cao PP, Yao Y, et al. Multidimensional endotypes of chronic rhinosinusitis and their association with treatment outcomes. Allergy 2018;73:1459-69.
112. Kim DK, Kim JY, Han YE, Kim JK, Lim HS, Eun KM, et al. Elastase-positive neutrophils are associated with refractoriness of chronic rhinosinusitis with nasal polyps in an Asian population. Allergy Asthma Immunol Res 2020;12:42-55.
113. Kim DK, Lim HS, Eun KM, Seo Y, Kim JK, Kim YS, et al. Subepithelial neutrophil infiltration as a predictor of the surgical outcome of chronic rhinosinusitis with nasal polyps [published online ahead of print October 31, 2020]. Rhinology. https://doi.org/10.4193/Rhin20.373.

114. Watelet JB, Demetter P, Claeys C, Van Cauwenberge P, Cuvelier C, Bachert C. Neutrophil-derived metalloproteinase-9 predicts healing quality after sinus surgery. Laryngoscope 2005;115:56-61.
115. Watelet JB, Claeys C, Van Cauwenberge P, Bachert C. Predictive and monitoring value of matrix metalloproteinase-9 for healing quality after sinus surgery. Wound Repair Regen 2004;12:412-8.
116. Watelet JB, Demetter P, Claeys C, Cauwenberge P, Cuvelier C, Bachert C. Wound healing after paranasal sinus surgery: neutrophilic inflammation influences the outcome. Histopathology 2006;48:174-81.
117. Nakagome K, Matsushita S, Nagata M. Neutrophilic inflammation in severe asthma. Int Arch Allergy Immunol 2012;158:96-102.
118. Kikuchi I, Kikuchi S, Kobayashi T, Hagiwara K, Sakamoto Y, Kanazawa M, et al. Eosinophil trans-basement membrane migration induced by interleukin-8 and neutrophils. Am J Respir Cell Mol Biol 2006;34:760-5.
119. Gorski SA, Lawrence MG, Hinkelman A, Spano MM, Steinke JW, Borish L, et al. Expression of IL-5 receptor alpha by murine and human lung neutrophils. PLoS One 2019;14:e0221113.
120. Liu H, Lazarus SC, Caughey GH, Fahy JV. Neutrophil elastase and elastase-rich cystic fibrosis sputum degranulate human eosinophils in vitro. Am J Physiol 1999; 276:L28-34.
121. Xue L, Fergusson J, Salimi M, Panse I, Ussher JE, Hegazy AN, et al. Prostaglandin D2 and leukotriene E4 synergize to stimulate diverse TH2 functions and TH2 cell/neutrophil crosstalk. J Allergy Clin Immunol 2015;135: 1358-66.e1-e11.
122. Haskell M, Moy J, Gleich G, Thomas L. Analysis of signaling events associated with activation of neutrophil superoxide anion production by eosinophil granule major basic protein. Blood 1995;86:4627-37.
123. Moy JN, Thomas LL, Whisler LC. Eosinophil major basic protein enhances the expression of neutrophil CR3 and p150,95. J Allergy Clin Immunol 1993;92: 598-606.
124. Irvin C, Zafar I, Good J, Rollins D, Christianson C, Gorska MM, et al. Increased frequency of dual-positive T_H2/T_H17 cells in bronchoalveolar lavage fluid characterizes a population of patients with severe asthma. J Allergy Clin Immunol 2014; 134:1175-86.e7.
125. Hastie AT, Moore WC, Meyers DA, Vestal PL, Li H, Peters SP, et al. Analyses of asthma severity phenotypes and inflammatory proteins in subjects stratified by sputum granulocytes. J Allergy Clin Immunol 2010;125:1028-36.e13.
126. Moore WC, Hastie AT, Li X, Li H, Busse WW, Jarjour NN, et al. Sputum neutrophil counts are associated with more severe asthma phenotypes using cluster analysis. J Allergy Clin Immunol 2014;133:1557-63.e5.
127. Nishio T, Wakahara K, Suzuki Y, Nishio N, Majima S, Nakamura S, et al. Mixed cell type in airway inflammation is the dominant phenotype in asthma patients with severe chronic rhinosinusitis. Allergol Int 2019;68:515-20.
128. Gurrola J II, Borish L. Chronic rhinosinusitis: endotypes, biomarkers, and treatment response. J Allergy Clin Immunol 2017;140:1499-508.
129. Green RH, Brightling CE, Woltmann G, Parker D, Wardlaw AJ, Pavord ID. Analysis of induced sputum in adults with asthma: identification of subgroup with isolated sputum neutrophilia and poor response to inhaled corticosteroids. Thorax 2002;57:875-9.
130. Pujols L, Alobid I, Benítez P, Martínez-Antón A, Roca-Ferrer J, Fokkens WJ, et al. Regulation of glucocorticoid receptor in nasal polyps by systemic and intranasal glucocorticoids. Allergy 2008;63:1377-86.
131. Cox G. Glucocorticoid treatment inhibits apoptosis in human neutrophils. Separation of survival and activation outcomes. J Immunol 1995;154:4719-25.
132. Liles WC, Dale DC, Klebanoff SJ. Glucocorticoids inhibit apoptosis of human neutrophils. Blood 1995;86:3181-8.
133. Bachert C, Han JK, Desrosiers M, Hellings PW, Amin N, Lee SE, et al. Efficacy and safety of dupilumab in patients with severe chronic rhinosinusitis with nasal polyps (LIBERTY NP SINUS-24 and LIBERTY NP SINUS-52): results from two multicentre, randomised, double-blind, placebo-controlled, parallel-group phase 3 trials. Lancet 2019;394:1638-50.
134. Pauwels B, Jonstam K, Bachert C. Emerging biologics for the treatment of chronic rhinosinusitis. Expert Rev Clin Immunol 2015;11:349-61.
135. Bachert C, Sousa AR, Lund VJ, Scadding GK, Gevaert P, Nasser S, et al. Reduced need for surgery in severe nasal polyposis with mepolizumab: randomized trial. J Allergy Clin Immunol 2017;140:1024-31.e14.
136. Bachert C, Zhang N, Cavaliere C, Weiping W, Gevaert E, Krysko O. Biologics for chronic rhinosinusitis with nasal polyps. J Allergy Clin Immunol 2020;145: 725-39.
137. Bachert C, Mannent L, Naclerio RM, Mullol J, Ferguson BJ, Gevaert P, et al. Effect of subcutaneous dupilumab on nasal polyp burden in patients with chronic sinusitis and nasal polyposis: a randomized clinical trial. JAMA 2016;315:469-79.
138. Gevaert P, Van Bruaene N, Cattaert T, Van Steen K, Van Zele T, Acke F, et al. Mepolizumab, a humanized anti-IL-5 monoclonal antibody, as a treatment option for severe nasal polyposis. J Allergy Clin Immunol 2011;128:989-95.e8.
139. Gevaert P, Omachi TA, Corren J, Mullol J, Han J, Lee SE, et al. Efficacy and safety of omalizumab in nasal polyposis: 2 randomized phase 3 trials. J Allergy Clin Immunol 2020;146:595-605.
140. Gevaert P, Calus L, Van Zele T, Blomme K, De Ruyck N, Bauters W, et al. Omalizumab is effective in allergic and nonallergic patients with nasal polyps and asthma. J Allergy Clin Immunol 2013;131:110-6.e1.
141. Barretto KT, Brockman-Schneider RA, Kuipers I, Basnet S, Bochkov YA, Altman MC, et al. Human airway epithelial cells express a functional IL-5 receptor. Allergy 2020;75:2127-30.
142. Buchheit KM, Dwyer DF, Ordovas-Montanes J, Katz HR, Lewis E, Vukovic M, et al. IL-5Rα marks nasal polyp IgG4- and IgE-expressing cells in aspirin-exacerbated respiratory disease. J Allergy Clin Immunol 2020;145:1574-84.
143. Lan F, Zhang L. Understanding the role of neutrophils in refractoriness of chronic rhinosinusitis with nasal polyps. Allergy Asthma Immunol Res 2020;12:1-3.
144. Chalmers JD, Haworth CS, Metersky ML, Loebinger MR, Blasi F, Sibila O, et al. Phase 2 trial of the DPP-1 inhibitor brensocatib in bronchiectasis. N Engl J Med 2020;383:2127-37.
145. Wu W, Bleecker E, Moore W, Busse WW, Castro M, Chung KF, et al. Unsupervised phenotyping of Severe Asthma Research Program participants using expanded lung data. J Allergy Clin Immunol 2014;133:1280-8.
146. Sridhar S, Liu H, Pham T-H, Damera G, Newbold P. Modulation of blood inflammatory markers by benralizumab in patients with eosinophilic airway diseases. Respir Res 2019;20:14.